This is a digital copy of a book that was preserved for generations on library shelves before it was carefully scanned by Google as part of a project to make the world's books discoverable online.

It has survived long enough for the copyright to expire and the book to enter the public domain. A public domain book is one that was never subject to copyright or whose legal copyright term has expired. Whether a book is in the public domain may vary country to country. Public domain books are our gateways to the past, representing a wealth of history, culture and knowledge that's often difficult to discover.

Marks, notations and other marginalia present in the original volume will appear in this file - a reminder of this book's long journey from the publisher to a library and finally to you.

Usage guidelines

Google is proud to partner with libraries to digitize public domain materials and make them widely accessible. Public domain books belong to the public and we are merely their custodians. Nevertheless, this work is expensive, so in order to keep providing this resource, we have taken steps to prevent abuse by commercial parties, including placing technical restrictions on automated querying.

We also ask that you:

+ *Make non-commercial use of the files* We designed Google Book Search for use by individuals, and we request that you use these files for personal, non-commercial purposes.

+ *Refrain from automated querying* Do not send automated queries of any sort to Google's system: If you are conducting research on machine translation, optical character recognition or other areas where access to a large amount of text is helpful, please contact us. We encourage the use of public domain materials for these purposes and may be able to help.

+ *Maintain attribution* The Google "watermark" you see on each file is essential for informing people about this project and helping them find additional materials through Google Book Search. Please do not remove it.

+ *Keep it legal* Whatever your use, remember that you are responsible for ensuring that what you are doing is legal. Do not assume that just because we believe a book is in the public domain for users in the United States, that the work is also in the public domain for users in other countries. Whether a book is still in copyright varies from country to country, and we can't offer guidance on whether any specific use of any specific book is allowed. Please do not assume that a book's appearance in Google Book Search means it can be used in any manner anywhere in the world. Copyright infringement liability can be quite severe.

About Google Book Search

Google's mission is to organize the world's information and to make it universally accessible and useful. Google Book Search helps readers discover the world's books while helping authors and publishers reach new audiences. You can search through the full text of this book on the web at `http://books.google.com/`

BOSTON
MEDICAL LIBRARY

IN THE
Francis A. Countway
Library of Medicine
BOSTON

TRANSACTIONS

OF THE

AMERICAN

OPHTHALMOLOGICAL SOCIETY.

Volume IX.

HARTFORD:
PUBLISHED BY THE SOCIETY.
1900.

BOSTON MEDICAL
MAR 6 1903
LIBRARY.

Press of The Case, Lockwood & Brainard Company.

CATALOGUED
MAR 6 1903
E. H. B.

TRANSACTIONS

OF THE

AMERICAN

OPHTHALMOLOGICAL SOCIETY.

Thirty-sixth Annual Meeting.

WASHINGTON, D. C., 1900.

HARTFORD:
PUBLISHED BY THE SOCIETY.
1900.

Press of The Case, Lockwood & Brainard Company.

TABLE OF CONTENTS.

	PAGE.
Members of the society,	5
Minutes of the thirty-sixth annual meeting,	9
Operation for atrophic entropion, especially of the lower lid. Dr. A. E. Ewing,	15
Operative treatment of entropion by the transplantation of a flap of mucous membrane. Dr. J. E. Weeks,	18
Three cases of vascular tumor of the orbit — operation on two of these cases with successful result — apparent spontaneous cure of the third case. Dr. C. S. Bull,	27
Case of removal of a retro-bulbar lymphosarcoma with preservation of normal vision. Dr. C. A. Oliver,	36
Distension of nasal accessory sinuses involving the orbit. Dr. G. C. Harlan,	44
Lesions of the frontal sinus and anterior ethmoidal cells in infancy and old age. Dr. R. Sattler,	50
Report of post-mortem examination, with specimens of a case of leontiasis ossea in which ocular symptoms were present. Dr. R. Sattler,	59
Frontal headaches apparently ocular, but really of nasal origin — their recognition and treatment. Dr. A. E. Ewing,	60
On the nasal conditions found in these cases, with special reference to an abnormal relation of the uncinate process of the ethmoid to the bulla of the ethmoid. Dr. G. Sluder,	60
Displacements of the eyeball by disease of the frontal and ethmoid sinuses. Dr. S. D. Risley,	72
Case of primary (traumatic) non-infective thrombosis of the cavernous sinus — operation by Dr. F. Hartley — remarks. Dr. H. Knapp,	77
Optic atrophy from blows on the forehead and temple. Dr. J. A. Spalding,	83
Concerning relative accommodation and convergence, with the description of an instrument for their measurement. Dr. L. Howe,	92
Surgical treatment of a case of high myopia. Dr. C. W. Kollock,	100
Excision of the lachrymal sac and gland, followed by an unusual variety of neuro-paralytic keratitis, markedly resembling clinically the so-called lattice-like keratitis. Dr. C. A. Veasey,	101
Opacity of the posterior capsule of the lens, due to the remains of the membrana vasculosa lentis. Dr. A. G. Thomson,	108
Two unusual cases of choroidal disease. Dr. W. H. Wilder,	111
Case of acute double retro-bulbar optic neuritis hereditary in origin. Dr. H. F. Hansell,	114
Homonymous similar sector defects in the visual fields, with probably a central cause. Dr. S. M. Burnett,	118

PAGE.

Case of alexia, mind-blindness, etc., with autopsy. Dr. E. E. Jack, . 122
On the treatment of dendritic keratitis and of marginal ulcer of the cornea with tincture of iodine. Dr. H. Friedenwald, . . . 129
Sarcoma of the eyelid, with report of a case. Dr. H. Friedenwald, . 133
Observations on some blind but quiet and apparently inoffensive eyes. Do they produce a pseudo-sympathetic inflammation? Dr. S. C. Ayres, ... 137
The corneal section for cataract and the cataract-knife. Dr. E. Jackson, ... 145
Exfoliation of the anterior layer of the iris with partial opacity of the lens. Dr. E. Jackson, ... 149
On the advantages of strong, portable, or easily movable magnets in eye surgery. Dr. J. A. Lippincott, ... 152
Case of transient, spastic, convergent strabismus. Dr. S. Theobald, 167
Clinical study of the ocular symptoms found in so-called posterior spinal sclerosis. Dr. C. A. Oliver, ... 173
Spasm of accommodation in glaucoma relieved by eserine. Dr. J. A. Lippincott, ... 178
The histology of the lachrymal gland in chronic dacryo-cystitis. Dr. G. E. de Schweinitz, ... 182
Papilloma of the plica semi-lunaris. Dr. G. E. de Schweinitz, . . 187
A lantern for detecting color-blindness in railroad employees. Dr. Wm. Thomson, ... 189
An improved lantern for testing color-perception. Dr. C. H. Williams, 192
An improved perimeter. Dr. F. D. Skeel, ... 196
Edward L. Holmes, M.D., LL.D. (obituary notice), ... 199

6887

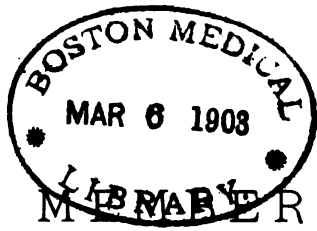

MEMBERS

OF THE

American Ophthalmological Society.

1900-1901.

ACTIVE MEMBERS.

The (*) indicates *Associate* Members.

NAME.	RESIDENCE.	PLACE.
Dr. F. W. ABBOT,	523 Franklin Street,	Buffalo, N. Y.
Dr. A. E. ADAMS,	44 Grand Street,	Newburg, N. Y.
Dr. WM. F. AIKEN,	228 Oglethorpe Ave. E.	Savannah, Ga.
Dr. L. A. W. ALLEMAN,	64 Montague Street,	Brooklyn, N. Y.
*Dr. A. ALLING,	199 York Street,	New Haven, Conn.
*Dr. G. W. ALLYN,	515 Penn Avenue,	Pittsburg, Pa.
Dr. A. ALT,	3036 Locust Street,	St. Louis, Mo.
§Dr. J. A. ANDREWS,	107 Madison Avenue,	New York, N. Y.
Dr. S. C. AYRES,	14th East 7th Street,	Cincinnati, Ohio.
Dr. WM. T. BACON,	11 Pratt Street,	Hartford, Conn.
Dr. H. W. BRADFORD,		Jamaica Plain, Mass.
Dr. CHARLES S. BULL,	47 West 36th Street,	New York, N. Y.
Dr. F. BULLER,	123 Stanley Street,	Montreal, Canada.
Dr. SWAN M. BURNETT,	916 Farragut Sq. (17th St.),	Washington, D. C.
Dr. PETER A. CALLAN,	35 West 38th Street,	New York, N. Y.
Dr. F. P. CAPRON,	118 Angell Street,	Providence, R. I.
Dr. W. H. CARMALT,	87 Elm Street,	New Haven, Conn.
*Dr. JOHN T. CARPENTER, JR.,	1419 Walnut Street,	Philadelphia, Pa.
Dr. H. B. CHANDLER,	34½ Beacon Street,	Boston, Mass.
Dr. WM. CHEATHAM,	303 West Chestnut Street,	Louisville, Ky.
Dr. F. E. CHENEY,	Hotel Bristol,	Boston, Mass.
*Dr. J. H. CLAIBORNE,	39 West 36th Street,	New York City.
Dr. C. F. CLARK,	188 East State Street,	Columbus, Ohio.
*Dr. ANTON COE,	1110 F. St.,	Washington, D. C.
Dr. DAVID COGGIN,	7 Chestnut Street,	Salem, Mass.
*Dr. WM. E. COWEN,	35 E. 60th Street,	New York, N. Y.
Dr. C. M. CULVER,	36 Eagle Street,	Albany, N. Y.
Dr. W. S. DENNETT,	8 East 49th Street,	New York, N. Y.
Dr. HASKET DERBY,	182 Marlboro Street,	Boston, Mass.
Dr. RICHARD H. DERBY,	9 West 35th Street,	New York, N. Y.
Dr. LEWIS S. DIXON,	232 Clarendon Street,	Boston, Mass.

§ Temporarily residing at Santa Barbara, Cal.

NAME.	RESIDENCE.	PLACE.
Dr. J. B. EMERSON,	20 East 30th Street,	New York, N. Y.
Dr. ARTHUR E. EWING,	2670 Washington Avenue,	St. Louis, Mo.
Dr. T. H. FENTON,	1319 Spruce Street,	Philadelphia, Pa.
Dr. GEORGE F. FISKE,	100 State Street,	Chicago, Ill.
Dr. EDW. FRIDENBERG,	242 Lenox Avenue,	New York, N. Y.
Dr. H. FRIEDENWALD,	1029 Madison Ave.,	Baltimore, Md.
Dr. B. F. FRYER,	Cor. 9th and Cherry Streets,	Kansas City, Mo.
*Dr. G. M. GOULD,	119 South 17th Street,	Philadelphia, Pa.
*Dr. H. Y. GRANT,	414 Delaware Avenue,	Buffalo, N. Y.
Dr. JOHN GREEN,	2670 Washington Avenue,	St. Louis, Mo.
Dr. EMIL GRUENING,	109 East 23d Street,	New York, N. Y.
Dr. G. W. HALE,	Wilcox Building,	Nashville, Tenn.
*Dr. WM. D. HALL,	387 Boylston Street,	Boston, Mass.
Dr. H. F. HANSELL,	254 South 16th Street,	Philadelphia, Pa.
Dr. GEORGE C. HARLAN,	1515 Walnut Street,	Philadelphia, Pa.
Dr. DAVID HARROWER,	9 Elm Street,	Worcester, Mass.
Dr. GUSTAVUS HAY,	383 Marlborough Street,	Boston, Mass.
Dr. NEIL J. HEPBURN,	369 West 23d Street,	New York, N. Y.
*Dr. WARD HOLDEN,	60 West 39th Street,	New York, N. Y.
Dr. E. E. HOLT,	723 Congress Street,	Portland, Me.
Dr. LUCIEN HOWE,	87 West Huron Street,	Buffalo, N. Y.
Dr. A. A. HUBBELL,	212 Franklin Street,	Buffalo, N. Y.
Dr. D. W. HUNTER,	233 Madison Avenue,	New York, N. Y.
*Dr. J. W. INGALLS,	848 Lafayette Avenue,	Brooklyn, N. Y.
*Dr. E. E. JACK,	215 Beacon Street,	Boston, Mass.
Dr. EDWARD JACKSON,	McPhee Building,	Denver, Col.
Dr. B. JOY JEFFRIES,	15 Chestnut St., Beacon Hill,	Boston, Mass.
Dr. W. B. JOHNSON,	170 Broadway,	Paterson, N. J.
Dr. CHARLES J. KIPP,	534 Broad Street,	Newark, N. J.
Dr. H. KNAPP,	26 West 40th Street,	New York, N. Y.
Dr. CARL KOLLER,	715 Madison Avenue,	New York, N. Y.
Dr. CHAS. W. KOLLOCK,	Cor. Wentworth & Com'g Sts.,	Charleston, S. C.
Dr. W. E. LAMBERT,	8 West 35th Street,	New York, N. Y.
*Dr. F. N. LEWIS,	35 W. 36th Street,	New York City.
Dr. J. A. LIPPINCOTT,,	435 Penn Avenue,	Pittsburg, Pa.
Dr. F. B. LORING,	1420 K. Street,	Washington, D. C.
*Dr. D. B. LOVELL,	32 Pearl Street,	Worcester, Mass.
Dr. F. W. MARLOW,	731 University Block,	Syracuse, N. Y.
Dr. W. V. MARMION,	1110 8th Street, N. W.,	Washington, D. C.
*Dr. W. B. MARPLE,	20 W. 31st Street,	New York, N. Y.
Dr. ARTHUR MATHEWSON,	139 Montague Street,	Brooklyn, N. Y.
Dr. CHAS. H. MCILWAINE,	264 Willis Avenue,	New York, N. Y.
Dr. R. J. MCKAY,	Cor. 9th and Market Streets,	Wilmington, Del.
Dr. C. S. MERRILL,	23 Washington Avenue,	Albany, N. Y.
Dr. B. L. MILLIKIN,	278 Prospect Street,	Cleveland, Ohio.
Dr. HORACE GEO. MILLER,	262 Benefit Street,	Providence, R. I.
Dr. J. LANCELOT MINOR,	14 Randolph Building,	Memphis, Tenn.

NAME.	RESIDENCE.	PLACE.
Dr. W. F. MITTENDORF,	140 Madison Avenue,	New York, N. Y.
Dr. WM. O. MOORE,	42 East 29th Street,	NewYork, N. Y.
Dr. RUSSELL MURDOCH,	418 Cathedral Street,	Baltimore, Md.
Dr. WM. F. NORRIS,	1530 Locust Street,	Philadelphia, Pa.
Dr. HENRY D. NOYES,	233 Madison Avenue,	New York, N. Y.
Dr. CHARLES A. OLIVER,	1507 Locust Street,	Philadelphia, Pa.
Dr. H. S. OPPENHEIMER,	16 E. 32d Street,	New York, N. Y.
Dr. R. J. PHILLIPS,	123 So. 39th Street,	Philadelphia, Pa.
Dr. THOMAS R. POOLEY,	107 Madison Avenue,	New York, N. Y.
*Dr. WILLIAM C. POSEY,	1831 Chestnut Street,	Philadelphia, Pa.
Dr. M. H. POST,	Beaum't St., cor. Wash. Av.,	St. Louis, Mo.
Dr. H. R. PRICE,	485 Franklin Avenue,	Brooklyn, N. Y.
Dr. J. S. PROUT,	26 Schermerhorn Street,	Brooklyn, N, Y.
Dr. B. ALEX'R RANDALL,	1604 Walnut Street,	Philadelphia, Pa.
Dr. R. L. RANDOLPH,	816 Park Avenue,	Baltimore, Md.
Dr. WILLIAM RANKIN,	23 Cedar Street,	Newark, N. J.
Dr. J. M. RAY,	423 West Chestnut Street,	Louisville, Ky.
Dr. R. A. REEVE,	22 Shuter Street,	Toronto, Canada.
*Dr. H. O. REIK,	5 W. Preston Street,	Baltimore, Md.
Dr. STEPHEN O. RICHEY,	732 17th Street,	Washington, D. C.
Dr. CHARLES E. RIDER,	53 South Fitzhugh Street,	Rochester, N. Y.
Dr. WHEELOCK RIDER,	53 South Fitzhugh Street,	Rochester, N. Y.
Dr. H. W. RING,	46 Elm Street,	New Haven, Conn.
Dr. SAMUEL D. RISLEY,	1722 Walnut Street,	Philadelphia, Pa.
Dr. EDMUND C. RIVERS,	16th and Stout Streets,	Denver City, Col.
*Dr. WM. K. ROGERS,	118 East State Street,	Columbus, Ohio.
Dr. D. B. ST. JOHN ROOSA,	20 East 30th Street.	New York, N. Y.
*Dr. DUNBAR ROY,	Grand Opera House Block,	Atlanta, Ga.
Dr. JOHN D RUSHMORE,	129 Montague Street,	Brooklyn, N. Y.
Dr. ROBERT SATTLER,	7th and Race Streets,	Cincinnati, Ohio.
*Dr. T. B. SCHNEIDEMAN,	112 South 18th Street,	Philadelphia, Pa.
Dr. G. E. DESCHWEINITZ,	1401 Locust Street,	Philadelphia, Pa.
Dr. P. N. K. SCHWENK,	810 North 7th Street,	Philadelphia, Pa.
Dr. W. W. SEELEY,	4th Street and Broadway,	Cincinnati, Ohio.
Dr. HENRY L. SHAW,	19 Commonwealth Avenue,	Boston, Mass.
*Dr. F. D. SKEEL,	58 E. 25th Street,	New York N. Y.
Dr. J. A. SPALDING,	627 Congress Street,	Portland, Me.
Dr. FRANCIS P. SPRAGUE,	229 Commonwealth Avenue,	Boston, Mass.
Dr. MYLES STANDISH,	6 St. James Avenue,	Boston, Mass.
Dr. GEORGE T. STEVENS,	33 West 33d Street,	New York, N. Y.
Dr. SAMUEL B. ST. JOHN,	68 Pratt St.,	Hartford, Conn.
Dr. GEO. STRAWBRIDGE,	202 So. 15th Street,	Philadelphia, Pa.
Dr. T. Y. SUTPHEN,	999 Broad Street,	Newark, N. J.
*Dr. WM. M. SWEET,	1131 Spruce Street,	Philadelphia, Pa.
Dr. J. OSCROFT TANSLEY,	28 West 43d Street,	New York, N. Y.
Dr. LEWIS H. TAYLOR,	41 South Franklin Street,	Wilkes Barre, Pa.
Dr. SAMUEL THEOBALD,	304 West Monument Street,	Baltimore, Md.

NAME.	RESIDENCE.	PLACE.
Dr. CH. HERMON THOMAS,	1907 Chestnut Street,	Philadelphia, Pa.
*Dr. A. G. THOMSON,	1426 Walnut Street,	Philadelphia, Pa.
Dr. WILLIAM THOMSON,	1426 Walnut Street,	Philadelphia, Pa.
*Dr. JAS. THORINGTON,	120 South 18th Street,	Philadelphia, Pa.
Dr. JOHN VAN DUYN,	111 South Salina Street,	Syracuse, N. Y.
*Dr. C. A. VEASEY,	116 South 19th Street,	Philadelphia, Pa.
Dr. O. F. WADSWORTH,	526 Beacon Street,	Boston, Mass.
Dr. LEROY P. WALKER,	25 East 24th Street,	New York, N. Y.
Dr. DAVID WEBSTER,	327 Madison Avenue,	New York, N. Y.
Dr. J. E. WEEKS,	154 Madison Avenue,	New York, N. Y.
*Dr. CASSIUS D. WESTCOTT,	31 Washington Street,	Chicago, Ill.
Dr. J. A. WHITE,	200 E. Franklin Street,	Richmond, Va.
Dr. W. H. WILDER,	103 State Street,	Chicago, Ill.
Dr. CHAS. H. WILLIAMS,	15 Arlington Street,	Boston, Mass.
Dr. WM. H. WILMER,	1610 I Street, N. W.,	Washington, D. C.
Dr. F. M. WILSON,	288 Myrtle Avenue,	Bridgeport, Conn.
*Dr. WILLIAM L. WOOD,	412 Oregonian Building,	Portland, Oregon.
*Dr. HIRAM WOODS,	842 Park Ave.,	Baltimore, Md.
Dr. J. P. WORRELL,	20 South 7th Street,	Terre Haute, Ind.
Total, ...		144

HONORARY MEMBER.

Dr. C. SCHWEIGGER, ...		Berlin, Prussia.
Whole number, ...		145

MINUTES OF THE PROCEEDINGS.

THIRTY-SIXTH ANNUAL MEETING.

ARLINGTON HOUSE,
WASHINGTON, D. C., May 2, 1900.

The Thirty-sixth Annual Meeting of the Society was called to order by the President, Dr. O. F. WADSWORTH, at 10 A. M. The President announced the following committees:

Committee on Bulletin — Drs. C. A. OLIVER and H. F. HANSELL.

Committee on Membership — Drs. JOHN GREEN, S. THEOBALD, W. H. CARMALT, C. S. BULL, and A. MATHEWSON.

Auditing Committee — Dr. H. S. OPPENHEIMER.

The Committee on Bulletin reported and the following papers were read:

1. "An operation for atrophic entropion, especially of the lower lid," Dr. Ewing.

(Drs. Mary P. Eddy and D. W. Torrance of Syria were invited to attend the session as guests of the Society.)

2. "Operative treatment of entropion by the transplantation of a flap of mucous membrane," Dr. Weeks.

Discussed by Drs. Knapp, Theobald, Lippincott, Wilder, Green, Torrance, and Weeks.

3. "Optic atrophy from blows on forehead and temple," Dr. Spalding.

4. "Three cases of vascular tumor of the orbit, successfully treated by operation," Dr. Bull.

5. "A case of orbital lympho-sarcoma with preservation of normal vision," Dr. Oliver.

6. " Distension of the nasal and accessory cavities involving the orbit," Dr. Harlan.

7. " Uncommon expressions of frontal sinus lesions," Dr. Sattler.

8. " Report of post mortem examination (with specimens) of a case of Leontiasis Ossea in which ocular symptoms were present," Dr. Sattler.

9. " Case of primary (traumatic) non-infective thrombosis of the Cavernous sinus — operation by Dr. F. Hartley," Dr. Knapp.

Operation described by Dr. Hartley.

10. " Frontal headaches, apparently ocular, of nasal origin," Dr. Ewing.

(Dr. Sluder of St. Louis was invited to address the Society on the subject of the nasal condition in these cases.)

11. " Displacement of the eyeball due to disease of the ethmoidal or frontal sinuses," Dr. Risley (by title).

(Papers 3–11 were discussed by Drs. Gruening, Lippincott, Harlan, Risley, Knapp, and Randall.)

Adjourned for Executive Session.

[Executive Session, Wednesday, May 2d, 1900.]

Report of the Treasurer was read and accepted. No assessment was called for.

The President called up the amendment to the Constitution presented by Dr. Prout, and Dr. John Green moved that, in the absence of its author, the amendment should be carried over until the next annual meeting. Motion was adopted.

The Committee on Membership then presented favorable reports upon the following candidates: Drs. C. D. Westcott, Chicago; Wm. M. Sweet, Philadelphia; W. K. Rogers, Columbus; Hiram Woods, Baltimore.

Secretary read several names placed in nomination as candidates for membership.

The ballot on names presented by the committee being concluded, the President announced that the vote cast was too small to constitute an election. Dr. Green thereupon moved that these

four names be referred back to the committee to lay over another year. (No action taken.)

Dr. Taylor moved to reconsider the vote upon Dr. Green's motion to postpone consideration of Dr. Prout's amendment. Dr. Gruening seconded this motion and it was unanimously carried.

The Secretary then read the amendment again, and, upon motion of Dr. Harlan, seconded by Dr. Risley, the amendment was adopted.

Session then adjourned.

May 3. Meeting called to order at 9.30 and reading of papers was resumed.

12. "Improved method of measuring relative convergence and accommodation," Dr. Howe.

13. "Notes on the surgical treatment of high Myopia," Dr. Kollock.

14. "Excision of the lachrymal sac and gland followed by an unusual variety of neuro-paralytic Keratitis," Dr. Veasey.

15. "Case of desquamation of the Iris," Dr. Jackson.

16. "An opacity of the posterior capsule of the lens due to the remains of the membrana vasculosa lentis," Dr. A. G. Thomson (by title).

17. "The corneal section for cataract extraction and the cataract knife," Dr. Jackson.

18. "The advantages of strong, portable, or easily portable magnets in eye surgery," Dr. Lippincott.

Discussed by Drs. Johnson, Jackson, Lippincott, and Millikin.

19. "Observations on the influence of some blind but quiet and apparently inoffensive eyes. Do they produce a pseudo-sympathetic inflammation?" Dr. Ayres.

20. "Case of transient spastic convergent Strabismus," Dr. Theobald.

Discussed by Drs. Howe, Harlan, Allyn, Jackson, Thomas, and Theobald.

21. "Spasm of accommodation in Glaucoma relieved by Eserine," Dr. Lippincott (by title).

22. "Two unusual cases of choroidal disease," Dr. Wilder.

23. "The effects of flashes of electric light upon the eyes," Dr. Roy.

24. "Study of the ocular symptoms found in so-called 'Posterior spinal Sclerosis,'" Dr. Oliver (by title).

25. "Case of double acute retro-bulbar optic neuritis hereditary in origin," Dr. Hansell.

26. "Homonymous symmetrical sector-defect in the visual fields," Dr. Burnett.

Discussed by Dr. Allyn.

27. "The material composition of printed matter," Dr. Culver (by title).

28. "Lantern for the detection of color-blindness," Dr. Wm. Thomson.

29. "New lantern for testing color-perception," Dr. Williams.

Discussed by Drs. Thomson and Williams.

30. "Case of Alexia, mind-blindness, etc., with autopsy," Dr. Jack.

31. "Treatment of Dendritic Keratitis and of marginal concentric ulcers of the cornea with Tinct. of Iodine," Dr. Friedenwald.

32. "Sarcoma of eyelid with microscopic examination," Dr. Friedenwald (by title).

The Histology of the lachrymal gland in chronic dacryocystitis, Dr. G. E. de Schweinitz (by title).

Papilloma of the plica-semilunaris, Dr. G. E. de Schweinitz (by title).

33. "An improved Perimeter," by Dr. F. D. Skeel (by title).

Society then went into Executive Session.

[Executive Session, Thursday, May 3d.]

The Executive Committee reported the choice of the follow-

ing officers and, upon motion of Dr. Harlan, the report was accepted and Secretary instructed to cast the ballot:

President — Dr. O. F. WADSWORTH.

Vice-President — Dr. C. S. BULL.

Corresponding Secretary — Dr. J. S. PROUT.

Recording Secretary — Dr. S. B. ST. JOHN.

Publishing Committee — Drs. W. S. DENNETT and R. H. DERBY.

Place of Meeting for next year, New London.

The committee called attention to a communication from the American Committee on International Medical Congress — composed of the presidents of the societies in this Congress — and recommended the appropriation of $25 towards defraying the expenses of this committee. Upon motion of Dr. Oliver the recommendation was adopted.

The committee also announced that in view of the amendment to the Constitution adopted yesterday, they would declare the election of Drs. Westcott, Sweet, Rogers, and H. Woods as associate members unless ballot was called for.

There was no such call.

They further asked that the names of seven other candidates which had been referred to them, be referred to the Committee on Membership for 1901 for consideration.

The report in full was adopted.

Upon motion of Dr. Jackson a committee of three was appointed to collect, so far as possible, and arrange systematic supplementary reports of cases that have been reported in the transactions of this Society.

The President subsequently appointed Drs. Edw. Jackson, Geo. E. de Schweinitz, and C. H. Williams.

S. B. ST. JOHN,
Recording Secretary.

Members present at the Thirty-sixth Meeting:

Dr. ST. JOHN,	Dr. CULVER,
Dr. THOMAS,	Dr. DE SCHWEINITZ,

Dr. SPALDING,
Dr. VAN DUYN,
Dr. WEEKS,
Dr. CARMALT,
Dr. OPPENHEIMER,
Dr. RUSHMORE,
Dr. MARLOW,
Dr. GOULD,
Dr. BURNETT,
Dr. KOLLOCK,
Dr. TAYLOR,
Dr. SKEEL,
Dr. VEASEY,
Dr. HANSELL,
Dr. LOVELL,
Dr. GRANT,
Dr. MILLIKIN,
Dr. ALLING,
Dr. RISLEY,
Dr. LORING,
Dr. ALLYN,
Dr. GREEN,
Dr. WADSWORTH,
Dr. REIK,
Dr. OLIVER,
Dr. RICHEY,
Dr. GRUENING,
Dr. FENTON,
Dr. W. THOMSON,
Dr. JOHNSON,
Dr. AYRES,
Dr. COE,
Dr. MERRILL,
Dr. HARLAN,
Dr. PHILLIPS,
Dr. MATTHEWSON,
Dr. REEVE,
Dr. BULL,
Dr. RANKIN,
Dr. JACKSON,
Dr. KNAPP,
Dr. WHITE,
Dr. WEBSTER,
Dr. EWING,
Dr. WILSON,
Dr. WILMER,
Dr. ROY,
Dr. FRIEDENWALD,
Dr. STRAWBRIDGE,
Dr. FRIEDENBERG,
Dr. ADAMS,
Dr. HARVEY,
Dr. LIPPINCOTT,
Dr. MILLER,
Dr. THEOBALD,
Dr. A. G. THOMSON,
Dr. CARPENTER,
Dr. SATTLER,
Dr. AIKEN,
Dr. HOWE,
Dr. JACK,
Dr. CLAIBORNE,
Dr. MARMION,
Dr. POSEY,
Dr. WILDER,
Dr. THORINGTON,
Dr. RANDOLPH,
Dr. WILLIAMS,
Dr. RANDALL.

AN OPERATION FOR ATROPHIC ENTROPION, ESPECIALLY OF THE LOWER LID.

BY ARTHUR E. EWING, M.D.,

ST. LOUIS, MO.

When the lower eyelid has been distorted by disease, as from trachoma or other cause, so that the cilia turn against and rub upon the globe, it has been my experience that operations for the correction of the defect are frequently unsuccessful. With most of the methods in common use, the removal of a strip of skin or of muscle, or both, is the rule, although the atrophied lids can ill afford to lose any of their already shrunken tissue. To such lids Dr. Green's operation is the kindest of all, because collodion (contractile) is used as a splint for keeping the lips of the tarsal incision apart until healing can be effected, so that no tissue is sacrificed; in fact, after the healing there is an actual gain in the height of the tarsal surface. The operation has the further valuable feature that it may be repeated upon the same lid as often as may be necessary, without any evil results. It also truly everts the margin of the lid, and with time the cilia tend more and more to take their proper direction. That this should be so is easily understood when we consider that the incision is made through the tarsus along a line very near the bases of the papillæ of the cilia. With the consolidation of the cicatrix these bases are drawn to it, and thus the lashes are gradually tilted into a more normal position.

One of the subjects of the operation to be described had suffered with trachoma for nine years, and besides this had been from time to time presented by electrolysis. When she presented herself the entropion was complete throughout the full length of both the upper and lower lids, and the conjunctival sacs were greatly shrunken. A canthoplasty upon each eye improved

the condition somewhat, and the operation by Dr. Green's method upon the upper lids resulted with them as favorably as could be desired. The same operation was tried twice thoroughly upon the right lower lid, and once upon the left, each time with improvement in the position of the lid margins, but still leaving the cilia along the central portion of each lid turning in. During the long course of inflammation from which the patient had suffered, the atrophy had become so great that the lids of each eye at best barely came together when normally closed. For this reason it was imperative to obtain a result by the tarsal incision, or by some means that would lengthen the tarsal portion of the lid instead of shortening it. This seems to have been accomplished in the following manner:

Beginning on the inner surface of the lid as near the openings of the Meibomian glands as is possible, the conjunctiva, along the full length of the lid, from the outer canthus as far as to the punctum, was dissected back three to four millimeters (Figs. 1 and 2). Then, about two and a half to three millimeters from the lid margin, an incision was made entirely through the tarsus (as in Dr. Green's method) also the full length of the lid (Figs. 1 and 3). The portion of the tarsus containing the cilia was then turned forward, and into its posterior edge next the orbicularis muscle a suture was introduced about the centre of the lid, and brought out about the centre of the incised surface of the cartilage. The same needle was then again entered upon the skin surface in the line of the cilia, and carried vertically downward and brought out through the skin about six millimeters below the point of entrance (Fig. 4). A similar suture was placed in the inner half of the lid, and another in the outer half. A firm roll of moist aseptic gauze, or absorbent cotton, about three millimeters in diameter, was then placed along the lid just below the cilia, and over this the sutures were tied, making a sort of flexible quill suture (Fig. 5). It is not necessary or advisable to tie these sutures very tightly, for fear of impairing the circulation in the central portion of the lid. Their purpose is to evert the margin of the divided tarsus and bring the raw surface into the position formerly

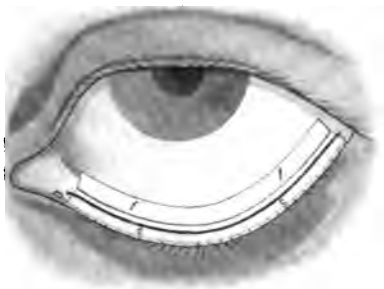

FIG. I.

FIG. II.

FIG. III.

FIG. IV.

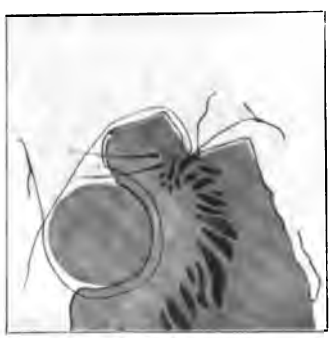

FIG. V.

Fig. I.— Conjunctival flap (f), and the tarsal incision (c). Fig. II.— Cross-section showing the dissected conjunctival flap; Fig. III. the tarsal incision; Fig. IV. the mode of suturing; Fig. V. the application of the gauze or cotton roll.

occupied by the inverted mouths of the Meibomian glands. It is also not necessary to enter these sutures at the cilia and carry them through the skin. They may be carried over the roll and tacked into the skin below it. The only reason for entering them at the cilia is that the track through the skin will form a slight scar which may assist in maintaining the eversion. After the eversion was accomplished, the conjunctival flap was brought forward by numerous fine sutures and stitched deeply into the angle made by the turning forward of the everted portion of the tarsus (Fig. 5). This covers, with an epithelial surface, both the raw edge of the divided tarsus and the exposed fibres of the orbicularis. The conjunctival sac was then irrigated with corrosive sublimate, 1/5000 solution, and the eye bandaged.

The following day the eye was again cleansed in the same manner. The third day the roll of gauze was removed and the threads drawn out from their tracks under the skin, but not from their tarsal attachment. They were still utilized to maintain the eversion by pasting them, in company with such cilia as were available for the purpose, to the skin surface with contractile collodion. The conjunctival sutures, being very superficial, generally come away of themselves after five or six days, or they may be removed as may seem best.

The greatest difficulty in the operation is to dissect the conjunctival flap evenly and smoothly. For this purpose I use a thin, double-edged, round-ended spatula-shaped knife, the cutting edge extending around the end. The same knife may also be used for the tarsal incision. The bellied half-round knife used by Dr. Green for the tarsal incision is also excellent for this dissection. In this, as in Dr. Green's operation, it is of the greatest importance that the tarsus be thoroughly divided. When this is accomplished it is known by the dark muscle showing in the incision, by the ecchymosis on the skin surface, and by the ease with which the two parts of the divided tarsus may be raised up from the muscle tissue. The incision should be kept at least two and a half millimeters from the lid margin, as the papillæ of the cilia extend thus far into the tarsus. Should any of these papillæ

be left on the posterior portion, cilia would be very likely to sprout up through the incision. The formation of granulomata is not so common as when the tarsal incision is left uncovered by mucous membrane. When they appear in the line of the divided tarsus, they may be removed by curette, knife, or scissors. Puckering of the lid margin may follow, as in the simple tarsal incision; this may be remedied later by making one or more deep vertical incisions, as practiced by Dr. Green, or it may be left to take care of itself. I have usually found that in time it straightens out of its own accord with advantage to the desired eversion. The method differs from that of Dr. Green only in the applying of the quill suture, and in covering a portion of the incision with mucous membrane. A combination of a form of quill suture with the tarsal incision has, I am told, been used by Professor Voelckers in the University at Kiel for a number of years.

OPERATIVE TREATMENT OF ENTROPION BY THE TRANSPLANTATION OF A FLAP OF MUCOUS MEMBRANE.

By JOHN E. WEEKS, M.D.,

New York City.

Shrinkage of the palpebral conjunctiva from whatever cause may produce entropion, but by far the most common cause is trachoma. The long-continued congestion of the tarsus occasions some hypertrophy of that body. The traction of the shrinking tarsal conjunctiva lessens the vertical dimension of the tarsus, causing it to become more concave on its posterior surface and more convex on its anterior surface. The same condition is found in the lower as in the upper tarsus, but the former is so much narrower and thinner that the deformity is much less.

The photophobia occasioned by the superficial keratitis which usually accompanies trachoma in the second stage causes more or less tonic spasm of the orbicularis palpebrarum muscle, which results in forcing more than the normal number of muscle fibers to the margins of the lids, aiding in a thickening of the margins of the lids and in crowding the lashes against the cornea. In all cases of marked contraction of the palpebral conjunctiva the palpebral fissure is shortened, from the external commissure. In not a few cases of entropion the intermarginal space is narrowed; also the ducts of the Meibomian glands are so curved that their orifices are constantly in contact with the eyeball.

The writer has operated in many ways for the correction of entropion. He has found that the Anagnostakis-Hotz operation produces permanent, satisfactory results in only the mildest cases of entropion. The Jaesche-Arlt operation is inelegant. The Green and Burow operations are too often followed by relapse, and the Streatfield-Snellen operation is sometimes insufficient when used alone.

A study of the conditions present in entropion has impressed the writer with the necessity for the reconstruction of the margin of the lid in many cases, and he now employs a modification of the Streatfield-Snellen operation combined with the Van Millingen operation.

If the palpebral fissure is much shortened, a canthoplasty is first performed.

In all pronounced cases of entropion, either of the upper or lower lid, the margin of the lid is reconstructed by the Van Millingen method. When the lower lid is the seat of the entropion, reconstruction of the margin of the lid alone is sufficient.

In operating on the upper lid (after having performed canthoplasty if that is necessary), the lid is split along the intermarginal space, the incision extending to a depth of 2.5 mm., and so made that all of the lashes are in the anterior flap and the tarsus in the posterior flap; the groove thus formed is wedge-shaped and measures about 2.5 mm. in width at its base. This groove is made in the early part of the operation, so that the bleeding will

have ceased when the other parts of the operation are complete. The lid is then fixed with a Knapp clamp and an incision made through the integument 3 mm. from the margin of the lid and parallel to it, extending the whole length of the tarsus. If the integument is redundant, a narrow strip is dissected from the upper flap. A strip of subcutaneous tissue is now dissected out, exposing the upper two-thirds of the tarsus. The tissue immediately beneath the lower flap is left *in situ*. By means of a scalpel, or Beer's knife, a wedge-shaped strip of the tarsus is removed, the groove formed running parallel to the lid margin, its apex almost reaching the tarsal conjunctiva; the strip is taken from the thickest part of the tarsus. Four sutures are applied, each passing

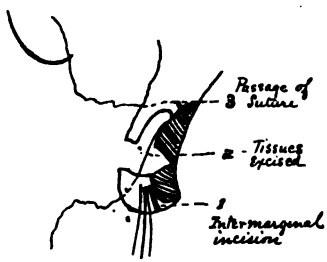

through the integument of the lower flap 1.5 mm. from its edge, then through the epitarsal tissue at the upper margin of the tarsus, emerging on the surface 8 mm. above the margin of the upper flap.

These sutures are of No. 3 silk and are tied firmly. The groove in the edge of the lid is now freed from clots, making it ready for the reception of the flap.

One-half of the lower lip is now engaged between the blade of a Knapp clamp, the plate lying against the integument, and pressure applied. The clamp acts as a hemostat, and also puts the mucous membrane on the stretch. A strip of mucous membrane 2 to 2.5 mm. in width and as long as the groove in the intermarginal portion of the lid is now removed by means of a

Graefe knife. If this knife is made to cut along the entire length of its edge, two strokes will be sufficient to excise a wedge-shaped strip of the lid of sufficient length. Scissors and forceps may be required for the final separation of the flap. The flap is immediately transferred to the groove in the lid and pressed into place. The plastic lymph is sufficient to retain the flap. No sutures are required.

The operated lid and the opposing margin of the lower lid are covered with bichloride vaseline 1/5000, moist gauze, cotton, and a bandage. The dressing is not disturbed until forty-eight to seventy-two hours have elapsed. At the expiration of seventy-two hours the flap is quite firmly adherent and the bandage may be dispensed with. As a rule the bandage is replaced and permanently removed on the fourth or fifth day. The margin of the lid is smeared with borated or sublimated vaseline for a few days longer. The stitches employed in the modified Streatfield-Snellen operation are removed on the seventh to ninth day. The wound in the lip is closed by a continuous silk suture and heals by first intention; the stitch is removed on the fifth day.

In all operations in which the transplantation of a flap of skin or mucous membrane is involved, the question of shrinkage must be considered. My experience in some twenty cases in which I have employed the method described is that flaps transplanted from the lip shrink less than flaps of integument. Some of the cases have been under observation for a number of years; in none has there been a relapse of the entropion.

In cases where the union between lid and flap is rapid, the flap of mucous membrane does not lose its epithelial layer, as is almost always the case when integument is employed; its surface remains smooth and is restored to a normal condition sooner than that of integument. There is no irritation to the cornea from the exfoliation of corneous epithelium, and no trouble from the growth of fine hairs. The Tiersch graft does not possess sufficient substance to give perfectly satisfactory results in reconstructing the margin of the lid.

DISCUSSION.

Dr. H. KNAPP. I want to say that I have long practiced exactly the same method and described it six or seven years ago with skin flaps, and also every now and then with mucous membrane, and I can endorse all that Dr. Weeks says, except that I have not found any great advantage in mucous membrane over skin flaps. If we take the skin flap from the upper border of the lid wound, or from behind the ear, we secure a good membrane free from hair. The operation of implanting a flap of skin belongs to the late Dr. Waldhauer, who published it about twenty or thirty years ago.

Of all the methods that I have used I have found this the most satisfactory in the generality of cases, but I must say, however, that of late I have seen some very excellent results attained by a pupil of Panas' with the latter's operation.

Dr. THEOBALD. I should like to say just a word on this subject in regard to senile entropion of the lower lid. Perhaps some of the members may remember that several years ago I read a paper on the use of caustic potash in the treatment of this form of entropion. It is a very simple operation, and can be repeated a second time if necessary. The results have been very satisfactory, and because the operation is so simple and so readily performed I am led to speak of it here. The operation is not original with me, but was practiced by my grandfather, Professor N. R. Smith. The crayon of caustic potash is sharpened to a point and is moved back and forth across the lid at about 4 mm. from its margin. An extension or spreading of the caustic action of perhaps 2 mm. from the line of application is to be allowed for. By simply causing the potash to act upon this little strip of tissue parallel to the lid margin, and moving it back and forth gently, perhaps a dozen times, you secure a very marked caustic action upon the tissue, and, when desired, you can check this action by the application of vinegar and water. As a rule the lid will immediately stay out in good position. A slough takes place, and the cases in which a complete cure is not effected in senile entropion are very unusual in my experience. I have sometimes employed it in cases of entropion the result of trachoma. The method is not adapted to entropion of the upper lid.

Dr. LIPPINCOTT. I have also used the method described by Dr. Weeks with very happy results, but I also, as Dr. Knapp has done, have used the skin flap. I have had no disagreeable re-

sults from the few thin hairs. The malposition of the lid is certainly very beautifully corrected by this method and the patient's comfort increased correspondingly. In one case of marked entropion existing for eight years, with an opaque cornea, the operation was followed very shortly by decided clearing of the cornea and improvement of the vision.

Dr. WILDER. I have found that a canthoplasty is necessary in many of the cases that I see in my service at the Illinois Eye and Ear Dispensary. I think it is well also to emphasize the importance of removing those bundles of muscular fibers that remain in the lower flap when the incision is made for the ordinary entropion operation. If this bundle is allowed to remain it naturally contracts just as it did before, and the entropion recurs. This is one of the important features of the operation of Dr. Hotz, who showed that in extreme cases if these muscle fibers are removed there is much less liability to recurrence than there otherwise would be. In addition, there may be combined with this operation the planting of an intermarginal graft, and in my experience the skin flap has been more satisfactory than the mucous membrane. I have often taken a strip of skin from the hairless portion of the hand with very good results.

I have found the correction of the deformity of the cartilage a very difficult point, and have devised an instrument for the purpose. With it a wedge-shaped piece can be taken out of the cartilage at any point. It has also proved useful for cutting a skin flap that will exactly fit into the little groove made by splitting the edge of the lid.

Dr. GREEN. My name has been mentioned in connection with an operation which was evolved in the course of my operative work over 25 years ago. I had tried, as I think I may fairly say, all the operative methods then in vogue for the cure of entropion, with trichiasis, of cicatricial type; that is, the type characterized by cicatricial contraction of the conjunctiva and tarsus following trachoma. I have uniformly found the operation of Arlt unsatisfactory. I believe, however, that the supplementing of his procedure by the insertion of a strip or wedge of integument or mucous membrane into the lid-margin obviates one great defect in that operation. My old Arlt operations were entirely successful as judged by their primary results, but when I saw the patients six months or a year later, as I often did, with their condition scarcely at all improved as compared with that

existing before the operation, I became disheartened. In a large number of cases of cicatricial entropion there is such alteration of the lid-margin that the cilia lie flat against the eyeball, and the ducts of the Meibomian glands also open backwards against the eye. In my attempts to devise some means to correct the incurvation of the tarsus I finally hit upon a plan, which was to me original, which consisted in making an incision from end to end of the lid through conjunctiva and tarsal tissue, down to the muscle, but leaving the muscle intact. The operation was completed by the removal of a narrow strip of skin from the front of the eyelid, near the line of the cilia, and closing the wound by sutures. Having had abundant experience from my own operations, and also from seeing the results of operations by others in which very broad pieces of skin had been removed, I had learned that in these cases there was nothing to be gained from the excision of a large flap of skin. I had even seen cases in which the lids could not be closed, as the result of such mutilation, but in which, nevertheless, the position of the lid-margin was not greatly improved.

Comparing this operation with other historical methods that had preceded it, I discovered that a mine of information was contained in Himly's *Krankheiten und Missbildungen des menschlichen Auges.* I found operative procedures there described which must have given good results, in which the entire thickness of the eyelid was cut through, so that the whole margin of the lid could be freely tilted forwards, as indicated in one of Dr. Ewing's diagrams, and as accomplished also in my own operations. Such an operation was the *tarsotomia horizontalis* of von Ammon (1833), as modified and improved by Rosas (1835). The obvious weak point in that method is the danger that the lid-margin may possibly slough, and more or less serious deformity result. The original Jaesche operation also involved the detachment of the tarsal margin from the rest of the lid, but it was an operation originally proposed for partial trichiasis, confined to a portion of the length of the eyelid. I learned also that an operation closely resembling mine had been described by Burow some two or three years before I made any public mention of my method. This led me to look a little further into the literature, and I found that this writer too had been anticipated, namely, by Celsus, by Aetius, and by Paulus Ægineta.

All these authors refer to a condition which is clearly to be identified as true cicatricial entropion such as follows trachoma, but they also employ language clearly descriptive of another

and different condition, namely spastic entropion, which almost always occurs in the lower lid, and which yields readily to different operative methods, including that mentioned by Dr. Theobald. The ancient operation, which in the upper lid is called *ἀναῤῥαφή*, and in the lower lid *καταῤῥαφή*, consists of two distinct procedures, namely, the *ἀναῤῥαφή* or *καταῤῥαφή*, proper, which consists in the excision of a rather large flap of skin from the eyelid and closure of the wound by sutures, and the *ὑποτομή*, or *subsectio*, which is a long and deep incision carried through the conjunctiva and tarsus parallel to the line of the cilia. All the writers mentioned state, however, that the *ὑποτομή* may be sufficient, without the excision of the flap of skin from which the operation derives its name.

My first insistance upon some modification of this ancient method was on restricting the width of the strip of skin to be removed, and, secondly, on a better way of applying the sutures, which, while not exactly that of Dr. Ewing, is much like it. Presently, however, having occasion to operate upon cases in which no skin could be spared, it occurred to me to try a substance not known to the ancients, namely collodion. After making the tarsal incision from one end of the lid to the other, making it deep, so that the lid margin could be easily turned out, and painting a strip along the entire length of the lid with contractile collodion, I was able to evert the lid-margin without previously excising any skin or using any sutures. Now while I do not hesitate to remove a strip of skin whenever it appears to be redundant, I nevertheless limit myself to removing a very narrow strip, and in the majority of cases I do not excise any skin at all. In the process of healing, the gaping incision in the tarsus fills rapidly by granulation and is soon covered by smooth conjunctiva. The increase in the height of the tarsus, by this formation of new tissue, is generally not less than two millimeters, and this gain in height and also the restoration of the lid-margin and the correction of the direction of the cilia are permanent.

This operation is essentially one adapted to the cure of cicatricial entropion of the upper lid. When the operation is performed on the lower lid the results are less satisfactory. I believe the modification described by Dr. Ewing will prove valuable. So far as I have had an opportunity of observing the cases in which he has employed this method in operating for true cicatricial entropion of the lower lid, the results have been excellent.

Dr. TORRANCE. As I come from the home of trachoma and trichiasis, perhaps I may be allowed to say a few words. Probably from sixty to eighty visitors a day come to my hospital suffering from this terrible disease, which causes more blindness than people are aware of. I find that eyes differ very much and that no one method of operating will suit them all. It is very important to consider the thickness of the tarsal cartilage and how the hairs grow out. Sometimes you will find the glands coming right out on the surface, and it is difficult to make this incision and keep all the hairs of the anterior flap out, and the cause of failure I believe in many of these cases is that you do not get all the hair bulbs in your anterior flap. Where you have a thick cartilage, my experience is that the best operation is the old Snellen method. I find that in at least fifty per cent. of all cases you can get a very good result with the old Jaesche-Arlt operation. There is no danger whatever of sloughing in the old cases. I have never seen one. You know how vascular everything about the eye is, and even though you have a very small flap it will heal and grow. I have tried the so-called Van Millingen operation, but I may say that as a matter of fact I try to adapt the operation to the case in hand and do not know when I begin an operation how I am going to end it.

Dr. WEEKS. I am very much pleased to have listened to the extended discussion of this subject, for it is really, to my mind, an important one. The operation that Dr. Green has so well described has certainly proven unsatisfactory in the hands of some others than Dr. Green, for a number of cases have presented themselves to me with relapses.

In regard to dissecting out the sub-cutaneous tissue in the lower flap, if the tissue is very abundant and bulges into the wound, I excise some of it; if we should excise all of this subcutaneous tissue we might jeopardize the nutrition of the lower flap. I do not think the operation referred to by the last speaker, that of scalping, should be done at all.

THREE CASES OF VASCULAR TUMOR OF THE ORBIT. OPERATION ON TWO OF THE CASES WITH SUCCESSFUL RESULT. APPARENT SPONTANEOUS CURE OF THIRD CASE.

BY CHARLES STEDMAN BULL, A.M., M.D.

NEW YORK CITY.

CASE I. *Large Nævus of Orbit and Eyelid.*

Miss E. W., aged 41; first seen January 14, 1898. Patient has been a teacher for many years, and her eyes have been under a more or less constant strain. Refraction, hypermetropic and astigmatic; vision normal with correcting glasses; media clear, and fundus normal, though slightly hyperæmic; field of vision normal; tension normal. About two years before I saw her she first noticed a slight protrusion of the right upper lid, coming on in the morning after she had risen, and increasing somewhat towards evening. It remained about the same size for eighteen months, but since then it has steadily increased in size, and during the last two months has grown somewhat rapidly. At first it always disappeared during the night or after lying down, but of late it has been constantly present. When I first saw her there was partial ptosis, the lid covering about three-fifths of the cornea, but it could be completely raised by the united action of the levator palpebræ and occipito-frontalis muscles. The tumor presented just above the middle of the right upper lid, as a distinct congeries of vessels, showing blue through the skin. This mass of blood vessels involved the upper portion of the lid, and could be followed inwards and backwards along the nasal wall of the orbit. There was neither pulsation nor bruit, and there had been no pain at any time. Any forced muscular exertion, lifting, coughing, or forced expiration, caused a distinct increase

in the size of the tumor, and stooping or bending towards the ground produced a rapid increase in size, so far as to entirely close the eye, and this condition did not subside for about five minutes after resuming the erect position. After lying on the back for fifteen minutes there was a perceptible diminution in the size of the tumor. A careful examination of the nasal meatus and naso-pharynx revealed an hypertrophy of the turbinated bones, and cystic disease of the right middle turbinated bone, with a subacute laryngitis.

On the inner aspect of the left thigh, just above the internal condyle of the femur, there is a large purple nævus, about two and a half inches in diameter and of an irregularly circular form, with some elevation above the surrounding skin, and a similar nævus, somewhat smaller, on the inner aspect of the left tibia, just below the condyle. These nævi had existed for many years. Pressure upon the tumor with the finger caused its complete disappearance within the orbit, but it reappeared as soon as the pressure was discontinued. There was no sign of a similar growth in the other orbit. There was no cardiac complication of any kind.

After a careful study of the case on several visits, it was decided to try what could be effected by electrolysis, though I had never employed this method of treatment in so old a patient. The first application, lasting five minutes, produced no apparent effect. Between February 17 and November 19, 1898, electrolysis was applied sixteen times at intervals of varying length. Then the patient was obliged to absent herself from observation for a period of three months. Then the electrolytic treatment was resumed and continued at intervals of four days for a month. This method of treatment produced some consolidation in the tumor, but no diminution in its size. It was then decided to attempt its excision. On March 14th the patient was prepared for the operation under the strictest antiseptic precautions. She took the anæsthetic, ether, extremely well, and was profoundly anæsthetized in about six minutes. I was about to make the preliminary incision when the tumor suddenly increased rapidly in size and

extended in all directions, upwards upon the forehead, inwards over the bridge of the nose, outwards upon the temple, and downwards upon the side of the nose, and soon reached the size of an orange. The skin covering this area was of a dark purple color and was very tense. The anæsthetic was at once discontinued, and all operative procedures were temporarily postponed. The enormous swelling began slowly to subside as soon as the patient recovered consciousness, but did not entirely disappear for two days. She remained in the hospital till the end of March, and as I went off duty April 1st I did not resume charge of the case until the following October.

When I saw the patient again, on the first of October, the condition was about the same as it had been in the preceding March, and it was decided to again attempt the removal of the tumor by excision.

On October 11, 1899, the operation was performed under cocaine anæsthesia, hypodermically. Two injections were made, each of ten minims of a five per cent. solution of cocaine, into the mass, one on the temporal side and one on the nasal side. An incision was made, an inch and a half long, just beneath the superior orbital margin, through the skin and tarso-orbital fascia, care being taken to avoid incising the tendon of the levator muscle. The index finger was then introduced through the wound for exploratory purposes. No distinct tumor was found, but a mass of enlarged vessels was discovered, filling the entire nasal side of the orbital cellular tissue, extending back nearly to the apex of the orbit, and upwards along the roof of the orbit. The bleeding was somewhat profuse. No opening into the ethmoid cells or frontal sinus was found. The mass of connective tissue and enlarged vessels was separated as rapidly as possible from the eyeball and periosteum, and then grasped by a pair of stout forceps with very broad blades. The mass was then put on the stretch, being drawn forwards and upwards, and a stout catgut ligature was passed round it, pushed back as far towards the apex of the orbit as possible, tied tightly, and the ends were then cut off. Much of the bleeding then ceased, and an examination

showed that the pulley of the superior oblique and the belly of the muscle were uninjured. After all active bleeding had ceased, the cavity in the orbit was carefully irrigated and packed with iodoform gauze. The patient did very well, there was no secondary hemorrhage, and very little oozing. The dressing was left undisturbed for three days and was then removed, the cavity was again washed out, and the gauze packing reapplied. Fresh dressings were applied every two days for two weeks, at the end of which period the cavity had filled from the bottom. The wound in the skin was then closed by six sutures. One month after the operation the improvement was very marked, but there was still some bulging and protrusion at the inner end of the upper lid, and the enlarged vessels could be distinctly seen through the skin.

On December 7, 1899, a second operation was done under the hypodermic injection of cocaine, for the removal of the palpebral portion of the growth. An incision was made through the skin of the lid, about an inch long and extending towards the top of the bridge of the nose. The skin was dissected free in all directions, and the mass of enlarged vessels was then grasped with the same broad forceps and rapidly separated from the tarsus as far as the inner angle of the orbit and lachrymal bone, where there was quite a firm connection with the periosteum. The mass was then tied off in a similar way with a catgut ligature. There was but little hemorrhage, but the wound was packed with gauze as at the first operation. This was removed on the fourth day, the wound was carefully cleansed, and closed by three sutures. The result was very successful, and on April 18 the scars were scarcely visible; there was no protrusion or discoloration, and only a very slight condition of ptosis.

The two masses of tissue and enlarged vessels were examined by Dr. Dixon, the Pathologist of the Eye Infirmary, who reports as follows: "The specimens submitted by you are composed of fat, loose connective tissue, a large number of blood vessels, and a few cavernous spaces, with considerable extravasation of free blood into the tissue. Diagnosis: Caverno-Angioma."

CASE II. *Pulsating Tumor of the Orbit.*

J. B., aged 23, first seen September 2, 1889. Two years before I saw him he had received a violent blow on the right side of the head by a large timber falling from a height. He was unconscious for two days, and then slowly regained his senses. There was a large, irregular scalp wound, running from the middle of the sagittal suture downwards, and forwards across the parietal and squamous bones as far as the middle of the zygoma. He said that he understood that no fracture of the skull had been found. He was confined to his bed for two months, with more or less constant headache and mental torpor. When he first attempted to walk he staggered and complained of vertigo, but does not remember that he ever had diplopia. The tendency to vertigo gradually diminished, though the attacks still come on at irregular intervals. He never fully regained his physical strength or mental vigor. For some weeks after the accident the eyelids were swollen and bruised as if from subcutaneous extravasation of blood, and there was an extensive hemorrhage beneath the conjunctiva, downwards, and on the nasal side. Somewhat more than a year after the accident the upper lid began to swell and the eye to protrude, and these symptoms have steadily increased up to date. The headaches have also become more continuous, and are always worse when he bends forwards or stoops.

When I saw the patient the right eye protruded forwards and downwards, but was freely movable in all directions except upwards, in which direction its motility was limited. The upper lid was much enlarged and drooped over the eye, was of a dark red, almost dusky hue, and pulsated strongly. The whole eyeball also pulsated visibly, and a very distinct thrill was communicated to the fingers when placed upon the lid. On auscultation, a harsh blowing sound was heard over the closed lids, on the right side of the forehead, and on the right temporal region, like the exhaust of steam pipes heard at a distance. The media of the eye were clear, and the retinal veins were engorged, tortuous, and pulsating; vision was 20/30 in the right eye and 20/20 in the left eye. A rough, broken ridge of bone was discovered on the floor of the

orbit, running backwards from the inferior orbital margin near the inner canthus, and another sharp edge of bone at the infero-temporal angle of the orbit was found, which ran backwards and inwards towards the median line. Pressure on the common carotid artery on the right side, just below the region of its bifurcation, caused an immediate and marked diminution in the pulsation and bruit, and in the prominence of the eyeball, but it could not be continued for more than four minutes, because of an apparent marked interference with the respiration produced by the pressure.

There seemed to be no doubt that the accident two years before had caused a fracture at the base of the skull, involving the floor of the orbit, and probably the optic foramen. The main point to determine if possible was whether the pulsating tumor, evidently existing in the orbit behind the eyeball, was a pure arterial aneurism of the ophthalmic artery and possibly of the ciliary arteries, or whether the fracture extended farther back, and involved the internal carotid artery and the cavernous sinus. The history of severe traumatism and the gradual development of all the orbital symptoms would seem to favor the idea of aneurism of the ophthalmic artery. But this lesion is rare and has been found in very few cases. The more frequent lesion of laceration of the carotid artery within the cavernous sinus is always due to fracture at the base of the skull, and the orbital symptoms generally develop somewhat rapidly within a few weeks after the injury. In my patient the orbital symptoms did not develop until a year after the receipt of the injury. It may be here remarked that the literature of this subject is quite extensive, but our exact knowledge of such cases is relatively very small.

It was thought best to try what could be effected by compression of the common carotid in the neck, at first by the fingers, and afterwards by a pad devised for the purpose, but all these efforts were abandoned at the end of the first week, on account of their interference with the respiration. It was then decided to ligate the right common carotid, which was done under the strictest aseptic precautions. The incision was made in the usual place

and followed the inner border of the sterno-mastoid muscle, extending from just below the cricoid cartilage nearly to the sterno-clavicular articulation. Careful dissection exposed the artery without any difficulty, the sheath was opened, and the aneurism needle was gently passed between the sheath and the vessel, and around the artery till the end appeared in the incision. The ligature was then passed through the eye and the needle was withdrawn, bringing the ligature with it. The latter was then slowly and firmly tied. No vessels of any size were wounded in the operation. All pulsation and bruit ceased immediately in the tumor. The wound was then closed, covered with iodoform, and a small pad and bandage were applied. The wound healed rapidly, but the patient was kept in bed for two weeks. On the fourth day there was a return of the bruit and thrill to a slight extent, but no positive pulsation, and these symptoms continued with varying intensity for nearly six weeks. Even after the patient was discharged he was kept under observation for more than a year, and there was always a slight thrill perceptible to the fingers, though auscultation revealed no bruit. Somewhat more than a year after the operation the patient contracted a pneumonia, which rapidly involved the entire right lung, and he died on the eighth day. I endeavored to procure an autopsy but was unsuccessful, and I am still ignorant of the exact pathological condition of things in the orbit. The protrusion of the eyeball gradually subsided, and its motility was restored to the normal condition. The vision was immediately impaired by the operation and sank to 10/200, but in about three weeks it began to improve, and finally rose to 20/100. The fundus immediately after the operation was very pale, but gradually regained an approximately normal appearance, though the retinal arteries never attained their normal caliber.

CASE III. *Pulsating Tumor of the Orbit. Apparently Spontaneous Recovery.*

Mrs. T. W., aged 39, first seen January 9, 1899. This patient had had more or less occipital headache for nearly six months,

and had pain in the right orbit for nearly four months. Three months ago the right eye began to protrude. Four weeks ago the right upper lid began to droop and this ptosis increased. On examination I found complete ptosis and complete paralysis of all the branches of the right third nerve, including the branches to the sphincter iridis and to the ciliary muscle. The exophthalmos was forwards and outwards, and could not be reduced by pressure. The eye could be moved to the outer canthus. The media were clear and the ophthalmoscopic examination was negative. R. E. V. = 20/100 and with + D 3 = 20/30: L. E. V. = 20/20. Nothing could be discovered in the orbit by palpation, and there was no bruit or pulsation, nor any thrill. A careful examination of the nose, naso-pharynx, and ears revealed nothing but a chronic catarrhal condition of the mucous membrane and a moderate amount of hypertrophy of the turbinated bones on the right side. There was no evidence of any disease in the maxillary antrum. The patient was seven and a half months pregnant with her eighth child. The urine was examined and was of normal specific gravity, acid, clear, light straw color, and contained one per cent. of albumen, but no sugar and no casts. Six analyses were made of as many different specimens, and each gave practically the same result. The heart sounds were normal, and there was no hypertrophy. There was no history of any injury to the head, nor of any traumatism.

The patient was put on small doses of Potassium Iodide and carefully watched. There was a slight improvement in the ptosis, but none in the motility of the eyeball or in the exophthalmos. On January 29th the patient complained of a sharp pain in and around the orbit, and of a constant rushing noise in the head on the right side, which had come on suddenly two days before, and sounded like the falling of water from a height. There was a well-marked thrill on palpation over the closed lids, a slight visible pulsation in the eyeball, and a well-marked bruit on auscultation over the eye, forehead, and temple. The pressure over the carotid artery in the neck produced no appreciable effect upon either the pulsation or the bruit.

On February 6th the patient complained of an obstruction in the right nostril, but an examination showed nothing more than a swollen mucous membrane.

Owing to her advanced pregnancy, it was thought wiser to wait until she had recovered from her confinement before attempting any operative treatment. On March 21st she was delivered of a rather small but healthy male infant, the labor being brief and without instrumental assistance. There was almost immediate relief from the pain in the head and orbit, which had become continuous until her confinement was over. Ten days after delivery a purulent discharge appeared from the left ear, neither accompanied nor preceded by any pain.

On April 12th the thrill under the finger was particularly marked at the inner canthus and over the internal angular artery. There was a slight visible pulsation of the eyeball, and a strong blowing sound was heard over the eye, forehead, and temple, and indistinctly at the vertex and over the malar bone. She complained of a constant dull ache in the eye, but the severe pain in the head and orbit had disappeared after the birth of the child, and had not returned. The discharge from the left ear had ceased, and the perforation in the drumhead was closing, but she complained of constant tinnitus. No effect on either bruit or pulsation was produced by compression of the carotid in the neck. The pulse was 132 and regular. There was no enlargement of the thyroid.

On April 24th there was a marked improvement in the ptosis, in the motility of the eye, and in the exophthalmos. The bruit was less audible and the pulsation less noticeable. The patient did not complain of the noise in her head, and said that it sounded very much farther away.

On June 1st all bruit and pulsation had ceased, the ptosis was nearly gone, the eye was freely movable in all directions, and the protrusion much diminished. The tinnitus in the left ear was only perceived when she was tired, or excited, and the hearing had improved. This patient has not been seen since, but the case looks like a spontaneous recovery.

HISTORY OF A CASE OF REMOVAL OF A RETROBULBAR LYMPHOSARCOMA WITH PRESERVATION OF NORMAL VISION.

BY CHARLES A. OLIVER, A.M., M.D.,

PHILADELPHIA, PENN.

On the 11th of January, 1899, F. K., a fifty-seven year old weaver, applied at my clinical service at Wills' Hospital. He gave the following history: He was born in Germany. His health was good until twenty-one years of age. At that time a swelling termed a "goiter" by some government surgeons slowly developed in his neck. The enlargement became so great in size that he was rejected from military service. It was unaccompanied by exophthalmos, tachycardia, or any vasomotor symptoms, and gradually disappeared in about sixteen years' time.

Twenty-six years before I saw him he had a chancre on the glans penis. This, which lasted some five or six weeks' time, and was repeatedly cauterized, was not followed by any glandular enlargements, skin eruptions, or alopecia. Six years after this he began to complain of occasional diplopia.

Many years ago, possibly about twenty, he went to Wills' Hospital for glasses, though he does not remember the exact date of the visit or the name of the attending surgeon.

In 1887 his eyes were examined by Dr. A. G. Heyl at the Hospital of the Protestant Episcopal Church in Philadelphia. Dr. Heyl informed him that "a small vessel which would eventually give him trouble was developing in his right eye."

Twelve years later he again sought advice at Wills' Hospital and became a patient of Dr. S. D. Risley. Study of the notes of the case in Dr. Risley's records shows that vision in each eye was brought to practically normal by a convex sphero-cylinder lens placed before the right eye and a convex spherical lens before the left one. At that time he complained of an intense pain in the

right side of the head and in the right eye. This he said dated back for some three weeks' time, and had been produced by catching cold. At that time tension in each eye was normal. The right eye was congested. Its cornea was sensitive, and its iris responded to light-impulse and efforts for accommodation. The rims of the crystalline lenses were noted as being opaque, and there were four degrees of homonymous diplopia for distance.

For five years before I saw him he had noticed a "ringing at night in the ears," this having gradually lessened. He never complained of dizziness.

Three years before his first visit he suffered from an attack of gonorrheal urethritis. A year after this he had a slight fall, followed in six months' time by a prominence of the right eye. About three months before he came to the clinic he noticed that he could feel a swelling above the same eye.

He stated that eight days before he had applied to the clinic he had consulted Dr. T. B. Schneideman of this city, who informed him that he was suffering from an orbital growth, and advised him to go to Wills' Hospital for operation.

A photograph taken when he was twenty years of age showed a swelling in his neck, which was more marked on the right side. There was not any appearance of exophthalmos. The palpebral fissures were apparently of the same size.

Another photograph, taken in a group some eighteen years later, was unfortunately so positioned as to make the patient face the direct sunlight. In it some spasm of the left orbicularis palpebrarum associated with an elevation of the left angle of the mouth could be determined; both expressions probably having been caused by the impingement of the direct rays of the sun upon the parts.

In a third photograph, sat for only five or six years before he came to the hospital, the neck appeared normal. The right palpebral fissure was a trifle wider than its fellow, and there was no exophthalmos.

A fourth photograph, taken in a badly placed and too brilliantly lighted group some three years after the third one, ex-

hibited a similar character of facial distortion to that seen in the second picture. In it there did not seem to have been any exophthalmos present.

At the time of the first examination it was found that the affected organ projected markedly forwards and downwards, its corneal summit being six millimeters in advance of its fellow and three millimeters lower. The conjunctival vessels, particularly the bulbar, were injected and swollen. Above the globe there was a rather deeply seated and freely movable mass of tissue giving a sensation to the finger tips as though it were composed of a series of underlying swollen and twisted blood vessels. At times this tumor-mass seemed to pulsate synchronously with the aortic beat. Carefully repeated examination, however, failed to evidence any thrill, though an unmistakable bruit could be occasionally heard in the orbit and in the temporal region. There did not seem to be any projections or deformities in the osseous parts. Von Graefe's and Stellwag's signs were undeniably present.

The pupil of the affected side was two and a half millimeters in size, and oval, with its long axis at eighty degrees. There were a number of equatorial striæ in both the anterior and posterior cortices of the crystalline lens. The optic disc was seven by eight diameters in its apparent magnitude, and its long axis was situated at eighty degrees. The edges of the disc were everywhere hazy, though a broad scleral ring with an absorbing conus beyond could be fairly well seen. The disc substance was dirty dull red gray in tint, and there was an excentrically situated physiological excavation. Both the retinal veins and arteries were much reduced in size, the former being exceedingly tortuous. The usual light streak along the vessels could not be determined after most careful examination. There was not any spontaneous arterial pulse, though a slight venous pulsation could be determined at times. The chorioid was quite granular but did not evidence any signs of gross inflammation. There was a marked astigmatism, the fine retinal vessels at the long axis of the disc being most plainly seen with a convex lens of five diopters' power.

The pupil of the left eye was the same size as its fellow, its

long axis being at seventy degrees. With the exception of a few striæ in the anterior and the posterior cortex of the crystalline lens, the media were clear. The optic nerve head was seven by eight diameters in apparent size, with its long axis situated at eighty degrees. There was a broad scleral ring to the outside of the nerve head with a narrow one in. Annular pigmentation could be plainly seen. The currents of the retinal arteries were somewhat narrowed, although the retinal veins were not tortuous. The ordinary light streak along the main retinal vessels was quite manifest.

The iris of the left eye reacted more freely to light-stimulus and accommodation than its fellow, while varying degrees of exophoria during both near and far vision could be determined at times; particularly in the lower portions of fields of vision.

Uncorrected vision with the right eye equaled about one-seventh of normal, while that with the left eye was one-sixth. Both the accommodative regions and powers in each eye were proportionate to the character and the degrees of refraction error and age. There was a marked astigmatism with hypermetropia and presbyopia.

The fields of vision for white, red, and green were normal. The field of fixation was quite large and well shaped.

General physical exploration and study of the blood made for me by my friend and former student, Dr. Joseph Sailer of Philadelphia, was practically negative. There was not the slightest evidence of any gross organic disturbance, the signs of Hodgkin's disease being most carefully and assiduously sought for. Dr. Sailer's report in full is as follows:

"Muscular system well developed; skin sallow; mucous membranes good color; no scars or marks upon the body. None of the lymphatic glands can be palpated through the skin. The spleen is apparently large in size. The liver can be felt one finger's breadth below the border of the ribs and extends above to the sixth rib. The heart dullness commences superiorly at the upper border of the fourth rib at the mid-sternum and passes to one inch to the right of the left nipple line. The apex beat is dis-

tinctly felt in the fifth interspace in the nipple line. On auscultation there is a reduplication of the first sound at the apex, which persists with a slight roughness as the stethoscope is placed at higher levels. The second sound is somewhat roughened in the third interspace. The second aortic sound is louder than the second pulmonic. The first sound in the fifth interspace to the right of the sternum is loud, clear, and resonant.

" There is distinct pulmonary expansion at the liver border, although posteriorly, at the apex, no expansion can be felt by percussion. On auscultation there is prolongation of the expirium at both apices. This is less distinct towards the base; otherwise the pulmonary sounds are clear.

" By percussion there appears to be a mass giving a tympanitic note extending two inches below the ribs of the left side, and about one inch to the right of the median line, which probably represents the stomach. Palpation and percussion of the abdomen is otherwise normal.

" There are no pareses or any gross disturbances of sensation. The right bicipital and corresponding tricipital reflexes are slightly increased. There is considerable myotonic irritability. The tendon reflexes of the left arm cannot be elicited, though the myotonic irritability is similar to that as on the right side. The thoracic and abdominal reflexes are prompt. The cremasteric reflex is very pronounced on both sides. The knee-jerks are exaggerated. There is a distinct patellar tendon reflex on each side. The achilles tendon reflex cannot be distinctly obtained. There is no ankle clonus.

" Examination of the blood shows that the red blood cells are of normal size and shape and stain distinctly. There is about a normal proportion of white blood cells with the following differential count: polymorpho-nuclears, 64 per cent.; small lymphocytes, 29 per cent.; large mononuclears, 5 per cent., and degenerated cells, about 2 per cent." No eosinophilic or basophilic cells were present.

Both chemical and microscopic examination of the urine failed to reveal the presence of anything abnormal in this excretion.

In other words, aside from the slight alteration in the heart, which was probably due to a commencing atheroma of the valves, and an emphysema of the apices of the lungs, the general physical examination was negative.

After a fair trial of medicinal agents, including the administration of large doses of arsenic, I made the following operation for the removal of what I felt certain was a postocular growth. A circumlinear incision following the line of the upper orbital margin and extending nearly the entire length of the superior palpebral fold was made in the upper eyelid just above its sulcus. The underlying tissues were freely dissected until the finger tip could be gotten into the extraocular muscle cone, care being taken to avoid injuring the fibers of the levator muscle.

In this position a multilobular mass which was composed of four distinct parts could be plainly felt. The largest lobe extended into the upper inner angle of the orbit, and the entire mass was connected with a peduncle which arose from the outer side of the lobe outside of the funnel, and passed directly back to the apex of the orbit.

These masses were extirpated by means of the finger tips, scissors, and flushings of one to four thousand strength bichloride of mercury. The operative field was freed from all useless and ragged tissue, cleansed, and dried. The surface wound was coapted with six superficially placed iron dyed black silk sutures. The conjunctival sac was cleaned with sterile water, and a few drops of a one per cent. strength solution of atropine were dropped on the corneal surface. The field of operation was covered with a single figure-of-eight gauze bandage. The patient was placed in bed and iced compresses were applied on the bandage for the first twenty-four hours.

The specimens were given to Dr. Edward A. Shumway in charge of the Eye Department of the Pathological Laboratories of the Philadelphia Polyclinic and School for Graduates in Medicine.

The stitches were removed on the second day, and as there

had not been any post-operative reaction, the patient was given indoor liberty.

A marked ptosis with almost complete want of action of the palpebral levator ensued, while examination of the extraocular muscle balance at this early period showed but two and a half degrees of exophoria at six meters' distance. Corrected vision in each eye was almost normal.

In ten days' time the ptosis had somewhat diminished, the patient being able to lift the upper lid some two or three millimeters.

In less than a month, without the employment of any form of treatment, the eyelid operated upon could be lifted so well that its ciliary border was kept almost constantly on a level with that of its fellow — the closest scrutiny being necessary to distinguish any difference between the widths of the two palpebral fissures.

Examination of vision and refractive error, four, eight, and twelve months later gave normal results.

The double vision was quite persistent and most variable, necessitating at first, though at present to a much less degree, the employment of a shade before one eye during any attempts for near work.

At present writing, nearly eighteen months after the operation, there has not been any return of the growth, the patient being well, and daily employed at his livelihood.

The pathological and microscopic report of the orbital growth was practically as follows: The specimens which exhibited similar macroscopic appearances consisted of six pieces, two of which were large and four small. The large ones were evidently a part of one mass. Together they measured four centimeters in length by two and a half centimeters in thickness.

They were imbedded in celloidin, and the sections were stained with hematoxylin and eosin.

Examination with the microscope showed the tumor to mainly consist of a dense mass of closely packed round fascicular nuclei. The cell bodies were indistinct. In places there were broad bands of connective tissue that stained deeply with eosin. In some por-

tions of the growth, aggregations of large endothelial cells with distinct protoplasm and pale round or oval nuclei could be seen. Many of these were associated with blood vessels, though in a few situations they were collected into clumps without the presence of red blood cells. The vessel walls were somewhat thickened and exhibited a tendency to hyaline change. There were neither any aggregations of true lymphocytes nor evidences of karyorhexis in the nuclei.

A carefully conducted detailed local and general re-examination of the patient at present writing fails to show the slightest evidence of any local return of the growth or the least appearance of any metastasis. With the exception of an almost infinitesimal degree of non-disturbing diplopia in the lower field of vision during near work, the gross local signs have ceased. The patient is apparently healthy in every respect and is employed many hours daily as a weaver.

REMARKS.

This case is of some interest.

Occurring in a goiterous subject, free from any other sign of Hodgkin's Disease, and with the history of acquired syphilis, the tumor furnished the ordinary symptoms of exophthalmos with bulbar displacement; mechanical and functional limitation of motility of the eyeball; diplopia; contraction of the retinal arteries, and engorgement of the retinal and conjunctival veins, in fact, most, if not all, of the pressure symptoms of a retrobulbar growth.

The tumor successfully extirpated without any injury to the eyeball or its functioning power, merely giving rise to a temporary disturbance of the contiguous muscular structures, serves to illustrate the average results of ophthalmic surgery of to-day.

The findings of the microscope, which necessarily are indeterminate as to such growths being truly sarcomatous or lymphomatous in character, taken into consideration with the multilobular nature of the mass, distinctly point to its being a lymphsarcoma.

The lapse of time since the removal of the growth without the

least signs of any local or metastatic expression of the former disease, although of course of too brief a period for any certainty of conclusion, is of much importance in showing that the growth was not malignant in character; while the return of the organ to its original healthy condition is a result which must be considered as most fortuitous.

DISTENTION OF NASAL ACCESSORY SINUSES INVOLVING THE ORBIT.

By GEORGE C. HARLAN, M.D.,

PHILADELPHIA, PENN.

Some excuse is perhaps in order for introducing here a subject encroaching so much on the border regions of rhinology, but the ophthalmic surgeon is held responsible at least for the diagnosis, if not for the treatment, of the orbital and ocular conditions resulting from disease of the neighboring sinuses, and it is well known how difficult that diagnosis may be and how often high authorities have failed in the attempt to make it. This difficulty was painfully brought to my notice a few years ago by the case of an important patient who came to me first with what seemed to be an ordinary lachrymal abscess. During the treatment there was developed an exophthalmos which I supposed was due to orbital cellulitis but was unable to relieve. Inquiry of a rhinologist under whose care the patient had recently been, and consultation with a distinguished ophthalmological confrere and a well-known general surgeon, followed by an exploratory operation, failed to clear up the case; and it was not until rather late in the progress of a disease that eventually resulted in death that I made the correct diagnosis of sarcoma of the maxillary sinus. There was some comfort to be found in the records in literature, which showed that I was by no means the first or the most experienced to meet with similar difficulties. Then, too, in a large proportion of the cases in which empyema of the neighboring

cavities gives rise to orbital symptoms, the disease may be attacked most thoroughly and treated most successfully through the orbital walls. To these considerations may be added the comparative rarity of such affections. As Dr. Knapp has observed, "the affections of the frontal sinuses are so rare that no one observer can obtain a sufficient knowledge of their various clinical features by his own experience," and the same may be said of affections of the ethmoid cells.

CASE I. *Tumor of Orbital Wall from Empyema of Ethmoidal Cells.*

F. C., aged nine years, suffered a fracture of the nose from a fall when three years old, but had no trouble, except obstruction of the right nostril, until attention was called to the right eye, some months before he was brought to me for treatment, on September 8, 1898, by epiphora. There was a small tumor, a little larger than a split pea, at the inner angle of the orbit just above and behind the lachrymal duct. It was rounded and of stony hardness and had all the appearance of an ivory exostosis. There was no evident exophthalmos, but a slight limitation of adduction and occasional diplopia, and a red glass brought out an exophoria of ten degrees. The septum was deviated to the right, and that side of the nose was too much obstructed to admit of satisfactory examination, but Dr. MacCoy found only a slight hypertrophy of the turbinates on the left side and no catarrh. Two months later the tumor had extended downward below the tendo-oculi and increased somewhat laterally, so that it measured 12 mm. vertically and 6 antero-posteriorly. The eye was now decidedly displaced outwardly. The upper part of the tumor was still bony hard, but it yielded slightly to pressure below, which indicated pretty clearly the character of the affection.

On November 25th an incision was made, beginning in the region of the trochlea and curving along the margin of the orbit and side of the nose to end below the tendo-oculi. A flap of skin was turned down, freely exposing the tumor which the knife easily penetrated and gave exit to several drachms of a dark-colored ropy fluid. The bone was cut away with small rongeur

forceps until the little finger could be introduced into the cavity, which extended slightly backward but more downward and forward well into the nostril. There was no dead or bared bone. The lining of the cavity was smooth and felt like mucous membrane. The walls were bony, except the lower external portion, where there was a membranous space apparently periosteal. Through this membranous portion a director was pushed and was followed by a fenestrated silver probe, very sharply curved, and carrying a thread to which a drainage tube was attached. The tube was thus introduced through the wound and passed out by the nose, and the edges of the wound were sutured about it. The cavity was syringed daily with warm boric acid. At the end of ten days the tube was drawn down so as to disengage it from the wound, which was allowed to heal, but was retained in the cavity and held in place by a silver wire fastened to the nose by plaster. A month later the tube was removed entirely; the wound had healed and there was no deformity, beyond a slight linear scar nearly hidden by the eyebrow. More than a year afterwards there was no sign of a return of the disease.

There can hardly be any question that the disease originated in the anterior ethmoidal cells, though the cavity extended far downward and forward into the nasal fossa. It was probably of long duration and connected with the fracture of the nose. Though the ethmoid cells are developed comparatively early, they are normally still very small at nine years of age, and this case illustrates how extensively they may be distended without disease of the bone.

CASE II. *Extensive Exophthalmos from Empyema of Frontal, Ethmoidal, and Maxillary Sinuses.*

I. J., aged 19, had tonsilitis several times as a child and has since had repeated severe attacks of grippe. He has always had slight nasal catarrh, with frequent exacerbations. On June 6, 1899, while chewing maple candy, he felt a severe pain in the right side of his face, the next day headache and chills, and two days later the eye began to protrude. His attending physician reports

that there was extensive swelling of the nose, throat, soft palate, cheek, and eyelids, and exophthalmos. A competent dentist examined the teeth and pronounced them sound. Dr. Ed Martin, who was called in, found the symptoms so severe that he suspected basilar meningitis. He broke through the median wall of the right maxillary antrum, by way of the nose, and gave exit to a large quantity of pus, after which the exophthalmos, which had been very great and directly forward, was much diminished. A few days later, incisions were made into the orbit, but no pus was found. A drainage tube was worn in the nose for two weeks. Since the operation he had had some discharge, though not profuse, from the nose, chiefly by way of the pharynx. He was referred for examination of the nose to Dr. Walter Freeman of the Philadelphia Polyclinic, who reported "almost total obstruction of the left fossa by deviation of the septum. The right side is also obstructed considerably by septal deformity. The faucial tonsils are very large and should, with the adenoids, be removed. The elevation and narrowing of the hard palate, the cause of the septal deformity, show that the deformity has existed all his life, the primal cause being the adenoids. *There is no involvement of the antra.*"

The history of this case indicates that it was in the first instance one of polysinusitis involving the frontal, ethmoidal, and maxillary sinuses and originating in rhinitis. The disease seems to have been checked in the antrum by the intranasal puncture made by Dr. Martin, while it continued to progress in the frontal sinus and ethmoidal cells. It may have originated independently in each or have been propagated from one to the others; more probably from the frontal, which is so rarely involved alone in purulent inflammation that Zukerkandl states that in a large experience he has never met with an isolated case. This is not to be wondered at when we remember that it pours its secretion directly into the anterior ethmoidal cells and indirectly into the antrum.

Admitted to Wills' Hospital February 9, 1900. O. D. exophthalmic and pushed very much down and slightly out. Mo-

tions limited up and in. V = 5/C in small nasal field. Fundus indistinct from cloudy vitreous, but disc apparently atrophied. Palpation gave the impression of a rather firm swelling of orbital tissue above the ball. Near the nasal end of the middle third of the upper orbital margin there was a tumor about the size of a cherry, having exactly the appearance of a dermoid cyst, except that it was firmly adherent to the bone. When it was opened, a small amount of dark colored fluid escaped. A spontaneous opening would probably have resulted later in a permanent fistula. The walls of the sac were formed of periosteum, and at its base there was an opening in the bone about 6 mm. by 4 mm. in size, through which a probe passed freely into a large cavity. The incision was continued along the margin of the orbit and side of the nose and a skin flap turned down, and the opening in the bone was enlarged with a gouge until it admitted the little finger. The cavity was found to occupy the median half of the roof of the orbit and the upper half of its median wall, and to extend backward about 3 cm. Its floor and outer wall were composed partly of the lower lamina of the roof of the orbit and partly of thickened periosteum containing thin scales of bone. There was no communication with the orbit, but on the median wall of the cavity, near its bottom, there was a loose plate of bone about 1 cm. by ½ cm. in size, a part of the os planum, and when this was removed a probe passed into the carious ethmoid cells; much the same conditions as in a case reported by Dr. Arnold Knapp*, except that pus had not escaped into the orbit. The bleeding, which was free and very troublesome during the operation, concealed the nature and amount of the discharge, but it did not seem abundant. It had probably drained through the ethmoid and escaped in large part by the posterior nares. The carious bone was scraped with a sharp spoon, and, by means of a long slender fenestrated silver probe very much bent, a drainage tube was passed into the external wound, through the ethmoid cells, and out by the nose. The cavity was washed out daily with warm peroxide of hydrogen. At the end of a month the tube was drawn just within the external

* Archives of Ophthalmology, January, 1899.

wound and held in place by means of a silver wire anchored to the forehead by plaster. The tube, being cut off within the nasal fossa, was entirely out of sight and was worn with very slight inconvenience, while the wire held it securely in position and admitted of removing and renewing it if necessary. Three weeks later the tube was removed entirely and the patient was discharged with only a very minute fistula where the wire had passed, and the exophthalmos slowly diminishing. He reported in a month with the wound entirely closed and the scar perceptible only on close inspection. There was complete anæsthesia of parts supplied by the supraorbital nerve. A delicate silver wire offers very little obstruction to healing of the wound, but it would perhaps be better still to close the wound completely and pass the wire through the sound skin above it. This procedure, if adopted immediately after the operation, would secure prompt union and avoid the danger of a fistula, and at the same time allow thorough cleansing of the whole cavity, as the upper end of the tube remains just behind the closed wound.

An important consideration in operations upon the frontal sinus is the degree of disfigurement that they are likely to leave. The incision advocated by Jansen* and used in this case, along the edge of the orbit beneath the eyebrow, is practically invisible if immediate union is secured, but tamponing the cavity as he recommends prevents this. Probably in a large proportion of cases thorough curetting and more or less prolonged drainage and antiseptic irrigation will make it possible to dispense with the tampon.

A study of reported cases and discussions inclines me decidedly to prefer the upper inner angle of the orbit as the location for cutting through the bone, which is thinner in this position and more likely to be diseased. The sinus is easily opened in this way in the normal skull, and when distended by empyema it is still more accessible. Then, too, this method of operating enables one to reach the ethmoid cells, which are nearly always involved. When the supraorbital arch is attacked and the anterior wall of

* Archives of Ophthalmology, xxvii, 297.

the sinus removed, as advocated by Kuhnt,* a more or less disfiguring depression of the visible scar must necessarily result; unless the osteoplastic method of Czerny and Golvini is adopted. It is claimed for the latter that it may be resorted to harmlessly as an exploratory operation.

Careful refracting by the shadow test showed a hypermetropia of 2.50 in the right eye, while the left had a hypermetropia of 4.75. This anisometropia may of course have existed previously, though the patient is positive that there was no difference in the eyes, but the question suggests itself whether the hypermetropia might not have been diminished by pressure of the frontal sinus above and the antrum below.

BOSTON MEDICAL LIBRARY MAR 6 1903

LESIONS OF THE FRONTAL SINUS AND ANTERIOR ETHMOIDAL CELLS IN INFANCY AND OLD AGE.

BY ROBERT SATTLER, M.D.,

CINCINNATI, OHIO.

Lesions of the frontal sinus and adjacent cells of the ethmoidal labyrinth, in the two extremes of life — infancy and old age — are of interest not only because of the rarity of their occurrence, but also for the reason that noteworthy differences are observed so far as their course and clinical features are concerned. If the latter are carefully contrasted with similar, certainly more common, morbid processes during the intervening periods of life, this statement will be even more fully confirmed.

In very young subjects, the air spaces of the frontal bone are known to be rudimentary cavities, and in some cases an interspace only between the two layers of the bone marks the site of a future development. During early life these spaces gradually assume more roomy proportions. The adjacent anterior cells of the ethmoidal labyrinth, separated only by fragile partitions of bone from the air spaces of the frontal bone, with which they have such a close anatomical relationship, are also during infancy and

* Archives of Ophthalmology, xxvii, 297.

early youth imperfectly developed, but they have, even at these early periods of life, a more distinct existence than the air cavities of the frontal.

This probably explains why, before a more distinct development of these cavities and cells has taken place, sinus lesions are so uncommon. Nevertheless, it is probably also true (and this is supported by the clinical observations herewith mentioned) that such lesions are more common than has been generally supposed. An accurate or definite diagnosis of these lesions of the cells of the frontal and ethmoid bones is well nigh impossible in some cases; in others it is beset with the greatest difficulties, since the clinical evidences which are present suggest indefinitely only a lesion of the sinus. During the inception of such a lesion it may even be impossible to recognize its true character, because the general or constitutional symptoms rather suggest a cerebral or meningeal lesion, and overshadow, in severity and importance of expression, the local ones.

Owing to the small size of the air cavities affected, pyogenic or bacterial infection which has traveled along the ostium frontale, lights up a reaction of lesser severity on the part of the sinus cavities of the frontal bone. The larger development of the adjacent ethmoidal cells, the fragile partition walls separating these cavities, also the not infrequent anomalous communication with the middle fossa of the nose or with the frontal sinus itself, cause it to happen that a more marked declaration of the morbid changes enacted takes place here and the activity is withdrawn to the deeper recesses of this locality, attended, in most cases, by most uncertain and meager clinical symptoms.

An apt illustration is afforded by the recital of the following cases:

CASE I. *Child, 16 months: sudden choking of the right frontal sinus and adjacent ethmoidal cells. Pyogenic infection from nose or gastro-intestinal canal. Increasing proptosis; alarming symptoms. Recovery without operation.*

This patient, a girl aged 16 months, was the daughter of a fellow practitioner, who wrote me that she had been for some time

ill with a gastro-intestinal affection, and also with pronounced coryza, but that the diagnosis was by no means clear. Suddenly new symptoms had developed on the part of the right eye and orbit with great prostration and cachetic appearance, which led him to infer either the presence of cellulitis orbitæ or even malignant disease of the orbit. The child was seen by me on the following day. Asymmetry of the right side of the face with changed contour of the orbital margin, rigid infiltration and dusky discoloration of the inner half of the upper lid, great tenderness over the region of the sinus frontalis, pointed to a lesion of this cavity and the adjoining cells of the ethmoid.

Proptosis was most pronounced and the globe firmly crowded against the outer wall of the orbit. Movements of the eye were but little restricted. Fever was high, and tenderness over affected region was pronounced. Anterior rhinoscopy showed the presence of numerous herpes vesicles and incrustations over the swollen and reddened mucous membrane.

Preliminary to an exploratory operation, an expectant course was decided on, consisting of iced antiseptic compresses, spraying of the nose with alkaline antiseptic mixtures and, internally, small doses of calomel.

On the following day, the child's condition seemed more favorable, but the exophthalmos was more marked, as well as the other local symptoms. In passing the finger over the swollen region, this seemed to yield to the pressure, whereupon more forcible stroking was practiced. This manipulation was repeated, and it, or a spontaneous rupture into the nose, caused a disappearance of all the alarming symptoms without operation.

There was little room for any other conclusion than that this was a typical frontal sinus and ethmoidal labyrinth lesion, due to the transplantation of pyogenic or bacterial products from the nasal mucous membrane, or even from more remote sources of infection — the oral and gastro-intestinal lining — to these air cavities. Fortunately, discharge of the choked cavities came about along the natural channels into the nose. The close resemblance to malignant disease and cellulitis of the orbit, as

well as to meningeal or cerebral complications, are the features of interest and diagnostic importance.

CASE II. *Infant, aged 5½ months: chronic lesion of the right frontal sinus and ethmoidal cells with typical complex of symptoms, followed by periostosis and a general hyperostosis of the affected region. Two operations: recovery.*

Shortly after birth, the child suffering from blenorrhœa was brought to me. In due time, recovery without complication on the part of the cornea of either eye was brought about. There was no question concerning the venereal origin of the blenorrhœal infection of the eyes. Several weeks afterwards the child was again brought to me. The occasion of this visit was a swelling near the inner and upper margin of the orbit. There was some œdema of the upper lid, slight redness but no displacement of the eye. The child's general appearance and nutrition had been excellent and in no way suggested congenital lues.

During a short period of observation, proptosis (which, at this time, however, was transitory) manifested itself. More marked drooping and œdema of the upper lid were also noted. An exploratory operation was decided upon, but not until a thorough anti-specific course of treatment had been tried without favorable result.

A free incision through the soft parts disclosed only a serous infiltration of the overlying tissues. The periorbita was firmly adherent. No pus was found, but a roughened area of bone with distinct periostosis directly over the sinus frontalis region was discovered. The entire region was thoroughly curetted and the wound packed with gauze. It healed without special incident. At no time after the operation did the proptosis disappear, which we supposed was due to the infiltration of the adjacent cellular tissues of the orbit, and this dependent upon the existing periorbitis or caries. On the contrary, it, and in particular the lateral displacement of the globe, steadily increased.

Four weeks after the first operation a second operation was made, having for its purpose the thorough exploration of the frontal and adjacent sinuses.

The sinus frontalis, considering the age of the patient, was found quite roomy but empty. The anterior wall was much thickened and the posterior wall appeared pearly white. The temporal angle of the sinus was fully exposed, and here perforation had taken place, followed by the growth of the osteophite referred to in the account of the first operation. The ostium frontale was patulous. The entire sinus cavity appeared stripped of its mucous lining, and the inner wall or plate of the bone showed the same whiteness already referred to. It was evident that the morbid changes discovered did not explain the proptosis and lateral displacement of the globe. The adjacent ethmoidal cells were opened only to discover that there was no pus or other content, but the same pearly, almost chalky, appearance of the bony framework of the ethmoid was here also found. The cells were broken down and a free communication or opening was made with the nose. Recovery with subsidence of proptosis came about, as the accompanying photograph illustrates.

This case presents several interesting features: the early period of inception of the sinus lesion and its latent course; the absence of pus or other pyogenic products. The operation, furthermore, disclosed marked morbid changes on the part of the frontal and ethmoid bones. Venereal disease, although denied, could not be excluded on the part of the parents. Aside from defective nasal bones (marked but not excessive flattening), there was nothing in the history of the early months of its life which upheld a syphilitic origin. Nevertheless, the low grade and latent course of the bone lesion and the resulting hyperostosis may assign it to one of the vagaries of congenital syphilis.

It is a tenable inference that in this case micro-organisms or pyogenic products may have traveled from the nose into the frontal and ethmoidal air spaces and there started an insidious lesion which, after a comparatively long interval only, disclosed its real morbid nature. It is not improbable that the blenorrhœal lesion of the conjunctiva may have contributed a certain share towards its causation and excitation.

In the other extreme of life — old age — lesions of the air

spaces just referred to may give rise to symptoms which, because of their resemblance, might at first be considered the attendants of malignant disease. So close is the resemblance in some cases that this opinion is held until an exploratory operation or a spontaneous disappearance of the symptoms discloses the real nature of the morbid process and points out the error of diagnosis.

In old persons, the sinus cavities of the skull, especially the sinus frontalis, as the result of normal or physiological causes, reach enormous proportions as far as capacity and dimensions are concerned. The feature of excessive development may be accentuated if one or several of these spaces at any time — recent or remote — have been the seat of latent pathological invasions, or if an acute but wholly latent morbid process establishes itself. The roomy capacity prevents, in such cases, a more positive declaration and, owing to the thinning of the walls, perforation takes place at one or several points which offer a lesser resistance to the uniformly exerted pressure. Doubtless, also, trophic changes play a part in the perforation of the walls and the subsequent discharge of the grumous contents. The periorbita is extensively dissected and elevated except at the apex and around the orbital margin where the attachment is so much firmer. But even here, and especially at the temporal side of the orbit, dissection of the pericranium and burrowing of pus under the temporal fascia and malar arch, are not infrequently observed.

The symptoms, not characteristic but so generally associated with and strongly suggestive of sinus lesions, are: displacement — lateral and forward — of the globe; asymmetry of the upper part of the face on the affected side; drooping, swelling, and dusky discoloration of the inner one-third or one-half of the upper lid. Less commonly associated with these are pain and diplopia. The former is rarely a prominent symptom and the latter is often transitory. Disturbances of function are in most cases unimportant or absent. The feature, however, of interest, and one which two recent observations have again corroborated, is that spontaneous disappearance of the entire clinical complex of symptoms may take place.

The two cases referred to were observed at the Ophthalmic Hospital of Cincinnati, and I am indebted to Dr. Christen for the clinical reports.

The first patient was a man aged 64. He had marked proptosis with lateral displacement of the left eye. There was present a distinctly circumscribed, very hard, lobulated tumor, which could be felt occupying the inner wall, part of the roof and floor of the left orbit. The man was haggard in appearance, and, aside from numerous infirmities of senility, he had been in bad health for months. He complained of little or no pain. Diplopia was present, but because of the drooping upper lid gave rise to little or no annoyance. Rhinoscopic examination was negative, at least as far as gross abnormal findings were concerned, but there was a noticeable stenosis on the affected side and the usual attendants of chronic catarrhal disease.

An operation was proposed to explore thoroughly the seat and character of the lesion, to be followed by whatever surgical interference the special needs might direct. During the interval of several days only, between his visit to the hospital and the day appointed for the operation, there came about a sudden, spontaneous disappearance of all the symptoms, with prompt recession of the exophthalmos after this had been present for several years.

The second case was — as the accompanying photograph shows — equally pronounced. The man's age (70), his appearance, and the rapid course (6 to 8 months) rather suggested a malignant neoplasm. For months he had occasional diplopia and steadily increasing proptosis, but there was little or no pain. Even at his first appearance at the hospital, the asymmetry of the left side of the face and orbital opening was pronounced. The globe was dislocated forwards, outwards, and downwards. There was also an extensive deep-seated swelling occupying the temporal and infra-orbital regions, and this was connected with that which occupied the cavity of the orbit. Exploratory puncture with aspirator needle failed to discover fluid. Rhinoscopic examination was negative, and the clinical features so commonly associated with the declaration of malignant disease of the bony

framework of the orbit, all appeared to be present. An unfavorable prognosis was given and, because of the extensive involvement of the tissues within and adjacent to the orbit, surgical intervention was not at once resorted to.

During the following months he was kept under observation, and it was noted that suddenly a marked improvement came about, the exophthalmos receded and the extensive swelling disappeared.

In both cases, extensive osseous perforation due to erosion or pressure absorption, with extensive dissection of the periorbita, must have taken place. The ethmoidal cells were probably the principal starting places of the lesion, and spontaneous relief was effected at a subsequent period by similar osseous perforation, affording partial exit at least of the contents of the choked up cells into the nose.

Another expression of a sinus frontalis lesion, but in which the adjacent ethmoidal cells are not necessarily involved, corresponds in many of its features with a similar one of the mastoid cells — Bezold's mastoiditis. Clinically and pathologically, the two lesions have much in common.

Both are eminently chronic. Almost without exception, during the early stages, their course is wholly latent. The real character of the morbid changes is not disclosed until multiple osseous perforation with extrusion of the contents of the distended air spaces under the periorbita has taken place. This is followed by deep burrowing and the appearance of fistulous openings at remote points from the original seat of the lesion.

It may also happen that external fistulæ do not make their appearance at all, but the ropy contents of the air cavities are forced through the bone perforation under the periorbita into the adjacent deeper tissues of the orbit, or even find their way under the tear sac into the maxillary antrum, and more frequently even into the nose.

The accompanying brief history and photograph of a case illustrate the principle features of a left frontal sinus lesion belonging to this category.

H. S., Swiss, aged 64, stated on admission to the Ophthalmic

Hospital that, with the exception of an attack of typhoid fever, he had enjoyed excellent health. At the age of 32 he had an offensive discharge from the nose, which, after several weeks, however, disappeared completely. Venereal disease was denied. Nine years after this attack of supposed acute coryza, he began to suffer from severe headaches, with swelling of the lower part of the forehead. This was almost inflammatory in character and was mistaken for erysipelas. The paroxysms, at first interrupted and of shorter duration, became more severe and constant until a spontaneous fistulous opening, one-half inch above the inner canthus, came about. This opening continued to discharge a thick, brownish, stringy fluid until the end of the year 1898, at which time it closed. From this time, exophthalmos, which had long been present, as well as diplopia, became more pronounced, but vision was unimpaired. The asymmetry of the left side of the face became more and more marked. The constant suffering, the steady increase of the lobulated tumor (which occupied the region of the inner canthus and encroached so much upon the lumen of the orbit that the globe was displaced forwards and outwards), made surgical intervention imperative.

The affected region was exposed for inspection and exploration. It disclosed a frontal sinus of enormous proportions. The periorbita had been detached and a large cavity which extended to the extreme apex of the orbit was filled with caseated pus, débris, and opalescent, ropy mucus. The outer lower wall was excessively thickened and the lateral or orbital partition wall was the seat of numerous perforations. The orbital plate of the frontal was so thinned that the dura was exposed over a large area. The ostium frontale was firmly closed.

The adjacent ethmoidal cells were carefully exposed, but were not found implicated. The anterior cells and those near the floor of the frontal sinus were opened and a free communication established with the middle fossa of the nose.

The subsequent course was tedious, but recovery with little deformity and the cessation of constant suffering was brought about.

FIG. 1.

FIG. 2.

BRIEF REPORT OF POST MORTEM EXAMINATION, WITH SPECIMENS, OF A CASE OF LEONTIASIS OSSEA IN WHICH OCULAR SYMPTOMS WERE PRESENT.

DR. ROBERT SATTLER, CINCINNATI, O.

Leontiasis ossea is of interest to us as specialists, for the reason that ocular symptoms are commonly observed, at one time or another, during the long course of this mysterious overgrowth of the bones of the skull.

To the information gained from a clinical study of a typical case, and its relentless progress, an opportunity was afforded to add the disclosures of the necropsy.

Interest, of course, centers around the question whether, in these cases of Leontiasis, morbid changes of the pituitary gland are present, such as are quite uniformly met with in typical cases of giantism of the extremities or acromegaly.

At the time of her death, the patient had just completed her twentieth year. The lesion began, as nearly as can be determined, at the age of 11; at least, at or about this time, her increasing ugliness and the coarseness of her facial expression were forced upon her own and her parents' attention.

The upper face region on the left side appears to have been the starting point of the lesion. Ocular symptoms (epiphora, stricture of the left nasal duct) were present at its inception. At the age of 15, proptosis of both eyes — but more marked on the part of the left — was noticed. This increased steadily but slowly. At 19, optic atrophy was added. It advanced slowly in the right, but more rapidly in the left eye.

Until she was suddenly attacked with the complication which resulted in her death, she appeared to be in her customary state of health of body and mind. She was active and cheerful.

The attack which resulted in death came on with intense pain in the occipital region, followed by general convulsive seizures and coma.

Mention will only be made of the more important disclosures of the necropsy:

The calvarium, owing to the thickness of the bone, was re-

moved with difficulty. The brain was much compressed and the superficial veins prominent and varicose. The body of the sphenoid had undergone great rarefaction. The sella turcica was very deep. The pituitary gland was much enlarged, but presented no gross lesion.

The section of the skull through the frontal and orbital regions affords a better conception of the excessive overgrowth of the bony framework of the skull than any attempts at description.

The orbital plate of the frontal bone on both sides was much thickened. The left frontal sinus was completely occluded, and the ethmoidal labyrinth was also in part solidly filled up. The sphenoidal sinus was much contracted.

The optic foramina were not contracted, nor were the other openings which gave exit to important nerves or blood vessels.

The immediate cause of death was an extensive hemorrhage occupying the base of the brain, anterior to the basilar process, the body of the sphenoid, and extending into the middle fossæ on each side.

FRONTAL HEADACHES, APPARENTLY OCULAR, BUT REALLY OF NASAL ORIGIN; THEIR RECOGNITION AND TREATMENT.

By ARTHUR E. EWING, M.D.,

St. Louis, Mo.

ON THE NASAL CONDITIONS FOUND IN THESE CASES; WITH ESPECIAL REFERENCE TO AN ABNORMAL RELATION OF THE UNCINATE PROCESS OF THE ETHMOID TO THE BULLA OF THE ETHMOID.

By GREENFIELD SLUDER, M.D.,

St. Louis, Mo.

(By invitation of the Society.)

For a number of years a form of eye trouble has interested me for which I never could find any rational explanation until I myself was a temporary victim. This experience occurred during an

attack of grippe in 1892. For three days there was intense neuralgia over the right frontal region, through the right eye, and in the right malar bone. Any attempt to read would excite such acute pain through the right eye that reading was out of the question. There was tenderness and soreness on pressure upon the malar bone, the eyebrow, the eyeball, and particularly the upper-inner wall of the orbit in the region of the pulley of the superior oblique muscle, where the sensitiveness was comparable to that evoked by pressure upon a boil. On the left side and in the left eye, none of these symptoms were present.

After the fourth or fifth day there was a profuse purulent discharge from the right nostril, which continued for two or three weeks. With the appearance of this discharge the acute pain ceased, the soreness gradually disappeared, and I was apparently well. For many months, however, the right eye would frequently ache, and whenever this was the case a little tenderness was always present in the ethmoidal and frontal region of the right orbit, but none in the corresponding region of the left orbit.

The grippe recurred annually, each year in a milder form, for four years, always accompanied by tenderness of the upper-inner orbital wall and aching of the eye, but without soreness of the globe, or over the frontal or malar bone; there was never any pain in the left eye, or any tenderness about the left orbit.

This experience led me to a special investigation of other cases of persistent headache supposed to be of ophthalmic origin, but in which treatment directed to the eyes seemed to benefit only temporarily. In many instances the same tenderness on pressure was found, but after referring the cases to a rhinological expert for examination I was generally informed that no evidence of nasal trouble could be detected. Only later, after Dr. Sluder had become interested with me in this subject, have our joint efforts led to positive results.

In the description of my own case I have outlined the symptoms of an acute form of frontal or ethmoidal trouble, such as not infrequently ends in frontal or orbital abscess with persistent fistula. In the two or three cases that have come under my ob-

servation, in which such fistula existed, the tenderness on pressure was absent. This is doubtless due to the existence of a free opening, just as the pain and tenderness ceased with me when the swelling in the nose had subsided, with the discharge of the retained secretions into the nostril. In such acute cases the nasal symptoms are generally so marked that error of diagnosis is quite impossible. But in the later stages of the nasal affection, after all the acute symptoms have subsided, the orbital tenderness may persist as almost the only remaining sign of the previous acute affection. The same symptom is found also in cases in which no history of an acute attack can be brought to light, and it is from the aching, which is rendered worse by the use of the eyes, that the patient is induced to consult the oculist. The usual complaint is of inability to do near work without severe pain through the eyes and forehead, and with this there is often continuous dull frontal headache, generally worse on rising in the morning. Not infrequently this pain is in and over one eye only. If the trouble is severe, there may be marked conjunctival hyperæmia, and in nearly every case there is more or less conjunctival irritation. Treatment of the conjunctiva alleviates the feeling of irritation, and the correction of an incidental refractive error will often diminish the aching through the eyes. Under such tentative treatment the trouble may entirely disappear, but only to re-appear when the patient again takes cold, or on the next change in the weather. General treatment is of little value.

The focal point of the trouble is really in the nasal cavity or its accessory ethmoidal or frontal cells. The diagnosis is established by making moderate pressure against the inner and upper-inner wall of the orbit, namely, the orbital plate of the frontal bone in its nasal half, the os planum of the ethmoid, and particularly in the neighborhood of the pulley of the superior oblique muscle. If abnormal tenderness is present, and especially if the tenderness is greater in one orbit than in the other, it is an evidence of the existence of nasal trouble. Of course, too firm pressure will cause pain in the nasal or ethmoidal branches of the fifth nerve, and if made higher up on the forehead it will cause pain in the supra-

orbital nerve. The pain in question is, however, not that of pressure upon a normal nerve, but is rather a feeling of soreness and tenderness, as on pressing upon a boil.

A routine examination of the nares may fail to reveal anything abnormal. In the most typical case that has thus far come under my observation, two rhinological examinations were made, several months apart and by two different practitioners, and in both instances the nasal cavities were pronounced normal. The patient had been also under the care, at different times, of two of our best general practitioners, but without material improvement. For many years the patient had been under the almost constant care of different ophthalmic practitioners, one of whom was said to have divided both the recti externi. In the right eye there was hypermetropic astigmatism of 1.25 D, with the rule, and in the left eye there was mixed astigmatism, mainly hypermetropic, of 2. D, also with the rule. There had been frequent attacks of conjunctival redness and irritation. Often, for many weeks at a time, it was impossible to read for even a minute or two without bringing on severe pain in the forehead and eyes, and never more than an hour a day in the aggregate, using the eyes five or ten minutes at a time. After the first operation on one of the externi, there appeared to be a little improvement, but after the second operation, performed six weeks later on the other externus, both the frontal pain and the inability to use the eyes were greatly increased. Relief was next sought in a distant city, and later in another; in these efforts, during a period of three years, eight different ophthalmic practitioners had been consulted, three of whom besides myself are members of this society. Various changes had been made in the glasses, to no purpose, and direct treatment of the irritated or inflamed conjunctiva had been persistently tried without affording more than temporary relief. The tenderness at the roof of the orbit, and particularly at the site of the pulley of the superior oblique, was very great on both sides. Guided by this symptom, I prevailed on the patient to submit to a course of treatment on the nasal cavities. The effect was prompt and pronounced; the conjunctival attacks became less frequent, as also

the headaches, and the eyes could be used longer and with greater ease. Although there are still occasional slight relapses, for more than a year the patient has been able to use the eyes easily from three to five hours a day, and there has been almost no headache.

Another quite typical case presented a moderate grade of myopic astigmatism with the rule, which had never been corrected. It was stated that there had not been a night's rest for three months, and many nights the patient had been compelled by the pain to walk the floor. The correction of the refraction gave practically no relief. The orbital tenderness was very marked. A rhinologist of excellent reputation, who was consulted by my advice, gave it as his opinion that unless the trouble came from the eyes the patient was a subject for the general practitioner. Before acting upon this advice I sent the patient to Dr. Sluder for his examination and if possible for treatment, with the result that within three days the pain had entirely ceased. This was a year ago, and there has been no return of the trouble.

In another case I was for a long time deceived, the tenderness not being sufficiently marked to be regarded by me as decisive. When the patient first came to me there was marginal blepharitis complicated with conjunctivitis, also hypermetropia with astigmatism. The eyes had been inflamed from time to time for several years, and at times there was a good deal of headache. With correction of the refraction and care of the lids, the inflammation in the main disappeared, and the headaches were greatly lessened, but there was always inability to use the eyes by artificial light. The relapses of conjunctivitis were also frequent. Afterwards the headaches became more frequent, and were made worse by any use of the eyes in near work. As the subject was a teacher, some use of the eyes was imperative. There was some weakness of the interni which I corrected with prisms, to be worn in near work in addition to the spectacles which corrected the refractive error. For a time these served fairly well, with periods every two or three weeks during which the eyes could not be used even with this aid. The headaches gradually became more frequent, and were finally almost constant.

Eventually, when I had almost concluded that my patient was a confirmed neurotic, I detected during a slight exacerbation of the conjunctivitis a positive tenderness in one orbit. A rhinological examination by Dr. Sluder revealed closure of the frontal sinus. Under appropriate treatment for this condition the headaches and the conjunctivitis have entirely disappeared, the prisms have been discarded, and the eyes are used freely day and night.

Neuralgia of the nasal or ethmoidal nerves may play a principal part in some of these cases. Of this I had evidence last fall in a patient with relapsing subacute follicular conjunctivitis of several months' duration. During an exacerbation there was complaint of intense frontal headache and tenderness above the left eyebrow. There was no tenderness about the orbit except over the supra-orbital foramen and along the course of the nerve upon the forehead. An examination of the nose showed moderate follicular swelling of the nasal mucous membrane. After two days' treatment of the nasal passages the frontal neuralgia disappeared, and the inflammation in the eyelids was notably less; the condition of the conjunctiva rapidly and steadily improved, and there has since been only one, and that a slight relapse. Whether the neuralgia of the frontal was dependent upon the condition of the nasal mucous membrane and the conjunctival trouble combined, or upon some general condition underlying these, I do not know. The case is mentioned as a possible parallel to what might exist in some of the cases under discussion, the course of the ethmoidal and nasal nerves not being so easily determined and followed as that of the supra-orbital.

Of cases with tenderness in the inner and upper angle of the orbit, I have many that I might mention, for they are not at all infrequent, but they are all practically the same so far as concerns the ophthalmologist, as he has but the one sign for his guide. The nasal treatment I have left entirely to Dr. Sluder, who has kindly consented to discuss the probable causes for this sign, and to give the results of his experience in treating the conditions that give rise to it.

A. E. EWING.

Dr. Ewing has described a symptom that I have found to be directly dependent upon four classes of nasal conditions.

(1) Neuralgia of the ethmoidal or frontal nerves, branches of the fifth.

(2) Empyema of the frontal or ethmoidal sinuses.

(3) Mucocele of these sinuses.

(4) A probable closure of either or both of these sinuses from chronic catarrhal inflammation about their openings, or from some other cause, so that the air pressure within them is changed.

The first of these conditions I do not think occurs independently; but believe it is an accompaniment of neuralgia of other branches of the fifth.

The relationship between empyema of the frontal and ethmoidal sinuses and eye disturbances has been recognized for some time, and much has been written about it. I therefore mention it merely, without attempting to go into any detailed consideration of these conditions.

Mucocele of the frontal and ethmoidal sinuses has likewise been recognized, and correctly described.

The fourth and last-mentioned condition, so far as I know, has not hitherto been described. To this class of cases my attention was first called by Dr. Ewing in 1895. These cases are characterized uniformly by tenderness of that part of the orbit which is made up of the frontal sinus, namely, the upper and inner part, as already described by Dr. Ewing. Without exception the patients complain of a dull, heavy headache. This headache is usually constant, with more or less severe exacerbations; it is generally worse in the morning. The patients generally complain of inability to use the eyes for any close work, and some complain of distinctly recognizable pain upon movement of the eyes from side to side or up and down. Dr. Ewing assured me that many of these patients had almost no intrinsic eye trouble. In other cases there were more or less pronounced errors of refraction. I have since found similar cases altogether without eye disturbances. Some of the patients show changes of one kind or another in the nose, such as a slight swelling or hypertrophy of the membrane

of the middle turbinate. Others show seemingly normal noses, and none present nose symptoms. As a rule, none of the cases show changes in the nose sufficiently pronounced to account for the headache.

In December, 1897, while studying some anatomical specimens, I thought I discovered a possible explanation for these cases, but so hidden as to be impossible of recognition by the ordinary examination of the nose. This cause I think I have found in the relation of the uncinate process of the ethmoid to the bulla of the ethmoid, and in the relation of the middle turbinate to both. Under normal conditions the uncinate process is separated from the bulla by a space of about two millimeters. The turbinate should stand free from the lateral wall, that is, not lapped down upon it. If the bulla and uncinate are more closely approximated than two millimeters, a moderate congestion or inflammation may cause it to swell sufficiently to close the infundibulum. There can be no reasonable doubt that the effect of closure of the infundibulum will be to alter the air pressure in the frontal cavity sufficient to produce discomfort varying from heaviness to dull pain localized sharply to the frontal region. This is so in the closure of the Eustachian tube, and there is no reason why a like condition should not produce a like effect here. I have long believed this condition to be the explanation of this sign. A few days ago I found that a similar view regarding acute cases is held by Professor Killian, *Heyman's Handbuch der Rhinologie und Laryngologie, Lieferung* 35, just published.

This class of cases is always free from suppuration and polyps, and is in no way connected with empyema of the frontal or ethmoidal cavities. One never sees the least trace of abnormal moisture in the nose except when there may be an accompanying coryza. I have seen cases that had persisted for periods varying from three months to fifteen years, those of less than three months rarely coming into the hands of the rhinologist. The patient, having no nose symptoms whatever, is referred to the ophthalmologist by the general practitioner, or seeks his aid independently,

knowing that many apparently similar cases are referable to the eyes and are cured by eye treatment.

The infundibulum may be closed by the juxtaposition of the bulla to the uncinate process, or by hypertrophy of the middle turbinate blocking the meatus, or by the anterior tip of the middle turbinate being so placed as to correspond with the hiatus semilunaris, being at the same time lapped close to the lateral wall of the nose. Dr. Hajek once showed me a specimen in which the frontal cavity was closed by a tumor-like swelling which sprang forward from the bulla. A drawing of this specimen he publishes in his *Krankheiten der Nebenhoelen der Nase*, p. 35. This specimen, I believe, was obtained from the Anatomical Institute of the University of Vienna, and was without history as to whether the man suffered in the eyes or from headache during life. He also showed me several specimens in which the middle turbinate was lapped close upon the lateral wall of the nose; and I myself have such specimens, without history, obtained from the dissecting room.

The pain and tenderness on pressure is due, as I believe, to a disturbance of the air pressure in the sinuses, which disturbance of pressure is responsible for the varying but almost constant discomfort. This discomfort, however, never reaches the degree of suffering occurring in a confined empyema or mucocele. These conditions may, however, be transformed into mucoceles by acute coryzas, and the history of these cases, almost without exception, is that a coryza intensifies the suffering. The general health of the patient is never affected apart from the nervousness and irritability which the constant discomfort produces. They never yield to treatment for headache *per se*, that is, to so-called headache powders containing one or more of the coal tar products.

I have had no opportunity to make post mortem examinations in these cases, but the anatomy may be made out distinctly upon the living. I have sometimes found that the obstruction to the frontal sinus was caused by the anterior tip of the middle turbinate being tucked in, as it were, into the hiatus semilunaris. I have also found a small degree of hypertrophy of the soft tissues, and

FIG. I.

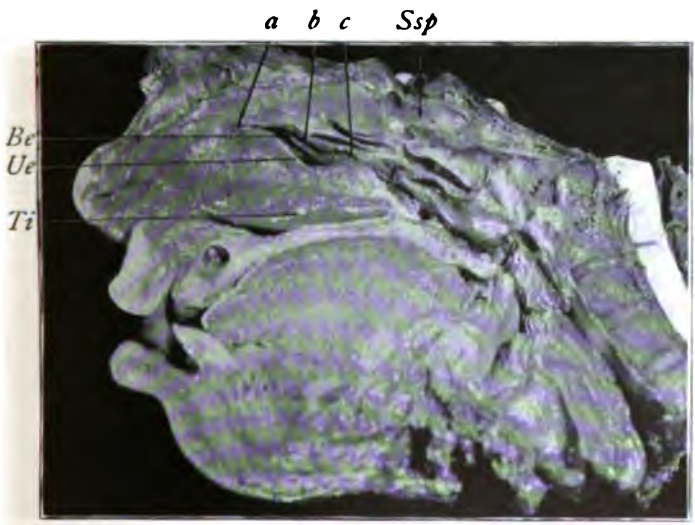

FIG. II.

a b c d*—*Line of amputation of middle turbinate.* *b*—*A cell of the ethmoid opened in the amputation of the turbinate.* *Be*—*Bulla of the ethmoid.* (*Fig. I. Bulla normal; Fig. II. Bulla very small.*) *Ue*—*Uncinate process of the ethmoid.* *p*—*A probe, 1 mm. in diameter, passing through the hiatus semilunaris and infundibulum into the frontal sinus.* *Sfr*—*Frontal sinus.* *Sap*—*Sphenoidal sinus.* *Oe*—*Orifice of the Eustachian tube.* *Ti*—*Inferior turbinate.

the anterior tip of the middle turbinate forced into the hiatus semilunaris by a deflection or bulging of the septum just opposite the tip. At other times I have found the bulla of the ethmoid large and projected forward. Under such circumstances both the uncinate process and the hiatus assumed a more nearly vertical direction and were nearer the anterior tip of the middle turbinate than normal. This condition can be made out by a probe bent so as to slip under the middle turbinate and take the direction of the hiatus. The breadth of the hiatus may sometimes be made out in this way. I have found also the bulla so large as to prop the middle turbinate inward, that is to say, raise it from the lateral wall to such an extent that the condition of the membrane upon the bulla and the uncinate could be inspected directly; a probe introduced to determine the caliber of the hiatus found no opening, inasmuch as the membrane of the bulla jutted forward against the uncinate process. I have an anatomical specimen showing the bulla rather small and receding backwards, the uncinate process also taking the same direction, being rather closely applied to it so as to cover it very much as does the middle turbinate; the bulla then being covered by both the uncinate process and the middle turbinate, both being lapped so tight and so close as to leave scarcely any room even in the anatomical specimen, with its membrane completely shrunken down upon the bone. This specimen was obtained from the dissecting room of the St. Louis Medical College, without history. I have also found the bulla of the ethmoid jutting so far forward as to render the direction of the uncinate process almost vertical, the hiatus being obliterated. Again I have found the bulla small and receding backwards, with the uncinate process lying close upon it, likewise obliterating the hiatus; in another case I have found the bulla large, extending backwards and upwards, fitting in closely under the middle turbinate in such a way as to close the opening to the ethmoid.

The only part that can be submitted to histological examination is the middle turbinate which is removed in these cases. A number of these turbinates, which have been examined by myself and by Dr. Theodore Kodis, have shown changes in the mucous

membrane in the way of round-celled infiltration about the glands and proliferation of connective tissue in some parts. One case showed hypertrophy of the basilar membrane, with slight atrophy of the epithelial covering. Another showed periostitis with atrophy of the bony lamella. If the changes in the membrane corresponding to these are present also in that part of the middle meatus bounded by the uncinate and the bulla, it may be readily understood how, in the case of a naturally very narrow hiatus or infundibulum, such changes, even though slight in degree, may be sufficient to close the cavities.

The diagnosis in these cases is sometimes extremely difficult. The one constant, trustworthy sign, irrespective of all others, is the soreness and tenderness to pressure in that part of the orbit corresponding to the walls of the frontal sinus. This symptom is described by Dr. Ewing in the *St. Louis Courier of Medicine*, Vol. 21, No. 5, November, 1899. This sign has been found by me in cases which did not present eye trouble, as well as in a great number in which a variety of eye symptoms were present. In the cases where no eye trouble was present I have found this tenderness by examining particularly for it. In many of the cases presenting this sign an examination of the nose showed something more or less definite. Other cases showed nothing upon examination of the nose, *but presented constantly, month after month, typical orbital tenderness and remained helpless in the use of their eyes;* under such conditions I felt justified in removing enough of the middle turbinate to permit an inspection of the middle meatus, the uncinate process, the hiatus semilunaris, and the bulla of the ethmoid. In these cases I have found without exception that in one way or another the outlet of the infundibulum, that is, the hiatus semilunaris, was obstructed.

The treatment of these cases has been based upon the theory that they were cases of occluded sinuses, and the effort has been to establish free connection with the general nasal cavity. In the more recent cases, of three months' to a year's standing, astringent applications made under the middle turbinate have often cured the trouble by merely shrinking the membrane. Shrinking the mem-

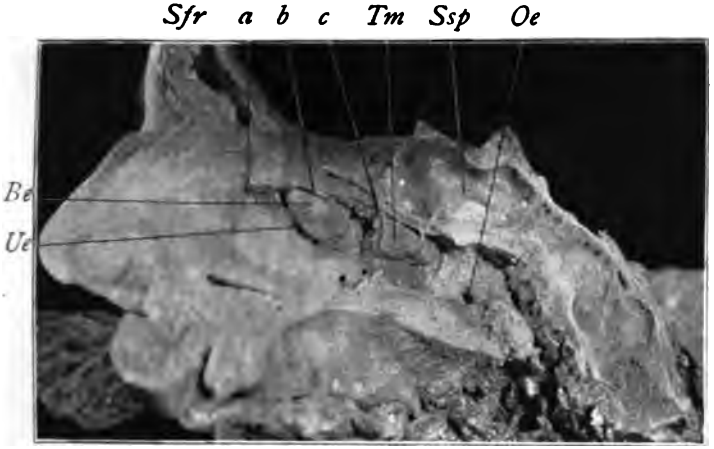

FIG. III.

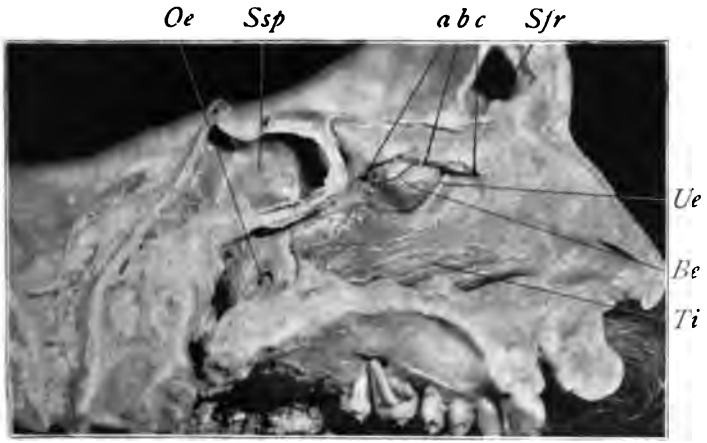

FIG. IV.

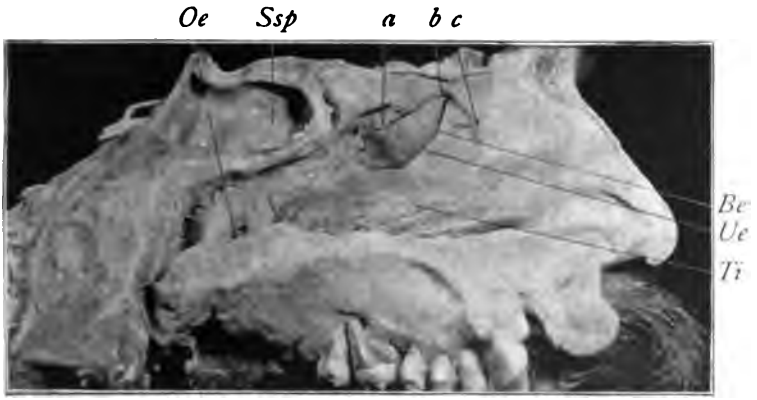

FIG. V.

a b c — Line of amputation of middle turbinate. Be — Bulla of ethmoid. (Fig. III. Large bulla, narrow hiatus semilunaris and infundibulum; Figs. IV. and V. very large bulla, which occludes the hiatus semilunaris and infundibulum.) Ue — Uncinate process of the ethmoid. Tm — Middle turbinate, posterior third. Ssp — Sphenoidal sinus. Oe — Orifice of the Eustachian tube. Sfr — Frontal sinus. Ti — Inferior turbinate.

EXPLANATION OF PLATES.

Figures I to V are half-tone reproductions of untouched photographs taken from median sections of decalcified heads.

Fig. I. Female, age *ca* 35 years; Vienna. Left lateral wall of nose. This is believed to be in every way a normal specimen.

Fig. II. Female, age *ca* 40 years; Vienna. Right lateral wall of nose. This specimen shows *a small bulla ethmoidalis, with a wide hiatus semilunaris and infundibulum.*

Fig. III. Male, age *ca* 40 years; St. Louis. Right lateral wall of nose. This specimen shows *a large bulla ethmoidalis, with a narrow hiatus semilunaris and infundibulum.*

Fig. IV. Left half of head represented in Fig. III. This specimen shows *a very large bulla ethmoidalis which occludes the hiatus semilunaris and infundibulum by extending forwards, and occludes the ostium ethmoidalis by extending upwards and backwards, fitting tightly under the middle turbinate.*

Fig. V. Same as Fig. IV, but with the stump of the middle turbinate removed, showing *the bulla of the ethmoid extending forward to plug the hiatus semilunaris and infundibulum to within about 2 mm. of the cribriform plate of the ethmoid.* This specimen admits only a fine bristle into the frontal sinus.

brane of the middle meatus with cocaine and supra-renal extract relieves much of the headache, especially when the occlusion is not bony. These applications are always given a trial. When they fail, it becomes necessary to operate. Where the hiatus is closed by the turbinate being tucked into it, or by an hypertrophy, the hiatus itself being of sufficient breadth, simple removal of the anterior third of the turbinate suffices to effect a cure. Where the ethmoid has been closed by the turbinate being lapped over the bulla in such a fashion that the opening to the ethmoid was closed, removal of enough of the turbinate to free this opening has cured the trouble. Where the bulla and uncinate process were found in close contact with each other, the uncinate process was removed well up into the nose, almost to the level of the cribriform plate, thus establishing a free opening to the frontal cavity through its infundibulum. Removal of the middle turbinate is rarely, if ever, accompanied by any great danger, but removal of the uncinate process, it seems to me, is an operation by no means devoid of danger. I think it can readily be understood how the cribriform plate might be injured and how an infected wound might set up a meningitis. It also seems to me very easy to fracture through the ethmoid, including its paper plate, with the possibility of setting up an orbital abscess. It has so far been my fortune to relieve these cases by intranasal operation. I can understand how, under some conditions, external operation may be necessary, but I believe this to be extremely rare. In the cases in which I have operated, as soon as I have succeeded in establishing a free opening into the sinuses, the headache and orbital tenderness have disappeared, and the patients have been able to again use the eyes freely and comfortably.

G. SLUDER.

DISPLACEMENTS OF THE EYEBALL BY DISEASE OF THE FRONTAL AND ETHMOID SINUSES. TWO CASES.

BY S. D. RISLEY, A.M., M.D.,

PHILADELPHIA, PENN.

The following cases of displacement of the eyeball seem of sufficient interest to place on record in the annals of this society, since in neither case did the signs of disease permit a correct diagnosis as to its real nature.

CASE I. *Exostosis of the orbital rim, cyst of the lachrymal sac. Distension of the ethmoid cells, Lateral displacement of the eye, choked disc.*

A lad, aged 11 years, came to the Wills Eye Hospital, April 28, 1899, suffering from lachrymal retention and double vision. O. D. V. = 6/VI. O. S. 3/LX. The left eye exhibited no exophthalmos, but was displaced outward and slightly downward. The movements of the ball were normal except to convergence. The ophthalmoscope showed the characteristic appearances of choked disc without hemorrhages. The boy was in good health. There was a hard bony tumor in the region of the lachrymal sac extending from a point 5 mm. to the nasal side of the supra-orbital notch to a corresponding point on the infra-orbital ridge, skirting in a semicircle the bridge of the nose. It was notched in its central portion and through this notch projected a tense, cyst-like tumor. The exostosis was very hard and unyielding, and seemed, so far as could be determined by palpation, to project backward along the nasal aspect of the orbital walls. No light was thrown

upon its extent or character by study of the nose or pharynx. The tear duct had been treated by Bowman's method, without relief, by a surgeon near his home in the interior of the state. A probe and fluids passed readily through the lachrymal duct into the nose.

The condition described had been first noticed three years before and the tumor has slowly increased in size. The cyst-like tumor in the region of the lachrymal sac was subject to great variation in size, at times suddenly disappearing, only to slowly recur. After consultation with my colleague, Dr. George C. Harlan, and assisted by him and the hospital internes, operation for relief was undertaken. A semicircular incision, outlining the outer rim of the exostosis, was made through the soft tissues and periosteum and these carefully dissected and turned back over the eye, exposing the exostosis and cystic tumor. This last proved to be the thinned and distended lachrymal sac, which readily ruptured and was found filled with a glairy muco-purulent contents. The walls were capacious and smooth, and from the bottom of the cavity thus exposed a large Bowman's probe passed readily into the nose. It was found that the exostosis was a dense rim of bone roofing in this cavity and gradually merging backward to the normal plane of the nasal bone and the nasal aspects of the superior and inferior orbital walls. As this could not account for the displacement of the eye, the finger was carried backward into the orbit, where it was discovered that the ethmoid cells were distended and that this portion of the orbital wall was very irregular and encroaching upon the orbit. The exostosis was cut away and an opening made through into the ethmoidal cells. A profuse glairy discharge of a lead-colored contents was removed and the inner orbital wall forced back into place. After thorough cleansing, drainage tubes were passed into the nose through the ethmoid cells and nasal duct, and the soft parts replaced.

Recovery was rapid and without reaction. The deformity was corrected, and binocular vision secured. A lead style was worn for several weeks in the nasal duct, but this was then removed and but little annoyance from lachrymal retention remained when he returned to his home. Two years before the appearance of the

tumor the boy had received a severe blow on the bridge of the nose, which was regarded by the parents as the cause of the trouble.

CASE II. *Marked Exophthalmos Apparently due to Malignant Disease of the Orbit.—Cyst of the Frontal and Ethmoidal Sinuses.*

Mrs. L. T., a mulatto woman, aged 52, in good health, came to the Wills Hospital, April 13, 1896, with marked displacement of the left eyeball. The exophthalmos was so great that the upper lid could be closed over the ball only by the aid of her fingers, and could readily be caused to slip back of the ball, producing complete dislocation. There was also well-marked downward and inward displacement — V = 6/XV. The fundus was healthy. The movement of the ball upward was impeded but was quite free in other directions. There was no bruit or aneurismal thrill; pain was not a marked symptom, although at times she suffered from occipital headache and hemicrania. The exophthalmos could not be diminished by firm pressure. The deformity began in 1891, three years before, and had slowly increased. There was no known cause — no history of injury. Palpation revealed a prolapsed lachrymal gland and a firm nodular mass occupying the upper and outer two-thirds of the orbit, only slightly tender to firm pressure. The physical properties of the mass, together with its history of steady increase in size, seemed to suggest a neoplasm, probably mildly malignant in type. After consultation with my colleagues, operation was deferred and she was placed on rapidly ascending doses of iodide of potassium, which were increased to eighty grains three times daily. Under this treatment and her protected life and regular regimen in the hospital she became much more comfortable, the exophthalmos diminished, the orbital mass was smaller, and the upward excursion of the ball was greatly increased. V = 6/XII. The dose of the potassium iodide was now diminished and she was allowed to return to her home in Virginia because of the severe illness of a member of her family.

She was not seen again until January 29, 1900 — four years after her first visit to the hospital, and nine years after the first appearance of disease. She then returned in much impaired health, to all appearances the subject of some cachexia, but had taken the potassium iodide with but little intermission, and without professional advice. The displacement of the ball, now directly downward, had greatly increased, so that the upper surface of the eye was on a level with the lower surface of its fellow. The exophthalmos was even greater than in 1896, so that the lids could be closed over the ball by the aid of the fingers with difficulty. Vision had sunk to 2/LX, but the fundus presented no gross lesion. The movements of the ball in all directions were singularly free and extensive. The physical properties of the orbital mass had not materially changed, but it had increased in extent, especially toward the nose.

After consultation with my colleagues at the hospital, operation for the removal of the mass, and possibly of the eyeball and exenteration of the orbit, was undertaken. Assisted by Dr. George C. Harlan and the hospital internes, I made a free incision outward at the external canthus, and, passing a suture through the upper eyelid, turned it strongly upward on the brow, and fastened it there by adhesive plaster. The free movement of the eye seemed to show that the neoplasm, if any, was outside the cone of muscles. A horn spatula was therefore so placed as to protect the muscles and tissues immediately around the ball, and an attempt made to dissect out the mass. Cutting through the conjunctiva and orbital fat, I soon came upon a firm nodular mass, dark bluish green in color, but presenting none of the appearances of a cyst. Efforts at dissection, however, soon led to a rupture of its surface, and the evacuation of profuse quantities of dark lead-colored glairy contents without odor. Exploration with the finger revealed a large opening with ragged bony edges in the floor of the frontal sinus, through a probe passed freely into the frontal sinus on the opposite side, and its withdrawal was followed by an additional quantity of glairy discharge. Carrying the finger back into the orbit revealed a plate of bone, apparently the wall of the eth-

moid cells and a part of the floor of the frontal sinus lying in a diagonal position extending downward and backward, and forming the anterior inferior wall of the cyst, and which had caused the forward and downward displacement of the eye. A part of this bony wall was found detached and partially necrosed, and was therefore removed. The remainder was pressed back to its normal plane and allowed to remain. An opening was made into the frontal sinus above the bridge of the nose and carried downward into the ethmoid cells, and a drainage tube inserted and carried out through the nostril. The displacement of the ball at once disappeared, and after a few days vision rose to 6/XV, but the upper lid was greatly stretched and could be raised only by the aid of the fingers, and so remains. There is still abundant muco-purulent discharge from the frontal sinus, notwithstanding daily cleansing through the drainage tube. The eye itself is healthy and vision $=6/XII$. It is probable that further surgical interference will be required to correct the ptosis and possibly for the permanent relief of the discharge from the frontal sinus.

The points of especial interest are the long duration of the disease without permanent injury to the eye, and the simulation in all other respects of an orbital neoplasm. Notwithstanding the most careful study of the nasal passages and illumination of the sinuses by the electric lamp, the true nature of the affection was not suspected until revealed by operation. The physical properties of the tumor and the cachetic appearance of the patient were such as to counteract any opinion, based upon the long duration of the disease, in favor of its cystic character.

FIG. 1.

A CASE OF PRIMARY (TRAUMATIC), NON-INFECTIVE THROMBOSIS OF THE CAVERNOUS SINUS. OPERATION (BY DR. FRANK HARTLEY). REMARKS.

BY HERMAN KNAPP, M.D.,

NEW YORK CITY.

(With four photographs.)

Francis H. Cuffe, æt. 30, 629 East One Hundred and Thirty-seventh Street, New York City, admitted to New York Ophth. and Aur. Inst., January 1, 1900.

History.

Five weeks previously the end of a billiard cue struck the ball and upper orbital margin of the left eye. The eye watered considerably for about ten days, without any other symptoms. The lids and conjunctiva began to swell and the eyeball protruded. Soon after, it receded somewhat, but since December 25th the protrusion has been more pronounced.

Condition on Admission.

The lids are swollen; the eye is pushed forward and downward; its mobility restricted; most so, upward; least, outward; patient counts fingers at 20′; F., T., and pupil normal; media clear; periphery of optic disc and adjacent retina swollen; veins engorged, dark-red (thrombosis of central vein?); no hemorrhage; arteries and veins pulsate on strong pressure; the upper lid hangs as an inert, dark-red mass of flesh over the eyeball; it feels soft on the nasal side, hard and somewhat uneven on the temporal; the hardness begins at the brow and extends uninterruptedly about 15 mm. down; the patient is somewhat apathetic, but gives reasonable answers when asked. For years he has been hard of hear-

ing on both sides; his drumheads are pale, irregular, cicatricial, free from inflammation, but giving evidence of former purulent otitis media; the right ear is completely deaf; the left moderately hard of hearing. The *probable diagnosis* is: injury of the roof of the orbit, possibly a fissure, with effusion of blood and serum; yet as there is no sub-conjunctival hemorrhage noticeable, the presence of a traumatic sarcoma is thought of. The patient is ordered to lie in bed, with sustaining diet.

Course of Disease.

January 2d. Considerable chemosis; temporal margin of od free; the other parts ill defined and swollen; on palpation, no tenderness in any part of the orbit.

January 5th. Fingers at 5′; less swelling of lids and conjunctiva.

January 6th. Fingers at 8′; veins of retina dark and swollen; arteries and veins pulsate on light, and empty on strong pressure.

January 8th. Od and retina more swollen; chemosis on lower side greater; fingers at 4′, excentrically.

January 9th. Neuro-retinitis; movements of hand only. Incision into nasal part of the upper lid liberates little serum.

January 10th. Pupil large; fundus reflex normal; no details recognizable; left eyeball immovable.

January 19th. Hearing of left ear weaker; the swelling of the lids and conjunctiva slowly increases.

January 21st. The skin of the left side of the face, the anterior half of the forehead and scalp, and the anterior surface of the left auricle show diminution of sensibility; cornea sensitive; dull in lower part, which is exposed.

January 30th. Keratitis from lagophthalmos.

February 18th. (See Fig. 1.) The condition of the lid and conjunctiva essentially the same; patient more apathetic; the whole region of skin supplied by the sensitive branch of the fifth pair now anæsthetic; the cornea is sloughing; iris prolapsed in lower part; temp. 98.6; pulse 68, normal in character; sensibility of mucous membrane of mouth and nose preserved. From *right*

FIG 2.

ear slight discharge at times; none from left. Fundus, S. and F. of right eye normal; no signs of inflammation in either ear.

Extended Clinical Diagnosis.

Œdema of lids and conjunctiva, exophthalmos; diminution and gradual abolition of mobility of the third, fourth, sixth, and anæthesia of the sensitive branch of the fifth pair; the venous engorgement and œdema of the retina, and the neuro-retinitis furnish sufficient evidence to assume the presence of **thrombosis of the left cavernous sinus.** As the most probable cause, a fissure of the roof of the orbit with injury to the sinus was supposed in a similar way as the arterio-venous communication in the cavernous sinus is caused by a traumatic rupture of the carotid in the sinus, yet I thought that the presence of that rare and fatal disease of a traumatic palpebral and orbital sarcoma could not be excluded. In the latter case all surgical interference would be contraindicated; in the former, the chances, according to our present knowledge, were scarcely less appalling. In the limited number of cases reported, the other eye nearly always became blind under the same symptoms as the first, namely, by extension of the thrombosis from the cavernous sinus of one side to that of the other. Panas*, who collects the incident literature, counter advises an operation, as only one case had been operated on before (by Horsley), and the patient had died eleven hours after the operation. Yet in our case I did not want to let misfortune continue its inexorable course, but was determined to have an operation performed as soon as there were symptoms of beginning thrombosis in the other eye. These symptoms soon enough made their appearance.

February 21st. I made the round through the hospital at 2 P.M., as usual; examined the patient, in particular his right eye, for which I now cared chiefly. I found everything normal. At 4.30 P.M. the same day I showed our patient to a visiting physician. He presented a different picture in the right eye; œdema of conjunctiva, lids, and neighboring skin, slight but distinct pro-

*Text-book. Tome II.

trusion of the eyeball, and the retinal veins swollen; T., S., and F. normal. These symptoms diminished later, were almost gone the next day; but returned more markedly on the following days, abated, and re-appeared again. Convinced that the case would follow the same course as the similar ones on record, I told the patient and his father — both extremely sensible men — that in my judgment the other eye also was threatened with blindness, and only an operation could possibly save it. The operation would not be without danger. Both father and son unhesitatingly said: "We are willing to take any risk to avert blindness."

I went to **Dr. Frank Hartley,** one of the attending surgeons of the New York Hospital, of whom I knew that he had several times successfully extirpated the Gasserian ganglion, and asked him whether he was willing to clean out the left cavernous sinus (which I supposed to be obliterated by a non-infective thrombus) and prevent the thrombus from extending to the other cavernous sinus, by ligating or compressing with a tampon the circular sinus. He seemed startled at first, but when I had told him the history of the case and he had examined the incident literature and we had discussed the case together a second time, being convinced that total blindness and subsequent death would be inevitable, he said: "I will do it." The greatest counter-indication was the possibility of the presence of a traumatic sarcoma, but this we could not yet assume with any degree of probability.

The patient was transferred to the New York Hospital February 28th and operated on there March 1st by Dr. Hartley in the presence of a number of physicians, myself included.

Dr. Hartley, on my invitation, was kind enough to be present at the meeting of the American Ophthalmological Society, at which he detailed the operation and gave me the following description of it:

"The patient was prepared in the usual manner for operation. The anæsthetic used was nitrous oxide and ether.

An incision was made over the temporal region (Fig. 2) — horseshoe in shape — and situated as in my operation for the ex-

FIG. 3.

tirpation of the Gasserian ganglion. The periosteum was divided in the line of the skin incision. The bone was divided by means of Doyen's drills, Obalinski's dural depressors, and Gigle's wire saw, and in shape similar to an equilateral pentagon. The osteoplastic flap thus formed was raised and reflected over the zygoma. The dura mater was loosened from the squamous and petrous portions of the temporal bone sufficiently to recognize the second and third divisions of the fifth nerve and the middle meningeal artery at its entrance into the middle fossa of the skull. The middle meningeal artery was now divided. Its distal end was managed by compression beneath the brain retractor, while its proximal end was plugged with catgut in the foramen for its passage through the sphenoid bone.

At this stage the dura mater was incised just above the cavity of Meckel enclosing the Gasserian ganglion, which, being followed by the escape of cerebro-spinal fluid, allowed a greater field for the operative work. This escape of fluid allowed a very good field for work, but it implied that the retraction of the brain must be carefully and evenly carried out. The cavernous sinus was now located. In front of the junction of the second and third divisions of the fifth nerve the cavernous sinus was incised longitudinally as far as the sphenoidal fissure. No hemorrhage took place at this time, since the vein lumen was occupied by a clot, which filled it and which was removed without difficulty, but not in its entirety. The division of the third and fourth nerves, and the ophthalmic branch of the fifth in incising this portion of the sinus wall was not thought to be of moment, since they had already shown evidence of paralysis. After the removal of the clot in this portion of the sinus a fine probe was passed into the sinus beneath the fifth nerve and toward the superior petrosal sinus. When this point was located, the incision in the cavernous sinus was extended and the remaining clot removed. The entrance of the superior petrosal sinus, which at first did not bleed, was seen. After assuring one's self that no portion of the clot remained in the cavernous sinus, the circular sinus and the superior petrosal sinus were investigated carefully with a fine probe. From these

sinuses blood soon flowed, but from the ophthalmic vein no blood escaped. The escape of blood from these two sinuses was thought to be sufficient and satisfactory to demonstrate their permeability. The walls of the cavernous sinus were now allowed to drop together, and, as they apposed very accurately, a small strip of gauze (sterile) was placed against them and over the entrance of the circular sinus. The end of this piece of gauze was brought out through the lower angle of the wound in the skull. This gauze was small in amount but very accurately applied over the sinus. The brain was now allowed to fill the fossa, which it did in about twenty minutes. There was no hemorrhage at this time. The osteoplastic flap was replaced and sutured, but in such a manner that the gauze could be easily removed on the third day without greatly disturbing the flap.

The condition of the patient at the conclusion of the operation was good. He left the operating room in excellent condition."

The subsequent history of the case is as follows:

There was no affection of the right eye; he could always see well, and its outer aspect and the background remained normal. The left eyeball has sloughed, the tumor has continued growing steadily; at the margin it is nodular; it has encroached on the temporal side (Fig. 3), the region of the brow and the glabella. (Fig. 4.) At the upper nasal corner it begins to slough (Fig. 3). The diagnosis of a traumatic sarcoma is evident, and as, according to general opinion, with which my experience agrees, these tumors are never cured, and operations hasten rather than retard a fatal issue, I counter-advised every further operative interference.*

*The patient became apathetic, soporose, and died, May 16, 1900. The autopsy verified the diagnosis of sarcoma, showed corrosion on both sides of the left orbital plate of the frontal, muco-purulent secretion in the uncorroded accessory cavities of the orbit, complete filling of the interior of the *right* petrous bone with cheesy material, the outer table of the petrous, however, unbroken.—I intend to give a more detailed account of the later history and the autopsy of the patient as well as bibliographical notes on incident cases in the Archives of Ophthalmology. H. K.

In the illustrations, Fig. 1 is from a photograph by Dr. Ch. W. Stevens of N. Y., and shows the patient two days before operation. Figs. 2, 3, and 4, are from photographs by Dr. John B. Solley, house surgeon, New York Hospital, and show the condition of the patient after operation, the configuration of the osteo-plastic flap, and different aspects of the tumor.

FIG. 4.

OPTIC ATROPHY FROM BLOWS ON THE FOREHEAD AND TEMPLE.

BY JAMES A. SPALDING, M.D.,

PORTLAND, MAINE.

CASE NO. 1. Several years ago a locomotive engineer received a severe blow on his left temple, probably from a stone suspended by a string from a bridge under which the train was passing rapidly. He had his head out of the cab window to see if all the switches were correct, when he suddenly felt the blow. It dazed him a little, but he was able to continue his work.

At the end of the four hours' run there was a large lump on the left temple, and a distinct incision where he had been cut.

The eyelids themselves, as well as the eye, were free from any irritation, and the man thought nothing about the occurrence except as regards the feeling of soreness until about twenty-four hours later, when he perceived a mist over all objects to the left hand, and on covering the eyes alternately he was able to limit the mist to the left eye. In other words limitation of the visual field of the left eye had set in. This went on without interruption, gradually extending from half sight to total loss of all sight, central or excentric. When I first saw him there was a small recent scar at about the junction of the temporal and frontal bones and about one inch above the superciliary ridge. The eyelids were normal. There was nothing to be seen in the way of an injury to the eyeball. The pupil was rather wider than that of the right eye. Ophthalmoscopic examination showed white optic atrophy, no vision. Right eye normal. The treatment consisted in hypodermatic injections of strychnia, rising from 1/30th to 1/10th grain, and the use of a galvanic battery around the eye and temples. Tonics of various sorts were employed, but all in vain; the eye remained totally blind. Other specialists were consulted, but without avail. The case

terminated in a typical atrophy of the left optic nerve, and has remained unchanged to this day, the man having long since been taken from the passenger trains and consigned for safety to ordinary switching work in the yard.

CASE No. 2. This lady had always had good eyesight, had even been tested by me a few weeks before and lenses given so that with each eye she had perfect vision, both for far and near. Owing to this circumstance I am able to set aside any simulated or exaggerated loss of sight, even if such could be suggested. She received a severe blow in the face by colliding with the edge of a door in the dark, and fell to the ground from the concussion and rebound. She soon recovered consciousness, but went directly to bed with a headache and severe localized pain. On beginning to dress in the morning she found objects looking dim, could not seem to lay hands on any object accurately, and on closing first one eye and then the other, she found that the sight of the left eye was seriously affected. She came to me at once and I discovered in the retina not far from the pupil a very dense, red, fresh retinal hemorrhage. Treatment of various sorts, including hypodermatic injections of pilocarpine, was employed, but to no avail in the absorption of the clot which gradually extended downward, then gradually degenerated into what we may suppose was fatty tissue, for it soon resembled the white patches in Bright's retinitis, and after a month or two optic atrophy ensued, the case terminating in total blindness, with a hard, white, pale disc. The left pupil was active and a little larger than the right. Vision was normal in her other eye, and has remained so ever since.

CASE No. 3. A lady, Miss A., was thrown from her wheel and struck on her head, not hitting her body anywhere. The outer margin of the left orbit was cut, as well as the bridge of the nose, and a tooth was knocked out of the left upper jaw. The whole side of the face was also extensively bruised. The patient became at once unconscious, and had no remembrance of anything until she came to her right mind in a hospital an hour or more later on the same day. The numerous stitches that the

surgeon was compelled to take in the superciliary ridge and on the bridge of the nose in order to make good coaptation of the wound and obtain a nice cosmetic effect, necessitated a bandage to cover the left eye. Six days later, on lifting the bandage, she discovered that she could no longer see the upper half of objects with that eye alone. Thinking that this phenomenon might be due solely to the swelling of the lid she did not pay much attention to it until the next day, when on carefully raising the upper lid so as fully to uncover the eyeball and pupil she became convinced that the eye had lost part of its sight. A specialist was called in who said that he could see nothing wrong, but some weeks later he was of the opinion that the optic nerve was atrophied. There was at no time any pain in the eye except directly after the fall, and that was soon relieved by using hot water. When the patient consulted me she expressed herself as seeing a shadow covering the sight constantly, and causing the eye to feel as if the lid were swollen. The shadow covered the sight of all things above, and there was very little difference in what could be seen to the right and left; that is to say, she could see nothing above, but about the same sort of misty sight on the right and left lower halves. She could for some time see letters of Snellen 10 close to the eye with some difficulty.

When I saw the patient in consultation several months later there were distinct traces of former hemorrhage in the periphery of the retina, loss of sight described as "a veiled appearance over the outer world," and distinct shiny, white optic atrophy, for which all remedies were of no avail, though persistently employed for several months. Vision of the other eye normal.

CASE NO. 4. This is a very curious case in which it is difficult to decide whether the fall from a cycle caused optic atrophy or whether there was sunstroke or cerebral hemorrhage intervening and exercising some influence in the production of optic atrophy and total blindness in one eye, and that eye the one below the injured orbit.

One hot June day a clergyman, aged 26, was intending to attend a quarterly meeting of the neighboring clergy some ten

miles from the place where he had been for a year or two preaching. On reaching the house of another clergyman whom he had proposed to accompany on his wheel, he found to his regret that the friend had gone on ahead. He made another stop farther along, and is said there to have complained of his head feeling tired and overworked. After resting awhile he went along rapidly, impressed with two ideas, one that a mile and a half farther along he had to make a turn in the road to reach his destination, the other being to stop at a house where a short time before he had officiated at the burial of a young man who had died of consumption. But before he reached either the turn or the looked-for house, something occurred to him; what, we shall never know. But somewhere between eleven and twelve o'clock he fell from his wheel on a road which he never had the least idea of taking, and which he knew he ought not to have taken because he knew all the roads perfectly well, and knew that that road would lead him miles away from the conference. Three hours later he was found unconscious beneath his wheel, with deep wounds in his right forehead, and orbital ridge, and on his right shoulder, from all of which he must have lost a great deal of blood. The deepest wound was directly over the right eye, and he thinks came from his spectacles or lenses striking him there, but from my observation such a long cut from spectacle-frames or lenses would seem incredible. He was taken to a physician's house a mile or so distant apparently lifeless, and remained absolutely unconscious for ten days, and, as the physician says, " when he came to his senses he was exactly like a mere infant learning to talk." But this physician saw no reason from the appearance of his injuries why he should not soon come round all right.

All this happened in June, and when I saw him in July I found a high degree of myopia in the left eye, and he wore a — 5 D lens for constant use. The sight of the left eye with this lens was nearly normal in the distance, and he could read diamond type. The right eye showed a small pupil, though a trifle larger than the left, freely movable, media transparent, and no other

ophthalmoscopic picture than a typical white atrophy of the optic nerve. He described the sight of that eye as a "great dimness," a "flame of light that goes out before it comes to anything," "something that I cannot exactly localize," in other words, total blindness, with occasional phosphenes, such as are often heard of in optic atrophy.

The patient's handwriting, which used to be elegant, was now like that of a child learning all over again how to write. He often wrote to me reasserting that his bows had made the large, deep scar in the orbital ridge. He acknowledged that he could not control his handwriting as of old, but his speech was more clear than his way of expressing himself with his pen.

A recent letter from the physician who picked up the injured man at the time of the accident tells me that mentally he is now much better, that he speaks more clearly, expresses himself better; his memory is still poor, and although he can recollect impressions and events long before his accident, he has no recollection of what has occurred since, except of his physicians and of a few striking incidents. He is decidedly odd. He writes me long letters, yet, in every few sentences he reiterates the fact that he can no longer see with his good eye, yet that is the eye with which he is writing, for the other one is totally blind from optic atrophy, being unchanged from what it was when I saw him two years ago. His expressions are odd. Thus he says, in speaking of a physician using strychnia and the iodide of potassium: "In trying to reach the eye, I think he went too far with the functions of the weakened body," "I have about surrendered hope, but still I am not hopeless yet."

This case is very interesting, but still doubtful in its pathology. The optic atrophy indicates fracture somewhere along the optic canal, yet the mental condition suggests a blood clot or pressure elsewhere as a possible cause of the atrophy. The mental condition points to a central cause, probably due to the traumatism. Nevertheless, above all this, the heat of the day and the complaint of the weary head shortly before the accident suggests meningitis as the most probable cause of both the mental and ocular symptoms.

The interesting points about cases like these are, first, the rapidity with which optic atrophy ensues after injuries about the orbit. In three of these cases it occurred in about six days, according to the patient's assertions, while in the fourth some weeks elapsed before blindness was total, during all which time there was a constant decrease in the vision of the eye on the same side as the injury to the orbit or temple.

All injuries to the eye are interesting, whether gross or small, tending to excite sympathetic ophthalmia or not, requiring surgical interference or not, but to all such mysterious cases as these which I here report greater interest should always attach itself. Here we have perfect eyes, never subject to any traumatism, yet losing sight entirely beyond all human help simply from a blow on the forehead or temple. As post mortem examinations in such cases are rare, we are thrown back on the old accepted doctrine of fracture of part of the roof of the orbit or optic canal. In one case, however, the presence at a late date of retinal hemorrhage or traces of such a hemorrhage, would suggest hemorrhage along the optic nerve sheath as the cause of blindness, rather than actual force applied to the optic nerve through the fracture of the bone.

I regret that no examination could be made of the field of vision, but at the time when I saw all of these cases the sight was practically abolished, so that such measurements could not be made.

The remarks made by the lady falling from her wheel are well worth recalling, for she is a very intelligent teacher, one accustomed to observe accurately for the purpose of teaching her children. She said that she could not see the upper halves of objects and thought that the upper lid was swollen, and so fell down over the eye, or else that it partially covered the pupil. Such an explanation would naturally occur to the laity (or to some of them), but we know that the visual field was affected by concussion or hemorrhage. The exact location of the latter I am unable to state, having lost my notes.

A still farther interesting point is the behavior of the pupil

in all of these four blind eyes. There was no chance or inclination for fraud nor desire for pension, or demand for damages calling for exaggeration of the actual condition of the eye and its sight. There can be no question that the sight was ultimately wholly lost in all four eyes, and that it remains so to date. Now the pupil of each of these blind eyes contracted and expanded consensually with the admission of light into the good eye and its withdrawal. Furthermore, on throwing light into the blind eye the pupil remained immovable and of the same dilated size as at the instant when the light was shut off from the good eye. This test can be suitably used for simulated blindness when the asserted blind eye is uninjured. Plenty of textbooks state that the pupil of the actually blind eye remains motionless on reflecting light into it, but I do not recall this precise statement: that, if you reflect light with the ophthalmoscope into the good eye the pupil of the blind eye contracts, but again immediately and rapidly dilates on removing the source of light from the good eye, and remains dilated, no matter how much light you throw into it later.

Another point of interest is in Case 1, in which a *motionless* stone of a size probably not larger than a horse-chestnut destroyed the sight of the eye by a blow on the orbit from the patient being carried with great velocity *against it.*

Finally, two of the cases emphasize the risks attending on riding the wheel; no matter what care one exercises, an occasional fall is a possibility, and with it comes the chance for the loss of the sight of one eye, at least, from optic atrophy.

DISCUSSION.

Dr. GRUENING. I wish to speak first of the cases referred to by Dr. Spalding. He seems to hold the views of Berlin as obsolete, and I wish to state that this is by no means so. If one knows the history of these cases and knows how obscure the subject was before Berlin read his epoch-making paper, one would understand what a debt of gratitude we owe him.

Now as to the cases presented by Dr. Harlan, these have interested me very much, and I have thought for some time that

it is necessary to attack these cases of sinus disease by orbital operation. I have quite recently seen a case presenting symptoms of frontal and ethmoidal trouble in which I resorted to the operation described by Jansen and secured subsequent healing without any deformity. I think this operation should be practiced by us in many cases, not only in sarcoma of the ethmoidal sinuses, as in this case, but for the relief of acute inflammatory conditions.

I next wish to mention one point in regard to the cases presented by Dr. Ewing. This matter is certainly not new, for I read a paper on the very same subject fourteen years ago in the New York Academy of Medicine, under the title of "Reflex Ocular Symptoms in Nasal Affections," and published it in the New York Medical Record, 1886. The nose is only an appendage of the eyes, and any man who knows anything about the eye should know much about the nose.

Dr. LIPPINCOTT. Just a remark upon the subject of Dr. Spalding's paper. The atrophy following the injury in his cases was rapid, but the atrophy does not always follow so speedily, and these cases may have a medico-legal interest. I saw a case recently of a person thrown from a street car who claimed blindness of the left eye as a result of the accident. About three weeks after the injury she was sent to me by the railroad company for an examination, and I found with the ophthalmoscope an absolutely normal retina, the fundus on each side being exactly alike. Furthermore, although she stated that the left eye was absolutely blind, the test which I introduced ten years ago for testing binocular vision, viz.: placing a cylinder before the good eye and thus producing metamorphopsia, proved that binocular vision was present. With Harlan's test for malingering — a strong lens before the good eye — she read 20/XL with the supposedly blind eye. There was strong reason, therefore, to believe that the case was made up and that no great damage had been received. A few months later I was asked by a neurologist if I had not given such an opinion on the case, and I said yes. He said that the woman had now a pronounced atrophy. He sent her down for my examination and I found the nerve as white as paper. Cases of this kind go to show that under similar circumstances a negative opinion ought to be given with caution.

Dr. HARLAN. Only a few days ago a man came to me who had received an injury to the brow and temple, and had absolute

blindness without any ophthalmoscopic changes. I took the view that there had been a fracture at the apex of the orbit, involving the nerve, and that atrophy would probably appear later.

Dr. RISLEY. I have reported a group of seven cases in which atrophy of the optic nerve followed injury to the orbital ridge. In one case the blow was received on the inferior orbital ridge, in five on the superior, and in one case the man was injured by a timber falling upon the front part of the head. In this case the atrophy was double and did not go on to complete blindness. In all the others the atrophy was monocular and the blindness complete. In all but one the atrophy came on late, and in that case there was profuse intraocular hemorrhage following the injury. One case did not complain of any trouble until six weeks after the injury, when the ophthalmoscope revealed commencing atrophy. I have in the hospital now a man who was struck by a crane on the superior orbital ridge about five weeks ago and there is now a commencing atrophy, with distinct diminution of the sharpness of vision. This substantiates the claim just made by Dr. Lippincott, that we should not be hasty in our prognosis in such cases of injury.

Dr. H. KNAPP. In my opinion the third case of Dr. Bull was one of infective thrombosis of the cavernous sinus. The otorrhœa, the exophthalmos, etc., support this diagnosis. That the patient recovered without operation is not unheard of, for a goodly number of infective sinus thrombosis are on record which, even when accompanied by optic neuritis and metastatic pneumonia, with a steep-peaked temperature chart, ended in recovery without surgical interference.

Dr. RANDALL. In relation to the bruit in cases of vascular orbital lesion help may sometimes be gained from the aural auscultation tube in cases of aneurism of the first and, perhaps, the second sigmoid curve of the carotid, as I have had occasion to report.

As to the nasal lesions affecting the eyes, we had much light on this subject from Harrison Allen in Philadelphia, and have long employed the pressure back of the lachrymal sac in seeking anterior ethmoid involvement; and Coyer has called attention to variations of the uncinate process as impeding the hiatus semilunaris and giving rise to the accessory opening of the antrum. Careful exploration with cocaine in this region has long greatly aided me, and internal administration of atropin is almost specific in relieving sinus stenosis of slighter grades.

CONCERNING RELATIVE ACCOMMODATION AND CONVERGENCE, WITH THE DESCRIPTION OF AN INSTRUMENT FOR THEIR MEASUREMENT.

BY LUCIEN HOWE, M.D.,

BUFFALO, N. Y.

The reason for this study will be more apparent if we recall for a moment the clinical importance of the varying degree of accommodation with relation to a definite amount of convergence, or of the varying degree of convergence with relation to a definite amount of accommodation. It is well known, of course, that when the visual axes converge to a certain point, *p*, for example to reading distance of about thirty centimeters, the individual

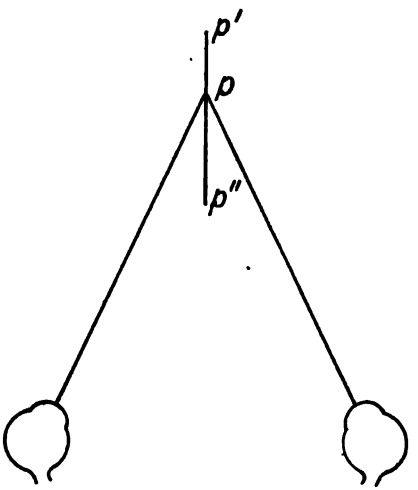

FIG. 1.

must still be able to increase his accommodation (as shown by the ability to overcome concave glasses), up to a certain limit of strength. This increased accommodation for a point *p''*, nearer than the one to which the axes converge — represented by the distance *pp''* — being the *positive* part of the relative accommodation.

Or, with the axes converging to this same point, p, the individual must also be able to relax his accommodation (as shown by the ability to overcome convex glasses), up to a certain limit of strength. This lesser accommodation for a point *p'*, further off than the one to which the axes converge—represented by the distance *pp'*, being the *negative* part of the relative accommodation. In other words, it is a well-established physiological fact that if eyes are to be used with comfort, they must hold in reserve the ability to accommodate, if desired, to a nearer point than that to which the axes of vision converge. Any disturbance of this physiological relation between accommodation and convergence is the main cause of that discomfort, pain in the eyes, headache, with other symptoms, which together we call asthenopia — if not indirectly, the only cause of it. Whenever that proper relation does not exist, we endeavor to furnish glasses which will make it possible. In fact, the greater part, if not all, of our aim in the selection of glasses is to enable the patient to converge at a given distance, still keeping in reserve a certain amount of positive accommodation.

Now, in spite of this, I think all will agree that in practice our measurements of relative accommodation or convergence are both insufficient and unreliable. It is true we do test the relative convergence, in a certain way, at the far point, using for this the Maddox rod or prism or Stevens lens or phorometer, etc. We even base diagnoses upon those tests, and perhaps imagine them sufficiently reliable to warrant resort to operative procedure.

However that may be, in practice we do not test the relative accommodation or convergence for the near point, the very point for which the eyes are most used. For example, in a case of asthenopia persisting after full and repeated correction according to tests made at the far point, we still do not know whether the accommodation for the near point is at fault with reference to the convergence, or the convergence at fault with reference to the accommodation, or whether both of these are at fault. In such a case it is much quicker and easier to weave theories concerning 'phorias, manifest or latent, than, with patience and accuracy, to measure the actual relation of accommodation to convergence.

But the difficulty was, that thus far, we could not make these measurements unless by rough approximation, for the reason, principally, that no instrument existed for that purpose, except possibly in occasional ophthalmological laboratories.

Now the object of this inquiry is to ascertain,

First: Whence come the data usually given us concerning the relation of accommodation to convergence?

Second: What are the difficulties in making these measurements, and how can they be overcome?

As to the first point. It is rather surprising to find how small an amount of original work is recorded, in proportion to the space usually given to the subject in the text-books, and how frequently and regularly the earlier statements are simply repeated by later writers. The first thought of those who thought at all of the subject was that accommodation and convergence were inseparable. But about forty years ago the question was investigated in the laboratory of Utrecht by Donders, and, under his evident guidance, by MacGillavry.

The instrument used then is figured by the former (Accommodation and Refraction, page 116) and the person whose eyes were measured was the girl of fifteen to whom Donders so often refers.

The results of that examination are the well-known principles in regard to relative accommodation and convergence which are repeated in every text-book more or less elaborately, which have been briefly referred to at the opening of this paper, but which it is impossible to consider in detail now. It is sufficient to observe that although the manner of recording the measurements was simplified by Nagel about twenty years later, by making them accord with the metric system, still, practically nothing new was attempted till 1882.

In that year the subject was taken up again, — that time by Bisinger, in Nagel's laboratory in Tübingen. The apparatus and the method were substantially the same as that employed by Donders and MacGillavry. Bisinger records the examination of five individuals, himself among them.

These results agreed in general with the findings of MacGillavry and Donders, but they were more complete.

It would require too long a digression to describe these here, but they will be discussed later. A careful search through the Jahresbericht back to 1882 shows that since then little or nothing has been done with this subject, in spite of the fact that the changes have been rung repeatedly on nearly every other phase of muscular dynamics, and in text-books of to-day like Landolt, Graefe and Saemisch De'Wecker, etc., the diagrams showing relative accommodation are copied from those made nearly twenty years ago.

From the description of the optometer previously used, it seemed that this might be simplified and improved in the following points, namely:

First. In the general plan of the instrument.

Second. In the selection of the radius of the arc through which the glasses or prisms are moved as the convergence of the visual axes increases.

Third. In the method of bringing the glasses before the eye.

Fourth. In the object used for testing the accommodation at various points.

Fifth. In the addition of revolving prisms for testing relative convergence as well as relative accommodation.

Sixth. In the more exact fixation of the head.

Seventh. In providing a more convenient visuometer.

Eighth. In the construction of a chart showing at a glance the angles of convergence at all meter angles from the minimum to the maximum degree possible.

As this instrument has gradually grown by repeated changes, it now differs so much from the original as to be practically another form. It may be described briefly as follows:

A square brass rod one hundred and three or four centimeters in length is attached like the long arm of a T to the center of a similar rod which is about eight to ten centimeters long. This longer arm is elevated at each end by a footpiece which is so arranged that the bar can be raised or lowered from twenty to

thirty centimeters or more from the table. Resting on each side of the short arm of the T there is a graduated disk which may be called " the carrier." This consists of a strip of brass measuring about fifty millimeters wide and three or four millimeters thick. Near its center there is a slot in the form of an arc, the center of



FIG. 2.

this arc being exactly thirty millimeters behind. The posterior portion of the carrier is removed in order that the cheek may be allowed to approach near to the slot. The center of the eye when under examination should be placed at the center of curvature of this slot.

The curved slot is graduated in degrees. The zero point of the arc on the carrier is where this arc is crossed by a radius exactly parallel to the long arm of the T, — that is, it represents the position of the visual axes when these are parallel and directed at an object in the horizontal plane. The degrees on the arc from this zero point inward, indicate, therefore, the convergence of the visual axes. A small nut is accurately fitted into each slot. The cap of this nut has an index line in front, showing its place with relation to the degrees of the arc, which are marked on the upper surface of the carrier, while beneath, the nut is easily tightened or

loosened by means of a thumbscrew. Through the center of this nut a short bar passes upward and holds in place the discs of a Loring opthalmoscope placed as indicated in the figure. In setting the opthalmoscope it is essential to have the center of the opening before which the various glasses pass, exactly in a perpendicular line over the index which marks the degree on the arc.

The disc of the ophthalmoscope contains seven plus glasses, 1 to 7, and eight minus, 1 to 8. With this there is an additional quadrant having six glasses, namely, plus 0.25, 0.5, and 16 and minus glasses the same. With these it is possible to make all the combinations necessary for a complete examination. It should be noted that this arrangement of the glasses is one of the decided advantages of this instrument. The former process of successively taking the glasses one after the other from the case, placing them before the eye of the patient, waiting for the answer, and then selecting another pair, with the doubt each time as to whether they are set exactly at the right angle of convergence, is tiresome to the examiner and to the patient, and liable to many errors.

Each carrier has also a second nut with index, thumbscrew, and upright like the one just described, moving in the same slot in the same way. This second nut, however, has attached to its upright bar not an ophthalmoscope, but a small rotating prism like that proposed by Risley. The center of this prism, like the center of the opening in the ophthalmoscope, is immediately above the index on the arc and as near to the carrier as possible. After the tests for relative accommodation have been made, the thumbscrew of that nut can be loosened, the ophthalmoscope removed and replaced by the other nut which supports the prisms. The tests can then be made for relative convergence.

The two carriers are joined in front by a screw of double rotation, so that they can be made to approach or be separated from one another in order to adapt the instrument to eyes which have different distances between their centers. Moreover, an index passing along the linear slot and over a millimeter

scale shows the distance between the zero points of the arc of the curved slot, — in other words, the distance between the centers of the eyes under observation.

The long arm of the instrument is graduated in meter angles, No. 1 being a distance of one meter from a line joining the centres of the two arcs in the carriers, that is, one meter from a line joi ing the centers of the eyes. On this long arm also a four-sided frame is arranged to slide back and forth. This frame revolves around a central pivot, and into each one of the four sides a small card of test types is placed. The plane of each one of the sides, when turned toward the observer, corresponds with the proximal end of the slide, and therefore marks the distance in meter angles from the line connecting the centres of the eyes of the observer. By means of this revolving frame it is easy at once to change the test object from letters which subtend a proper angle at a distance of one meter, one-half, one-third, and one-fourth, etc., corresponding, of course, to one, two, three, and four meter angles.

A word should be added as to the name of this instrument.

Donders described the arrangement which he used as an optometer, but that was designed to measure only the relative accommodation with a given convergence, not, as in this one, relative convergence also with a given accommodation. Moreover, the term optometer refers rather to an instrument for testing the *acuity* of vision, and of these we have innumerable forms, some based upon the action of a single convex lens, others upon Galileo's telescope or on the astronomical telescope, Schreiner's experiment, chromatic aberration, etc.— none of them are very often used. Evidently it is only confusing to add to that list, another which differs in principle from them. Besides, as the instrument here presented measures not only the refraction but also the force exerted by one set of muscles in their relation to another set, it might be called also a dynamometer, but that Landolt has used that term for a simple arrangement of quite a different kind. As this combines, however, the functions of the optometer and of the dynamometer, it seems not too far fetched to call it an opto-dynamometer.

So much for the instrument alone. In order to make it useful it was necessary to supply three adjuncts.

The first of these is a proper head rest. That appliance is shown herewith, but as a description of this would necessitate a digression, that will be given in another place,* together with a consideration of the uses in ophthalmology of such a head rest.

A second adjunct to the opto-dynamometer is a visuometer, or instrument for determining the exact distance between the eyes in any individual. There are various methods of measuring this distance, and I have found that an earlier form of the visuometer could be conveniently used, with some modification, to give satisfactory results.

A form of this is also shown here, but as a description of it would also necessitate a digression, that too will be described elsewhere.

A third desideratum is a chart of the angles of convergence. This should include eyes with all possible distances between their centres, when converged to all possible distances in the median line of the horizontal plane.

The chart here presented includes the arcs of convergence up to a distance of thirteen meter angles. For completeness and to accord with this instrument it should be carried to fifteen meter angles. This third adjunct will be completed and described elsewhere, together with the formula for obtaining the angles, for a consideration of any one of these three points would necessitate an extended essay instead of a paper suitable for presentation at a meeting of this kind.

Finally, we will probably all agree that the complete chapter on muscular dynamics still remains unwritten. Reasons can be given, I think, for believing that whoever does write that chapter will incline more to the views of Donders and Nagel and show that relative accommodation and convergence, especially at the reading distance, is a factor of much greater clinical importance than we now ascribe to it. For any such studies, either in the laboratory or in the consulting room, this instrument, I hope, will be found convenient and accurate, and for that reason it has seemed worth while to present it to the notice of the society.

*See American Journal of Ophthalmology, June, 1900.

NOTES UPON THE SURGICAL TREATMENT OF A CASE OF HIGH MYOPIA.

BY CHARLES W. KOLLOCK, M.D.,
CHARLESTON, S. C.

In August, 1895, a lad of sixteen years of age was brought to me on account of poor vision. With each eye he could see 3/CC, and with — 13 D vision was increased in each to 15/L, but could not be further improved. The ophthalmoscopic examination showed a healthy condition of the media and but little retinal and choroidal disturbance beyond small crescents at the outer margins of the disks. He was given — 10 D for constant use, and these he wore for three years, when he again came under my observation. The myopia had increased 3 D, the crescents were slightly larger than before, and with — 16 D his vision was still 15/L. He was advised and agreed to undergo the surgical treatment. After several discissions had been performed the lens matter was evacuated through an upward incision in the cornea without an iridectomy having been made. A slightly distorted pupil, due to adhesions between the iris and capsule, is the only visible trace of the operation. Before the removal of the lens his vision without correction was 3/CC; after it was 15/LXX without a correcting glass. Before the operation, with — 16 D for each eye, vision was 15/L; after, with +1.50 + 2.50 cyl. ax. 90°, it was 15/XL, and he reads Jaeger No. 1 easily with + 5 + 2.50 cyl. ax. 90°. The eye has remained quiet, the vitreous clear, and apparently no retino-choroidal changes have occurred since the operation was performed last summer (1899). The lens of the second eye is undergoing absorption, as discission has been performed several times. I decided to do only the needle operation on the last eye, as it seemed safer in spite of the fact that it was necessary to repeat it several times. There can be no doubt that the operation by discission is safer in children and in young adults, in whom the lens has not become hard; and on account of the slight disturbance which is

usual after a carefully performed discission, the danger of increased tension and of retinal separation is lessened. The disadvantages of discission are the length of time required for absorption of the lens and the danger of infection from the increased number of operations. The first objection has but little weight, as a loss of time cannot be seriously considered when a gain in vision is the reward. Infection should not occur when proper precautions are taken.

Most authorities agree that the operation should not be performed unless there are D 12 of myopia, and in general it would seem best to follow this rule, but in children, in whom myopia has been congenital or has advanced rapidly, and especially when heredity seems to have played a part, as it certainly does in some cases, surgical intervention would seem to be indicated at an earlier period, while the lens is still soft, retinal detachment less apt to occur, and progressive structural changes may be retarded or stopped.

EXCISION OF THE LACHRYMAL SAC AND GLAND FOLLOWED BY AN UNUSUAL VARIETY OF NEURO-PARALYTIC KERATITIS, MARKEDLY RESEMBLING CLINICALLY THE SO-CALLED LATTICE-LIKE KERATITIS.

By C. A. VEASEY, M.D.,

PHILADELPHIA, PENN.

S. D., a married woman aged 58, was brought to me first in the early part of November, 1899, with an attack of acute dacryocystitis of the right side, the attack being the third within a few months. The abscess was opened and treated in the usual manner, healing taking place in about ten days with a patent duct and no fistula, Bowman's probe number 7 being easily passed. The patient lived in a sparsely-populated district, eight miles from the nearest physician, the latter being obliged to ride this distance in order to render his services. He was instructed

in the use of the lachrymal syringe and advised to keep the duct patent and frequently cleansed.

The patient was of an exceedingly neurotic temperament, a condition that seemed to be hereditary, and that had affected all the female members of the family alike. There was a vague history of another member having had some inflammatory condition similarly situated, that was finally pronounced to have been cancer.

Five weeks from the time the patient was first seen she presented herself, with another attack even more severe than the first, and as she refused to remain in the city for treatment longer than a few days, after the acute symptoms had subsided, a silver canula was inserted into the duct. At her urgent request the physician was again instructed as to the method of removing the canula and cleansing the duct, and she was advised to come to see me again in two weeks. This she did and the canula was found in place, the symptoms having subsided, and the fistula healed; but when she next reported, at the expiration of another two weeks, the lower end of the canula was found in the upper portion of the nasal cavity, having been forced through the lachrymal bone. Drainage was naturally imperfect and there were symptoms of the formation of another abscess, the secretions being dammed up in the sac and nasal duct, it being impossible to effect an opening into the nose. Considering the distance of the patient from medical aid, the fact that she had suffered from several attacks and that she absolutely refused to remain in the city for a sufficient length of time to allow me to treat the duct until it was well, it was advised that she have the lachrymal sac and gland extirpated.

This was done on the following day under ether anæsthesia without any complication, the method advocated by Holmes[1] being closely followed. The nose had been sprayed several times with a 1-2000 solution of potassium permanganate, and the lower nasal meatus plugged to prevent hemorrhage from passing into the throat. A slightly curved incision was made

[1] C. R. Holmes.—Extirpation of the Lachrymal Sac and Gland. *Archives of Ophthal.*, Vol. xxviii, No. 1, 1899.

over the lachrymal sac in the natural line of the face, and when the sac was exposed it was so bound down by adhesions that it could not be dissected out as a whole, but came away piecemeal. What remained was carefully removed with the curette, the next step being to obliterate the nasal duct. For this purpose Skeel's chalazion curette was found most admirable, it being small enough to pass into all portions of the canal. The wound was then closed with deep and superficial sutures. The incision for the removal of the gland was made just beneath the eyebrow on a line corresponding to and following the outer third of the orbital margin. The gland was reached without difficulty, and with very little hemorrhage, and the larger lobe removed by careful dissection. This wound was also closed by deep and superficial sutures. On the second day after the operation, when the dressings were first removed, some drooping of the upper lid was observed. On the fourth day half the sutures were removed, and on the fifth day the remaining half, the dressings being discarded.

On the eighth day following the operation, after the lid had regained about half of its lost movement, the lips of the wounds had firmly united and the sites of the incisions were indicated only by two narrow lines, the patient complained of intense pain in the eye, which was accompanied by some conjunctival secretion. Inspection of the cornea did not at this time reveal anything abnormal, so far as could be seen, but on the following day, the ninth since the operation, there was a severe membranous conjunctivitis in both eyes, the membrane peeling off easily and leaving a smooth, not unusually red surface beneath. The cornea of the right eye was slightly abraded near the center and considerably roughened, as if sprinkled with some coarse substance, staining readily with fluorescin, the edges of the abrasion being rough as if a bulla had broken and the edges curled. There was no anæsthesia of the cornea, conjunctiva, or surrounding parts. Hot and cold compresses and frequent irrigations were employed, but with little benefit, so far as the reduction of the membrane was concerned, the latter reforming within an hour after being removed. Bacteriological examination of the latter showed

only the diplococcus of Fraenkel in small numbers. Frequent irrigations, hot fomentations, and the internal administration of stimulating treatment were kept up constantly. The site of the abraded portion of the cornea would shift from day to day, but at no time was the epithelium completely reformed. At the time this was supposed to be due to the fact that bullæ had formed and broken, but at no time did we see a bulla before breaking, if such were present.

On the fifth day after the beginning of the above series of symptoms, the roughened epithelium occupied about two-thirds of the corneal surface, and the latter was becoming quite hazy, especially in the lower inner quadrant. With the loupe, the deeper portion of the cornea, probably Descemet's membrane, was seen thrown into folds, forming the so-called panel figure described by Schirmer, by the crossing of the lines of the folds, this being much more marked in the most hazy portion of the cornea, and probably due to the unequal swelling of the latter. A little later the anterior portion of the corneal tissue became involved and there appeared numerous minute lines, some straight and others branching, and while these were more marked near the center of the lower inner quadrant, that is, the most hazy portion of the cornea, they were also present in all the quadrants. A narrow strip of the cornea about 1½ mm. wide in the periphery seemed unaffected. These fine lines continued to increase in number and to cross each other in such a manner as to give the appearance of a lattice work, the openings between the lines not being perfectly regular, but imperfectly representing different geometrical figures, as irregular parallelograms, rhomboids, triangles, etc. This series of lines were much narrower than the deeper ones first described, and undoubtedly lie in the anterior portion of the cornea, so it is believed they were probably in Bowman's membrane. Additional evidence of their position was given by the appearance of a number of small but distinct spots of cloudiness here and there, about the same level, and beneath these the epithelium became more rough and a larger surface involved. With direct illumination the lines and spots appeared black, but with indirect illumination and the use of the loupe

they appeared grayish. It was thought at times that some of the lines and dots were translucent. The epithelium was so roughened that it was impossible to determine whether or not it was elevated at the site of each of the larger punctate spots.

The cornea was now partially anæsthetic, it being the thirteenth day since the operation. The membrane had entirely disappeared from the left eye, but was still forming in the right. Treatment was continued for several days along the lines mentioned, before the membrane entirely disappeared, the cornea becoming slowly more hazy all the time. The eye was now covered with a watch crystal for a couple of days, but the latter seemed to produce so much irritation of the skin by retaining the moisture, without, so far as could be seen, being of any benefit to the cornea, that it was removed and protective goggles substituted. The whole cornea and a part of the conjunctiva immediately surrounding it were now anæsthetic, and the former was still roughened, partially abraded, and quite hazy. The pupil dilated only moderately under atropin and the intraocular tension was always normal.

It was about this time that Dr. G. E. de Schweinitz, who had seen the patient with me, suggested the possibility of thyroid extract being of some use. Its administration was therefore begun, and whether on account of the medicament or as a coincidence, I do not know, but certain it is that from the second day of its administration the eye began to improve. Within seventy-two hours after the first dose the corneal sensation had partially returned and the cornea had become much clearer. The patient, who was markedly neurotic, had also grown more cheerful and her general expression was better. She was now sent to her home in the country, under the care of her trained nurse, with the hope that the familiar surroundings, together with the fresh air, would help her neurotic condition and incidentally the eye. Unfortunately she was of such a temperament that she could not be persuaded to do anything she did not wish to do, and though we could not get her out of doors every day the eye continued to improve and in a few weeks there was noticeable only a slight nebulous-like haze

in the lower inner quadrant of the cornea, no peeling of the corneal epithelium, and normal vision.

An examination made three weeks ago showed a slight haziness about 3½ mm. in diameter near the center of the lower inner quadrant, out of the line of direct vision. The lattice-like appearance of the superficial lines could still be observed, the deeper lines having entirely disappeared, and over the nebulous portion there was still partial anæsthesia of the cornea.

In 1890 Biber* described a form of bullous keratitis following superficial abrasions of the corneal epithelium occurring some time after an injury, that usually recurred for a long time with slight inflammatory symptoms, but finally ended in permanent recovery with but little, if any, corneal opacity.

In the same paper he describes a variety of keratitis which he has termed "lattice-like," in which there have been numerous fine lines in the superficial portions of the cornea crossing each other so as to resemble lattice-work, accompanied by many small opaque spots, at the site of each of which the epithelium was elevated, the latter being also more or less roughened and later abraded and anæsthetic. It was usually found in several members of the same family affecting both eyes and terminated badly as regards the integrity of the cornea and vision. Cases of this character have also been recently reported by Haab† and Dimmer.‡

There has also been described a condition in which numerous lines crossed each other in the deeper layers of the cornea, forming a sort of panel figure, and which were first supposed to be due to dilated lymph channels or infiltration of large nerve canals, but were afterward found to be due to a folding of Descemet's membrane (Hess, Schirmer) on account of a shrinking of the corneal tissue in cicatrization or to its unequal swelling in infiltration.

The case reported by myself seems to have possessed the

* Biber.— Inaug. Dissert. Zurich, 1890.

† Haab.— Die gitterige keratitis. *Zeitschrift für Augenheilk.*, Sept., 1899.

‡ Dimmer.— Ueber oberflächliche gitterige Hornhauttrübung. *Zeitschrift für Augenheilk.*, Oct., 1899.

symptoms of all three of these conditions. Whether they were produced in my case by some injury to the corneal epithelium or by injury to some portion of the trigeminius it is impossible to say, though a careful study of the manner in which the symptoms presented themselves and the later progress of the case would seem to indicate the latter. Whether there was direct injury to some portion of the fifth nerve, or whether the corneal condition was produced by an irritation is another interesting question impossible to determine.

The literature of the pathology of trophic keratitis has been recently reviewed by Harlan*, from whom I quote the following:

"The corneal lesions which follow section of the fifth nerve, or its paralysis from other cause, were formerly attributed to the loss of the trophic influence of this nerve, but since Snellen and Buttner reported that in their experiments on rabbits these lesions did not occur if the eye was protected, they have been quite generally attributed, at least in the text-books, to loss of sensation of the cornea and its consequent injury by external irritants. Numberless clinical cases have been recorded, and we have all met with such, which would prove this contention most satisfactorily, if there were not others which, if less numerous, are equally positive on the other side of the question and can be better explained by recourse to the older theory. They are too numerous also to be set aside as exceptions, and I have seen enough of them myself to make me quite sure, while still in doubt as to the true pathology of the disease, that the mechanical theory is insufficient."

My own case seems to belong to that class in which the mechanical theory must be excluded, because the anæsthesia did not present itself until some time after the corneal disease had been established; in addition, instead of securing improvement of the corneal disease by protection, for example, with the bandage and later with the watch crystal, the condition gradually became worse. I am, therefore, inclined to the belief that the affection was produced by some disturbance of the trophic nerves of

* Harlan, G. C.—Trophic keratitis, etc. *Trans. Amer. Ophthal. Soc.*, 1897, p. 107.

the cornea; but the question as to whether there are a special set of trophic nerves, or whether it is a part of the function of the trigeminius to exert trophic influence over the cornea, and also as to whether the lesion was irritative or paralytic must remain undetermined.

AN OPACITY OF THE POST CAPSULE OF THE LENS DUE TO THE REMAINS OF THE MEMBRANA VASCULOSA LENTIS.

BY A. G. THOMSON, M.D.,

PHILADELPHIA, PENN.

I present this case before the meeting as one of the interesting congenital anomalies that are found in the eye; and especially so as it differs considerably from the ordinary anomalies of the fœtal vascular system, more frequently seen, as the ordinary posterior polar cataract and retained pupillary membrane.

It is also extraordinary that from the amount of opacity in the lens the vision is so remarkably good and that the patient has never been conscious of its existence before.

The vascular capsule of the lens is formed between the second and third month of fœtal life by the hyaloid artery passing through the tissue which is after to be vitreous, reaching the posterior surface of the lens, branching out over its posterior surface, curving over the edge of the lens, and finally covering the anterior surface. The vascular capsule reaches its greatest development at the seventh month of pregnancy, and then begins to degenerate, finally disappearing at the end of gestation or the first few months of life.

DeBeck, in his monograph on the Persistent Hyaloid Artery, states that the remains of the vascular capsule of the lens are exceedingly rare, or the cases are not sufficiently reported. In his excellent monograph in the classification of cases collected, he gives two subdivisions under which this case may be included:

"Striæ of the posterior capsule of the lens" and "posterior capsular cataract."

OPACITY OF POSTERIOR CAPSULE OF LENS.

It differs from the class of cases he has collected under the head of Striæ of the Posterior Capsule of Lens; as we follow the opacity from the center to the periphery of the lens we find it widening out to five or six diameters of that at the central portion, and ending in a dense, thick membrane, showing that the opacity is due to capsule rather than to the presence of the obliterated vessels of the lens capsule. It may be more properly classified as a post-capsular cataract.

M. Treacher Collins, in his paper on Pseudo-glioma, Royal London Oph. Hospital Reports, Vol. XIII, 1891-93, reports the enucleation of four cases for glioma, due to thickening of fibro-vascular capsule. Three of the cases still retain the hyaloid artery. The case I report has no evidence of it, whatsoever. The history of the case is as follows:

The patient, a man and teacher of 40 years of age, presented himself at Wills Hospital in the early part of March, complaining only of poor vision for distance, he having been myopic all his life, with the usual gradual increase during the past twenty years. He had no asthenopia, being able to do all near work required in his profession without trouble. His vision equaled 2/60 in each eye, and external examination showed that pupil reacted normally and outer aspect of eyeball was practically normal.

O. D. ophthalmoscopic examination showed media perfectly clear. The disc was of good color; no conus, and fundus normal. Fundus better than ordinarily seen with 5° myopia. Not the slightest appearance of any fœtal remains of the hyaloid artery on the disc.

O. S. pupil reacting normally. With plus 6 D. a large linear opacity of the lens extending directly across the center of the pupil, corresponding to the size of an ordinary retinal artery as it emerges from the disc; the lens and its capsule otherwise clear. On closer examination I found the opacity to be strictly confined to the posterior capsule of the lens, with the shape as seen in the diagram.

In looking straight with the ophthalmoscope there is a linear opacity, and as it passes from the center to the periphery it be-

comes gradually enlarged to five or six times the diameter to that at the center of the pupil, making a large club-shaped extremity turning down, but not extending as far as the edge of the lens. The opacity is apparently very dense. There is no opacity in the vitreous, and positively no evidence of a persistent hyaloid artery. M. 5 D. disc and fundus are normal.

With oblique illumination and a dilated pupil the opacity is seen in its entirety, giving a sort of reddish brown color, resembling pigmented tissue of the uvea, and shape as seen in diagram.

The patient has never during his life been conscious of this opacity, and is not at present, having with his correction 5^s 6/6.

I found the patient had consulted a physician twenty years ago, and, being in a great hurry, simply had a correction prescribed, being —250 D., and no ophthalmoscopic examination made. He also came to the Wills Hospital ten years ago. The ophthalmic examination was meager, showing patient had a linear opacity traversing horizontally the lens, and, as he could not give the time then to have a mydriatic used in his eye, he never returned.

The entoptic image of the opacity is quite marked, the patient looking through a 14^s at point of light, giving a large circle of diffusion, which was almost entirely filled, the dark patches of different intensity. He describes it as looking like a head with mortar-board cap, which represents and corresponds to the opacity on nasal side.

The case is interesting and differs from the large majority of cases of this character, as the opacity is so great, and there is absolutely no other evidence in the eye of the other portion of the fœtal vascular system remaining.

Also as the opacity runs directly across the center of the pupil, and the entoptic image is so large, there is no interference with the vision.

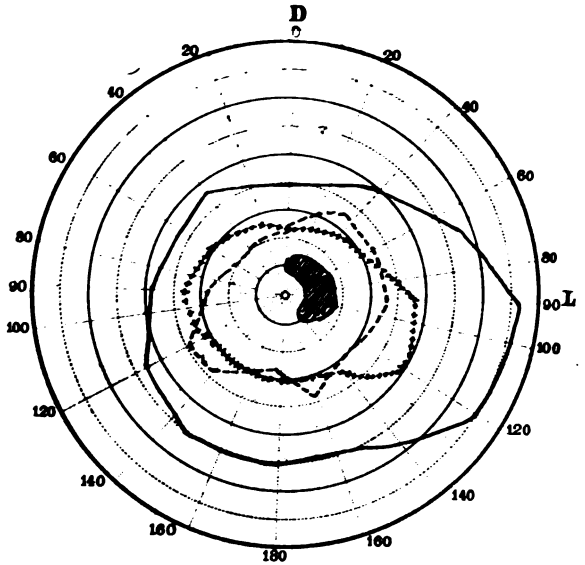

FIG. I.

Right Eye—H. C.
Visual fields taken Feb. 1[illegible], 1900.
Object, 5 mm. square.

White ——
Red xxxxxx
Green - - - -
Scotoma

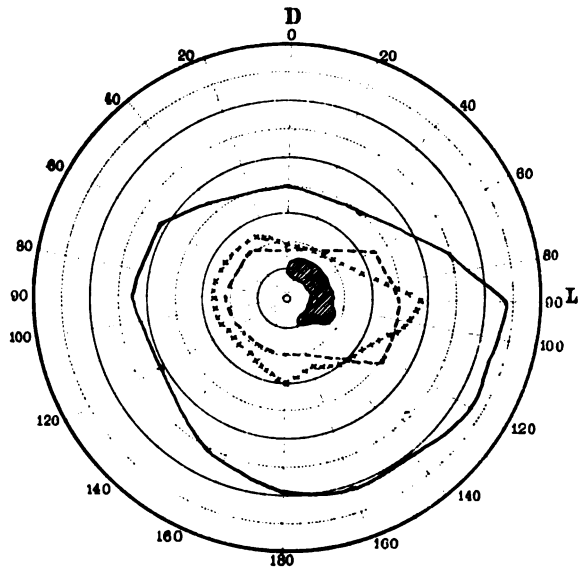

FIG. II.

Right Eye—H. C.
Visual fields taken April 21, 1900.
Object, 5 mm. square.

White ——
Red xxxxxx
Green - - - -
Scotoma

TWO UNUSUAL CASES OF CHOROIDAL DISEASE.

BY WILLIAM H. WILDER, M.D.,

CHICAGO, ILL.

The following cases presented such unusual features of interest that they seemed worthy of record:

CASE I. H. C., a well-developed, healthy country boy of 17 years, came to my service at the Illinois Eye and Ear Infirmary, October 21, 1899, with the statement that thirteen days previously he noticed that the sight of the right eye had suddenly become impaired, and that it was gradually growing worse. The trouble with the vision was first noticed when shooting a gun, and as this had been a constant pastime, he could fix quite accurately the date of the onset. His parents are living and healthy, his brothers and sisters are well, and, so far as he knows, there is no history of any malignant disease or tuberculosis in his family. Except an attack of measles in infancy, and mumps one year ago, he has always been in perfect health, and he denies the possibility of acquired syphilis, and presents no sign of congenital disease. Externally the eye appears perfectly normal. L. V. 20/20, R. V. 10/200 without mydriatic. Ophthalmoscopic examination showed the media perfectly clear. The right optic disc was normal, but was surrounded by a zone of degeneration of the choroid in which the sclerotic was exposed. Below and external to the optic disc was seen a small swelling, seemingly in the choroid and about the size of the disc. The nasal branch of the inferior retinal vein and artery passed over it, and its apex could be distintly seen with a +6.00 D. lens, while the retina was in focus with +1.00 D. It was grayish in color, and deeply shaded with pigment on its lower slope. Several minute hemorrhages, choroidal and retinal, were seen in the vicinity, directly below and a little to the inner side of the optic disc. When

he was first seen the yellow spot region varied little from normal, but later there were distinct evidences of change in this part, as shown in the illustrations presented. I wish here to express my indebtedness to my friend, Dr. Chas. H. Beard of Chicago, for the excellent and faithful reproduction of the appearance of the fundus in this and the succeeding case. The drawing, Plate I, was made about November 20, 1899, and at this time some of the pigment that showed so prominently in the little mass had been absorbed and some of the hemorrhage had disappeared. A few days after his admission there were seen numerous parallel narrow red lines running outwardly from the inferior border of the optic disc. The patient was ordered ten grains of potassium iodide three times a day and the eye protected from light; there was a suspicion that we had to deal with a melanotic sarcoma of the choroid. Repeated examination of the urine showed no melanin. The visual field for white seemed somewhat contracted, and a marked scotoma continuous with the blind spot was observed. This, however, did not correspond with the tumor, but represented that part of the retina below and to the inner side of the optic disc. Gradually a change occurred in the appearance of the tumor; the pigment that was so abundant in the lower part seemed to be absorbed, and at the same time the small hemorrhagic spots below the optic disc began to disappear. Several weeks after his admission, minute yellowish spots were seen in the region of the macula lutea, but notwithstanding these the central vision began to improve.

November 26, 1899, R. V. 14/200.

December 9, 1899, R. V. 20/200.

December 17, 1899, R. V. 20/80.

The tumor seemed to be shrinking slightly; the apex could be seen with Sph. +5.00 D. The last drawing was made April 20th, and represented the condition at the time the patient left the hospital. His central vision had then improved to 20/30, but the absolute scotoma continuous with the blind spot remained as before, and there was a similar contraction and overlapping of the fields. (See Figs. I, II, III.)

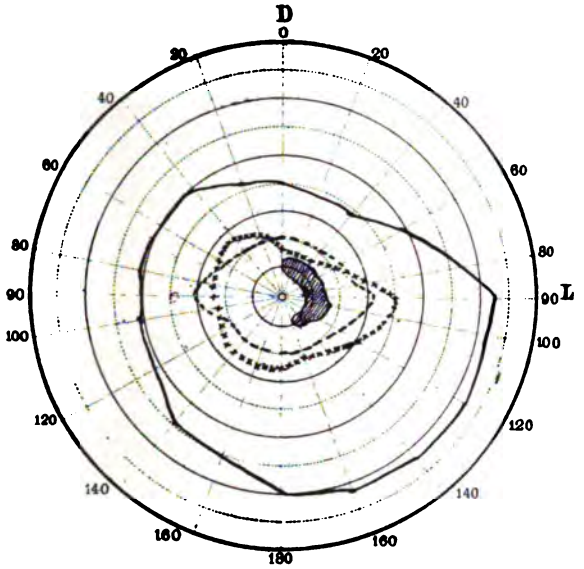

FIG. III.

Right Eye—H. C.
Visual fields taken April 23, 1900.

White ——
Red xxxxxx
Green - - - -
Scotoma

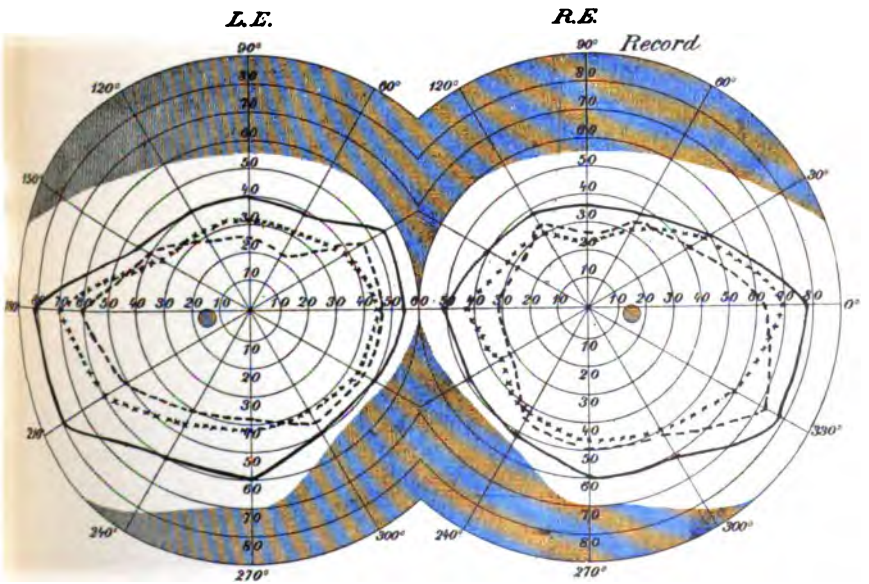

FIG. IV.

Visual fields of B. J. B., Feb. 12, 1900.
R. V. = 20/80 L. V. = 20/80
Case No. II. Object, 5 mm. square.

White ——
Red xxxxxx
Green - - - -

CASE II. B. J. B., a young man 23 years of age, came to the Illinois Eye and Ear Infirmary, August 15, 1899. He stated that his sight was formerly perfect but began to fail three years before the time of his visit, and at that time he had slight headache over the left eye. Some months later he was troubled with severe headaches, which were relieved by general treatment. His family history is excellent, his father and mother and all his brothers and sisters being in good health. His own health has always been good, and there is no history or sign of syphilis or rheumatism. There was no external evidence of disease of the eyes. R. V. = 20/160. L. V. = 20/200. No marked improvement with glasses. Objective examination of the refraction showed very slight hypermetropia, not more than 0.25 D. Ophthalmoscopic examination (Plate II): Scattered around the macular region of both eyes were seen yellowish spots, with a peculiar greenish tinge, apparently about two or three mm. in diameter, situated in the choroid. At one point a retinal vessel was seen passing directly over one of these spots which did not seem to cause any prominence or elevation in the choroid. In the right eye the spots were bunched like grapes. This patient's visual fields also presented unusual features. The field for white was somewhat contracted, but the green field in several places overlapped the red and even extended to the limits of the white. (See Fig. 4.) There was no metamorphopsia. He received treatment with small doses of calomel for two months, then he had potassium iodide in twenty-grain doses three times daily for one month, after which he was given tonic doses of iron, quinine, and strychnia. He remained under observation for seven months, at the end of which time he was dismissed with R. V. 20/80, L. V. 15/80, as against R. V. 20/160, L. V. 20/200 at the time of admission.

The condition of the fundus remained practically the same, and all other parts of the fundus seemed in every way normal.

A CASE OF ACUTE DOUBLE RETROBULBAR OPTIC NEURITIS, HEREDITARY IN ORIGIN.

BY HOWARD F. HANSELL, M.D.,

PHILADELPHIA, PENN.

The affection of the optic nerves, characterized by the loss of central vision, usually rapid, without contraction of the peripheric field and unattended by pain, headache, or disturbance of the nervous system and without other assignable cause than heredity, has been fully described by Leber, Habershon, Norris, Nettleship, Posey, and others under the titles of medullary neuritis, axial neuritis, retrobulbar neuritis, and hereditary optic nerve atrophy. The designation "hereditary axial neuritis" would seem to be correct since it calls attention to the principal features of the affection, namely, its origin in heredity and its site in the axial fibers. Moreover, it is essentially an inflammation, followed by atrophy. It attacks several members of a family, notably the males, and has been traced through four generations. Families with neurotic tendencies, such as epilepsy and insanity, furnish, according to Leber, more cases than families in which no such tendency exists.

CASE. S. W., aged 56, was brought by Dr. Umstad of Phœnixville to the Jefferson Medical College Hospital, December 15, 1899. On the morning of the previous day he discovered, upon attempting to leave his bed, that he was nearly blind. He had retired in his usual health and sight and his rest had not been disturbed during the night. He could offer no explanation of the disaster that had overtaken him. He made no complaint of pain or headache preceding or accompanying the blindness, had received no injury, taken no medicine, had had no hemorrhages, and showed no signs of disturbances of the general health.

The ophthalmoscope revealed a low grade of optic neuritis

with swelling not exceeding one diopter. The veins were tortuous and distended, and the arteries slightly contracted. No patches of exudation in or other abnormality of the retina or choroid could be found. The fields of vision were not contracted except at the center, where each eye had a positive absolute scotoma. White and colors were not recognized in a small area — between 5 and 10 degrees — surrounding the fixation point. The pupils were moderately dilated, but responsive to light and accommodation. V. R. and L. 10/200 excentric. There was no history of hereditary or acquired syphilis or signs of nephritis. Mr. W. had for years smoked one or two cigars daily and drank very little or nothing. He had never previously complained of his eyes except upon one occasion, 16 years before; after prolonged near use he stated that he had lost the power of reading in one night. As this difficulty was repaired by glasses, the loss of vision was probably physiologic.

The origin in heredity is based upon the following family history: Several of his aunts and uncles on his mother's side became nearly blind in adult life; father and mother preserved their vision until old age; his oldest brother, a physician, had sunstroke at 35 years of age and in two years was almost blind; at the age of 60 he is still living and has preserved a small amount of vision; another brother, a farmer, lost his sight suddenly at the age of 50 while working in the field, and to-day is in the same condition as the eldest brother. From the data at my command, supplied by the patient and by Dr. Umstad, I infer that all these members of the family had the same affection as my patient, acute double retrobulbar hereditary neuritis, followed by atrophy.

Examination of the nose and throat by Dr. W. A. Freeman showed a healthy condition of the mucous membrane and of all the cavities excepting the left antrum, through which strong electric light could not be transmitted, indicating the presence of a tumor or a thickening of the osseous walls. Excepting the well-known relation between disease of the air cavities of the head to optic nerve affections there is no reason to believe that

the antrum affection had, in this case, any causative connection with the optic neuritis.

The etiology is obscure. The only possible exciting cause was repeated exposure to cold during the six weeks preceding the attack, while the patient was superintending the erection and furnishing of a large building and was compelled to remain for several hours each day in the unheated and damp structure.

There seems to be little doubt as to the correctness of the diagnosis. Hysterical amblyopia may properly be excluded because of the patient's sex, history, age, equal pupils, and the ophthalmoscopic signs of neuritis. The symptoms bear little resemblance to those of tobacco and alcohol amblyopia where we have gradual decline of vision, contracted pupils, central scotoma for colors only, very slight or no changes in the papillæ until the stage of atrophy. Moreover there is always in such cases a history consistent with the diagnosis. In my case the diagnostic features are the family history, the acute onset, the absolute central scotoma, the optic neuritis that in a few weeks advanced to atrophy, the dilated pupils, the uselessness of mercurial inunctions carried to mild ptyalism, of sweating induced by hot baths and pilocarpin, of potassium iodid, and of strychnia.

Nettleship has contributed several able papers on the subject of retrobulbar neuritis, the most recent appearing in the Royal London Oph. Hosp. Rep., May, 1899. He defines it as an inflammation originating in the optic nerve itself or communicated to it by some of the tissues between the front of the brain and the eye, and, excepting symmetrical toxic amblyopias, he classifies the affection into idiopathic and symptomatic. According to his description of these varieties the case above described belongs to a third class, since it differs in several important particulars from Nettleship's cases. For example, both eyes were affected simultaneously in equal degree; while the onset might not have been sudden, it was acute and without pain; instead of recovery vision has grown progressively worse; the patient is 56 years old, and, therefore, beyond the period of greatest sexual activity. He has no venereal disease and is not an excessive

smoker. In only nine of Nettleship's cases was exposure to cold considered as a probable cause.

Leber (Archiv. f. Ophthal., Vol. XVII, 1871) tabulated 40 cases of other writers, and added 15 of his own, a total of 55 individuals from only 16 families. He believes that the pallor is the expression of atrophy of the optic nerve due to an increase of its connective tissue elements, even if the remains of an earlier inflammation are slight or doubtful.

Several papers have appeared since the publication of Leber's article, notably Fuchs (Klin. Monats. f. Augenh. 1879), Higgins (Med. Times & Gaz., 1880), and (Lancet, 1881), Story (Trans. Acad. Ireland, 1884), Norris (Trans. Amer. Ophthal. Soc., 1884), de Kaersmaecker (Rec. d'Ophtal., 1885), all of which are reviewed in Habershon's paper (Trans. Ophthal. Soc. Uni. King., 1888). The last author contributes several cases of his own and of Nettleship. He mentions as possible causes hereditary diseases of the nervous system, hereditary syphilis, sexual excesses, excessive smoking, syphilis, and exposure. Posey (Ann. of Ophthal., July, 1898) reports three cases, aged respectively 25, 41, and 61 years, that were similar in many respects to the case reported above, including the shape of his skull. Posey partly accepts Berger's theory in explanation that the disease is found principally in persons with the "tower-shaped" skulls, and is due to the encroachment of bone on the optic canal and sphenoid fissure consequent upon the change in form of the sphenoid bone in advancing years.

The most recent contribution to the literature is the monograph of Vossius (Sammlung Zwangloser Abhandlungen; Aus der Gebiete die Augenheilkunde III Bd. Hft. 6, 1900), in which will be found a review of the cases hitherto reported and a consideration of the various theories of causation. Appended is a valuable list of references.

HOMONYMOUS SIMILAR SECTOR DEFECTS IN THE VISUAL FIELDS, WITH PROBABLY A CENTRAL CAUSE.

BY SWAN M. BURNETT, M.D., PH.D.,

WASHINGTON, D. C.

Sector defects in the visual field, not dependent upon intra-ocular disease, are rare, even when confined to one eye. It is exceedingly uncommon to meet with them simultaneously in the two eyes, of a homonymous and similar character. When they do thus occur they are chiefly interesting on account of the location of the lesion. The history of the following case is submitted as a clinical contribution to the further study of the subject, and as probably throwing some light upon the arrangement of the visual center in the brain.

Miss Sallie E. W., a woman of 38, returned from a rather fatiguing journey to the Pacific slope, whither she had been sent on account of a run-down condition of her system, in the latter part of August, 1899. On the evening of the 27th she was visiting some friends, and before leaving took a glass of beer, as it was her habit to do occasionally. Soon after leaving the house she was seized with nausea and vomiting, and a blindness on the left side. She is rather inclined to think that the blindness came first. She was very dizzy and reached her home with some difficulty. She continued ill during the night, and suffered with pains down the back of the neck. This pain continued with greater or less severity for a week or ten days. I saw her first on the morning of the 30th of August, and she was then laboring under great excitement and worry as to the condition of her vision. For a number of years she had had from time to time transient attacks of complete blindness lasting for a few seconds, and as this attack had continued for some days her fear as to its

permanency was great. Her central vision with her correcting glasses, given by Dr. Wilmer some time ago, was normal. An examination of the visual fields with a white square of 2 mm. gave charts as shown in Fig. 1. There was no paralysis of motion or sensation indicating the implication of any of the cerebral nerves, aside from that of vision. Speech was unaffected.

Five years ago she had what was called a neuritis of the right leg, which was very obstinate in healing. The fundi of both eyes showed no departure from the normal. Palliatives were ordered and she was carefully watched for further developments. The next day she was but little better as to her general condition, her nervous excitement being rather increased on account of the continuance of the "blind spot," which she was apprehensive might become total and permanent, particularly as last night she had another attack of total obscuration lasting for nearly a minute. Her walking is still uncertain, though there is no pronounced staggering. On September 1st another careful survey of the fields was made and is recorded in Fig. 2. This shows a considerable shrinking of the dark sectors, and it will be noted that the shrinkage is the same in the two eyes. Thinking that there might be some hysteria at the basis or as a complication of the condition, I had Dr. E. L. Tompkins of this city see her with me on the 7th. His thorough examination threw no certain light upon the origin of the trouble, though a central lesion was decided upon as the more probable. Urinalysis had shown the urine to be free. The fields again examined showed no departure from those in Fig. 2 that could not be easily referred to errors in observation or record. She was put upon the syrup of the iodide of iron. Her general symptoms gradually improved, but no marked changes were noted in the field charts except a very gradual shrinkage of the blind spaces. On the 22d of September the fields for color were taken and the charts are represented in Fig. 3. She was now able to resume her regular work. The fundi at that time showed no change from the normal. I saw her no more until April 1, 1900, when the charts shown in Fig. 4 were taken. It will be

observed by comparing these with Figs. 1 and 2 that there is a very pronounced shrinking of the blank spaces, the upper quadrant being entirely free. It will also be observed that the shrinkage has been identical in the two eyes. Her general health is now fully restored. No abnormal change noted in the disk or fundus.

It will be seen from an inspection of the two charts taken at any one time superposed on each other that the defect in the homonymous fields approximately cover each other, and so nearly are they identical that we may justly conclude that any variation is due to an error on the part of the observer or recorder. Such perfect identity it is hardly possible to associate with a tract lesion. All investigations on the course of the optic nerve fibers have shown that while there may be some approach to symmetry or order in the relative position of the fibers coming from different portions of the retina while they are yet in the nerve trunk, or even in the chiasm, after the tracts are reached there is such a commingling that pressure on any limited area of one tract will not give anything like a symmetrical defect in the homonymous fields. Without, however, discussing the question further I will state that in my opinion the foregoing case is of interest as tending to corroborate, from a clinical standpoint, the theory of Henschen as to the arrangement of the visual center in the posterior occipital lobe. As is well known, he places the center of vision in the calcarine fissure, on which is spread out an internal retina, as it were, with points corresponding to identical points in the retinal halves of the eyes on the corresponding side. The upper or cuneal lip belongs to the dorsal quadrant, the lower or lingual lip to the ventral quadrant. The center for the macular region is on the anterior part of the floor of the fissure.

Applying the data in our case for elucidation by this scheme, the phenomena observed are very simply explained on the supposition of a hemorrhage in the upper cuneal lip which completely inhibited the right dorsal quadrant of both eyes. The pressure also extended across to the lingual lip and inhibited a portion of the right ventral quadrant of both eyes. It did not

RIGHT

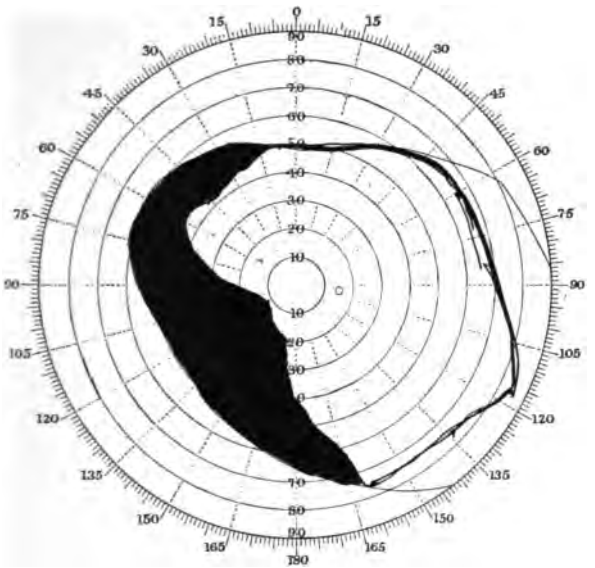

LEFT

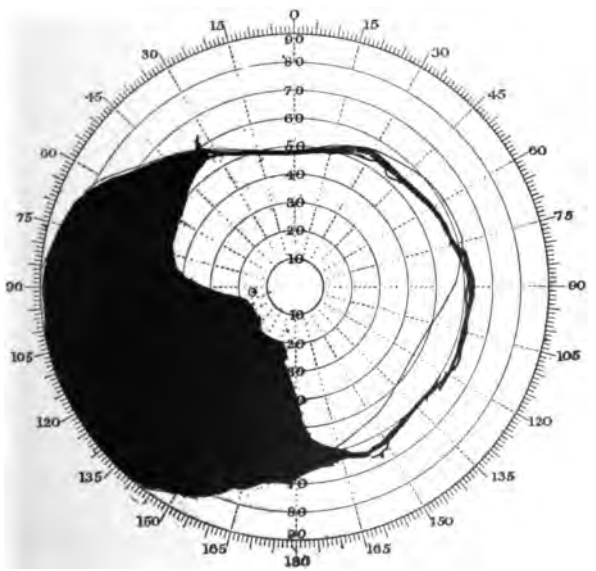

FIG. 1.
August 30, 1899.

RIGHT

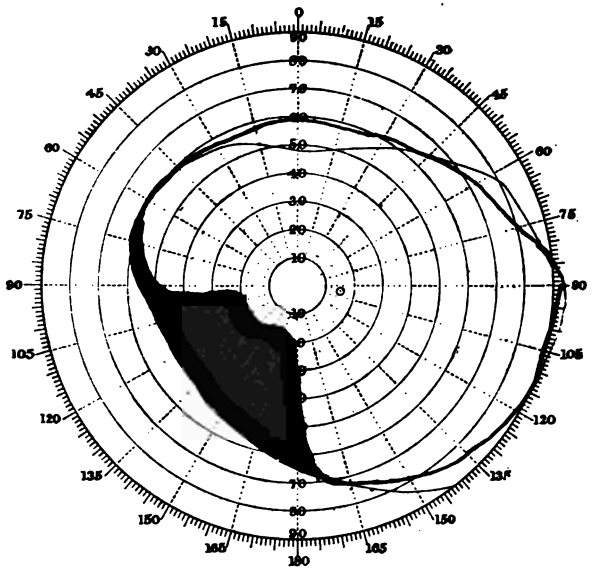

LEFT

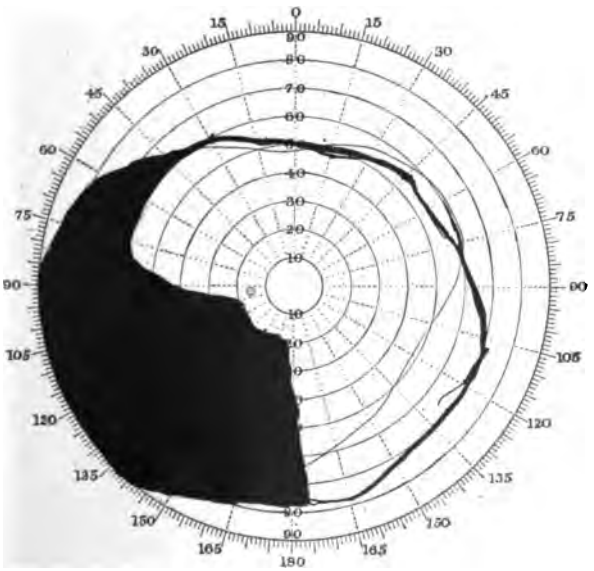

FIG. 2.
September 1, 1899.

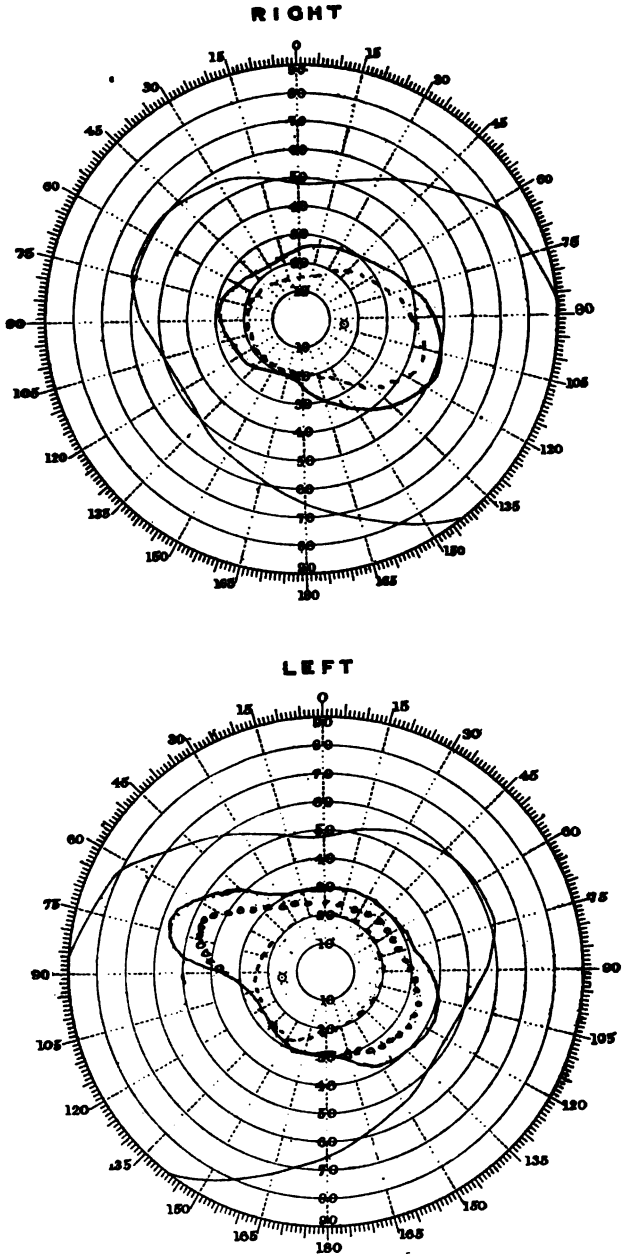

FIG. 3.
September 22, 1899.
_____ Blue and Red.
..... Green.

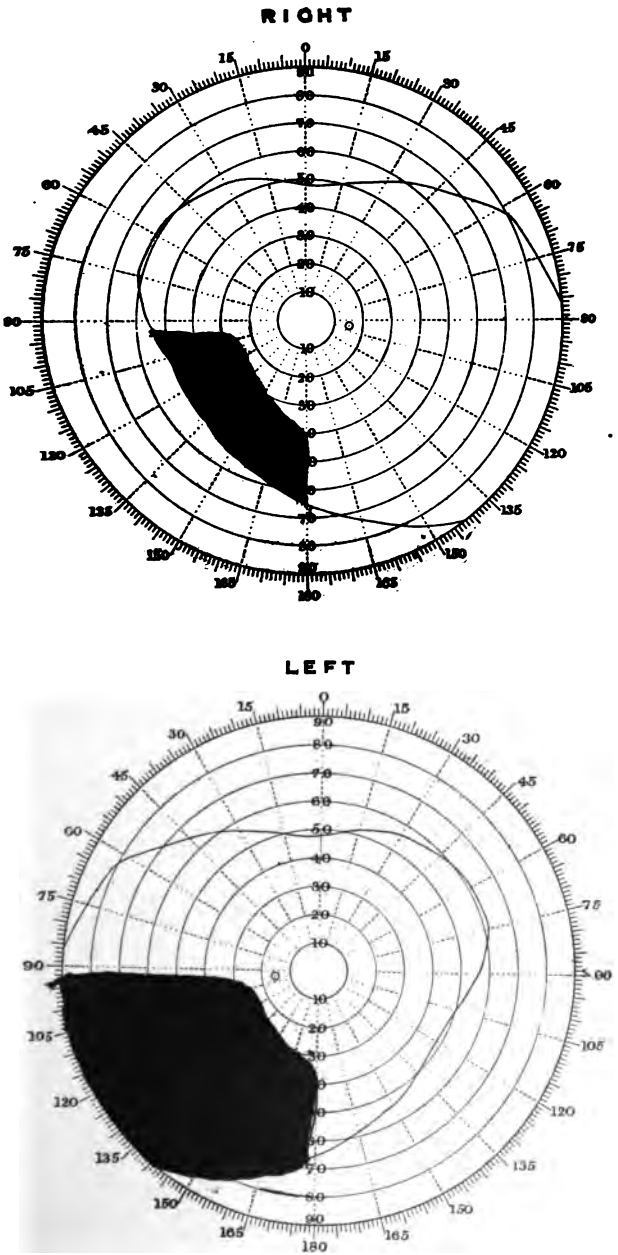

FIG. 4.
April 1, 1900.

extend far enough forward, however, to interfere seriously, if at all, with the macular center; though it would seem to be now generally agreed that there is a special provision of some kind which protects the central vision even in total destruction of a visual center on one side. The disturbance at first, no doubt, extended much beyond the locality of the hemorrhage, but these points regained their activity gradually, as manifested by the decrease in the size of the blank portion, even a few days after the onset of the trouble, as will be seen by comparing the fields taken on August 30th and September 1st. This contraction gradually progressing, but always symmetrical, till it reached its final stage on April 1, 1900, as shown in Fig. 4, would seem to indicate that the fibers from the two identical retinal points in each eye end either in the same or adjoining cells at the center. At the end of seven months, as will be seen by Fig. 4, the pressure on the lower lip had been entirely relieved and the ventral quadrant then fully restored to its function.

Attention should be called to the slight running over of the blind portion on the right side at the extreme lower part of both fields. This is most marked in the first charts, and might easily be attributed to an error in observation, owing to the extremely excited condition of the patient. It was much less in the fields taken two days later, and, it will be observed in the last chart taken, it nowhere passed the median line.

The color fields showed some departure from the normal in the way of irregular contraction, but it is interesting to note that all colors were perceived sharply up to the limits of the defect in the fields. Another feature of interest is that she was perfectly aware of the "blind spot" — indeed, distressingly so; whereas some authors have claimed that in central amaurosis the patient is as unconscious of the defect as we are ordinarily of Mariotte's blind spot.

DISCUSSION.

Dr. ALLYN. I believe it was in 1896 that I published in the Archives a case of Homonymous Hemianopsia. The fields con-

tracted to two pear-shape areas of healthy retina in each eye. The small ends of the pears included the yellow spot. The patient, after eight years, is in perfect physical health, but with no improvement in vision.

A CASE OF ALEXIA, MIND-BLINDNESS, ETC., WITH AUTOPSY.

BY E. E. JACK, M.D.,

BOSTON, MASS.

The patient was a rather thin, spare man, aged 63, whose general health, with the exception of chronic indigestion, had always been good. There had been some sickness, but it had no apparent bearing on his present condition. Up to a year ago he had been at work at his trade, wood-carving. It became necessary from lack of employment, etc., to turn to other things, and the change and the worry incident to it had a bad effect on him generally.

He consulted me first the 23d of last December, giving a history of failing vision for about one month, first noticed in reading the labels on boxes. V. O. D. — 5/20, V. O. S. — 5/27, the letters being slowly picked out. A correction of his H. did not seem to improve him. There was nothing in the test or in anything he or his wife said which led me to believe he could really see better. Fundi — both discs slightly red and hazy, but not abnormal; small spot of chorio-retinitis O. D. a short distance upward and to nasal side of macula. Fields normal, pupils normal. Inability to name colors. This latter fact, though the apparent color scotoma was not confined to the central region, suggested retro-bulbar trouble, and in the absence of any tobacco or alcoholic history the possibility of diabetes came to mind, and an examination for sugar was made later with negative result. I did not at this first visit suspect the real

trouble, no hint except that of a negative examination being got from either patient or his wife. At the second visit, three days later, correcting the H., I found that by pointing out letters at the first of the examination he could name a letter or two of much smaller type and that when after a moment or two he could not do this, he could roughly draw their shape. The power to do this also was quickly exhausted. These observations led to questions which showed the nature of his trouble.

He was unable to come to my office alone; he had no idea of the signs on the cars; former familiar streets were only partially or not at all recognized. There was evidently no difficulty in merely seeing letters, words, or objects. Later investigation brought out the following symptoms, which varied from time to time: with these I will give other negative ones, the two together making a more complete picture of the defects in question.

The patient could hear sounds of all kinds and recognize them, with one odd exception. He certainly on one occasion failed to interpret musical sounds. I asked him once if he knew the tune "Annie Rooney"; he did not; I then whistled it, still he did not know it. Immediately afterward I played on a small parlor organ a hymn of which he was particularly fond, and on asking what it was he slowly shook his head and said interrogatingly, "Annie Rooney"? A day or so later the same tune was recognized and awakened the sad memory of former failure. He understood spoken words. He could see letters, numbers, and words, printed and written, but he could not, except to a slight and variable extent, comprehend them. There was at all times an ability to recognize a few letters and figures and even words, and this not confined to any particular ones, but limited apparently by the exhaustion of his power. He could see objects, but there was an inability to a considerable extent to recognize them. Such objects as matches, a key, comb, napkin, photograph, etc., brought up no remembrance of similar previous ocular images. Other objects he evidently recognized, but could not find words to express the name or the idea vanished before he could put it into words. This inability to interpret objects

was not limited to those seen; when asked, he could not describe the schoolhouse across the way nor the arrangement of the streets, and this not due to lack of aural perception apparently. There was a variable inability to tell the use of objects, very often an absolute ignorance; *e. g.*, one day a key was held up, he could not tell what it was or its use, and when put into his hands he was helpless; an attempt to draw it on paper was also a failure. He once named a watch correctly and immediately afterward called a knife a watch; he could not tell its use, but could use it. A later examination showed less of this particular power even. In showing me the use of a small hand-mirror he took out a pencil and began to write on it; I think he had just been using a pencil. The use of a chair, stove, trousers, and money were unknown. His wife said that at times he did not recognize her, and that he made odd mistakes: trying to drink out of the sugar-bowl and salt-cellar, dipping his toast into the jelly tumbler instead of his coffee, and then eating without apparently noticing his mistake, and once mistaking his hat for his coat and trying to put it on over his arm. Hearing usually set him on the right track, touch sometimes failed: salt was readily recognized when tasted, though wholly unknown by sight. He could speak voluntarily for the most part well, but often forgetting words or stopping short, having the whole mental picture of what he wished to say vanish. He had spells of wandering off in his talk to the scenes of his past life, applying them to the present. He could not speak words, read, *i. e.*, he could not read aloud. Here again some modification of statement must be made, though a few letters or figures and a word or two were all he was at any time able to recognize. He could write voluntarily a little. The best example of this is shown on the paper dated January 23d, when he wrote his own name and recognized it afterward. The power of writing to dictation was limited in about the same way; the extent of his success is shown on the papers. He could not do transfer copying, *i. e.*, he could not turn writing into printing and vice versa. He could not give the names to the more ordinary colors, but there was not true

color blindness, though matching the worsteds was done very slowly.

After the second visit to my office the patient was too weak to make the rather long journey to the city. The only symptoms developed other than those mentioned were a lack of appetite, frontal headache spreading over the parietal region to the occiput, not severe, and variable, and some vomiting. The importance of this last symptom was doubtful, because of its following closely the taking of KI and because of its cessation soon after stopping the drug, the same process being repeated on taking up the iodide again. In about three or four weeks the patient took to his bed and did not again, except for a few days, leave it. At this time there was an increase of the localizing symptoms. He was uncomplaining, but the presence of pain was evident by his putting his hands to the forehead. There was, too, some soreness or pain on dragging the head on the pillow, in the left parieto-occipital region, but in all probability it was not at any time severe. In the latter days there was more vomiting and this without relation to any medicine. I made no observations the last ten days of the patient's life, but up to that time there was no optic neuritis, and to within two weeks of death no well-defined hemianopsia. An examination by Dr. J. P. Conroy of Everett, who referred the case to me, showed a mitral regurgitant murmur and moderate arterial sclerosis.

The clinical diagnosis made was alexia and mind blindness, both partial and of the cortical variety, and amnesic color blindness. The lesion was thought to be thrombosis and softening, possibly tumor, and was placed on the left side (the patient being right-handed), at the region of the angular gyrus and in the occipital lobe, probably sparing the cuneus and calcarine fissure. The cortical situation of the lesion was inferred from the inability to write spontaneously or to dictation, for in pure word blindness with a sub-cortical lesion between the visual word center and optic centers (or, as some put it, between the visual word center and the center for speech-sound memory), the ability to do both these things is present. The mind blindness, too, was regarded as cortical, because, beside the difficulty in recog-

nizing by sight objects placed before him there was a like difficulty in picturing them to himself voluntarily or on questioning.

The autopsy and pathological investigation and report were made by Dr. George Burgess Magrath of the Harvard Medical School, to whom I wish to express my indebtedness.

"Cranium. — Upon removal of the calvarium the dura presents a condition of somewhat increased tension; it is adherent to the under surface of the left temporal lobe within an area 5 by 4 cm., situated a little posterior to the middle third of the lobe.

Dura mater. — Presents conditions above mentioned.

Sinuses. — Natural.

Pia mater. — Over the convexity of the brain presents a somewhat cloudy appearance, most marked over the sulci, along the course of the blood vessels. The sub-arachnoid tissues are slightly œdematous.

Brain. — Weight, 1,350 gms.; arteries of the base natural. The inferior aspect of the left temporal lobe presents an area of softening occupying its middle third; posterior to this, the dura mater is adherent to the brain within an area 4 by 5 cm. The lateral aspect of this lobe, opposite the region of the adhesion, presents within an area 3 cm. in diameter a somewhat gelatinous appearance, differing markedly from the surrounding brain substance. Upon section through the area of adhesion there presents a spherical mass 4 cm. in diameter, adherent to the dura mater, which, at the site of adherence is 0.3 cm. in thickness; distinct from the surrounding brain substance, from which it is defined by a thin zone of gray pultaceous material. The surface of section presents a nearly homogeneous appearance, yellow, mottled, with minute translucent areas. The extent of the mass is, backward to the ant. boundary of the left occipital lobe; forward from this posterior limit for a distance of 6 cm.; upward to the level of the first temporal convolution; inward to the collateral fissure. It involves the third temporal convolution in its most posterior part and the gyrus fusiformis. Anterior to the mass and extending somewhat deeper into the substance of the left occipital lobe, there is a region of softening apparent only

on the under surface of the brain. Upon section this region extends forward, externally to the descending horn of the left lateral ventricle, into the substance of the temporal lobe, and backward from the mass into the substance of the occipital lobe; the latter presents upon the surface of section an irregularly outlined area occupying for the most part the white matter, at one point extending into the gray matter (base of occipital lobe), the central part of which is yellow, soft, and similar to the surface of section of the mass, the outer part reddish-gray, continuous anteriorly with the circumscribed mass, extending upward to within 1 cm. of the surface of the first occipital convolution, downward and backward to the posterior border of the occipital lobe, and inward to within 3 cm. of the mesial surface of the occipital lobe.

The floor of the left lateral ventricle presents a grayish appearance, and is softened in places to the point of disappearance. The roof of this ventricle presents extensive softening, being represented by more or less gelatinous, pultaceous material. This softening involves the under surface of the hemisphere as far as the hippocampal gyrus.

MICROSCOPIC EXAMINATION.

For the purpose of microscopic study, pieces were taken from (1) the main mass of the tumor; (2) the white matter of the occipital lobe (softened); (3) the white matter of the anterior part of the temporal lobe (softened). These pieces were prepared for staining neuroglia by Mallory's method, cut in celloidin, and stained with phosphotungstic acid hæmatoxylin. Upon microscopic examination:

1. The main mass of the tumor presents along one side the dura very much thickened. The histological components of the mass are blood vessels and abundant cells; the blood vessels are fairly numerous, and many of them are of the capillary type, with thin walls and surrounded by a moderate amount of fibrous connective tissue. The cells are for the most part placed very closely together, in places they are less numerous than elsewhere.

The cells are medium sized and small, round, with deeply staining nuclei; between these cells there is a rich network of fine threads; in places this constitutes an open meshwork, elsewhere it contains large numbers of cells. Some of the cells are apparently fatty degenerated. There are some areas of necrosis.

2. The white matter of the occipital lobe presents an appearance very similar to that above described; in this region, between the cells in addition to the neuroglia fibers there is a certain amount of granular material; there is little or no evidence of normal brain structure present.

3. The white matter (softened) of the anterior portion of the temporal lobe presents the same appearances, the blood vessels constituting the only surviving elements of the normal structure.

Anatomical diagnosis: Glioma of the brain; localized softening of the brain."

It will be seen by referring to the pathological report and to the sections which I have made, that the angular gyrus is apparently not directly involved, though the greatest development of the tumor is in the same vertical lateral plane. It is to be supposed then that either the effect was produced by pressure, inhibition, etc., of the tumor or that an involvement of the fibers to and from this center would give the group of symptoms present; or further that the area in question is not the only one that has to do with the visual memory of words. To me, unaccustomed to deal with such brain problems, and, therefore, accepting the more readily the easier solution which the involvement of definite centers gives, the first of the suppositions seems the most probable. This seems to agree well also with the partial and variable nature of the symptoms. The connecting fibers must have been affected, however, and possibly a partial isolation of the visual word center from the optic, auditory perceptive, and graphic centers would account for the symptoms, but such is purely hypothetical, and has no basis of fact. It would be simpler and very likely nearer the truth, as Dr. J. J. Putnam has suggested to me, to abandon trying to make certain symptoms or groups of symptoms correspond with defects in

I.



CORONAL SECTION OF BRAIN IN CASE OF ALEXIA, ETC., SHOWING AFFECTED AREA.

II.

III.



IV.

V.

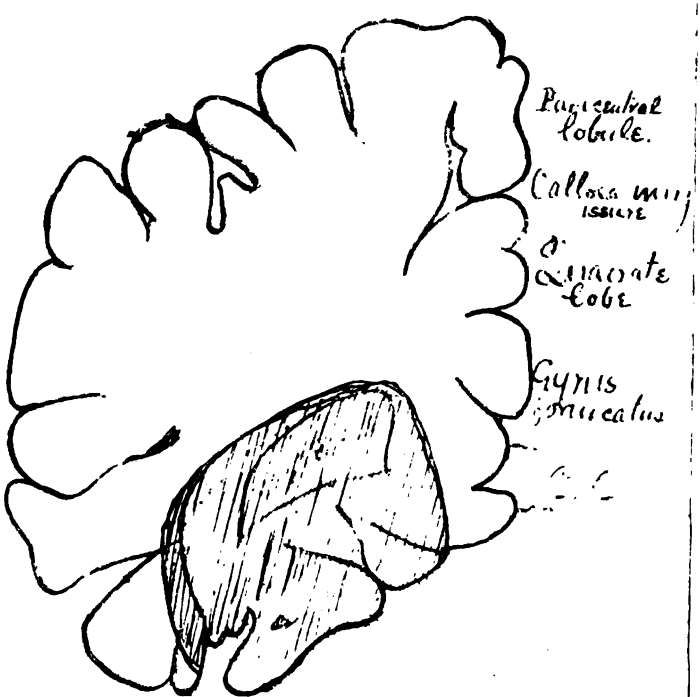

VI.

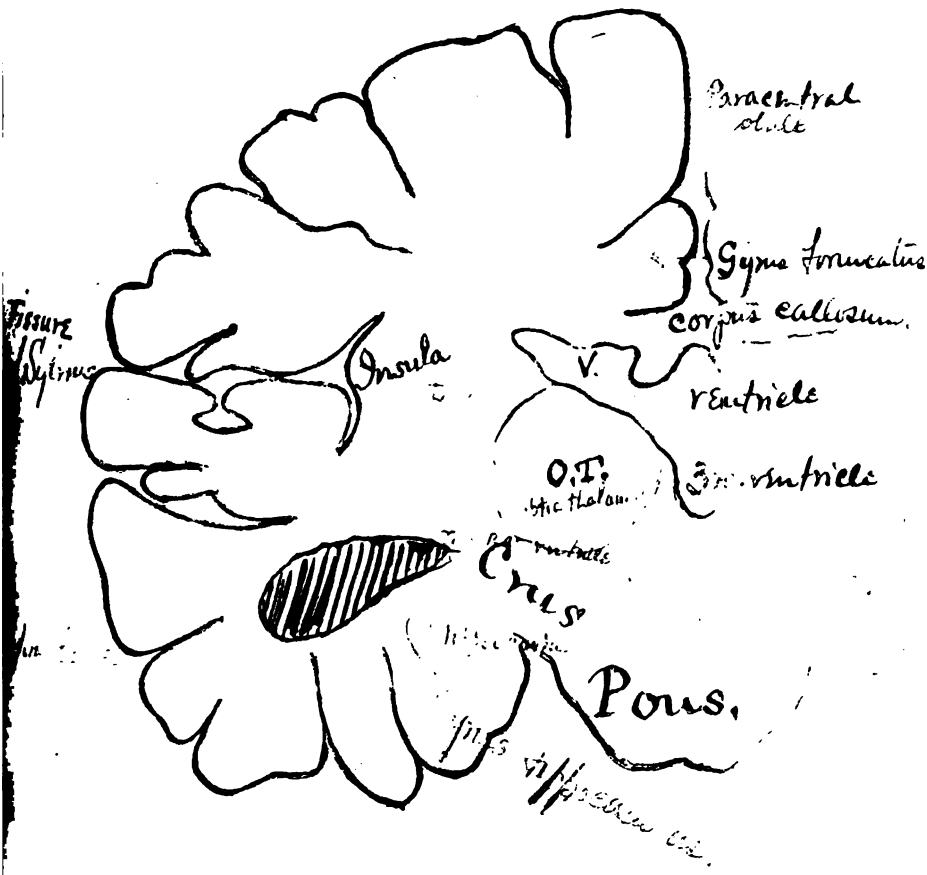
Paracentral
Gyrus fornicatus
corpus callosum.
Fissure
Insula
V.
ventricle
O.T.
Crus
Pons.

definite areas, but to regard this whole region as having to do with visual and sound perception and interpretation, all parts being intimately connected together and interdependent, on them resting the power of speech and writing, a break in any part of the mechanism throwing the whole machinery out.

A more careful investigation of the fields, especially in the later days, would probably have shown defects, not necessarily hemianopsia. I regret that this was not done, but it would have been very difficult under the circumstances. The sections show that the cuneus and calcarine fissure were probably not involved, but the course of the fibers forward around the horn of the ventricle, especially the upper ones, could hardly have escaped interruption, though I suppose considerable pressure might not be destructive of function. The absence of optic neuritis is not surprising. The mind blindness and amnesic color blindness I should say were easily accounted for by the changes in the occipital lobe.

The absence of hemianopsia with amnesic color blindness is, I believe, unrecorded. It unfortunately cannot be definitely stated that this case is an exception to that rule.

ON THE TREATMENT OF DENDRITIC KERATITIS AND OF MARGINAL ULCER OF THE CORNEA WITH TINCTURE OF IODINE.

By HARRY FRIEDENWALD, M.D.,

Baltimore, Md.

My experience for a number of years in the treatment of dendritic keratitis and of superficial rodent ulcer of the cornea was most unsatisfactory. Many cases were so protracted in their course that there was abundant opportunity for trying the ordinary remedies, all with more or less unsatisfactory result. The inflammation finally subsided in many cases because the disease had run

its course and not as a result of the remedies employed. Among these, atropine, eserine, bichloride of mercury, formaldehyde in solutions, and ointments of iodoform, iodol, aristol, etc., are to be mentioned.* Even the actual and the galvanic cautery often failed to prevent extension of the ulcer. In the belief that others have had the same unpleasant experiences, I am led to make the following communication, for I no longer look upon these cases with the dread of a long course of inefficient treatment resulting in great loss of vision from corneal opacities.

In August, 1898, Mr. G. came under treatment for beginning dendritic keratitis. There was a small horizontal linear furrow on the inner half of the right cornea near the periphery and pointing toward the lower edge of the pupil. Atropine and iodoform ointment were used with good effect, apparently, but in a few days the ulcer reached the lower margin of the pupil and one fine branch upwards indicated that it was about to traverse the center of the pupil. I determined, therefore, not to delay any further, and wiped the entire ulcer with tincture of iodine. On the next day, finding that this remedy had caused little irritation or pain, I repeated the application. On the following day the cornea was studded with fine points which rapidly developed into filaments, typical of filamentous keratitis. They were wiped off with cotton and touched with a three-grain solution of nitrate of silver and did not recur. The ulcer had in the meantime disappeared and it left no trace. The vision of this eye is almost perfect.

The very favorable result of the treatment in this case induced me to try the same in others, and I have employed it in more than twenty-five cases of dendritic and rodent ulcers. It has never failed to bring relief. Not only was the further spreading of the ulcer prevented, but its peculiar character was changed to that of a simple abrasion of the corneal epithelium which usually disappeared in a very few days. Nor have untoward symptoms ever manifested themselves excepting the appearance of filamentous keratitis in the one case mentioned above.

---

*I have recently learned that Swanzy uses absolute alcohol, and claims that this rapidly cures the affection. See Swanzy's text-book, 6th ed., p. 186.

Method of Application.

A bit of absorbent cotton is wrapped firmly about a fine wood toothpick, so as to form a narrow, firm swab. This is dipped into the tincture of iodine and the excess allowed to drop off. The eye having been prepared by instilling cocaine and a drop of fluorescine, the ulcerated area is thoroughly scrubbed until a distinct brown discoloration of the tissues is seen. The neighboring epithelium is very much loosened and curls up in all directions. It is important to touch this and especially the minute infiltrations seen a millimeter or two away from the main line of ulceration; for the progress of the disease is usually this, that after these fine infiltrations are observed the furrowed ulceration soon makes its appearance. The only error which is likely to be made is to apply the iodine too cautiously, for I have never seen any ill effect from its being used too freely. Since I have become bolder in using it, it is rare that I need to make a second application. More than twice I have not applied it in any one case — it was never necessary!

The application is usually followed by some pain, lasting for a few hours, though I have sometimes been told by the patients that they suffered little pain. The eye is bandaged and an ointment of boric acid, iodol, or the like applied. The bandage can usually be dispensed with after a day or two, though it may be well to use the ointment a few days longer.

I should like to state here that I have been able to definitely associate dendritic keratitis with malaria in but a single case. The patient was treated with tincture of iodine and was well on the second day following. She was not, however, cured of the malaria for some time.

In order to determine the amount of damage that it is possible to do with the too abundant application of the tincture of iodine, I applied it to the eye of a rabbit. A healthy cornea was scrubbed with a fine swab saturated with the tincture until half the cornea was denuded of its epithelium and then the rubbing was continued until this entire region was stained a deep brown. A little reaction

followed and this portion of the cornea became the seat of a gray infiltration, but this was gradually absorbed and disappeared entirely in a few weeks.

It may surprise some to hear that I have treated such a large number of cases of dendritic keratitis in so short a period, for it is usually considered a rare condition. I ascribe my large number to the fact that I am in the habit of examining all corneal lesions with fluorescine and the loupe. In a number of cases seen with colleagues I have thus been able to determine the true character of an ulcer, previously not recognized. Basing my statement therefore on experience, I desire to say that many cases looked upon as simple ulcers or as herpetic are in reality dendritic.

An important reason for the careful differentiation of the various forms of keratitis is that the treatment I have given for dendritic keratitis is without effect in phlyctenular, serpiginous, or other so-called infected ulcers with the exception of marginal ulcers, of which I shall now speak.

I have notes of three severe cases of marginal crescentic ulcers which I have treated with tincture of iodine, with rapid and complete recovery in all. In two of these the membrane of Descemet was laid bare and perforation imminent. Two of these cases had been treated elsewhere for some time. The application of tincture of iodine was followed by rapid abatement of all the symptoms and with immediate improvement of the appearance of the ulcer.

Three cases may appear as scarcely sufficient evidence of the efficiency of the method. The change in the condition, however, was so striking that those who saw the cases agreed that in this disease, as in dendritic keratitis, tincture of iodine may be considered as a specific remedy upon which we may rely with confidence.

During the winter of '98 and '99 Dr. Hiram Woods presented a case of dendritic keratitis, which had resisted all treatment, before the Ophthalmological and Otological Society of Maryland. Upon my suggestion he employed the tincture of iodine, and he has since told me that in this and in other similar cases in which he employed it its effect was most satisfactory.

Dr. Russell Murdoch has likewise employed this treatment in

July 7. 1899
Sarcoma of. Lid

a number of cases of dendritic keratitis and he has permitted me to say that his experience has borne out my statements.

I do not desire to make it appear that I am introducing iodine in the treatment of diseases of the eye, for many of our works refer to its having been used. It is my purpose to define those cases in which it may be used with advantage, and in which its usefulness cannot be overstated.

SARCOMA OF THE EYELID, WITH REPORT OF A CASE.

BY HARRY FRIEDENWALD, M.D.,

BALTIMORE, MD.

The great rarity of sarcoma of the eyelids and certain special features of the case to be narrated warrant its description.

Miss C., aged 15, an otherwise healthy and well-developed girl, was brought to me July 3, 1899, on account of a large swelling of the right upper eyelid. The onset of the growth could not be definitely determined; it was stated by her physician that this girl and another member of her family had had severely inflamed eyes three months previously, and that while the other recovered, the inflammation continued in our patient and the swelling of the lid rapidly increased. There had never been any pain. There was no history of injury. On admission to the Baltimore Eye, Ear, and Throat Charity Hospital the right upper lid was found to be enormously enlarged, thickened, and prominent. The tumefaction was so great that the lid hung below the lower lid, overlapping a part of the cheek. (See Phot. No. 1.) The conjunctival surface protruded below. The skin was movable over the underlying tumor, its veins were much enlarged, and it had a bluish discoloration. The conjunctiva was very congested, velvety, and secreted much mucus which partly dried upon the exposed portion and formed a crust. Upon palpation the tumor

was felt to be soft and somewhat yielding, but here and there were firmer portions. Its surface presented a number of prominences, but was not lobulated. There was no sensitiveness to pressure. The lid could not be raised by the patient. With the assistance of an elevateur the eyeball was exposed, and appeared to be unaffected by the swelling, and was not displaced. The vision of this eye, difficult to examine under these conditions, appeared to be good. There was no glandular enlargement. No bruit could be heard. The left eye was normal in every respect.

The diagnosis of sarcoma was made. In order to render this more certain a piece was excised from the conjunctival surface (July 11th). The wound bled freely and a few sutures were inserted to bring the lips together and stop the bleeding. The excised portion was frozen and cut into sections. These proved the tumor to be a sarcoma.

It is interesting to note that the wound in the sarcomatous tissue closed by first intention.

There was a perceptible increase in the size of the growth during the sixteen days while the patient was under observation. The question as to the advisability of sacrificing the apparently healthy eyeball was a difficult one. The absence of exophthalmos indicated that the growth did not extend deeply into the orbit. But, after consultation with colleagues, it was concluded to make the excision as radical as possible and sacrifice the eyeball.

Operation.

On July 19, 1899, the tumor was excised, together with the eyeball and the other contents of the orbit. An incision was made along the line of the eyebrows from end to end and carried down to the periosteum. This was next separated with a periosteal rasp from the orbit as far as possible. After sweeping around on the nasal and temporal sides of the orbit the entire mass, comprising the contents of the orbit, the eyeball, and upper eyelid, were removed *en masse*. The small portions remaining in the orbit were then excised. After checking the hemorrhage the cavity was packed with iodoform gauze and *the lower lid was used to close the*

#2

Microscopic Examination.

A piece was excised from the temporal portion of the tumor embracing the margin of the lid and cut into sections, stained, and mounted.

In these we find the tumor sharply separated from the tissues lying beneath the skin and the mucous membrane by a connective tissue capsule. The tumor is very vascular, some vessels showing distinct vascular walls; in other parts, large vessels without any definite wall structure, forming large lacunæ, are found. The tumor is made up of large round cells, in a few places spindle shaped. It is not pigmented. The skin shows nothing abnormal. The mucous membrane is much thickened and is infiltrated with leucocytes, the infiltration extending to the submucous tissues. In these, as well as in the subcutaneous tissues, there are foci of small cell infiltration around blood vessels. A portion of the lachrymal gland is likewise densely infiltrated.

The subject of sarcoma of the eyelid has been brought before this society by Dr. Randall in 1887, by Dr. Gruening in 1893, and by Dr. Wilmer in 1894, and by Dr. Veasey in 1899. In Dr. Wilmer's paper, thirty-five cases were collected. In four of these it was necessary to remove the eyeball, as was done in our case. "Forty per cent. of these sarcomata were spindle celled, forty-three per cent. were round celled, seventeen per cent. mixed, eleven per cent. presented myxomatous elements" (Wilmer).

I wish to add the following reference in order to complete Dr. Wilmer's and Dr. Veasey's lists:

1. Hohenberger, Arch. f. Ophth., 1892, Vol. 38, 2, p. 140. (H. describes a pigmented nævus with beginning sarcomatous degeneration. He mentions the following older references not found in Wilmer's list:

Gibson, Phila. Lancet, 1851.

Dauscher, Allg. Wien. Med. Zeitung, 1859.

Ruete, Bildl. Darstellung d. Krankh. d. menschl. Auges. Leipzig, 1860. Tafel XXXV.

Hirschberg, Markschwamm d. Netzhaut, 1869, p. 115.

Sarcoma of upper lid. (Friedenwald)

Fig. 3.

2. Zimmerman, Ophth. Review, 1894, Vol. LXIII, p. 184. (Small melanotic spindle celled sarcoma in the upper lid. Patient aged 50. Excision. No recurrence in eighteen months. He also describes an unreported case of Jackson, a small round celled melano-sarcoma. Excision. No recurrence within a few months.

3. Guibert, Rec. d'Opht., 1896, p. 527. (Mixed celled melano-sarcoma in a man aged 48, developing in the cicatrix of a burn in infancy. Removal together with the blind eyeball.)

4. Fage, Arch. d'Opht., 1898, p. 298. (Non-pigmented sarcoma of the size of a large bean, composed of mixed cells. Patient aged 37. Excision. No recurrence within two years.)

5. Wood, Ophth. Record, 1898, Vol. 7, p. 128. (Infant, aged 7 months; non-pigmented sarcoma composed of round and spindle cells. Excision. No return within three months.)

OBSERVATIONS ON SOME BLIND BUT QUIET AND APPARENTLY INOFFENSIVE EYES. DO THEY PRODUCE A PSEUDO-SYMPATHETIC INFLAMMATION?

By S. C. AYRES, M.D.,

Cincinnati, Ohio.

We are all disposed to treat blind but quiet and apparently inoffensive eyes kindly. We naturally consider a blind eye, which is free from inflammation and tenderness, not the probable source of trouble to the good eye, and it is better for the majority of our clients than an artificial eye. But are these blind eyes as inoffensive and free from danger as we are disposed to think? May they not exert some subtle influence which we in our clemency have overlooked? That in many cases blind eyes remain in the orbits for an indefinite number of years and are not a source of irritation to the fellow eye is a well-known fact.

But are they all so harmless? Are they all innocent because some have not been proven guilty of exciting trouble in the good eye? I will leave this an open question.

CASE I. Right eye blind from incised wound, quiet and free from irritation for a period of fourteen years. Left eye very marked failure of vision; extensive exudations into the vitreous. Enucleation of the blind eye and recovery of vision.

G. W. D., aged 45 years, was examined December, 1898, and gave the following history. He states that I examined him about fourteen years ago and pronounced the right eye blind. It had been injured but was then quiet and free from irritation. As the left eye had perfect vision, he went on as usual and had no trouble in his good eye until October, 1897. The right eye is shrunken but not tender, except to firm pressure, and has never given him any trouble. Ossification of the choroid is detected upon pressure. In relation to the left eye, he gave the following statement: The sight became suddenly very dim while working in a stooping position. Under treatment of a very competent oculist his condition varied, being at times better and then worse, but gradually grew worse until when I saw him he had bare perception of light. With the ophthalmoscope a deep yellowish reflex is seen, but no vessels are visible. This yellowish mass seems to line the fundus like a membrane and is fixed. In front of this is a grayish mass, which is quite movable and makes excursions from side to side. The eye is not painful, nor is there any deep or superficial injection. Enucleation of the right or injured eye was advised and consented to and performed at once. While the eye was not apparently a source of irritation to the left eye, I hoped its removal might have a salutary influence on the left eye.

The patient's physical condition was not good. After fourteen months of confinement he was quite feeble, had lost flesh, and his mental anxiety had disturbed him very much. So fearful was he of making his condition worse that he scarcely ever left his house, and hence got no exercise. Being practically blind, he always required the aid of some second person. He

went home with instructions to take a vapor bath twice a week, and internally he was ordered twenty drops of dilute phosphoric acid. Six months later I saw him again. The mass which filled the eye was absorbed very considerably. There was now some depth to the vitreous chamber. The grayish mass was much contracted and floated around freely. The yellowish mass behind this was much thinner, and looked like a paste which lined the inner surface of the globe. Not a vessel of the retina could be seen. His vision had much improved. Directly in front of him he could see objects quite clearly, but his field of vision was contracted so much that he could not walk alone in a strange place. Yet with a stenopæic his vision was 0.5. As the stenopæic improved him greatly, I ordered one to be worn at his pleasure. His physical condition had also greatly improved, and he was cheerful and hopeful.

He was examined again April 13, 1900, with the following result: His field of vision was greatly improved, being about half the normal, but restricted below and inward. His vision is 0.5, and he sees to walk the street without difficulty. There is still a grayish cloud close behind the lens, but it is thinner than it was nine months ago when I saw him last. Downward and inward a red reflex can be seen.

CASE II. Loss of right eye; globe shrunken but free from tenderness or irritation. Twenty-three years afterwards, left eye attacked by bullous keratitis, and later on there were exudations into the vitreous. Enucleation of the shrunken stump was followed by complete recovery of the right eye and restoration of former vision.

M. C., aged 55 years. The right eye was lost in his youth and gave him trouble occasionally until 1873, when he had secondary glaucoma. An operation was done for its relief and the globe became shrunken. It was not in the least degree tender or sensitive. He suffered a traumatic cataract in the left eye, but made a good recovery with a vision of 0.3 with + 10D.

He had no trouble with the left eye from this time until December, 1896, when I treated him for bullous keratitis. The case

hung on for about three months, when he recovered and was not treated again until November, 1897. His vision was now considerably impaired. The vitreous was cloudy and a grayish mass could be seen close behind the iris. This exudation increased to such an extent that he could not see to walk the streets alone. I advised the enucleation of the blind eye, and he now consented, although he had declined before. The right eye was shrunken to a flat button of scleral tissue having no semblance to an eye. The left eye began to clear up at once, and within six months his vision was as good as it had been at any time since he recovered from the traumatic cataract. No internal treatment was given.

CASE III. Trauma of the right eye and loss of vision; globe not sensitive or irritable. Two years later left eye suffered from intra-ocular hemorrhages and exudations, with impairment of vision. Enucleation of blind eye and prompt improvement of vision.

S. W., aged 24 years, was injured in the right eye in January, 1897, the eye having been struck by a branch of a tree. The eye was very painful for a week or two, but then quieted down. The sight, however, was lost entirely. The globe now diverges, the lens is opaque, and there are numerous posterior synechiæ, but the tension is normal and the eye quiet and free from irritation.

In April, 1899, the vision of the left eye suddenly failed, so that a person ten steps away could not be recognized. Two weeks later, vision improved, and in time became about as good as ever. On July 1st, while plowing, vision suddenly failed again, and I saw him July 15, 1899. The ophthalmoscope revealed an extensive hemorrhage in the macular region, with haziness in this region, due to exudation. Two points of hemorrhage stood out in front of the retina, and there was some subretinal hemorrhage. Vision 0.1. For several days general treatment was tried to improve the left eye, but without avail. I then enucleated the injured eye about the first of August. The effects were immediate, and I may say striking. Within a week his vision improved from 0.1 to 0.4. He then returned home and

has not been seen since. He is at work as usual, and it is to be presumed that his vision has improved since he left, although I have no means of knowing what it is.

CASE IV. Injury of the right eye in childhood. Lens calcareous and resting in the bottom of the vitreous chamber. Eye free from tenderness. Thirty-five years later, exudations and hemorrhages in the left eye. Enucleation of blind eye and improvement in vision.

A. P., aged 45, has an old calcareous lens in the bottom of the vitreous chamber of the right eye. The eye diverges, but has never given her any pain and has always been free from irritation and inflammation. The injury was inflicted by a blow from a cow's horn in childhood. Her left eye is myopic 6 D, and she has worn glasses for many years. The ophthalmoscope shows some patches of choroidal atrophy which are old, and also some recent ones. The vitreous is full of floating opacities. V = fingers at 2′, with her myopia corrected. The eye has failed for some months past, but more rapidly within the past few weeks, and her sight is now so bad that she cannot see to do her work, which is ordinary housework. The retina is very much veiled by the turbidity of the vitreous, but the fundus can be seen indistinctly. The injured eye was not painful to pressure, nor did it exhibit any evidence of inflammation. There was no scleral injection and no evidence of recent changes in the eye.

Enucleation of the blind eye was done at once in the hope that it might cut short or favorably influence the progressive trouble in the left eye.

She was not seen again until February 20, 1900. The following is the condition at that time: The vitreous is much clearer, and the retinal vessels and the entire fundus can be seen more clearly than when the enucleation was done last April. There are numerous black flakes floating in the vitreous. A long but narrow black mass hangs down from the ciliary region immediately behind the lens. The posterior capsule of the lens shows a small star-shaped opacity in its center. Vision is now improved to counting fingers from 2′ to 4′ with her glasses.

Stronger glasses do not improve her vision. She says that the eye is now much stronger than before the enucleation of the blind eye. Then she was conscious of a gradual failure of her sight. Now her vision seems to be slowly improving, and is nearly as good as it has been for some years past. She received no internal treatment.

CASE V. Loss of left eye from ophthalmia neonatorum; globe shrunken but quiet. Right eye had partial vision through an iridectomy made for visual purposes. Seventeen years later the right eye was attacked by secondary glaucoma. Partially relieved by the use of eserine, but completely relieved by enucleation of the shrunken globe.

B. M., aged 20 years, had ophthalmia neonatorum in a very severe form, which resulted in total loss of the left eye. The right eye retained a portion of clear cornea, and when she was five months old I made an iridectomy upward. This saved her barely sight enough to see large objects indistinctly. Three years ago (1896) the right eye began to have attacks of secondary glaucoma, which threatened to destroy the little sight she had. I treated her with eserine and under this she improved. While the left globe, which was shrunken and not sensitive, did not seem to be the cause of the irritation in the right eye, I presumed it might be, and recommended its enucleation. To this she would not consent at first, but after several attacks at intervals she consented to the removal of the blind eye, and the operation was done in June, 1899. Since then the right eye has been quiet and entirely free from any tendency to secondary glaucoma. She returned to her school, where she now is.

CASE VI. Sight of right eye lost from detachment of the retina. Submitted to operation for relief. Eye quiet and not sensitive. Two years later, exudations into the vitreous of the left eye. Recovery of vision under treatment.

In the case of S. M., aged 50 years, the right eye is blind from extensive detachment of the retina. He has consulted the best authorities in this country and Europe in relation to his affliction. While abroad he was operated upon by one of the most eminent

surgeons, but in spite of all treatment the detachment remained unimproved and the eye blind. In July, 1898, he had a "shower of soot," as he said, in his right eye which alarmed him, but as it soon passed off and his vision returned he paid no attention to it. But soon another "shower of soot" came on, and he consulted Dr. Vail, in the temporary absence of Dr. C. R. Holmes. I was called in consultation by Dr. Vail and found the left eye in the following condition: The vitreous was cloudy, being filled by dustlike particles and black strings which moved freely, being in the anterior portion of the vitreous chamber. There was no appearance of exudation in the choroid, no hemorrhage, and it was evident that the inflammation was in the anterior portion of the choroid or ciliary body. The eye cleared up promptly and later on his vision was 0.8 with ametropia corrected. Since then the eye has remained quiet with very good vision.

Let us now analyze these cases. In case No. 1 the trouble began in the fundus with exudations and hemorrhages. These increased in spite of treatment, until his vision was reduced to the perception of motions of the hand. After the enucleation of the blind eye the improvement was slow but gradual, and in a year he had a central vision of 0.5 with a stenopæic. His peripheral vision was so poor he could hardly go where he was not well acquainted. What effect the internal treatment had can hardly be estimated. I ordered the vapor baths, thinking they might favor the absorption of the mass in the vitreous.

In the second case the improvement after the enucleation was steady, and within six months he regained his former vision, and there has been no trouble with the eye since the enucleation, now nearly two years and a half ago.

In the third case the improvement after the enucleation of the blind eye was immediate, and, within a week, vision improved from 0.1 to 0.4, and is probably better now.

In the fourth case the improvement was all that could be expected, and her vision is now probably as good as it has been for some years past. In this eye there were changes in the choroid and also in the ciliary.

In the fifth case the tendency to secondary glaucoma subsided as soon as the shrunken globe was removed. In only one of these cases was there any internal treatment given.

In the sixth case the right eye was blind from detachment of the retina and had been operated on by punctures through the sclerotic and injections into the vitreous. The left eye had first a cloud of "soot," which passed away, and then another one, which alarmed him, and for which he was treated. In this case there were no hemorrhages, but the vitreous was filled with black masses which were very noticeable in the anterior portion of the vitreous. The eye regained its former vision, and it may be presumption to say that his eye is still in danger from the injured eye, but the lesson drawn from the other cases leads me to believe that he is liable to suffer another and more severe attack unless he has the blind eye removed.

Were these cases simply coincidences? There seems to be a similarity in the disease. In cases I., II., III., IV., and VI. there were exudations into the vitreous, and in case III., seen in the acute stage, there were hemorrhages in the region of the macula lutea. In case V. the cornea was so nebulous it was impossible to see the interior of the eye. In the five cases operated upon there was relief after the enucleation of the blind eye, and an improvement, if not a complete restoration, of vision.

Case VI. is still *sub judice*, and time only can tell whether another attack will occur. These cases bear no resemblance to true sympathetic irido-cyclitis. The attack involves the posterior portion of the globe and not the anterior. The ciliary does not from any physical sign seem to be sensitive or show any external evidence of inflammation. Yet in the five cases operated on there was relief. Was the blind but quiet eye guilty of exciting the disturbance?

THE CORNEAL SECTION FOR CATARACT EXTRACTION AND THE CATARACT KNIFE.

BY EDWARD JACKSON, M.D.,

DENVER, COLO.

The cataract knife is an instrument designed to accomplish a mechanical effect, under such definite conditions that it is capable of very accurate adaptation to its purpose. The size of the cornea, the size of the incision to be made for the escape of the lens, and the distance that the point of the knife can be thrust forward without sticking the side of the nose, are so constant that the dimensions of the knife should be made to conform accurately to them.

The corneal section for cataract extraction, whatever its preferred size, shape, or position, should be as smooth as possible, and should be accomplished with the least possible mechanical disturbance of the eye. This smoothness is secured by making the section, so far as possible, by a single forward thrust of the knife. The mechanical disturbance of the eyeball is to be avoided by making the exertion of force in cutting the cornea as uniform as possible, and reducing to the minimum the turning effect, that has to be opposed by fixation of the globe.

To understand the problem of keeping uniform the force exerted, we must consider the relation of different parts of the corneal section to the edge of the cataract knife. Let us take first the case of a corneal section made with a narrow Graefe knife, which has for the greater part its edge and back parallel. While such a knife is making the puncture, while the tapering point is entering the cornea, a certain amount of force is required. But when the full width of the knife has entered, the resistance to its forward thrust ceases; only to begin again with the counter-puncture. At the completion of the counter-puncture it will

again cease, unless the operator promptly begins that upward (or downward) pressure, designed to divide the remaining bridge of corneal tissue. This pressure, or force, tending to rotate the eyeball upward (or downward), must then increase until the edge of the knife passes from the anterior chamber entirely into corneal tissue, after which time it rapidly diminishes with the length of the bridge of tissue the knife is dividing.

The greater extent of tissue presented to the edge of the knife as it leaves the anterior chamber is a point of much practical importance. By using either the puncture or the counter-puncture as a sort of fulcrum, and cutting chiefly with the other part of the knife, these variations of resistance can be reduced. Some operators seek to overcome the difficulty by giving a peculiar sweep of the knife. But it cannot be wholly avoided, when using such a knife, without at least two distinct changes in the direction of the motion. Many operators have come to prefer wider knives than Graefe suggested, and these, although not perfectly proportioned, possess some of the advantages of the knife to be presently described. The fact is that Graefe's plan, of making the cataract knife transfix the eyeball and then cut out, lost the chief reason for its existence when we began to operate under local anæsthesia, and so gained the full co-operation of the patient.

Beer's knife, and its various modifications, designed to complete the section by a single forward thrust, gave a smooth incision without angles, and with no intermission in the resistance. But this resistance continued to increase until the edge of the knife had passed out of the anterior chamber. Then the decrease was sudden. The knife I showed before this Society some years ago (see Transactions, 1888, p. 62) was open to the same criticism. But it prevented the escape of aqueous until the practical completion of the incision, and aided in fixation by the counter pressure of the back. So I continued to use it until three years ago; when the form to which I now call attention was adopted, because to the above advantages it added the securing of uniformity of the resistance to the simple forward thrust.

The essential characteristics of the knife now presented are: The blade has a maximum width barely sufficient to complete the desired corneal section. The maximum width is reached 20 mm. from the point. At 10 mm. from the point fully two-thirds of this maximum width is reached. From the point to the 10 mm. line the edge of the knife is straight. From the 10 mm. line it begins to curve, so that at the 20 mm. line the edge is parallel to the back. The back is straight throughout. The blade is flat and is as thin as is compatible with sufficient rigidity and strength. Its outline is shown in Fig. 1, in which the dotted lines indicate distances of 10 mm. and 20 mm. from the point.

Fig 1.

The particular width of the knife must be determined by the depth of the corneal section it is desired to make. The dimensions given in the figure are for nearly the maximum corneal flap of 4.5 to 5 mm. For a 3 mm. flap the maximum width of blade should be 3 mm. or a little less, and the width at 10 mm. from the point should be 2 mm.

By holding such a knife with its widest part in front of the cornea with its cutting edge opposite the corneal margin, where the center of the incision is to come, the back will indicate quite accurately the points for the puncture and counter-puncture.

The knife is to be entered at the point for the puncture with its plane in the plane of the proposed section, and its straight back pointing toward the point for the counter-puncture, and

then pushed steadily forward. In Fig. 2 the solid outline represents the position of the knife at the completion of the counter-puncture. The boundaries of the corneal section are shown by

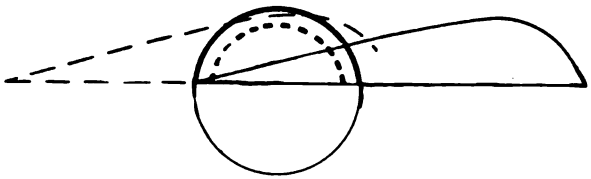

Fig 2.

the heavy lines, the section of the external surface by the solid line, and of the internal surface by the broken line.

The back of the knife, by its counter-pressure, so balances the pressure of the cutting edge that there results only a slight tendency of the eyeball to rotate. This tendency is to turn in the direction of the forward thrust. It is best met by placing the fixation forceps just outside the limbus, close below the counter-puncture.

The forward thrust of the knife is continued until the section is completed, or until the widest part of the blade has fairly entered the cornea. If the section made is a smaller one than the knife is capable of cutting, it will be finished before the widest part of the knife has quite entered the cornea. If it be deeper than the maximum width of the knife, the end of the forward thrust, indicated by the broken line in Fig. 2, leaves a thin bridge of tissue undivided. This is best divided as the knife is withdrawn, by rocking the knife about the point of puncture so as to complete the section with the part of the cutting edge near the point.

EXFOLIATION OF THE ANTERIOR LAYER OF THE IRIS WITH PARTIAL OPACITY OF THE LENS.

BY EDWARD JACKSON, M.D.,

DENVER, COLO.

The following case presents such striking changes of the iris, and seems so suggestive of the significance of changes of color in that membrane, that I deem it worthy of record.

J. M., male, aged 44, a cook, is an inmate of the wards for the insane of the Arapahoe County Hospital, on account of chronic dementia. He gives a history of typhoid fever, acute articular rheumatism, malaria, gonorrhœa, and chancroids. He denies syphilis, but has suffered from what were probably the secondary and tertiary manifestations of that disease. He has been a moderate drinker, and is now well nourished. Since his admission he has complained of headache and poor sight, and has pounded his head against the wall until it was severely bruised, " to drive out the spirits " that are troubling him.

His vision is reduced to R. E. 20/200, L. E. counting fingers at two feet. The corneas are clear, the irides show the appearances to be presently described, and the crystalline lenses present diffuse haziness and clouds of opacity sufficient to account for the impairment of vision. The fundus reflex seems good in all directions. The ocular tension and movements are normal.

The general appearances of the irides and pupils are shown in the accompanying colored plate. The pupils are free, and their reactions normal or but slightly sluggish. The left pupil is somewhat larger than the right. The upper part of each iris presents an area having the blue-gray color of the iris seen in early infancy. In this area the structure of the iris stroma is especially distinct. This part of the iris has lost its anterior layer of epithelium and condensed pigmented tissue. Below the

above area is an irregular strip, in which the anterior layer is hanging in shreds and flakes, which while still attached to the iris, swing about in the anterior chamber with the different movements of the eye. At some points this swinging of the loose shreds so influences the iris as to cause a tremulousness of the iris that closely resembles that seen when the iris has lost the support of the crystalline lens. This strip of shreds is distinctly yellowish brown in color. Below this strip the iris presents what was probably its original appearance, a gray-brown color, and the stroma is indistinctly seen through the anterior layer, which remains in normal position throughout this portion. During the four weeks that this case has remained under observation there has been a distinct progress in the exfoliation.

In 1869 Jonathan Hutchinson reported the case of a man aged 36 who had recently discovered that he could not see well with his left eye. "The whole lens was slightly opaque and had probably been so for some months. The iris acted well. To myself," says Hutchinson, "the chief point of interest was in the very dissimilar color of the two irides. That of his right eye was gray, with much yellow and brown pigment, and that of the left blue-gray, without a trace of brown. He told me that his sisters had often mentioned that his eyes were odd ones. He had not observed any difference in their sight. He was quite aware that they differed in color. Thus the case confirms an opinion which I formerly expressed, that when the colors of the two irides are markedly different, not unusually ulterior changes follow, or marked differences in accommodation are present." (Royal London Ophthalmic Hospital Reports, Vol. VI, p. 277.)

In the next succeeding volume of the same reports, in some "Suggestions for Future Clinical Work in Ophthalmology," Hutchinson says that it "would be of much interest to observe whether the irides usually differ in tint in cases where only one eye becomes the seat of cataract."

Dr. Malgat of Nice reported (Recueil d'Ophtalmologie, August, 1895) three cases of similar difference in the colors of the two irides. A woman, aged 50, whose right eye showed a brown

RIGHT

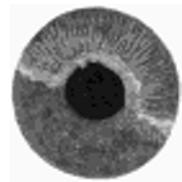

LEFT

EXFOLIATION OF THE IRIS.

BRAUER PRESS

iris and normal vision, had a left eye the iris of which was gray-blue, and which presented opacity of the lens of six months' standing.

A man, aged 45, presented a right eye with a brown iris and normal vision, and a left eye with a light blue iris, in which cataract had been noticed for about six months.

In the third case of a man aged 24, the right iris was yellowish brown, and the left was pale blue; but vision was good in both eyes. In a previous paper in the same journal (June, 1889), Dr. Malgat had reported six other cases of heterochromia in comparatively young patients, who nevertheless had good vision in both eyes.

In the above cases the differences of color were supposed to date from early childhood, although the evidence upon this point was not always conclusive. Last year Dr. A. Schapringer reported a case (New Yorker medicinische Monatsschrift, April, 1899), in which the history clearly indicated that the difference of color was of later date.

A woman aged about 55 had the right iris brown, and the left iris gray-blue, and in the latter eye there was a complete gray cataract, while in the former the crystalline was quite normal. According to the history of the case both eyes had been of the same color, brown, until nine years before; then, without any evidence of inflammation or other disease, the color of the left eye had changed.

Two cases in which the irides were said to have changed color are reported by E. Nettleship. (Royal London Ophthalmic Hospital Reports, Vol. XI, p. 272.) A mother brought her son, aged 14, who had myopia of 10 D. His "eyes (irides) had changed color; they were now of a uniform greenish-gray, without spots; she said 'they used to be dark brown.'" In the other case, in a woman aged 23, one eye was said to have changed from brown to a uniform gray after a chronic irido-cyclitis.

It will be noticed that in all these cases the change of color which occurred was from brown to blue or gray, the change that would be produced by loss of pigment; and that in each of these cases in which one eye became affected with cataract, it was the

eye having this same blue or gray color. In my case the change of the iris is going on in both eyes, and both lenses are becoming opaque, and the more advanced cataract is in the eye presenting the greater iris changes.

The pigment that gives color to the iris is in its anterior layer, and the removal of this layer, as my case beautifully illustrates, produces just the color noted in these cases. The deficiency of this layer might be either congenital or acquired. This layer consists of an imperfect stratum of epithelium and condensed stroma, while the lens is an epithelial structure closely allied in origin to the iris epithelium, and its nutrition closely dependent on the state of the uveal tract, of which the iris is a part. The association of the lens changes with the gray iris is probably not accidental, whether the gray is due to the absence of the anterior layer, or of the pigment from it.

ON THE ADVANTAGES OF STRONG, PORTABLE, OR EASILY MOVABLE MAGNETS IN EYE SURGERY.

BY J. A. LIPPINCOTT, M.D.,

PITTSBURG, PENN.

Haab's introduction of the magnet which bears his name was a very important advance in the methods of removing particles of metal from the interior of the globe. The electro-magnets of Hirschberg and Bradford, and even the small permanent magnet devised by Gruening, had proved of undoubted service in this department of ocular surgery, and I, like others, have successfully used them in very many cases. But not infrequently their traction power was found inadequate. The giant magnet has demonstrated the value of force, and the great usefulness of the instrument is apparent. Its comparative immobility, however, even with recent improvements, in my judgment constitutes a serious drawback. This is especially true from the point of view of diagnosis, particularly with reference to the location of the foreign body.

In 1896 I had Mr. F. F. Howe, of the firm of Orr & Howe, Pittsburg, make for me a magnet with high drawing power, and at the same time small enough to be readily manipulated when suspended from the ceiling of my operating room. The instrument which he then made, and which I hold in my hand, is 12 inches long and 2½ inches in diameter. Into the end of the core, which is ⅛ inch in diameter, can be screwed the tips belonging to the Hirschberg magnet. Of these I use two, a short tip 1 inch long, and with a flattened point 3/16 inch one way and 1/10 inch the other, and secondly a long tip 1½ inches in length and terminating in a rounded point 1/16 inch in diameter — small enough to be introduced into the globe if necessary. With this magnet I have lifted a mass of iron weighing 51 lbs. The iron was in contact with the end of the core. At the end of the short tip the pulling strength is 4 pounds, and at the end of the long tip half a pound. A bit of iron weighing 5 grains was held to the core with a force equal to 20 ounces, to the short tip with a force equal to 15½ ounces, and to the long tip with a force equal to 2½ ounces. The same piece of iron suspended with a string is attracted horizontally from a distance of 3 inches from the core, 2¼ inches from the short tip, and 1¼ inches from the long tip.

The instrument weighs nearly 9 pounds and is therefore too heavy to be easily manipulated without other support than that afforded by the unaided hands. Suspended, however, by a wire cord attached to its center and passing through two pulleys in the ceiling, and balanced by a counter weight at the other end of the cord, the instrument can be handled with a minimum of effort and can be held in any desired position while operating. Among the advantages of such a magnet as this, or the beautiful instrument described by Dr. Johnson in the Archives of Ophthalmology for May, 1899, are in the first place that the presence of the metal in the eye can usually be diagnosticated, and its location, actual or approximate, frequently determined, and this without the loss of time required by the use of the Roentgen Ray apparatus. I fall back upon the latter, however, in suspicious cases in which, nevertheless, the magnet gives no sign. These cases

are rare in my experience. In making a diagnosis with the magnet the signs upon which reliance is placed are: First, a sensation of pain or discomfort elicited, and second, a perceptible movement of the ocular tissues produced, when the instrument is brought sufficiently near the foreign substance in the eye. The first of these phenomena is manifested in the great majority of cases in which the foreign body is situated elsewhere than in the lens. When it is in the lens there is no sensation, but movement can usually be observed on close examination. If the substance is in the iris or immediately behind it, both sensation and movement are exhibited. With the object of attaining greater accuracy in locating the foreign body, I have had a telescopic tip made with the object of reducing the strength of the magnet to the point at which the minimum of either pain or movement or both can be elicited. If the tip is moved in gradually diminishing circles, we can frequently settle on a small area within which either sensation or movement is most pronounced. During the examination the patient is instructed to hold the eye in every possible position. By strong rotation of the globe upwards, downwards, outwards, and inwards the posterior quadrants can be satisfactorily investigated. I have not used the Haab magnet, but its size obviously makes such refinement of diagnosis difficult if not impossible.

Cases occasionally occur in which the foreign body is so small that the X-Ray test must in the nature of things be negative. As illustrative of such a condition of things I beg to exhibit a fragment of steel diagnosticated and removed about three weeks ago (See case X, towards end of this paper). From the size of the object, which is only about $\frac{1}{4}$ mm. in length, skiagraphic investigation must necessarily have been fruitless. In this case the evidence furnished by the magnet was absolutely conclusive. Whether the diagnosis could have been made with the sideroscope of Asmus I am unable to say, as I am not familiar with this instrument; but from the reports which I have seen I should judge that the conditions for its employment are too stringent to permit of its finding a wide field of usefulness.

It is needless to say that to use the magnet for diagnostic purposes, accurate and painstaking observation is often necessary. I have sometimes failed, generally owing to insufficient light, to make a positive diagnosis at the first trial.

Occasionally the test is entirely negative. In one instance (case 13) the approach of the magnet caused no pain, although there was a thin strip of steel 20 mm. long and 1½ mm. wide in the globe, one end having penetrated the posterior inner wall. Notwithstanding the failure of the test in this case, enucleation was at once advised without even waiting for an X-Ray examination, because the vision of the other eye was already seriously compromised, the ophthalmoscope revealing a pronounced sympathetic inflammation of the optic nerve and retina. While cases of this character show that the magnet test has its limitations, and that, when negative, it is not to be regarded as final, they by no means detract from the value of the positive evidence so frequently and so promptly furnished by the instrument.

The movable magnet has also some advantages in operating, *e. g.*, when general anæsthesia is necessary, or when for any reason the recumbent position is deemed advisable. In many of my cases the metal was situated in the lens which was cataractous. In most of these cases a corneal incision was made large enough to permit of the removal of the lens and also of a small iridectomy where there was adhesion of the iris to the lens capsule — so frequently met with in these cases. Such operative work is, in my judgment, most easily and safely done in the reclining or recumbent position; and I think it important to bring the magnet within working distance as speedily as may be after the completion of the cut. In almost any case it will be found more convenient to move the magnet to the patient than the patient to the magnet. It is a case of Mahomet and the mountain, and the patient may from timidity or some other cause find it difficult to play gracefully the rôle of Mahomet.

A brief account is given below of the cases, fourteen in number, in which the magnet shown to-day was used for diagnostic and operative purposes during the past year. I limit myself to

this period because I do not wish to make the paper too long, and also because my assistant has during that time carefully preserved all foreign bodies removed; and the records, especially with regard to measurements, are therefore more complete. In ten of the cases the metallic particle was situated in the anterior part of the globe. Nine of these were operated upon with good results. In one, a boy of 11, operation was refused by the mother, although the presence of iron or steel in the eye was demonstrated beyond the possibility of doubt.

Of the four cases in which the metal had lodged in the vitreous chamber the only one which could be expected to end favorably is too recent to give the result. One of the remaining three required enucleation on account of sympathetic neuro-retinitis. The two others recovered quantitative vision with "quiet" eyes. I may say that my observation goes to show that a piece of metal with impetus enough to go through the cornea and lens is usually large enough to do irreparable damage to the eye. When to the size of the object is added the increased danger of infection of so receptive a medium as the vitreous, it must be obvious that the cases in which useful vision is retained after the extraction of foreign bodies from the vitreous chamber may be regarded as affording just grounds for congratulation.

FOREIGN BODIES IN ANTERIOR CHAMBER.

CASE I. May 9, 1899. *Bit of steel 1 mm. long and ½ mm. wide in lens and covered by adherent iris. Diagnosticated and removed with magnet.*

G. G. B., farmer, of Arroya, W. Va., aet. 54, while putting a hoop on a barrel seventeen days before, was struck in left eye with something which flew either from the hoop or from a file he was using at the time. On examination, V'n was 1/CC. Field good. Globe moderately congested. T. normal. Pupil dilated and oval, with long diameter vertical. Posterior synechia at a point midway between center and outer margin of cornea. Just over this point a small corneal scar. Lens par-

tially opaque. Eyeball aches at times. Magnet held close to cornea causes discomfort and produces distinct movement of iris in region of synechia. Corneal incision with lance at outer margin. Excision of adherent iris. Magnet brought to wound moved, but did not extract foreign body. Tip introduced promptly effectual. Atropine.

May 16, 1899. V'n = 1 p. Lens quite opaque.

April 13, 1900. Cataract being absorbed. Central triangular spot fairly clear. V'n with + 11 = 10/C and gradually improving.

CASE II. May 23, 1899. *Steel splinter ½ mm. square projecting from Descemet's membrane into anterior chamber. Removed with magnet.*

A. B. H., Ph.D., chemist, aet. 36, while examining steel had left eye injured by a flying fragment four weeks previously. V'n 15/CC. Small wound near center of cornea, slightly to inner side, apparently still open, and surrounded by a nebulous area. Foreign body with oblique illumination seen projecting into anterior chamber. Eyeball red. Hirschberg's magnet applied without effect. Large magnet instantaneously withdrew the object, which was followed by aqueous. Atropine. Bandage.

June 14, 1899. V'n L. E. with — 1 cy. hor. = 20/XXX. The corneal scar is yellowish from rust. Some catarrhal conjunctivitis, for which a mild astringent was prescribed.

CASE III. June 16, 1899. *Piece of steel ½ mm. square in cataractous lens left eye. Lens removed and steel in it. Magnet test failed.*

A. K., laborer in steel mill, aet. 17, had never to his knowledge received any injury to either eye. Discovered the defective sight in left eye about one month prior to first consulting me, which was May 25th, through trying to enlist for service in the Philippines. He remembered, however, that several weeks before that the eye was a trifle red but without any pain.

Examination revealed a small scar to outer side of center of cornea. Lens, and especially capsule, opaque, and fundus reflex too faint to make out any foreign body, although V'n was 3/CC. Pupil freely dilatable. Projection good. T. normal. Magnet elicited no sensation or visible movement. Skiagraph taken, but not satisfactory.

After spraying the nostrils with permanganate of potassium solution, as is my custom before opening the eyeball for any purpose, the cornea was incised at upper margin and iridectomy performed. Magnet then ineffectually tried. While screwing on a tip which could be inserted into the anterior chamber, patient violently squeezed his eyelids, expelling the whole lens, which was found to contain a small fragment of iron or steel in its posterior portion just above the horizontal meridian. The lens was soft. The pupil was quite black and vision was sharp. Healing process prompt, and patient left the hospital in a week. No chance to test vision subsequently, the young man having probably left the city.

CASE IV. June 29, 1899. *Splinter of steel 2 mm. by 1 mm. in anterior chamber and lens, left eye. Removal of steel with magnet. Development of cataract. Extraction. Good recovery.*

J. W., aet. 47, machinist, while at work a few hours before was struck by a flying splinter in left eye. The foreign body, which appeared to be about half the size of a grain of wheat, could be seen sticking by one end into the cornea and by the other into the lens. Latter looks hazy. Anterior chamber extremely shallow.

After cocainizing the eye and without enlarging the wound of entrance the magnet was held close to the cornea. For a moment or two no apparent effect. Then suddenly the foreign body appeared, adhering to the magnet.

A week later, as the eye was quite painful, my assistant, Dr. J. L. Duncan, in my absence, removed the lens, which was much swollen, washing out the anterior chamber thoroughly. The

wound healed well; but for a few weeks there remained some pain and increased tension, which finally yielded to eserine.

August 25, 1899. V'n L. E. + 10. + 2 cy. vert. = 20/L. V'n in the other eye was also 20/L and not improved by a glass.

CASE V. Aug. 28, 1899. *Flat bit of steel* 1 *mm. square in iris, L. E. for* 9 *days. Diagnosticated (at second trial) and removed with magnet.*

J. L., machinist, of Johnstown, Pa., was seen by my assistant August 26th, 1899. He stated that while chipping steel nine days previously a fragment struck the left eye. The globe was red. T. normal. Pupil dilated. No foreign substance visible. No corneal scar. Magnet test at that time negative, but revealed movement of the lower portion of the iris on the 28th, when an incision was made at the lower corneal margin and the foreign body immediately removed with the magnet.

September 21, 1899. V'n 20/XXX.

CASE VI. Oct. 12, 1899. *Steel splinter* 1 *mm. by* ½ *mm. in anterior chamber and attached to cornea. Removed with magnet. Escape of aqueous.*

W. D., aet. 36, machinist, while chipping steel six hours before, received a wound in the right eye. The wound was central. The foreign body was distinctly seen in the anterior chamber, one end being still in the cornea. Promptly removed with magnet, and followed by jet of aqueous. Next day anterior chamber normal in appearance. Eye looks well, and patient discharged at his own request.

CASE VII. Dec. 15, 1899. *Metallic substance in right lens covered by posterior synechia. Magnet test elicited both pain and movement. Operation refused.*

A. B., aet. 15, cooper's assistant, was driving tacks in a barrel twenty-four hours previously when he suddenly felt something strike the right eye. On examination the eye was found red

but not painful. A small linear split was seen in the cornea outside its center. Edge of pupil torn and adherent at its outer margin. Lens slightly cloudy. V'n 20/LXXX. On applying the magnet, some pain was felt, and a forward movement of the iris was readily seen.

The boy's mother, a stolid and ignorant woman, resisted all the arguments I could bring to bear and took her son away. I have not been able to trace the subsequent history of the case.

CASE VIII. Feb. 8, 1900. *Piece of steel 2½ mm. square and 1 mm. thick behind periphery of iris. Diagnosticated and removed with magnet, at second trial, the first having failed through instrument not being in good order.*

C. M., aet. 28, steel worker, of Mannington, W. Va., and referred to me by Dr. Fitch of that place, while sharpening tools at an oil well on February 5, 1900, received a wound from a hot fragment of steel in left eye. The anterior chamber was filled with blood when examined by Dr. Fitch. Forty-eight hours later, viz.: February 7th, the blood had been pretty well absorbed, but aqueous was a little cloudy. There was a fresh cicatrix about 3 mm. long and situated vertically at the upper outer sclero-corneal margin. Opposite this was a very small blackish spot on the iris, which looked as if it might be a foreign body. V'n was 10/CC. The eye had been cocainized by mistake, and no sensation was produced by the magnet, nor was any movement of the iris noticeable. The magnet, for a reason which I understood later, drew feebly. Nevertheless, I made a corneal incision at the site of the wound of entrance and endeavored to extract the metal which I was sure was in the eye. Failing with the magnet, I tried forceps, but did not succeed. Atropine was instilled and the eye closed. I thought the trouble was in the current, and did not suspect the magnet until next day, when I learned that some one had turned the current on the hospital magnet and left it on all night, thus making the instrument practically useless. My office magnet, similarly constructed and of the same power, elicited an instantaneous response in sensation

and movement, and on reopening the wound the offending substance was promptly removed. No reaction. Nine days later, patient went home with the eye free from irritation. V'n with —4. cy hor. = 20/L.

CASE IX. Mch. 6, 1900. *Thin bit of steel 3½ mm. by 1 mm. in right lens for two years. Diagnosticated and removed with magnet. Cataractous lens extracted. Subsequent discission. V'n corrected = 20/XX.*

J. M., aet. 20, while punching horseshoes on April 17, 1898, was injured in right eye. He was seen at that time by my assistant, who tried the magnet for sensation, but did not look critically for movement. Result negative.

When I examined him on March 6, 1900, the eye was slightly congested. Small vertical scar on lower part of cornea. Pupil dilated except at lower margin. Lens opaque and dark in color. V'n l. p. Projection good. Magnet elicited no pain, but movement of the attached portion of iris could be observed.

Operation. Small corneal incision. Excision of synechia. Instantaneous withdrawal of steel. Lenticular débris washed out with anterior chamber syringe.

March 27th. V'n R. E. + 12 = 20/C. Capsule opaque.

April 4th. Free discission.

April 12th. R. E. with + 12.5. V'n = 20/XX.

CASE X. April 10, 1900. *Very minute bit of steel ¼ mm. in length buried in lens. Diagnosis made and removal effected with magnet at second trial, the first having been negative.*

C. B., aet. 22, an intelligent German, had his right eye hurt slightly thirteen days before, while drilling holes in steel cars. His vision was good until six days after the accident. Patient first presented himself on April 5th. There was then very slight congestion of eyeball. No pain. Pupil normal. At lower pupillary margin a little to the nasal side was a very dense pinhead opacity of the lens capsule which spread out into a general

lenticular diffused haze. Under intense focal illumination a very small scar was found in the cornea over the seat of the opaque spot in the lens capsule. V'n R. E. = 2/CC, not improved by a glass.

L. E. 20/LXXX, and with = 2.75 = 10/XXX. Magnet test on that day did not develop pain, and no movement was perceived. But the light was not good — Pittsburgh is not always blessed with Italian skies — and I was not satisfied. Patient was given a weak atropine solution, and was requested to return in a few days.

April 10th. Lens a little more opaque, otherwise no change. Magnet test again tried. This time the light was good, and my own eyes were fortified with strong sphero-prisms. The tip of the instrument was held close to the cornea, and, as the current was turned on and off, an extremely slight, but unmistakable, to and fro motion of the capsular opacity was made out.

The patient at once submitted to an operation, and the particle was removed through a small peripheral corneal incision, the slender tip of the magnet being introduced for that purpose into the anterior chamber, and moved up close to the fragment.

FOREIGN BODIES IN VITREOUS CHAMBER.

CASE XI. Sept. 23, 1899. *Piece of steel 4½ mm. by 2½ mm. and 1½ mm. thick in the vitreous chamber diagnosticated and removed by means of magnet. Resulting vision = 1 p.*

J. B., aet. 22, machinist, while at work in one of the departments of the Westinghouse Electric Co., was injured by a flying bit of steel thirteen hours before. There was a pretty large wound in the inner lower ciliary region, and the pupil was drawn towards the seat of the injury. The eyeball was congested. The magnet in the hands of my assistant promptly elicited pain.

A few hours later the wound was enlarged and the metal easily removed with the aid of the instrument Suture applied.

Ten days later eye looks well. Pupil round. Retina extensively detached. V'n 1 p.

February 9, 1900. Eye quiet. Pupil almost perfectly round and freely movable. V'n seemed a little improved. Counts fingers doubtfully. R. E. = 20/XX.

CASE XII. Oct. 14, 1899. *Fragment of steel 8 mm. square by 3 mm. thick in the vitreous chamber. Diagnosticated and removed with magnet. Preservation of eyeball but not of useful V'n.*

R. McA., aet. 45, was struck in the right eye two days previously with a flying bit of steel.

On examination the eyeball was highly œdematous and very tender. Pupil contracted. Large irregular scar to the outer side of cornea. V'n = 1 p. The vision of left eye, which, according to patient's statement, had been blind for over four years, was also limited to 1 p., and ophthalmoscopically this eye showed a rather dense opacity of the vitreous. The patient complained of pain immediately on the approach of the magnet to the injured eye.

After reopening the entrance wound with a Graefe knife the foreign body was drawn out by the magnet.

January 9, 1900. V'n in each eye was 1 p. The right eyeball was free from irritation, but tension was somewhat reduced. The pupil was small and oblong and drawn towards the corneal scar. Light projection poor on both sides. Iodide of potassium prescribed.

March 6th. Patient thinks vision in both eyes improving, but, evidently, the wish is father to the thought.

CASE XIII. March 10, 1900. *Strip of steel 20 mm. long by ½ mm. wide in vitreous chamber and protruding through posterior wall. Sympathetic neuro-retinitis of other eye. Magnet test negative.*

A. P., aet. 27, of Johnstown, Pa., sent for my opinion by Dr. W. B. Lowman of that city, was struck in the right eye with a flying fragment while setting dies. On examination a scar was seen running completely across the cornea about 2 mm. be-

low its upper margin. Anterior chamber shallow. Pupil occluded. T. reduced. V'n = 0. L. E. V'n = CC at 9 inches, with +9 = 20/C. External appearances perfectly normal with the exception of a moderate dilatation of the pupil. No ciliary tenderness. The ophthalmoscope showed clear media. Inner margin of disc and adjacent retina markedly striated. Surface of disc hazy, as is also the retina, for a considerable distance from the disc. The swelling of the retina is rather more pronounced than that of the disc, the latter being most clearly seen with + 6 D, while the former is best examined with + 8 D. Retinal veins tortuous and about one-third of normal calibre. Arteries size of coarse threads. The magnet produced neither pain nor visible movement. The test might, perhaps, have been more carefully tried, and with positive results. But on account of the sympathetic trouble in the other eye the necessity for enucleation was so evident that persistent examination was deemed unnecessary. For this reason also skiagraphic investigation was thought superflous. Enucleation was advised and performed by Dr. Lowman, and the patient was put upon iodide and salicylate of sodium and muriate of pilocarpine.

Dr. Lowman informed me by letter that he found on removing the eye a piece of steel on the dimensions above stated.

April 4th. V'n slightly improved, although there is now a slight opacity of the vitreous.

The case is still under treatment.

CASE XIV. April 27, 1900. *Fragment of steel 4½ mm. by 2½ mm. in upper part of vitreous chamber, accurately located and removed with the magnet. A good visual result probable.*

J. C., aet. 23, boiler-maker's assistant, while chipping steel steps for a ladder, felt something strike the left eye. The accident happened three hours before I saw the patient, who was brought to me by Dr. D. A. Dean of this city. On examination a small wound was visible to the nasal side of the middle of the upper lid, and 1/8 inch above its free margin. Another wound about 2 mm.

in diameter was seen in the globe 5 mm. from the inner margin of the cornea, and just above the horizontal meridian. The eye was slightly suffused. Pupil normal. V'n = 1 p. Ophthalmoscopic examination showed some streaks of blood running towards the upper part of the globe, in which region there was what seemed to be a flat hemorrhagic extravasation lying close to the inner wall of the eyeball. In moving the magnet tip round the globe sensation was quickly evoked, and a slight movement of the sclera observed at a point situated 1 cm. above the upper corneal margin, and about 4 mm. to the outer side of the vertical meridian. A vertical incision in the conjunctiva was made in this region, the edge of the superior rectus held aside, and the sclera exposed. After further cocainization and the free use of bichloride solution 1-4000, a somewhat oblique incision was made in the sclera, as suggested by Knapp. The magnet tip being now held close to the wound, the foreign body was soon withdrawn. No loss of vitreous.

April 30th. Patient has been perfectly comfortable. Eye free from congestion. V'n, counts fingers at six inches in candle light, and improving every day.

DISCUSSION.

Dr. JOHNSON. I think the doctor's conclusions regarding the eventual results to the vision in cases of iron in the vitreous are very nearly correct. In most of these cases, even though successful in removing the iron, the result is a subsequent loss of vision. The operation is worth while, however, if it results in saving the eyeball itself, for an eyeball, if quiet, is more desirable than an artificial eye.

Regarding the strength of magnets it seems to me the magnet that is strong enough to be classed among the giant series is not of necessity so strong as to drag the eye out at the same time that it draws an object from it. I was rather amused at the description of the Haab magnet in one of our daily papers recently, which pictured the eye as being drawn out two inches, and the foreign body jumping out and smacking against the magnet. I suppose in due course of events the eye flew in again. I do not think it is necessary to have such powerful magnets. So far as

I am able to determine, the magnet which I devised myself has sufficient pulling power; according to the test made by Meyrowitz, its power is only equal to about 1/6 of the strength of the Haab magnet. I do not believe the test made was fair, for I do not think the wood used in the test bore a proportionate relation in area to the size of the core of the magnets.

There is a large portion of radiating energy going from the core of the magnet which adds to the apparent electro-magnetic force unless the non-conductor is interposed, equal in area to the size of the tested magnet core. I believe that a magnet possessing portability and a sufficient amount of force is better than one that is stationary, even though the larger magnet be stronger

I make it an invariable rule to approach the eye with the small or weak end of the magnet at first; the strength of a magnet tip decreases as the distance from the core of the magnet increases.

Dr. JACKSON. I would like to ask what current Dr. Lippincott uses to operate this magnet?

Dr. LIPPINCOTT. It requires the continuous current; the alternating current is not available for this purpose. No special connection other than the ordinary lamp socket is required, and the instrument can be used in all buildings that have a dynamo in the basement.

My magnet, instead of being too strong, is, in my opinion, scarcely strong enough. If we could only suspend the Haab magnet I believe that would be the ideal thing. I am now having a magnet made which will be much stronger than the one presented to-day without being much heavier. A system of winding the coil has been recently introduced which adds greatly to the power of the magnet without much increasing its weight.

Dr. MILLIKIN. I have recently had the opportunity of using the Haab magnet in our Lakeside Hospital, and Dr. Lippincott has, I think, expressed the conditions for the use of the Haab magnet when he stated that the strength of the magnet can be diminished as much as you please by simply changing its distance from the eye. This can be readily done by interposing any metallic substance between the magnet and the patient's eye, such as a pair of scissors, iris or fixation forceps. Recently I have used with much satisfaction in a case a pair of fixation forceps. The closed blades of the forceps were introduced between the lips of the wound, then slightly opened and

the other end brought in contact with the magnet. Immediately the metallic click was felt, and the bit of metal was readily extracted. If one needs it one has in the Haab magnet an instrument sufficiently strong for almost any purpose.

Dr. JOHNSON. In regard to the question of the current for the use of magnets, the alternating current must necessarily be transformed into a direct current. For the Haab magnet a dynamo is required that furnishes about thirteen ampères of current, and for Dr. Lippincott's instrument I should think it would require about two ampères; my own requires about 1/2 ampère. The majority of small cities use the alternating current for lighting purposes, and that must be transformed into the direct for the use of any magnet. An apparatus for this purpose would cost about $100 for my magnet, while one for the Haab would cost perhaps $250. I suppose there would be very little difference in cost between one for my own and one for Dr. Lippincott's magnet.

A CASE OF TRANSIENT SPASTIC CONVERGENT STRABISMUS.

BY SAMUEL THEOBALD, M.D.,

BALTIMORE, MD.

Spastic convergent strabismus, or strabismus from tonic spasm of the internal recti muscles, a condition to be sharply differentiated from ordinary concomitant convergent squint and from squint due to paralysis of the abducens, is one of the well-recognized ocular manifestations of hysteria; but, apart from this, it would seem, deserves to be regarded as a rare anomaly, to which, as a rule, the text-books upon diseases of the eye devote but scant attention.

De Schweinitz, in the paragraph of less than five lines which he devotes to "spastic strabismus," * says that it occurs only under rare circumstances in hysteria and brain diseases (meningitis). It is difficult of diagnosis, periodical concomitant squint

* Diseases of the Eye, third edition, p. 554

in hypermetropia being sometimes inaccurately described as due to spasm of the internal rectus (Mauthner)." Jackson, in a paragraph of equal brevity, says " deviations of the eyes due to spasm of the ocular muscles attend hysterical seizures and some forms of brain disease. They may assist in the general diagnosis, but have little localizing value, and require no treatment apart from that of their cause."* Fuchs, though he states that " tonic spasms of the ocular muscles are extremely rare," adds that " many cases of intermittent strabismus belong under this head," and he mentions two cases of this character which he had observed in hysterical women.† Roosa says children in whom optic neuritis is found to be present are often brought to ophthalmic clinics with strabismus in its early stages, which is non-paralytic. " Every careful observer," he adds, " will take great pains to determine in a given case of suddenly-occurring strabismus, that there is not some cerebral lesion. During dentition certain children are apt to squint." This, he thinks, " may fairly be ascribed to cerebral irritation."‡ Duane, in his chapter upon " Movements of the Eyeballs and their Anomalies," in De Schweinitz and Randall's American Text-Book of Diseases of the Eye, Ear, Throat, and Nose (p. 511), treating of paretic and spastic squint, says " spasm, which is much less frequent than paralysis, is due to irritative lesions (meningitis, etc.), chorea, epilepsy, and hysteria; rarely is idiopathic." Noyes, Norris, and Oliver, Fick, Nettleship, and Swanzy, so far as revealed by a glance through their respective treatises upon diseases of the eye, make no mention of the subject of spastic strabismus.

In Norris and Oliver's System of Disease of the Eye, Parinaud, treating of the ocular manifestations of hysteria, considers at some length the " anomalies of convergence " occurring in this condition. If we would understand the anomalies of the movements of the eyes in hysteria we must, he says, " consider that neither muscles nor nerves, but nerve centers, and, indeed, the higher centers, are affected — those whereby the movements

* Diseases of the Eye, p. 234.
† Text Book of Ophthalmology, p. 576.
‡ Diseases of the Eye, p. 553.

themselves are brought into unison with psychic action;" and, he adds, "another fact connected with a study of hysterical disorders of the ocular apparatus is that they are almost always of the nature of contractures, even when they present the objective characteristics of paralysis."* In the same volume (pp. 708 and 710) Santos-Fernandez, writing of the "ocular manifestations in influenza," mentions cases of paralysis of the third and sixth nerves, and of "convergent strabismus" as having been observed in this affection, while Culver, in the chapter upon "Anomalies of the Motor Apparatus of the Eye," says, "Changes in the centers of innervation as *primary* causes of strabismus are admissible only in certain definite cases," and, again, "Convergent strabismus may be due also to a *spasm of convergence*, independently of accommodation and refraction. We have observed cases of this kind in hysteria. It is perfectly admissible that the same phenomenon is produced in consequence of other irritations of the center of convergence."†

Briefly described, the case which I wish to report is as follows:

A little girl, seven years of age, convalescing from a pronounced attack of influenza, a marked feature of which had been persistent and severe headache, and during the course of which an otitis media had developed in the right ear, complained of diplopia, and on the following day exhibited an evident squint. At the request of the attending physician, Dr. W. D. Booker, I saw the case on the second or third day after the squint manifested itself.

There was present at this time in both distant and near vision a very decided convergent squint of the left eye. There were no signs of paresis of either rectus externus — each eye could be rotated outward farther than is commonly possible, and neither the extent of the squint nor the diplopia was influenced by the direction in which the head or the eyes were turned. The ophthalmoscope revealed a hypermetropia of rather more than 2 D, and, as I had previously performed a tenotomy upon the little

*Vol. IV, p. 754.
†Op. Cit., p. 100.

patient's mother for a pronounced esophoria, I concluded that the influenza had been the straw which had broken the camel's back, and developed a concomitant squint in a child who had, probably, inherited insufficiency of the external recti muscles and who was decidedly hypermetropic. That the trouble would be overcome without glasses or an operation seemed to me highly improbable. Dr. Booker had already prescribed iron and quinine and a nourishing diet, and the general condition of the patient was improving from day to day.

At my second visit, four days later, although the mother reported that the eyes had been straight at times during this interval (?), I found the squint unchanged except that it showed, perhaps, a greater tendency to alternate. Thinking that suppression of the accommodation might favorably influence the squint, I directed a two-grain solution of atropia to be dropped into the eyes twice a day. Two days subsequently, the eyes being thoroughly under the influence of the atropia, the squint seemed somewhat less marked. My next visit was five days after this, and, to my gratification, I then found no trace of the squint remaining. Not only so, but even with the cover test it showed no disposition to recur, and an esophoria for distance of only 4° was shown by the Maddox rod. A decided change for the better in the general condition of the patient was also evident.

After another interval of four days, the eyes meantime having remained quite straight, the atropia was discontinued, although, I confess, I still had serious misgivings as to what would occur when the ciliary muscles began to regain their activity. However, my apprehension proved to be groundless, for a week elapsed without any recurrence of the squint, by which time she had recovered her power of accommodation sufficiently to be able to read ordinary print. The Maddox rod now showed an esophoria for distance of only 3°, while, more noteworthy still, the vertical diplopia test showed at 12″ a so-called exophoria of 4° — a practically normal muscle balance. Since then the eyes have given no further trouble.

A few days since (April 26th), nearly two months having

elapsed since the disappearance of the squint, the muscle balance was tested with the following result:

Esophoria, $20' = 1°$. } Rod test.
No hyperphoria, $20'$. }
Exophoria, $12'' = 1°$. (Vertical diplopia test.)

That the squint in this case was a purely spastic one, due, doubtless, to an irritation (of influenzal origin) of the innervation center which controls the associated action of the internal recti muscles, is, in my judgment, not open to question. Had it been a concomitant squint, precipitated by the attack of influenza, as I at first supposed, it might, indeed, have disappeared under the influence of the atropia and with the improvement in the patient's general condition; but, under such circumstances, a normal muscle balance would certainly not have been re-established in the space of a few days, as actually happened. On the contrary, a marked and probably persistent esophoria would certainly have been encountered.

As to abductor paresis, I have already said there were no signs whatever pointing in this direction; but, apart from this fact, the rapid return of the lateral muscles to a condition of practical orthophoria, is as little consistent with this view of the case as it is with the view that the squint was a concomitant one.

An incomplete search through the literature of the subject has revealed only one case which bears a close resemblance to my own. In the Archives of Pediatrics, Vol. I, p. 634, Dr. Samuel S. Adams, of Washington, reports an interesting case of convergent strabismus as a sequela of diphtheria, in which paresis of the external recti muscles was excluded, and which he attributed to "a spasm or over-action of the internal rectus," due to an irritation of the center of ocular adduction. The squint disappeared completely within a few days of its onset.

DISCUSSION.

Dr. HOWE. To corroborate what I said this morning I wish to observe that Theobald's case shows that our tests for the dis-

tance are not reliable. If one will take the trouble to test not only with the Maddox rod, but also with the prism and the phorometer, and then to compare the results, he will find that a very large proportion of cases, especially when the accommodation is not at rest, give contradictory results. I would call attention now to these diagrams which illustrate some of the differences between such tests (showing diagram), and hope to bring up the subject again later.

Dr. HARLAN. It may be of interest in connection with this case to refer to one of regularly intermittent strabismus that I reported to the Society some years ago. A child four years of age had a convergent strabismus of 3 or 4 lines every other day, lasting throughout the day, while on the alternate days the axes were apparently quite parallel. I was unable to detect any refractive error by the ophthalmoscope, but another surgeon who saw the case thought that he found a low degree of hypermetropia, and convex glasses were worn for some time without result. This regular intermission lasted for more than a year, when it was suddenly broken by the occurrence of the squint on an off day. Afterwards there were only occasional and irregular intermissions.

Dr. ALLYN. I recall a case of squint in which every other day the child showed a strabismus of 2 or 3 lines. The suggestion to my mind was that it might be due to malaria, and under the use of quinine it promptly disappeared.

Dr. JACKSON. A few years ago I saw a case of spastic squint that recovered under atropine. It had followed diphtheria. I have also noticed very marked loss of accommodation following influenza.

Dr. THOMAS. Dr. Harlan will perhaps remember a case he saw with me about twenty years ago, a boy about four years old who had intermittent squint. After a year it became a settled strabismus, and operations were performed, first a complete tenotomy, and then graduated ones during two or three years, until perfect muscular balance was obtained. The young man is now twenty-four years of age, and within the last month I have seen him, the eyes remaining perfectly orthophoric.

Dr. THEOBALD. I should have said in my paper that there was no disturbance of the pupils or of the accommodation in this case, and that the vision was quite normal. In regard to Dr. Howe's observation, I may say that I do not confine myself to the Maddox rod, but use the Maddox prism and the vertical diplopia test as well. I have not found anything comparable to

the examples of contradictory results which his tables show. Dr. Verhoeff, working with me at the Hopkins Hospital, tells me that he finds some cases in which the Maddox rod used to measure esophoria gives an exaggerated result, but I have not found this to be the case myself. As to the cover test, of course, the question of personal equation comes into play, since some observers may detect slighter movements of the axes than others.

CLINICAL STUDY OF THE OCULAR SYMPTOMS FOUND IN SO-CALLED POSTERIOR SPINAL SCLEROSIS.

BY CHARLES A. OLIVER, A.M., M.D.,

PHILADELPHIA, PENN.

The following broad generalizations of the ocular symptomatology found in so-called posterior spinal sclerosis (a disease according to the newest teachings dependent upon an atrophy or degeneration of the sensory neurones, followed by sclerosis, though most probably antedated by varying degrees of low-grade inflammation) are the results of a series of most carefully applied studies extending over a period of more than five years. Much of the clinical work has been obtained from the services of the two great hospitals with which I am connected. Every case studied, now amounting to more than one hundred properly made uncomplicated diagnoses, has been submitted to a routine examination embracing every detail of relevant value, while several have been carried to the post-mortem room and the microscope table for further examination as to the histological and pathological changes in the ocular structures.

Given in this way, as a brief résumé of the entire work, and a crystallization of the whole, as it were, the subject-matter may be fairly assumed as having some weight in scientific medicine and of being of working value to the clinician. As such it is offered.

Recognizing, even from the ocular standpoint, the broadness of the subject and its many ways of approach, the main and most

salient points have been robbed of all detail, dyscrasic differences have been eschewed, and everything that has been considered worthy of notice has been given in a few brief words of description.

Realizing from an extensive clinical study the great primary divisions of the disease into a very badly-termed preataxic and an ataxic stage — better an initiative (or probably inflammatory) and a degenerative stage — the separation of the subject-matter into two great clinical subdivisions (cerebral) "optic type,"* and the spinal type, which latter many neurologists subdivide into the lumbo-dorsal and the cervical, is offered merely for sake of convenience and greater ease of comprehension, reserving for a later and more extended paper upon the different phases of the subject, the minute divisions and special ramifications of the disease in its etiological and histological bearings to a number of more specialized articles which will appear from time to time as experimental work may accumulate and pathological material warrant.

The gross "optic type," appearing in about 10 to 15 per cent. of the total number of cases (the average age in my series having been forty-two years, and the male sex predominating by 90 per cent.), is at first shown by fair if not normal vision. This is followed, without the appearance of any gross general symptoms or even pupillary changes in the majority of cases, by a whole series of visual paræsthesias and somewhat irregularly contracted fields of vision for white, with markedly diminished ones for color. In association there are frequently slightly marked, though undeniably present, spastic movements of the extraocular muscle series, combined with both normal and even exaggerated deep reflexes as particularly seen in the patellar tendon groupings. In this stage, in the majority of cases,† the tissues of the optic nerve head will be found somewhat swollen; the edges of the disc will

* By some classed among the cervical groupings.

† Unfortunately, this stage will be the one that is most infrequently seen, unless every case of ophthalmic disorder presented to the clinician in which an ophthalmoscopic study can be made is submitted to routine methods of examination, as has been constantly done by the writer.

appear slightly hazed; the retinal arteries, especially in the syphilitic types of the disease, will exhibit perivascular change; the retinal veins will be more or less tortuous; and slight disturbances in the chorioid will be manifest.

Sooner or later this grouping of irritative and inflammatory signs will be followed by symptoms of degeneration, each case being complicated with an intervening stage of apparent betterment of both the objective and the subjective conditions, lasting for varying periods of time, and dependent in most instances upon the grade of the disease, hygiene, and therapy.

The disease not kept in abeyance, atrophic processes in the optic nerves gradually and with only too great certainty take place. The optic nerve-head substance becomes intensely greenish-gray in tint, particularly in its temporal half. Its general capillarity lessens, the nerve-head borders again become visible, its surface sinks smoothly and quite evenly, exposing the cribriform plate in some instances, while the retinal and chorioidal tissues about its edges appear somewhat thinned and degenerate.

If perivasculitis has been present, the lymph-channel walls remain both thickened and opaque, while the vascular lumens are frequently encroached upon and diminished in calibre. If there has not been any perivascular change, the blood-streams, particularly the arterial, become narrowed and offer but slight contrast in tint to that of the contiguous structures.

Vision for both form and color, which may have induced false hopes for permanent betterment by having arisen to varying degrees of acuity, saturation, and kind — and even in some instances to what is ordinarily supposed to be normal — gradually decrease until at last all light-perception is gone.

The visual fields having broadened in a few cases, and in quite a number of instances having shown a fair amount of color saturation, again contract, as a rule, most irregularly without the presence of any scotomatous areas until sector after sector of the retained portions are removed and naught but absolute blindness remains — a blindness which though terrible in itself seems in some instances to limit and even lessen many of the gross motor

signs, and prevents the occurrence of the horrible visceral crises which make the lives of some of the cases frightful even to contemplate.

During this stage the preataxic, as it is improperly called by many, and at times even rather early in it, some of the well-known pupillary, ciliary, and extraocular muscle signs become manifest in at least 30 to 50 per cent. of the cases. Both temporary and permanent failures of iridic reaction to light impulse (80 per cent.), with frequently uncontracted oval and ovoid pupils; commencing inability of continuance of forced lateral monocular and binocular fixation, with tremulousness of palpebral movement; doubtful slight pareses of convergence, and paretic diplopias of various kinds are among the prominent motor signs present.

Later, after the most variable of periods, though unfortunately only too frequently quite early in the course of the disease, without the appearance of many of the ordinary gross general expressions of the condition, the completed ocular picture of absolutely irremediable total blindness in the two eyes generally appears. The aimless gaze, the contracted pupil, the failure of the iris light-reflex, the increasingly uncertain movements of the iris to accommodative and convergent efforts, the extraocular pareses, with palpebral fissure narrowing, even the epiphora in a few instances, and the not rare spontaneous twitchings of the sympathetic fibers of the orbicularis muscles during both forced and ordinarily imperfect action, are offered the ophthalmic clinician as some of the main and most important ocular guides* for the diagnosis of the disorder.

The other type of the disease, "the spinal," in which the classic symptoms of paræsthesia, in the trunk and upper and lower extremities, lancinating pains, enfeeblement of the muscular and temperature senses, rapid fatigue, inability to walk backward, loss of manual dexterity, etc., followed by lessening and loss of the main deep and superficial reflexes, inco-ordina-

* Hypotony, in some instances most doubtful, was found in but 15 per cent. of the cases studied.

tions of the most bizarre types, and crises (often barometric in type) of the most excruciatingly painful and serious character, seldom finds its way into the ophthalmic dispensary. In consequence, this form of the disorder is not so frequently seen by the ophthalmologist unless he have the wards of a large general hospital or the outdoor practice of a special hospital for nervous diseases at his command.

For long periods of time, in spite of coarse objective appearances of the optic nerve-head, good and even normal vision in fairly large form, though markedly decreased, color-fields of irregular and slightly indented shapes in the great majority of instances are found. Miotic pupils, often pin-point in size, with intermittent losses of light-reaction until at last the irides remain absolutely fixed to the strongest and the most prolonged light-stimulus,* are common. Early ataxias of all kinds, connected with the sixth, the third, the fourth, the fifth, and the seventh pairs of nerves, quite irregular in character (even to the slightest asthenopias, and uncertain pareses of accommodation), very variable in degree, and markedly interchangeable, seem at times to even usher in the main clinical aspects of the disease; while minor expressions of optic nerve head and adjacent retinal change, such as very slight greenish-gray discoloration of the tissues of the optic disc, shallow and broad cuppings of the disc-substance back to the lamina cribrosa (which is very frequently visible), and a diminution of the retinal circulation without perivasculitis or retinal hemorrhage, represent the most pronounced findings with the ophthalmoscope. In fact, in spite of all these symptoms it seems that there is an absence of all gross inflammatory signs in the ocular structures, even in association with the coarsest general disturbances of the disease, such as dystrophies and the grossest trophic disorders.

These objective and subjective signs, both constantly and intermittently progressive and markedly interrelated, express their presence upon a sensory functioning power at first during

*The so-called sympathetic skin reflex of the iris — a most uncertain sign to obtain in this class of subject — was undoubtedly absent at times in some of the cases.

exposure to feeble external stimuli, until at last nothing but small peripheral areas of light-perception in the lower temporal fields constitute the last visual expressions of physiological action, and exhibit their influences upon an unstable and variable motor apparatus that finally becomes fixed and at times all but useless.

SPASM OF ACCOMMODATION IN GLAUCOMA RELIEVED BY ESERINE.

BY J. A. LIPPINCOTT, M.D.,

PITTSBURG, PENN.

Mrs. J. G., aet. 30, a blonde and rather delicate-looking woman, consulted me March 3d of the present year, when she gave me the following history: Her eyes were never very strong, and there has been no sight to speak of in the left for ten years. Of the manner or circumstances of its failure she is unable to give a clear account. Two years ago after an operation for lacerated cervix and uterine prolapse the sight in her right eye began to fail. The impairment in vision progressed gradually but steadily up to the present time, being accompanied by occasional rather severe attacks of pain with rainbow vision. *Status præsens* — V. R. E. 20/C. L. E. lp. Left eye deviates upwards about 20°. Pupils of both eyes 7 mm. in diam. Deep vessels of globe slightly dilated and tortuous, but sclera on each side of normal tint. No haziness and no special anæsthesia of cornea. No special increase of tension perceivable.

Ophthalmoscopic examination of right eye showed clear media. The disk presented a characteristic and deep glaucomatous excavation, and was surrounded by a halo. The disc floor was mottled and silvery blue in tone. The retinal vessels were tortuous, the veins being rather larger and the arteries smaller than normal.

The left fundus was not so distinctly seen owing to a moderate haziness in the anterior part of the vitreous, but the general appearances were similar to those in the other eye ground.

The vision of the worse eye — the left — could not be improved by any glass, whereas on testing the right I found that the patient with — 4.5 — 1. cy 145° could make out 20/XXX —. Read best with — 1.5 — 1. cy 145°. The refraction in the blind eye could not be estimated ophthalmoscopically with any degree of accuracy on account of the opacity of the vitreous. The right visual field, which was much contracted, was limited practically to the lower outer quadrant, the extreme outer boundary being at 50°, the lower at 25°, the inner at 5°, and the upper at 15°.

A solution of eserine gr. 1/5 ad ℥j was ordered to be used morning and evening.

March 10th. — Pupils 6 mm. in diameter. V. R. E. 20/XXX —. With 1. cy 148° 20/XXX+. Adding the — 4.5, which at the first visit improved her sight so much, now impairs it decidedly.

March 16th. — Pupils 5½ mm. Vision and refraction same as at last visit. The patient, who has been suffering from a cold, has had pretty severe pain in both eyes, especially the left. The eserine solution was increased in strength to gr. 2/5, and to it was added morphia sulphate and cocaine muriate of each gr. i ad ℥j.

March 20th. — Has been almost free from pain. Pupils 4½ mm. V. = 20/LX. With — 2. — 1. cy 148° = 20/XXX+. Visual field to-day shows enlargement, chiefly downward, the lower boundary reaching 45°. The innermost point also has moved to near the 30° circle.

Careful measurement of the excavation to-day makes the depth 2 mm. Inasmuch as the accommodation was being overstimulated by the eserine I directed a suspension of the myotic until the next day.

March 21st. — Thirty hours since last instillation of eserine. No pain. Pupil 5½ mm. T'n +½. V. 20/LX —, and with — 1.5 — 1. cy 148° = 20/XX —. As the effect of the eserine

upon the accommodation must by this time have passed away, it was evident that there was a return of the *glaucomatous* spasm, and I therefore directed the resumption of the weak eserine solution (gr. 1/5, with morphia sulphate gr. j ad ℥ j).

March 26th. — Pupil 4½ mm. and more sensitive to light. T'n normal. V. 20/XL. With +.5 —1. cy 148° = 20/XX—. Eserine solution reduced to gr. ¼ ad ℥ j.

April 7th. — Has had a rather severe attack of suppurative tonsilitis. R. E. with — 1. — 1. cy 148° V. = 20/XXX.

L. E. some pericorneal congestion.

April 16th. — R. E. with — .25 + 1. cy 148° V. = 20/XX —, and reads best by adding + 1.25 to above.

Vitreous haze in left has almost disappeared and skiascopy shows simple MAs = 3 D axis horizontal. Optic disc excavated to a depth of 2 mm. (About the same as R. E.)

April 25th. — T. normal. Pupil 6 mm. in diameter. R. E. with + 1. cy 58° V. = 20/XX —. Reads best with the same. L. E. V. not improved.

A very similar case is reported in the Klinische Monatsblätter für Augenheilkunde for June, 1899, by Dobrowolski of St. Petersburg, who prefaces his report of it by relating a conversation held in 1870 with Nagel in which the latter asked him whether he had observed the phenomenon under consideration in the prodromal stage of the disease, adding that he (Nagel) had seen several such cases. Dobrowolski states that at that time he felt skeptical about the matter.

His patient, 62 years of age, was suffering from chronic glaucoma. R. E. M. V. = 20/LXX. Clear media. L. E. counted fingers at 20 inches. Opacity of the vitreous. Five days later, after the use twice a day of eserine gr. ii ad ℥ j, there was marked myosis, and the right eye had become emmetropic with vision 20/LXX. Stopping the eserine for a day, myopia appeared, to disappear again on the reapplication of the drug. This occurred three times. Pilocarpine, which produced as decided pupillary contraction as the eserine, reduced the myopia only from 1/16 to 1/24, showing that the visual improvement

was not due to the contracted pupil. In the left eye the vitreous opacity yielded to the drug and vision became = 20/LXX, but the myopia of 1/16 remained unchanged.

The view that the visual improvement in the right eye was independent of the myosis was corroborated in my case, as at the second visit, notwithstanding the decided diminution in the myopia, the pupil was 6 mm. in diameter.

Dobrowolski attributes the myopia to a spasm of accommodation produced by irritation of the ciliary body due to inflammatory changes incident to the glaucomatous process. That this explanation is in the main correct will probably be generally conceded, although there may be a difference of opinion as to the existence of a true inflammation in all cases of glaucoma. The fact that the artificial myopia in my case was so much greater than in Dobrowolski's is of course due to the fact that my patient was so much younger and the lens therefore more responsive to ciliary irritation. Indeed the cases must be quite exceptional in which enough lenticular elasticity remains at the period of life most affected by glaucoma to produce, through the irritation caused by the disease, or in any other way, a notable degree of myopia. Further and more exact observation may, however, show that the phenomenon is not so rare in younger persons.

It was interesting to watch in my case the varying action of the eserine on the accommodation according to the strength of the solution employed. At the second visit, March 10th, the relaxing effect of a weak solution on the glaucomatous spasm was evident. At the fourth visit, March 20th, the stimulating influence of a stronger solution, producing the ordinary eserine spasm, was manifest. At the fifth visit, March 21st, the cramp induced by the drug had given way, and the glaucomatous spasm had begun again to show itself. At the sixth visit, March 25th, after the renewed application of the mild solution, the relaxing influence of the latter was clearly shown in the laying bare of the hypermetropic element in the case. This fact of the two-fold action of eserine may have a bearing on the therapeutics of

glaucoma, especially with reference to the strength of the solution employed.

At the last visit, April 25th, there was practically no myopia present, but instead a simple hyperopic astigmatism, and now the accommodative power, which had been in abeyance, was found to have been restored. A gradual improvement in the fields of vision was also noticeable.

THE HISTOLOGY OF THE LACHRYMAL GLAND IN CHRONIC DACRYOCYSTITIS.

By G. E. DESCHWEINITZ, A.M., M.D.,

PHILADELPHIA, PENN.

With Bock,* we may say that the lachrymal gland, independently of neoplastic formation, may be enlarged by an essential inflammation in the form of an acute or chronic dacryoadenitis, by a sympathetic inflammation, that is, in association with inflammatory diseases of the eye, eyelids, or tear-passages, and sometimes by agencies which are not evident. With the microscopic findings in acute and suppurative dacryoadenitis we are not now concerned. The pathological histology of chronic non-suppurative dacryoadenitis is thus summarized by Bock:

"The distinguishing feature in nearly all the findings is the amount of glandular tissue destroyed, and its replacement by accumulations of round cells. The ground-substance for the latter is supplied by the connective tissue in the interior of the gland; this is rich in capillaries and lymph-corpuscles, and in addition to the trabeculæ surrounding the lobules exhibits numerous delicate fibers which ramify among the lobules. The round cells are arranged in rows or 'streets' following the course of the connective tissue; some are collected in large closely aggregated groups, others finally in sharply circumscribed circular foci projecting above the level of the surrounding tissue, so that some authors

* Zur Kentnis der gesunden und kranken Thränendrüse, Wien, 1896.

speak of lymphoma of the lachrymal gland. Raymond mentions amyloid degeneration of the newly formed lymphoid tissue."

Sympathetic inflammation of the tear-gland caused by phlyctenular conjunctivitis, keratitis, corneal abscess, etc., has also been investigated microscopically by Bock, who found the following lesions: "The sections were triangular, and contained part of the conjunctiva from the upper retrotarsal fold. The connective tissue was particularly well developed between the conjunctiva and the gland, and penetrated in robust bundles to some distance among the lobules of the gland. Round cells were scattered throughout the connective tissue, and beneath the epithelium of the conjunctiva there was a continuous layer of closely packed round cells. 'Streets' of round cells could be traced along the fine ramifications of the connective tissue among the lobules. The granulation of the protoplasm of the gland cells was very conspicuous, and the cells were so closely crowded that it was impossible to make out the lumen of a single acinus. The epithelium of the ducts was distinctly swollen; the ducts themselves were surrounded by a dense round-celled infiltration which, around the largest ones, is arranged in the form of small round islands. The bloodvessels were dilated and engorged. The connective tissue underneath the conjunctiva contained colonies of micrococci which occupied the lymph spaces."

The condition of the lachrymal gland in chronic epiphora has been the subject of an interesting research by G. Stanculéanu and A. Théohari.* These investigators examined sections of the palpebral lachrymal gland from (1) cases of epiphora with intact lachrymal passages; (2) cases of epiphora where the lachrymal passage had been made permeable by the passage of sounds; (3) a case of epiphora with impermeable lachrymal passages; (4) a case of epiphora from congenital dacryocystitis. The lesions found consisted of an interstitial inflammation and certain modifications in the cells of the acini. The latter were in a state of degeneration, the protoplasm being converted into a delicate net-like formation containing brightly staining granulations. In the

*Archives d'Ophtalmologie, 18, 1898, p. 737.

lachrymal glands of dogs stimulated to excessive action by pilocarpine they also found a punctuated protoplasmic reticulum, *i. e.*, at the intersection of the lines forming the net-like figure there was a fuchsinophile granulation. The similarity of the lesions under these clinical and experimental circumstances has led the authors to believe that the hyperactivity of the gland brings about a degeneration of the gland-cells.

In connection with the examinations of Bock, and to a certain extent with those just described, I desire to add an observation of my own.

Mary Craig, aged 48, a widow, was admitted to the Medical Wards of the Philadelphia Hospital for gastritis on August 25, 1897. There is nothing of importance in the patient's family history. She is the mother of four living and healthy children; one child died in infancy of whooping cough. The woman herself was usually in good condition, and gave no account of serious illness, other than the gastritis for which she was admitted to the hospital. Dacryocystitis had existed for some time, and she stated that three operations had been performed without relief. On December 10, 1897, entirely recovered from her gastric attack, she was admitted to the eye-wards with advanced right-sided phlegmonous dacryocystitis, the abscess having ruptured externally; the surrounding facial area was red and brawny. The duct was opened; the sinuses curetted and packed with iodoform. Relief was immediate, and for a time satisfactory. Pus having again begun to form, on May 27, 1898, the lachrymal sac (or its remains) and the duct were removed. Again there was a period of relief, although there never was complete stoppage of suppuration, which seemed to come from a pocket which passed upward and inward from the region of the sac. This gave but little trouble, but the epiphora was annoying, and hence on May 10, 1899, the lachrymal gland was extirpated without difficulty, the wound healing promptly. The gland itself was not in the least enlarged, palpation before operation giving only the sensation of a normal gland. Relief from epiphora was complete, but there is still a discharge of pus from the pocket or small sinus pre-

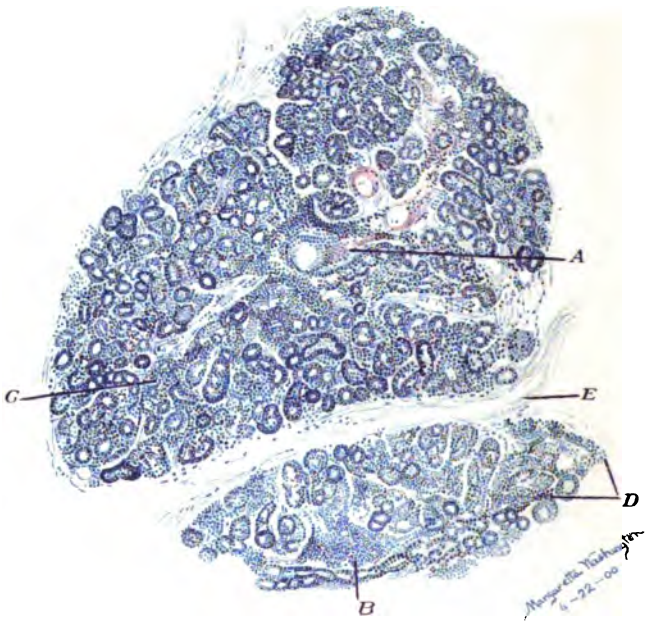

FIG. I. *A*, Round cells (lymphoid cells) surrounding one of the ducts; *B*, Round cells gathered into masses; *C*, General infiltration of interacinous tissues with lymphoid cells; *D*, Cells infiltrating in rows or "streets"; *E*, Interlobular connecting tissue.

viously described, which, I think, leads into the lachrymal division of the ethmoid cells.

The excised gland was immediately placed in a five per cent. solution of formalin, and after hardening sections were cut and stained with hæmotoxylin and eosin. These, which have been studied by Dr. J. Dutton Steele and myself, presented the following appearances:

The acini are well constituted, the nuclei of the secreting cells being normally placed and properly stained. The protoplasm of these cells, naturally granular, appears, as compared with the protoplasm of similar cells from a normal gland, somewhat swollen, with, perhaps, beginning fatty changes, but this swelling is nowhere sufficient to close the lumina of the acini, as Bock describes in his sections. The interacinous connective tissue is everywhere invaded by quantities of small round cells which are irregularly scattered, or especially gathered in rows or "streets," as Bock calls them, or collected in small roundish masses. They are particularly conspicuous around the ducts, which are usually literally surrounded by them. There are no notable changes in the duct epithelium. These round cells have very large nuclei with scarcely any or no surrounding protoplasm, and possess a darkly staining nuclear membrane on the inner side of which may be seen rather large chromophilic grains, the nucleoli in the center being darkly stained. They have therefore the ordinary composition of lymphoid cells, such as are always found in more or less chronic non-suppurative inflammations. Polynuclear leucocytes are not present.

The bloodvessels of the trabeculæ separating the gland-lobules and the interacinous capillaries are not engorged, and their walls are normal. Nowhere has the inflammatory process advanced sufficiently far to destroy the acini; in other words, there is not apparent a destructive process. (Fig. 1.)

It is apparent that the findings in this gland closely correspond with the observations of Bock in the portions of the gland which he removed from patients suffering from sympathetic dacryoadenitis, *i. e.*, a dacryoadenitis called into existence by inflam-

matory conditions of the cornea and conjunctiva. The process, however, appears to be a more chronic one, as there is an absence of engorgement of the vessels and of signs of inflammatory activity. The condition differs from that found in chronic non-suppurative dacryoadenitis (mumps of the lachrymal gland) in the preservation of the acini, *i. e.*, in the absence of a destructive tendency on the part of the interstitial inflammation.

Stanculéanu and Théohari have also found a more or less chronic interstitial inflammation, but have laid the most stress upon the changes in the protoplasm of the cells, changes which are not evident in my sections. As, however, the technique in each instance was different, no entirely accurate comparison in this respect can be made.

It would seem, therefore, as Bock has well shown, that inflammatory conditions of the cornea, lids, and conjunctiva may infect the lachrymal gland and excite an inflammation in it; naturally, chronic dacryocystitis for similar reason may produce similar results, which may be well developed without causing a noticeable enlargement of the gland, or giving rise to clinical signs indicative of their presence.

Tscherno-Schwartz,* on the basis of experiments on dogs, believes that diminution or cessation of epiphora after extirpation of the lachrymal sac is due to a compensatory atrophy of the corresponding lachrymal gland. The right tear-gland was excised from my patient just one year after the lachrymal sac had been removed, and certainly there are no signs of atrophy — indeed, the gland was removed to alleviate the annoying epiphora which had always existed, and which was not helped by the ablation of the sac.

* Nagel's Jahresbericht, XXIX, Zweite Hälfte, 1898, p. 633.

FIG. I. Papilloma of the Plica Semilunaris.

PAPILLOMA OF THE PLICA SEMILUNARIS.

BY G. E. DESCHWEINITZ, A.M., M.D.,

PHILADELPHIA, PENN.

Formerly many growths from the conjunctiva of diverse structure were classified under the collective name polypus or polypoid tumor. Elschnig[1] has provided a satisfactory classification based upon the histological characters of the growths, and Sigmund Fuchs,[2] writing on papilloma of the conjunctiva, has added still further to our knowledge of this subject. Recently Karl Grunert[3] has reviewed the literature to date, and added five observations of his own. Lagrange and Mazet[4] have also published an article on this subject, and described a case of multiple papilloma of the conjunctiva. The following growths we learn may be clinically confused one with the other:

1. Polypi of the conjunctiva, which are pediculated tumors covered with epithelium, and histologically are hard or soft fibromas which, in their growth, have pushed the overlying conjunctiva before them.

2. Angio-sarcomas of the conjunctiva, the cells of which have arisen from a proliferation of the adventitia of the blood-vessels, and in their growth, like the fibromas, have thrust the epithelial covering in front of them. Perhaps some angiomas may act in a similar manner.

3. Papillomas of the conjunctiva,[5] which either are pediculated or arise from a broad base, their surfaces being truly papillary, *i. e.*, like a cauliflower. Histologically they resemble the structures of the papillæ; but as they may arise from parts in

[1] Archives of Ophthalmology, Vol. XVIII, 1889, p. 255.
[2] Archives of Ophthalmology, Vol. XX, 1891, p. 537.
[3] Klin. Monatsbl. f. Augenheilk., XXXVII, 1899.
[4] Annales d'Oculistique, T. CXIX, 1898.
[5] This growth may be mistaken for epithelioma, especially when it occurs at the corneo-scleral border.

which no papillæ exist, they cannot always be said, as Fuchs points out, to be an excessive development of normal papillæ. They have been likened to ordinary cutaneous warts and pointed condylomas.

4. Granulation tumors, which have been compared in appearance to minute mushrooms, but which are not covered by epithelium. These growth are composed of granulation-tissue, which has arisen at a spot from which the conjunctical epithelium has been abraded.

The case which I report belongs to the third of these classes, the growth having arisen from one of the points of predilection, viz., the plica semilunaris:

William Adams, a negro, aged about fifty years, was admitted to the Nervous Wards of the Philadelphia Hospital on account of right hemiplegia. His general clinical history is unimportant. The resident physician, Dr. Roberts, noticed a small conjunctival growth arising from the neighborhood of the inner commissure, and brought him to the eye-ward for examination. The patient stated that the tumor had been present for many years, and gave him no special inconvenience; so far as he knew it had not increased in size. There was no history of injury, of chronic conjunctival catarrh, or of any condition which might have caused the neoplasm.

Examination. — The eyes themselves were fairly normal; the conjunctiva and lids gave no evidence of disease. Growing by means of a well-marked pedicle from the right plica semilunaris, a little in advance of and below the center of the caruncle, was a growth 6 mm. in height and 5 mm. at its broadest part, of typical cauliflower appearance. Its color was yellowish-white, and passing upward from it was a large tortuous vein, while a few enlarged subconjunctival vessels passed over the bulbus from its base. (Fig. 1.) The growth was excised, and its bed cauterized.

After hardening in five per cent. formalin, sections were cut by Dr. Shumway, and stained with hæmotoxylin-eosin. Their microscopic appearances may be seen in the accompanying illustration (Fig. 2), and are as follows: The framework consists

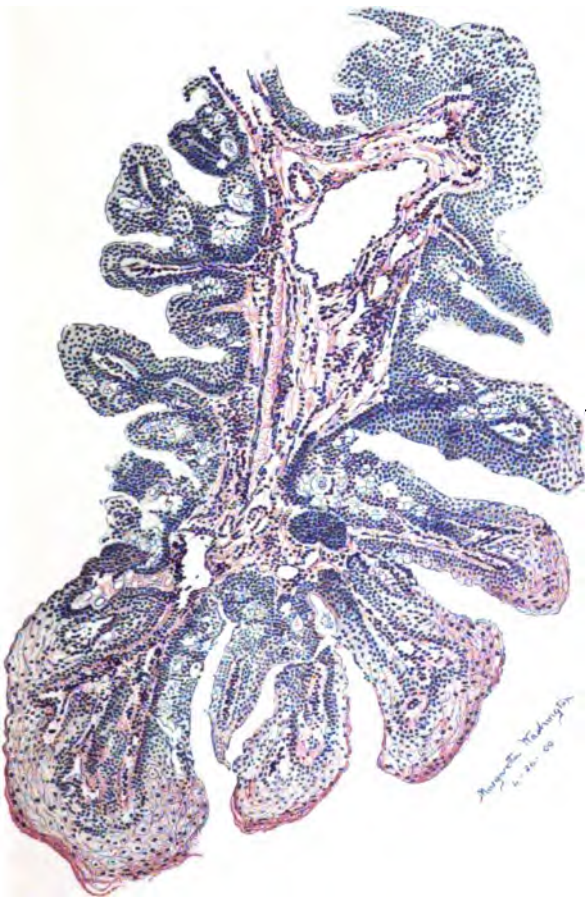

FIG. II. Microscopic Appearances of Papilloma of the Plica Semilunaris.

of connective tissue, rich in cells and bloodvessels, the latter terminating in capillaries. From the central stem proceed numerous branches or finger-like processes covered with thick layers of epithelium. Near the surface this epithelium assumes the stratified squamous or pavement appearance, while those cells near the connective tissue are cylindrical in shape. Concentric whorls of epithelium, such as occur in epithelioma, are not present; but small neurotic areas are not infrequently to be seen. The growth is therefore a soft papilloma, as the term is ordinarily used, and belongs, as before stated, to number three of Elschnig's classification.

A LANTERN FOR DETECTING COLOR-BLINDNESS IN RAILROAD EMPLOYEES.

By WILLIAM THOMSON, M.D.,

Emeritus Professor of Ophthalmology, Jefferson Medical College.

By an evolution of the Lantern of Donders which has for years formed a part of the examination of the ophthalmic surgeon in the system in use on the Pennsylvania Railroad I have produced an instrument which, like the "color-stick" of wools, can be used in all testing for color perception. While the wool tests have been accepted universally as requisite for the detection of color defects, the employees of railroads and their friends have always objected to their use as having no relation to their daily duties, and have demanded such colors as are employed as signals. Furthermore, for two-fifths of the time, during the night, of an employee's life he is expected to govern his actions by colored lights, and this lantern appears to have a practical value in imitating the night signals in form, color, intensity, and size, as they appear under all obstructions caused by rain, snow, fog, and smoke. Its power over the wools to detect the central amblyopias of tobacco, alcohol, drugs, disease, and scotomata that would not be revealed by the skeins, makes it almost a necessity.

I propose this lamp or lantern then as an adjunct to the "color wool stick," to be used, if desired, under the supervision of the division superintendent by intelligent laymen. With this addition to the Pennsylvania Railroad system it seems to me more complete, and sufficient to eliminate from any road all color-blind employees and to furnish an insuperable barrier to their admission to the service.

It consists of an asbestos chimney, which can be placed on the kerosene lamp in universal use on railroads, or over an Argand or other gas light, electric lamp, or spring candlestick. Two discs four inches in diameter are so placed upon the chimney as to permit of their being superimposed partly. The lower disc contains ten glasses in apertures 10 mm. in diameter, having the white, red, green, and blue colors in general use on railroads.

This may be considered the examination "in chief," while the upper disc, when combined with the lower by turning one or both, furnishes the "cross-examination." The upper disc has four apertures, ranging from 1 to 10 mm. The other six have one white ground glass, one deep London smoke, one medium London smoke, one pink, one green, and one Cobalt glass.

The combination of the white ground and the smoke glasses with the reds and greens of the lower disc enable all atmospheric conditions to be imitated, and the lights to be diminished in brightness and tint. The placing of the small openings enables size and distance to be imitated.

The standard of normal color sense is taken as 1 mm. opening at 5 meters. A man failing to see the light at this distance may have it increased ten times. Again failing, he may approach to half a meter and reveal a color sense equal to 1/100 only. Since the color-blind depend alone on intensity or brightness to distinguish the white, green, and red colors, the diminishing effect of the ground glass and of the London smoke often reveals the defect. The Cobalt, transmitting blue and red both, is usually described by the color-blind as blue, which color they always see well. The Cobalt combined with the lower reds, gives a very deep red color which, when compared with the usual red, may induce the color-blind to name one red, the other green: combined with the lower blue it gives a deep pink, called blue by the color-blind.

In the pink, medium smoke, and light green glasses in the upper disc I have imitated the "confusion colors." The pink looks cherry red to the normal eye, but it transmits both red and blue by the spectroscope, hence the color-blind pronounce it blue, or when backed by the yellow kerosene flame, white. The light green is always called white, as is also the light gray of the medium London smoke; hence, we have in these three glasses tints which the color-blind name white.

The upper disc has its ten openings marked by the letters of the alphabet, and its lower by the numerals from 1 to 10. The examination should be made in a darkened room, and the results

reported on the blank now in use, the details being used when requisite. The man is expected to call or name the colors.

An interesting experiment can be made by the ophthalmic expert in his demonstrations to the division superintendent and his examiners, by placing the chimney over an alcohol lamp containing some sodium chloride. The mono-chromatic lights thus formed destroys all the colors in the glasses and renders the observers for the time totally color-blind. The stick of colored wools should also be illuminated by this means, and its power to destroy the ability of the normal-sighted to select the colors, will enable them to partly comprehend the defect of the congenital color-blind for red and green.

The system of the Pennsylvania Railroad has been in use since 1881, and has been adopted by other corporations controlling 150,000 miles of track. It may now be considered complete.

Norris and Oliver's work on Diseases of the Eye contains an account of the entire system. It has been published also in Nettleship's book, and the last edition about to be issued has a full description of the lantern and of other novelties. Queen & Co. supply all the instruments used, which are accompanied by a certificate of their accuracy signed by Dr. Thomson.

AN IMPROVED LANTERN FOR TESTING COLOR-PERCEPTION.

By CHARLES H. WILLIAMS, M.D.,

Boston, Mass.

At the last meeting of this Society I showed the lantern which I had arranged for the Eastern District of the New York, New Haven & Hartford Railroad, and which is now being used by

them in their routine examinations of the color-sense, and to-day I have brought a new one with a number of improvements suggested by the use of the old lantern during the past year.

The new lantern is about twelve inches high and six inches on each face; it is square in shape, and carries on its front two discs; in the lower are thirteen glasses, five reds and five greens of different shades, including a red glass that transmits a certain amount of green when examined with the spectroscope, and a green glass that in the same way is seen to transmit a certain amount of red; for such glass is often found in signal lanterns, and is more easily mistaken by persons with defective color-perception than glass that transmits a purer color. The disc also has one blue, one yellow, and one colorless ground glass.

The upper disc carries three shades of smoke glass and some open spaces, so that by rotating these discs any of the colored glasses can be shown either alone or combined with any of the smoke glasses to alter their intensity. Inside the lantern are two pieces of ground glass arranged so that they can be placed in the path of the light or withdrawn, and by combining these ground glasses with the colored glasses and the smoke glass the effects of fog and smoke on signal colors can be well represented. The lamp of the lantern has two burners with a screen between them, and in front of each burner is an opening in the front of the lantern so that two colors can be shown at one time in comparison, or if it is desired to show only one color a diaphragm can be moved so as to cut off one of the lights. In this way two reds of different shades, two greens, a red and a green, a red and a white, etc., can be shown either in their full color or with modified intensity, and if it is desired to vary the size of the colored area shown it can be done by moving a diaphragm placed between the discs so that colored circles of three different sizes can be shown. It is best not to use the smallest holes with the darkest smoke glass, as it cuts off too much of the light, but with this exception any combinations can be used. Underneath each colored glass in the disc is a number illuminated by the lamp so that it can be easily seen by the examiner, but screened from the person examined, and underneath each smoke glass is a similar letter; in this way it is easy for the examiner to make note of the glass shown and the name given to it, and thus keep a complete record of each examination.

It is easy to make a satisfactory test with this lantern either by day, in a darkened room, or by night; the colors do not fade, they resemble very closely the signals in actual use, and this test will often detect a small central scotoma with defective color-perception that might be overlooked by the ordinary tests; these are very dangerous defects, because the retinal image of a distant signal light may be formed entirely within the area of this scotoma and not be recognized. In fact I have had during the past year four cases who passed the test with colored worsteds, both

Holmgren's and Thomson's, without making any mistakes, but who failed with the lantern; in these cases there was a history of excessive use of tobacco, and apparently the scotoma was limited to a very small area, so that when the test was made with a skein of worsted its retinal image was large enough to extend beyond the affected portion of the retina and a part of the image fell on retina where the perception was acute enough to recognize at once and correctly the color, whereas with the lantern or with signal lights the retinal image was formed entirely within the affected area, and was not recognized. It is very necessary, in order to have a thoroughly satisfactory test, to make the examination both with the worsteds and with the lantern, as has been done for many years on the railways of Holland. With the present form of lantern these tests can be easily and quickly made, and the results do not depend solely on the decision of the examiner, but are a matter of record and can be verified at any time if necessary.

DISCUSSION.

Dr. THOMSON. My objection to this lantern is that the lights are not shown alone, but in pairs. The color-blind can distinguish between red, green, and white lights not by their color, but by their brightness. The brightest he would call white, the next green, the least bright, red. He might thus escape detection. When shown singly he has nothing to compare with the light, and will reveal his defect.

A gentleman at the club last night informed me that he was color-blind, and that he was never able, on the elevated road in New York, to select his train for his home from two — the Harlem and the 58th Street, each carrying a red or a green light — but was obliged to ask an employe. He thought he might if they were seen together. He was found by the lantern a congenital color-blind, with no other visual defect. Each test of the lantern was found efficient, and especially the delicate one of the three confusion colors, viz.: pink, green, and gray, which he called in turn white.

Dr. WILLIAMS. It is often an advantage to show two lights together, by comparison, not only a red and a green, but two reds or two greens of different intensities, and a person who is defec-

tive in color-perception and judges these colors by their intensities will be likely to call one of the two reds green and the other red, and so with the two greens, and this is a valuable test to make. On the other hand, one sometimes wishes to use one color alone, and by moving the diaphragm this lantern can be used in both ways. It is a good plan to have these tests as nearly resembling actual conditions as possible, and also to simulate the varying conditions met with in the service. I have often been in the cab of a locomotive at night coming into some large yard where there might be fifty or more lights, red, green, and white, among which it was necessary not only to distinguish the colors, but also to pick out the particular lights which governed our track, to see whether they were set for us to stop or to proceed. In order to know that the color-perception is sufficiently good to do this work satisfactorily it is necessary to examine the eyes not only with some form of colored worsted test, but also with the lantern test.

AN IMPROVED PERIMETER.

By FRANK D. SKEEL, M.D.,

New York City.

The perimeter which I have the honor to show you is the result of an effort to make the plotting of the visual field a more exact and less tedious operation, and to make it possible for the examiner to concentrate his attention upon the patient, rather than upon the graduated circles and chart.

The large arc is carried upon a horizontal axis. The revolution of this arc is, however, transmitted downward through a beveled gear to the record sheet which is fixed on a table attached to the base of the instrument.

The main feature of the perimeter is that it is self-recording. The translucent indices are illuminated by small electric lamps placed behind them, thus rendering the illumination constant at all times. The instrument, however, may be used in reflected light in the usual manner. The indices are five in number, and are arranged on a revolving disc, one only being visible at a time. They are of the following colors: blue, green, red, yellow,

and white. The stationary index or fixation point is, of course, white. The revolving disc bearing the indices described is borne upon an arc inclosed in the main arc of the instrument, within which it slides to and from the fixation point. It is actuated by a



milled head and rack and pinion, which is placed at the back of the instrument near its axis.

By this means the hand of the examiner when moving the index is hidden from the patient.

This sliding arc is wedge-shaped, and its movement is transmitted backward through the axis to a finger bearing pencils, which, in color, correspond to the colors of the indices; that is to say, when the field for red is being taken the pencil marks on the chart are red, etc. This finger automatically takes a position

above the chart, corresponding accurately to the position of the index in the patient's field of vision.

The record of this position is made by depressing a lever at the foot of the instrument which brings the chart upward into contact with the pencil.

A considerable difficulty was experienced in designing a suitable recording mechanism until the following plan was luckily hit upon. Various stylographic pens were tried, and discarded. A perforating mechanism followed them, accompanied by a self-inking rubber stamp. A lead pencil was found most reliable, but did not mark distinctly enough when it was simply pressed upon the paper. It was then given a slight lateral motion by fixing it to the finger already described by means of a short-jointed lever, which yields upwardly when the paper is pressed against the point of the pencil, causing the latter to move across the paper a distance of about one-eighth of an inch; this is found to be very satisfactory. A chin rest adjustable for height is attached to the front of the perimeter in the geometrical center of its arc. When the electric light is desired a four-cell dry battery furnishes sufficient power for the purpose.

Great care has been taken to have the indices of a correct color by reflected as well as by transmitted light. The indices are square in shape, and ten millimeters (10 mm.) in diameter; this diameter may be reduced to five millimeters (5 mm.) by a little shutter provided for the purpose.

The arc is broad, and is blackened, furnishing a fine background for the indices. To make the purpose of this instrument more clear, let me say that it is not necessary for the examiner to read any graduation, nor, in fact, to look at the chart during the examination.

I am fully aware that this description is complicated, but the instrument is in reality very simple, and so constructed that it is not liable to get out of order.

It is to be hoped that the elimination of error and saving of time accomplished by its use will justify its existence.

I take pleasure in acknowledging the intelligent skill of Mr. E. B. Meyrowitz in the construction of this instrument.

EDWARD L. HOLMES, M.D., LL.D.

EDWARD L. HOLMES, M.D., LL.D.

Dr. Edward Lorenzo Holmes, who for thirty-five years was a member of this Society, died of pneumonia in Chicago, February 12, 1900, at the age of 72 years. Dr. Holmes was born January 28, 1828, at Dedham, Mass., was graduated from Harvard College at the age of 21, and then taught in the Latin School of Roxbury, Mass. He graduated from the medical department of Harvard in 1854, after which he served as interne in the Massachusetts General Hospital, Boston. He spent one year at the University of Vienna, and then went to Chicago, where he entered into the practice of ophthalmology and otology. He at once became associated, in that city, with the pioneers of the medical profession and took an active interest in the advancement of its institutions and the promotion of its principles. To the movement begun by him in 1858 the Illinois Charitable Eye and Ear Infirmary owes its foundation. He was deeply interested in its welfare and until his resignation very recently was at the head of its medical and surgical staff. He aided actively in the foundation of the Presbyterian Hospital in 1883, and was for a considerable time one of the attending surgeons for the treatment of diseases of the eye and ear.

In 1860, Dr. Holmes became lecturer on Ophthalmology and Otology in Rush Medical College, and was elected to a full professorship in 1867. In 1890 he succeeded Dr. J. Adams Allen as President of the College, a position which he held until his 70th birthday, Jan. 28, 1898, when he resigned from the faculty.

He was also a trustee of Lake Forest University, director in the Central Free Dispensary, Chicago, and a member of a number of medical societies of Chicago and of this country.

He was almost the pioneer of ophthalmology in the west, and did much by his sound practice and teaching to promote its truths. While not a prolific writer, he was a thoughtful one,

whose influence was wider than that of many who write much. As a practitioner he was exceptionally proficient and skillful, and this together with his warm sympathy made him highly respected and greatly beloved, not only by his patients, but by all with whom he was associated.

A man of learning and culture, he was, withal, unostentatious and unaffected. A man of studious habits and quiet refinement, he was also an organizer and a man of affairs. His active work in the organization and management of the institutions with which he was connected, attests his humanitarianism and his love for his profession. The esteem in which he was held by his professional brethren, his associates, and his friends, bespeaks his noble character and his beautiful life.

W. H. W.

TRANSACTIONS

OF THE

AMERICAN

OPHTHALMOLOGICAL SOCIETY.

Thirty-seventh Annual Meeting.

NEW LONDON, CONN., 1901.

HARTFORD:
PUBLISHED BY THE SOCIETY.
1901.

2660

PRESS OF THE CASE, LOCKWOOD & BRAINARD COMPANY

TABLE OF CONTENTS.

PAGE.

Members of the society, ... 205

Minutes of the thirty-seventh annual meeting, ... 209

Report of committee on supplementary histories of cases recorded in the transactions of this society prior to 1900; Dr. Edward Jackson, chairman, ... 215

Contribution to the pathology of vascular growths into the vitreous; Dr. W. B. Marple, ... 254

Case of melanotic, giant-celled sarcoma of the limbus associated with an implanted secondary growth in the lower lid; Drs. Wadsworth and Verhoeff, ... 274

Histological description of an eyeball with dropsical degeneration of the rod and cone visual cells of the retina which clinically simulated glioma; Drs. de Schweinitz and Shumway, ... 283

Concerning the treatment of the apparently unaffected or, at most, but slightly involved eye in cases of monolateral glaucoma; Dr. de Schweinitz, ... 291

Metastatic choroiditis occurring in the course of pneumonia due to grippe, based on a study of six cases with two autopsies; Dr. Bull, ... 316

Case of adenoma of the meibomian glands, with a synopsis of what is known on that kind of tumor; Dr. Knapp, ... 328

Case of sarcoma of the choroid, followed by phthisis bulbi and twenty years later by perforation of the globe and rapid growth of the neoplasm; Dr. Kipp, ... 332

Double panophthalmitis and septicaemia from abscess of the knee; Dr. Jackson, ... 335

Primary tuberculosis of the iris; Dr. Hepburn, ... 338

A case of sclero-corneal cyst; Dr. Gruening, ... 339

Case of sarcoma of the iris; Dr. Gruening, ... 343

Large foreign body in anterior chamber removed, with preservation of perfect vision, with photograph of the foreign body in situ; Dr. St. John, ... 345

Case of foreign body lodged within the eyeball and removed eighteen years after the injury. Sympathetic inflammation three times without loss of vision; Dr. Hubbell, ... 347

Results of X-ray diagnosis and of operation in injuries from foreign bodies; Dr. Sweet, ... 352

Thrombosis of the cavernous sinus; Dr. Jackson, ... 365

PAGE.

Unusual case of chronic inflammatory hypertrophy of the lid margins; Dr. Cheney, ... 367
Anophthalmos congenitus; Dr. Claiborne, ... 370
Eye complications in a case of anchylostomiasis; Dr. Hansell, . . 377
Cyst of vitreous; Dr. Koller, ... 380
Dislocation of lachrymal gland; Dr. Mittendorf, ... 382
Hunterian chancre of caruncle; Dr. Hepburn, ... 383
A corneal loupe; Dr. Koller, ... 385
Incandescent electric lamp for ophthalmoscopic examination; Dr. Williams, ... 387
New instrument for testing the position of the axes of the eyes; Dr. Williams, ... 388
Improved lantern for detecting color-blindness; Drs. Wm. and A. G. Thomson, ... 391
Two new instruments; Dr. Theobald, ... 398
Congenital coloboma of eyelid; Dr. Lambert, ... 402
Hypertrophy of lachrymal gland; Dr. Lambert, ... 403
Papilloma of orbital conjunctiva and cornea; Dr. Lambert, . . 404
Report of committee on standards and methods for examination for acuteness of vision, color sense and hearing; Dr. Williams, chairman, ... 406

MEMBERS

OF THE

American Ophthalmological Society.

1901-1902.

ACTIVE MEMBERS.

The (*) indicates *Associate* Members.

NAME.	RESIDENCE.	PLACE.
Dr. A. E. ADAMS,	44 Grand Street,	Newburg, N. Y.
Dr. L. A. W. ALLEMAN,	64 Montague Street,	Brooklyn, N. Y.
*Dr. A. ALLING,	199 York Street,	New Haven, Conn.
*Dr. G. W. ALLYN,	515 Penn Avenue,	Pittsburg, Pa.
Dr. A. ALT,	3036 Locust Street,	St. Louis, Mo.
†Dr. J. A. ANDREWS,	107 Madison Avenue,	New York, N. Y.
Dr. S. C. AYRES,	14th East 7th Street,	Cincinnati, Ohio.
Dr. WM. T. BACON,	75 Pratt Street,	Hartford, Conn.
Dr. H. W. BRADFORD,		Jamaica Plain, Mass.
*Dr. H. D. BRUNS,	Gas Co. Building,	New Orleans, La.
Dr. CHARLES S. BULL,	47 West 36th Street,	New York, N. Y.
Dr. F. BULLER,	123 Stanley Street,	Montreal, Canada.
Dr. SWAN M. BURNETT,	916 Farragut Sq. (17th St.),	Washington, D. C.
Dr. PETER A. CALLAN,	35 West 38th Street,	New York, N. Y.
Dr. F. P. CAPRON,	118 Angell Street,	Providence, R. I.
Dr. W. H. CARMALT,	87 Elm Street,	New Haven, Conn.
*Dr. JOHN T. CARPENTER, JR.,	1419 Walnut Street,	Philadelphia, Pa.
Dr. H. B. CHANDLER,	34½ Beacon Street,	Boston, Mass.
Dr. WM. CHEATHAM,	303 West Chestnut Street,	Louisville, Ky.
Dr. F. E. CHENEY,	Hotel Bristol,	Boston, Mass.
Dr. J. H. CLAIBORNE,	39 West 36th Street,	New York City.
Dr. C. F. CLARK,	188 East State Street,	Columbus, Ohio.
*Dr. ANTON COE,	1110 F Street,	Washington, D. C.
Dr. DAVID COGGIN,	7 Chestnut Street,	Salem, Mass.
*Dr. WM. E. COWEN,	35 E. 60th Street,	New York, N. Y.
Dr. C. M. CULVER,	36 Eagle Street,	Albany, N. Y.
Dr. W. S. DENNETT,	8 East 49th Street,	New York, N. Y.
Dr. HASKET DERBY,	182 Marlboro Street,	Boston, Mass.
Dr. RICHARD H. DERBY,	9 West 35th Street,	New York, N. Y.
Dr. LEWIS S. DIXON,	232 Clarendon Street,	Boston, Mass.
Dr. J. B. EMERSON,	20 East 30th Street,	New York, N. Y.
Dr. ARTHUR E. EWING,	2670 Washington Avenue,	St. Louis, Mo.

† Temporarily residing at Santa Barbara, Cal.

NAME.	RESIDENCE.	PLACE.
Dr. T. H. FENTON,	1319 Spruce Street,	Philadelphia, Pa.
Dr. GEORGE F. FISKE,	100 State Street,	Chicago, Ill.
Dr. EDW. FRIDENBERG,	242 Lenox Avenue,	New York, N. Y.
Dr. H. FRIEDENWALD,	1029 Madison Ave.,	Baltimore, Md.
Dr. B. F. FRYER,	Cor. 9th and Cherry Streets,	Kansas City, Mo.
*Dr. G. M. GOULD,	119 South 17th Street,	Philadelphia, Pa.
*Dr. H. Y. GRANT,	414 Delaware Avenue,	Buffalo, N. Y.
Dr. JOHN GREEN,	2670 Washington Avenue.	St. Louis, Mo.
Dr. EMIL GRUENING,	109 East 23d Street,	New York, N. Y.
Dr. G. W. HALE,	Wilcox Building,	Nashville, Tenn.
*Dr. WM. D. HALL,	10 Arlington Street,	Boston, Mass.
Dr. H. F. HANSELL,	254 South 16th Street,	Philadelphia, Pa.
Dr. GEORGE C. HARLAN,	1515 Walnut Street,	Philadelphia, Pa.
*Dr. HERBERT HARLAN,	516 Cathedral Street,	Baltimore, Md.
Dr. DAVID HARROWER,	9 Elm Street,	Worcester, Mass.
Dr. N. D. HARVEY,	262 Benefit Street,	Providence, R. I.
Dr. GUSTAVUS HAY,	383 Marlborough Street,	Boston, Mass.
Dr. NEIL J. HEPBURN,	317 West 23d Street,	New York, N. Y.
*Dr. WARD HOLDEN,	60 West 39th Street,	New York, N. Y.
Dr. E. E. HOLT,	723 Congress Street,	Portland, Me.
Dr. LUCIEN HOWE,	87 West Huron Street,	Buffalo, N. Y.
Dr. A. A. HUBBELL,	212 Franklin Street,	Buffalo, N. Y.
Dr. D. W. HUNTER,	80 West 40th Street,	New York, N. Y.
*Dr. J. W. INGALLS,	848 Lafayette Avenue,	Brooklyn, N. Y.
*Dr. E. E. JACK,	215 Beacon Street,	Boston, Mass.
Dr. EDWARD JACKSON,	McPhee Building,	Denver, Col.
Dr. B. JOY JEFFRIES,	15 Chestnut St., Beacon Hill,	Boston, Mass.
Dr. W. B. JOHNSON,	170 Broadway,	Paterson, N. J.
*Dr. W. H. KILBURN,	192 Marlborough Street,	Boston, Mass.
Dr. CHARLES J. KIPP,	560 Broad Street,	Newark, N. J.
Dr. H. KNAPP,	26 West 40th Street,	New York, N. Y.
Dr. CARL KOLLER,	715 Madison Avenue,	New York, N. Y.
Dr. CHAS. W. KOLLOCK,	Cor. Wentworth & Com'g Sts.,	Charleston, S. C.
Dr. W. E. LAMBERT,	8 West 35th Street,	New York, N. Y.
*Dr. F. N. LEWIS,	35 W. 36th Street,	New York City.
Dr. J. A. LIPPINCOTT,	435 Penn Avenue,	Pittsburg, Pa.
Dr. F. B. LORING,	1420 K Street,	Washington, D. C.
*Dr. D. B. LOVELL,	32 Pearl Street,	Worcester, Mass.
Dr. F. W. MARLOW,	731 University Block,	Syracuse, N. Y.
Dr. W. V. MARMION,	1110 8th Street, N. W.,	Washington, D. C.
Dr. W. B. MARPLE,	35 W. 53d Street,	New York, N. Y.
Dr. ARTHUR MATHEWSON,	139 Montague Street,	Brooklyn, N. Y.
Dr. CHAS. H. MCILWAINE,	264 Willis Avenue,	New York, N. Y.
Dr. R. J. MCKAY,	Cor. 9th and Market Streets,	Wilmington, Del.
Dr. C. S. MERRILL,	23 Washington Avenue,	Albany, N. Y.
Dr. B. L. MILLIKIN,	278 Prospect Street,	Cleveland, Ohio.
Dr. HORACE GEO. MILLER,	262 Benefit Street,	Providence, R. I.

NAME.	RESIDENCE.	PLACE.
Dr. J. LANCELOT MINOR,	14 Randolph Building,	Memphis, Tenn.
Dr. W. F. MITTENDORF,	140 Madison Avenue,	New York, N. Y.
Dr. WM. O. MOORE,	42 East 29th Street,	New York, N. Y.
Dr. RUSSELL MURDOCH,	418 Cathedral Street,	Baltimore, Md.
Dr. WM. F. NORRIS,	1530 Locust Street,	Philadelphia, Pa.
Dr. CHARLES A. OLIVER,	1507 Locust Street,	Philadelphia, Pa.
Dr. H. S. OPPENHEIMER,	16 E. 32d Street,	New York, N. Y.
Dr. R. J. PHILLIPS,	123 So. 39th Street,	Philadelphia, Pa.
Dr. THOMAS R. POOLEY,	107 Madison Avenue,	New York, N. Y.
*Dr. WILLIAM C. POSEY,	1831 Chestnut Street,	Philadelphia, Pa.
Dr. M. H. POST,	Beaum't St., cor. Wash. Av.,	St. Louis, Mo.
*Dr. L. A. PREFONTAINE,	1317 Main Street,	Springfield, Mass.
Dr. H. R. PRICE,	163 Hancock Street,	Brooklyn, N. Y.
Dr. J. S. PROUT,	29 Schermerhorn Street,	Brooklyn, N. Y.
*Dr. ALEX. QUACKENBOS,	373 Boylston Street,	Boston, Mass.
Dr. ALEX'R RANDALL,	1717 Locust Street,	Philadelphia, Pa.
Dr. R. L. RANDOLPH,	816 Park Avenue,	Baltimore, Md.
Dr. WILLIAM RANKIN,	23 Cedar Street,	Newark, N. J.
Dr. J. M. RAY,	423 West Chestnut Street,	Louisville, Ky.
*Dr. R. G. REESE,	56 East 25th Street,	New York, N. Y.
Dr. R. A. REEVE,	22 Shuter Street,	Toronto, Canada.
*Dr. O. H. REIK,	5 W. Preston Street,	Baltimore, Md.
Dr. STEPHEN O. RICHEY,	732 17th Street,	Washington, D. C.
Dr. CHARLES E. RIDER,	53 South Fitzhugh Street,	Rochester, N. Y.
Dr. WHEELOCK RIDER,	53 South Fitzhugh Street,	Rochester, N. Y.
*Dr. G. O. RING,	1900 Chestnut Street,	Philadelphia, Pa.
Dr. H. W. RING,	46 Elm Street,	New Haven, Conn.
Dr. SAMUEL D. RISLEY,	1824 Chestnut Street,	Philadelphia, Pa.
Dr. EDMUND C. RIVERS,	16th and Stout Streets,	Denver City, Col.
*Dr. WM. K. ROGERS,	188 East State Street,	Columbus, Ohio.
Dr. D. B. ST. JOHN ROOSA,	20 East 30th Street,	New York, N. Y.
*Dr. DUNBAR ROY,	Grand Opera House Block,	Atlanta, Ga.
Dr. JOHN D. RUSHMORE,	129 Montague Street,	Brooklyn, N. Y.
Dr. ROBERT SATTLER,	7th and Race Streets,	Cincinnati, Ohio.
Dr. T. B. SCHNEIDEMAN,	112 South 18th Street	Philadelphia, Pa.
Dr. G. E. DE SCHWEINITZ,	1401 Locust Street,	Philadelphia, Pa.
Dr. P. N. K. SCHWENK,	810 North 7th Street,	Philadelphia, Pa.
Dr. W. W. SEELEY,	4th Street and Broadway,	Cincinnati, Ohio.
Dr. HENRY L. SHAW,	19 Commonwealth Avenue,	Boston, Mass.
*Dr. F. D. SKEEL,	58 E. 25th Street,	New York, N. Y.
Dr. J. A. SPALDING,	627 Congress Street,	Portland, Me.
Dr. MYLES STANDISH,	6 St. James Avenue,	Boston, Mass.
*Dr. E. W. STEVENS,	421 McPhee Building,	Denver, Col.
Dr. GEORGE T. STEVENS,	33 West 33d Street,	New York, N. Y.
Dr. SAMUEL B. ST. JOHN,	68 Pratt Street,	Hartford, Conn.
Dr. GEO. STRAWBRIDGE,	202 So. 15th Street,	Philadelphia, Pa.
Dr. T. Y. SUTPHEN,	999 Broad Street,	Newark, N. J.

NAME.	RESIDENCE.	PLACE.
*Dr. WM. M. SWEET,	1205 Spruce Street,	Philadelphia, Pa.
Dr. J. OSCROFT TANSLEY,	28 West 43d Street,	New York, N. Y.
Dr. LEWIS H. TAYLOR,	41 South Franklin Street,	Wilkes-Barre, Pa.
Dr. SAMUEL THEOBALD,	304 West Monument Street,	Baltimore, Md.
Dr. CH. HERMON THOMAS,	1907 Chestnut Street,	Philadelphia, Pa.
*Dr. A. G. THOMSON,	1426 Walnut Street,	Philadelphia, Pa.
Dr. WILLIAM THOMSON,	1426 Walnut Street,	Philadelphia, Pa.
*Dr. JAS. THORINGTON,	120 South 18th Street,	Philadelphia, Pa.
Dr. JOHN VAN DUYN,	111 South Salina Street,	Syracuse, N. Y.
*Dr. C. A. VEASEY,	116 South 19th Street,	Philadelphia, Pa.
Dr. O. F. WADSWORTH,	526 Beacon Street,	Boston, Mass.
Dr. LEROY P. WALKER,	25 East 24th Street,	New York, N. Y.
Dr. DAVID WEBSTER,	327 Madison Avenue,	New York, N. Y.
Dr. J. E. WEEKS,	154 Madison Avenue,	New York, N. Y.
*Dr. CASSIUS D. WESTCOTT,	31 Washington Street,	Chicago, Ill.
Dr. J. A. WHITE,	200 E. Franklin Street,	Richmond, Va.
Dr. W. H. WILDER,	103 State Street,	Chicago, Ill.
Dr. CHAS. H. WILLIAMS,	1069 Boylston Street,	Boston, Mass.
Dr. WM. H. WILMER,	1610 I Street N. W.,	Washington, D. C.
Dr. F. M. WILSON,	288 Myrtle Avenue,	Bridgeport, Conn.
*Dr. WILLIAM L. WOOD,	412 Oregonian Building,	Portland, Oregon.
*Dr. HIRAM WOODS,	842 Park Ave.,	Baltimore, Md.
Dr. J. P. WORRELL,	20 South 7th Street,	Terre Haute, Ind.
Total, ...		149

HONORARY MEMBERS.

Dr. C. SCHWEIGGER, ...		Berlin, Prussia.
Dr. F. P. SPRAGUE,	229 Commonwealth Avenue,	Boston, Mass.
Whole number, ...		151

MINUTES OF THE PROCEEDINGS.

THIRTY-SEVENTH ANNUAL MEETING.

PEQUOT HOUSE,
NEW LONDON, July 17, 1901.

The Thirty-seventh annual meeting of the Society was called to order by the President, Dr. O. F. WADSWORTH, at 10 A. M. The President announced the following committees:

Committee on Bulletin — Drs. C. H. WILLIAMS and MYLES STANDISH.

Committee on Membership — Drs. JOHN GREEN, GEO. C. HARLAN, W. H. CARMALT, C. S. BULL, and E. GRUENING.

Auditing Committee — Dr. P. A. CALLAN.

The Committee on Bulletin reported and the following papers were read:

1. Report of committee on supplementary reports of cases which have been previously reported to the Society, by Dr. Edward Jackson, Chairman.

This report was not read in full, but ordered published in the Transactions. The committee recommended that a similar report be made every ten years, and it was so ordered by vote of the Society.

2. An improved lantern for detecting color-blindness to supplement the wool tests, Drs. Wm. Thomson and A. G. Thomson.

3. Report of Committee on Standards and Methods for Examination for acuteness of vision, color-sense, and hearing, by Dr. C. H. Williams, Chairman.

Discussed by Drs. Carmalt, Theobald, Williams, Green, and Kipp.

Voted, That the report of the committee be accepted and the recommendations embodied therein be adopted, leaving out paragraph nine.

Drs. J. P. Davidson of Richmond, Va., and F. L. Waite of Hartford, Conn., were invited to attend the sessions as guests of the Society.

4. Contribution to the pathology of vascular growths into the vitreous, with demonstration of a specimen, Dr. W. B. Marple.

Discussed by Drs. de Schweinitz, Mittendorf, Risley, Wadsworth, A. G. Thomson, and Marple.

5. Case of melanotic giant-celled sarcoma of the limbus associated with an implanted secondary growth in the lower lid, Drs. Wadsworth and Verhoeff.

Discussed by Drs. Holt, de Schweinitz, and Risley.

6. Case of sarcoma of the choroid followed by phthisis bulbi and twenty years later by perforation of the anterior part of the globe and rapid growth of the neoplasm, Dr. Kipp.

7. Double panophthalmitis of septic origin, Dr. Jackson.

8. Case of primary tuberculosis of the iris (with microscopic specimen), Dr. Hepburn.

9. Corneal cyst (with specimen), Dr. Gruening.

10. Sarcoma of iris (specimen), Dr. Gruening.

Discussed by Dr. Kipp.

11. Histological description of an eyeball with dropsical degeneration of the rod and cone visual cells of the retina, which clinically simulated glaucoma, Drs. de Schweinitz and Shumway.

12. Extraction of a large foreign body from the anterior chamber with complete preservation of vision (with photograph of the foreign body *in situ*), Dr. St. John.

13. Case of foreign body in the eye eighteen years; three attacks of uveal inflammation of the other eye without loss of vision, Dr. Hubbell.

Discussed by Dr. Kipp.

14. Results of X-ray diagnosis and of operation in injury from foreign bodies, Dr. Sweet.

Discussed by Drs. Standish, Holt, and Sweet.

Adjourned to 3 P. M.

Called to order at 3 P. M.

15. Concerning the treatment of the apparently unaffected eye in monocular glaucoma, Dr. de Schweinitz.

Discussed by Drs. Bull, Risley, Gruening, Harlan, Theobald, Kipp, Callan, Pooley, Standish, Williams, Jackson, Koller, Randall, Wadsworth, and de Schweinitz.

16. A new instrument for determining the position of the axes of the eyes, Dr. Williams.

17. An unusual case of chronic inflammatory hypertrophy of the lid-margin, Dr. Cheney.

18. Thrombosis of cavernous sinus, Dr. Jackson.

19. Anophthalmos congenitus, Dr. Claiborne (by title).

20. A note concerning the ocular conditions in anchylostoma duodenalis, Dr. Hansell.

21. Corneal Loupe with oblique illumination, Dr. Koller.

22. A new incandescent electric lamp for ophthalmoscopic examinations, Dr. Williams.

23. Two new instruments, Dr. Theobald.

24. Cyst of vitreous, Dr. Koller.

Discussed by Dr. Risley.

25. Adenoma of meibomian glands (with colored drawings of the clinical picture and microscopic demonstration of the original tumor and its development into adeno-sarcoma and adeno-carcinoma), Dr. Knapp.

Discussed by Dr. Wadsworth.

Society then went into executive session.

Several names of proposed new members were read by the Secretary and referred to the Committee on Membership for next year.

Treasurer's report, reported correct by Auditing Committee, was accepted and ordered on file.

Dr. Carmalt moved that a committee of one be appointed by the President to prepare for the Society a memorial of our

late colleague, Dr. Henry D. Noyes, and that a request be made of his family for a portrait, of which a copy shall be prepared for publication in the Transactions, and that a minute expressing our appreciation of his services to the Society, and our sense of personal loss in his death, be communicated to them. This memorial shall contain a list of his professional publications.

Motion carried, and Dr. C. S. Bull appointed.

A letter from Dr. F. P. Sprague, resigning membership in the Society, was read by the Secretary.

Voted, Not to accept the resignation, but to transfer Dr. Sprague to the list of honorary members.

The deaths of Dr. F. W. Abbot of Buffalo and of Dr. Wm. F. Aiken of Savannah were reported.

Dr. Williams moved that the Committee on Standards and Methods of Examination for acuteness of vision, color-sense, and hearing be continued with the addition of Dr. Jno. Green, and that they be instructed to prepare a set of standard test type and communicate the same to the Society.

Motion carried.

The Committee on Membership reported favorably on the following names of candidates, which were placed on the list of associate members, as no demand for a ballot was made:

Dr. H. D. Bruns of New Orleans, La.; Dr. Herbert Harlan of Baltimore, Md.; Dr. G. Oram Ring, Philadelphia, Pa.; Dr. E. W. Stevens, Denver, Col.; Dr. H. W. Kilburn, Boston, Mass.; Dr. Alex. Quackenbos of Boston, Mass.; Dr. L. A. Prefontaine of Springfield, Mass.; Dr. R. G. Reese of New York city.

Dr. Kipp moved that it is the sense of the Society that the President should hold office for one year only.

Motion lost.

The Executive Committee reported the following list of officers for the ensuing year, and by a vote of the Society the Secretary was instructed to cast the ballot of the Society and they were duly elected:

President — Dr. O. F. Wadsworth.

Vice-President — Dr. C. S. Bull.

Corresponding Secretary — Dr. J. S. PROUT.

Recording Secretary and Treasurer — Dr. S. B. ST. JOHN.

Publication Committee — Drs. W. S. DENNETT, R. H. DERBY, and the Secretary (*ex officio*).

Delegate to the Congress of Physicians and Surgeons — Dr. J. D. RUSHMORE.

Alternate — Dr. C. S. BULL.

Voted, That the assessment for next year be $5.

Place of meeting for 1902, New London, provisionally subject to change if thought best by a committee consisting of Dr. S. B. St. John, H. G. Miller, and W. H. Carmalt.

Dr. Carmalt moved that the limit of membership be raised to 175.

Dr. Knapp moved to amend by making membership unlimited.

The amendment was withdrawn and the motion passed.

Adjourned to July 18th, 10 A. M.

July 18th.

Meeting called to order at 10 A. M., and reading of papers resumed.

26. A study of six cases of metastatic choroiditis occurring in the course of pneumonia due to "grippe," Dr. Bull.

Discussed by Drs. Knapp, Mittendorf, Wadsworth, Bull, Koller, and Gruening.

27. Dislocation of the lachrymal gland, Dr. Mittendorf.

28. Case of Hunterian chancre of the caruncle, Dr. Hepburn.

Discussed by Drs. Pooley, Ring, Harrower, and Hepburn.

29. Demonstration of photographs of a case of congenital coloboma of the upper lid; a case of tumor of both lids supposed at first to be angioma, but found to be hypertrophy of the lachrymal gland, and a case of papilloma of the sclero-corneal margin, Dr. W. E. Lambert.

Discussed by Drs. Gruening and Koller.

Adjourned.

S. B. ST. JOHN, *Secretary.*

Present at the Thirty-seventh Annual Meeting:

Dr. S. B. St. John,
Dr. G. W. Allyn,
Dr. T. B. Schneideman,
Dr. H. F. Hansell,
Dr. W. Cheatham,
Dr. J. B. Emerson,
Dr. G. C. Harlan,
Dr. D. Harrower,
Dr. G. W. Hale,
Dr. W. F. Mittendorf,
Dr. N. J. Hepburn,
Dr. G. E. de Schweinitz,
Dr. J. H. Claiborne,
Dr. J. D. Rushmore,
Dr. H. G. Miller,
Dr. Jno. Green,
Dr. H. O. Reik,
Dr. F. N. Lewis,
Dr. S. Theobald,
Dr. W. B. Marple,
Dr. H. R. Price,
Dr. R. A. Reeve,
Dr. W. K. Rogers,
Dr. W. E. Lambert,
Dr. W. O. Moore,
Dr. J. W. Ingalls,
Dr. W. D. Hall,
Dr. Myles Standish,
Dr. C. S. Bull,
Dr. H. Knapp,
Dr. Charles H. Williams,
Dr. C. J. Kipp,
Dr. C. M. Culver,
Dr. W. M. Sweet,
Dr. S. D. Risley,
Dr. Wheelock Rider,
Dr. J. O. Tansley,
Dr. Geo. F. Fiske,
Dr. A. Mathewson,
Dr. T. R. Pooley,
Dr. E. E. Holt,
Dr. P. N. K. Schwenk,
Dr. F. M. Wilson,
Dr. A. A. Alling,
Dr. A. A. Hubbell,
Dr. B. A. Randall,
Dr. O. F. Wadsworth,
Dr. Edw. Jackson,
Dr. E. Gruening,
Dr. W. H. Carmalt,
Dr. T. H. Fenton,
Dr. P. A. Callan,
Dr. C. Koller,
Dr. D. Coggin,
Dr. H. W. Ring,
Dr. D. B. Lovell,
Dr. D. W. Hunter,
Dr. F. S. Cheney,
Dr. A. G. Thomson,
Dr. C. H. McIlwaine.

REPORT OF THE COMMITTEE ON THE SUPPLEMENTARY HISTORIES OF CASES RECORDED IN THE TRANSACTIONS OF THE SOCIETY PRIOR TO 1900.

In pursuance of the purpose for which it was appointed, your committee prepared the accompanying circular letter and sent a copy of it to each member of the society who had placed one or more cases on record in our transactions previous to the meeting of 1900. Subsequently a second copy was sent to each member who had not already responded. Responses have been received from forty-nine members, and sixteen members have so far failed to furnish the supplementary reports desired. It is recommended that members who have thus far failed to furnish the material desired be requested to do so before September 1st, and that such material be incorporated in the report for publication.

An examination of the supplementary reports received shows that the great mass of them refer to cases that have been published within the last ten years, and that rarely have the cases reported earlier been followed more than ten years after the date of the original report. We therefore suggest that hereafter a report of this kind be prepared and incorporated in our transactions at the close of each decennial period.

In arranging the present report we have sought as far as possible to group similar cases together, and to include therewith references to all cases of the kind reported in our transactions during the period covered. Where nothing more than the reference to the previous report is given it will be understood either that the original report was entirely complete or that no supplementary report could be obtained.

Where the grouping of conditions differs from what is commonly seen in treatises on ophthalmology, the departure has been

made for the purpose of bringing together conditions that in this aspect seemed closely connected.

EDWARD JACKSON,
GEORGE E. DE SCHWEINITZ,
CHARLES H. WILLIAMS.

LETTER SOLICITING SUPPLEMENTARY REPORTS.

315 McPhee Building,
DENVER, COL., March 30, 1901.

DEAR DOCTOR: — At the last meeting of the American Ophthalmological Society the undersigned were appointed a committee to collect and arrange for publication in the transactions the subsequent histories of cases that have been reported to previous meetings of the society.

It is desired that these reports should be brief, but that they should cover all subsequent developments bearing upon important features of the case to the present time, or until the patient's death.

They should especially state the subsequent vision, progress, arrest, or recurrence of the condition reported; permanence of operative results, and subsequent health of patient, and cause of death.

If a complete report is impossible, please send us such data as you can command. If you have reason to believe that some other member of the society can supply further information about a certain case please address him and let us have his name. If a case has been subsequently reported elsewhere we wish a reference to that report, and also the brief history above requested. If you know the subsequent histories of cases reported by other members of the society, especially of cases reported by members since deceased, please let us have an account of them.

The supplementary histories here contemplated will add greatly to the value of the original papers already in our transactions. As time will be required to secure special reports, and

for the arrangement of the material obtained, you are requested to give the matter the earliest possible attention. Below you will find the list of cases you have reported in our transactions, regarding each of which we wish such data as you can furnish.

Replies should be sent to the chairman of the committee at the above address.

Respectfully yours,

EDWARD JACKSON, Chairman,
GEO. E. DE SCHWEINITZ,
CHAS. H. WILLIAMS.

ANOMALIES.

For obvious reasons certain congenital conditions are grouped under other heads.

Congenital Entropion. Of the case recorded in 1894, on page 225, J. A. Lippincott reports that when last seen, November 1, 1895, the child was robust. No opacity of the cornea remained in either eye, and the eyelids were quite normal in appearance and action. Additional cases, 1895, pages 418 and 422.

Coloboma of the Lid. 1871, p. 142; 1880, p. 86.

Ectropion Uveæ. Of the case reported in 1894, p. 218, Lucien Howe reports: This patient has been examined at intervals during 1898 and 1899, the condition remaining practically the same as at first described. There was, meanwhile a slight increase in the myopia.

Persistent Pupillary Membrane. 1880, p. 110; 1896, p. 580.

Polycoria. 1884, p. 735.

Coloboma of the Iris. In the case recorded, 1891, p. 59, in which there was polycoria and primary glaucoma, G. E. de Schweinitz makes a supplementary report (see Glaucoma). Coloboma of iris, choroid, and lens. 1887, p. 564. Coloboma of Iris in mother, Congenital Irideræmia in child. 1888, p. 99.

Congenital Dislocation of the Lens. One case is recorded at successive periods. 1881, p. 225, 1891, p. 207, and 1893, p. 541. Other cases, 1883, p. 521. *Coloboma of the Lens,* with Retained Accommodative Power. 1894, p. 199.

Persistent Hyaloid Artery and Similar Remains. 1881, p. 211; 1882, p. 344 and p. 372; 1887, p. 491; 1888, p. 116; 1892, p. 412; 1899, p. 507; 1898, p. 606.

Coloboma of Optic Nerve and Sheath. Cases are recorded, 1887, p. 558.

REFRACTION.

Progressive Myopia, or Hypcropia changing to Myopia. Regarding the cases recorded in 1874, on page 139, Hasket Derby says of the atropine treatment of myopia: "My subsequent experience with this method has convinced me that its advantages are purely temporary, and with me, as with others, it has been superseded by full and permanent neutralization of the refractive error."

Of the cases recorded in 1892, p. 359, Edward Jackson reports the following are known to have continued without material change of refraction: Case VIII, two years; Case IX, two years, until the patient's death; Case XI, two years, until the patient's death; Case XII, five years; Case XIV, three years; Case XVIII, one year subsequent to the publication of the case; Case XXIV, three years.

In Case X, the refraction five years later showed diminution of astigmatism in the right eye, and no change in the left. The correction required was R. — 0.75 sph. ◯ — 2.25 cyl. ax. 180.

Case XXI at the end of six years required right — 0.50 ◯ — 1.25 cyl. ax. 100. L. — 0.62 spher. A slight diminution in the myopia of one meridian in the right eye, and in both meridians of the left.

In Case XXIII the correction one year after report was

R. — 4.25 ◯ — 1.00 cyl. ax. 96°,

L. — 4.25 spher.,

an increase of myopia of about 1D.

Case XXVII two years later required

R. — 7.75 ◯ — 0.75 cyl. ax. 55°,

L. — 6.75 ◯ — 0.75 cyl. ax. 105°,

an increase of myopia of 1.25 and 1.75 D. respectively. Four years later there had been no further change. This patient is a brother of Case XXIII.

In Case XIII at the end of six years the required correction was

R. — 4.00 ◯ — 1.25 cyl. ax. 97°,
L. — 3.25 ◯ — 0.75 cyl. ax. 85°.

In no case has there been any deterioration of vision.

The other cases of this series have not been seen since the original report, although some are known to retain good vision with the same lenses.

Of the case of progressive myopia checked by tenotomy of the external rectus, recorded 1885, p. 24, G. C. Harlan reports: "On April 20, 1898, vision equaled 20/20 with minus 4D (the former correction), and no change in ophthalmoscopic appearances."

Other cases of acquired or progressive myopia are recorded, 1885, p. 102; 1887, p. 520. Of these, S. D. Risley reports: Some of the reported cases exhibited steadily increasing refraction. For other cases see 1889, p. 306; 1890, p. 657; 1892, p. 373; 1894, p. 168.

Acquired and Changing Astigmatism. In the case of changes of refraction resulting from a blow, recorded in 1883, p. 579, W. H. Carmalt reports that "April 29, 1901, the patient's refraction measured by Dr. C. W. Cutler of New York gave

R. + 0.50 ◯ — 3.00 cyl. ax. 180° gave vision 20/20,
L. — 6.00 ◯ — 1.75 cyl. ax. 45° gave vision 20/15."

Regarding cases of progressive hyperopic astigmatism. Of the one recorded, 1888, p. 60, J. B. Emerson reports that "April 29, 1901,

R. + 6.00 cyl. ax. 165° ◯ — 1.00 cyl. ax. 75° gives 20/50,
L. + 1.00 ◯ + 0.75 cyl. ax. 15° gives 20/30,

the Javal Ophthalmometer showing right 7D. regular with irregular astigmatism; left, 1.25D. of astigmatism."

Of the cases of progressive hyperopic astigmatism recorded, 1890, p. 676, Edward Jackson reports:

Case I now requires

R. + 0.50 ◯ + 1.75 cyl. ax. 97°,

L. + 0.62 ◯ + 1.75 cyl. ax. 90°,

a farther increase of astigmatism of 0.50D. in one eye and 0.25D. in the other.

Case II required in November, 1896,

R. + 2.75 ◯ + 1.50 cyl. ax. 15°,

L. + 2.50 ◯ + 2.50 cyl. ax. 167°,

an increase of 0.50 cyl. and + 0.25 ◯ + 1. cyl. respectively.

Case VIII required in October, 1896,

R. + 0.50 ◯ + 2.25 cyl. ax. 95°,

L. + 0.50 ◯ + 2.25 cyl. ax. 88°,

a farther increase of over 1D. of astigmatism in each eye.

Case IX required May, 1895,

R. + 1.50 ◯ + 1.25 cyl. ax. 180°,

L. + 2.00 spher.,

a diminution of 0.50D. in the astigmatism of each eye.

Case XIII required in October, 1892,

R. + 1.50 ◯ + 1.50 cyl. ax. 5°,

L. + 2.25 spher.,

an increase of 0.50D. in the astigmatism of one eye.

Case XVIII required in September, 1894,

R. + 3.25 ◯ + 0.75 cyl. ax. 75°,

L. + 3.25 ◯ + 0.62 cyl. ax. 105°.

In Case VI there has been no material change of refraction since 1890 and the glasses are still worn. In none of the above cases has there been any deterioration or any improvement in vision.

In Case VII the lenses required in 1894 were

R. + 1.00 ◯ + 1.75 cyl. ax. 13°,

L. + 1.50 ◯ + 1.25 cyl. ax. 167°,

giving vision of 4/4 mostly, quite as good as she had ever obtained in either eye, although her hyperopia had diminished by one-half in both eyes. In September, 1896, she returned with vision diminished to 4/15 in the right eye and a greatly narrowed field. The eye was the seat of subacute glaucoma. Tension,

+T1. Iridectomy was done and the tension permanently lowered. In May, 1898, she required

R. + 3.00 cyl. ax. 20°. Vision, 4/20.

L. + 1.75 ◯ + 1.50 cyl. ax. 165°. Vision, 4/4.

This patient is a sister of Case II, who, however, has not suffered from glaucoma. The other cases in the above series have not been observed since the date of the original report.

Other cases of progressive astigmatism are recorded, 1885, p. 29. Astigmatism produced by tenotomy is recorded, 1874, p. 128; Acquired Astigmatism, 1867, p. 36; High Astigmatism, 1893, p. 580.

Astigmatism statistics, 1868, p. 134; 1880, p. 167; 1892, p. 308 and 315; 1894, p. 153. Statistics with the ophthalmometer, 1888, p. 48; 1892, p. 316; 1894, p. 177.

More general changes of the refraction of the eye are recorded, 1879, p. 530; 1883, p. 456; 1884, p. 751; 1886, p. 369; 1889, p. 435; 1897, p. 115.

Changes of Refraction in Diabetes. 1897, p. 121, S. D. Risley reports: This patient died during the autumn of 1900, having suffered several changes in refraction similar to those reported.

Myopia from Iritis and symptomatic of other conditions. 1887, p. 599; 1888, p. 70.

Corrections for Conical Cornea. 1874, p. 132. Hyperbolic lenses. 1884, p. 707.

Removal of the Lens for High Myopia. Regarding the first case recorded, 1898, p. 303, W. H. Wilmer, reports: "In June, 1900, there was no increase in myopia in this (right) eye, and V. with correction was 20/30. This patient's left eye was operated upon in June, 1898, but this operation has never been reported. The refraction of the left eye before the operation was 3/200 with — 18.0 ◯ — 2.50 cyl. ax. 180° = 20/50ths. The final vision of this eye in June, 1900, was 20/70+ and with — 1.25 ◯ — 1.75 cyl. ax. 120° = 20/30. The patient is very happy, and has comfortable binocular vision at all distances.

The other case reported — Mrs. C. — was last seen on November 28, 1898: R. E. V. = 20/100, with + 2.50 cyl. ax. 135°

= 20/50+. A very thin bit of opaque capsule was found, and discission advised. The patient was so comfortable, however, that the advice was not followed out. I have heard, through his friends, that the patient does a great deal of manual work without any glasses at all, and is very comfortable.

Another case of removal of the lens for myopia is recorded, 1898, p. 330; and a case of extreme myopia, 1874, p. 155.

Miscellaneous. Absolute Hyperopia with full vision, 1880, p. 103. The insufficiency of the ophthalmoscope alone in measuring hyperopia, 1880, p. 112; 1894, p. 142. Is there a hyperopia acquisita? 1899, p. 583.

Cases illustrating the value of the different mydriatics are given. 1881, p. 288; 1884, p. 707; 1889, p. 413 and p. 442.

The classic paper of Dyer upon asthenopia not connected with hypermetropia, with its illustrative cases, and the discussion it aroused, recorded in 1865, p. 28, may still be read with profit. The relations of blepharitis ciliaris to ametropia were illustrated by forty-seven cases in 1878, p. 387. Ocular headaches. 1895, p. 339.

Vagaries of accommodation and subnormal accommodation. 1889, p. 429; 1891, p. 127; 1894, p. 138.

Incidental phenomena of the shadow test, 1892, p. 388, also includes cases.

DISEASES OF THE EYELIDS.

Ptosis. Of the case of congenital ptosis recorded, 1895, p. 427, J. O. Tansley reports: "The condition and appearance of the patient is very satisfactory indeed. He can close his eyes completely and also open them enough to entirely expose his cornea; and, strange to say, the elevator of the lid in each eye has the power to elevate the lids to nearly the normal amount, whereas, previous to the operation these muscles had absolutely no power whatever.

The palpebral conjunctiva is white, thin, and apparently atrophic, but the atrophy is only apparent, not real. The thin and white appearance is caused by the removal of a portion of

orbicularis, which I purposely did at the time of the opera-
" The patient, under date of April 8, 1901, writes to Dr.
ley: "Since you have operated on my eyes in 1895 they
given me no trouble. I do not have to throw my head
to see a person as I had to do previous to your operation.
n also raise my eyelids and look upwards to an angle of
-five degrees."

n regard to the case of Resection and Advancement of the
tor Palpebræ Muscle in Traumatic Ptosis, recorded 1897,
3, C. A. Oliver reports: "Patient recently heard from, lid in
er position, and freely active."

Other cases recorded are Congenital Epicanthus and Ptosis,
p. 96; Operation for Ptosis, 1897, p. 99; Lipomatous
s, 1885, p. 49.

enign Tumors of the Lids. Cases are recorded as follows:
ma, 1896, p. 578; Lymphoma, 1898, p. 364; Neuroma, 1891,
(of which Dr. de Schweinitz reports "No further informa-
obtainable"); Vascular Tumors, 1880, p. 32; 1882, p. 335;
ma of the Tarsus, 1878, p. 408; Amyloid Infiltration of the
nd Orbit, 1878, p. 411; Epidemics of Molluscum Contagio-
1886, p. 262.

Miscellaneous. Herpes Zoster, 1867, p. 75; 1870, p. 101;
pp. 71 and 73; 1874, pp. 219, 221.

lepharospasm, 1874, p. 207; 1875, p. 302. Gangrene of the
1884, p. 644. Necrosis of the Skin of the Lids, 1896, p.
Alopecia of the Eyelids, 1882, p. 381. Treatment of Scars
e Lids, 1881, p. 219.

LACHRYMAL APPARATUS.

Of the case of *Acute Dacryo-Adenitis*, recorded 1884, p. 729,
. Pooley states that he has not heard from the patient since
ime of his original report, when she had fully recovered.

Regarding the *Angioma of the Lachrymal Gland*, recorded
, p. 321, G. E. de Schweinitz reports no further informa-
obtainable.

He also reports regarding the "*Growth in the Region of the*

Lachrymal Sac, with the Histological Characters of Tubercle": "This patient has been seen a number of times since the growth was removed, and always in perfectly good condition. The last examination was made by my assistant, Dr. Veasey, in March, 1901. There was no sign of recurrence and no symptom of tuberculosis in any region of the body. The patient reported for the relief of a slight epiphora."

Cases are also recorded of spontaneous prolapse of the lachrymal gland with extirpation, 1887, p. 494; Congenital Fistula of the Lachrymal Sac, 1874, p. 209; Injurious effects of Lachrymal Obstruction, 1878, p. 397; Treatment of Strictures of the Nasal Duct with Large Probes, 1879, p. 602; and Dacryocystitis in Nursing Infants, 1879, p. 537.

CONJUNCTIVA.

Ophthalmia Intermittens is the name under which is recorded a case (1865, p. 24) that anticipates Fuchs' description of periodic brief episcleritis. Of this case, Hasket Derby reports that the patient continued to have similar attacks monthly until June, 1867, when she was lost sight of.

In the Transactions for 1870, page 88, is recorded "A Peculiar Case of Conjunctival and Corneal Inflammation," which we might now be disposed to regard as an irregular form of *vernal conjunctivitis*. D. B. St. John Roosa reports that the patient is well, the mother of several children, her eyes sound.

Chronic Membranous Conjunctivitis. Of the case recorded, 1897, p. 36, Dr. Lucien Howe reports: "This little patient having been an inmate of a public institution has been under almost constant observation. In spite of the use of sublimate washes, or other forms of antiseptic application, and in fact of all forms of treatment which have been suggested by visiting surgeons, the membranous growth has not entirely disappeared at any time. On the contrary, it has extended at times over the upper palpebral conjunctiva.

Within the last two months one exacerbation has been un-

severe. The entire conjunctiva was suddenly covered
his growth, the lids became so much swollen as to make
ost impossible to see the cornea. The part which was
had become infiltrated, and vision was reduced to per-
n of light. In view of this condition the upper lid was
l transversely near the outer canthus and also just ex-
y to the upper punctum, both incisions being carried up-
o the margin of the orbit. A strong thread was then
through the upper lid and the ends of the suture being
gether were attached with plaster to the forehead. In
ay pressure on the cornea was relieved and the membrane
upper lid freely exposed.

on applications of protargol, twenty per cent.; sublimate
two thousand, and ice bags, the membrane covering the
and lower lids gradually disappeared and the cornea finally
ed almost its normal transparency. This attack lasted
two months, and, although the patient is now much bet-
e false membrane still covers about one-third of the con-
va near the cul-de-sac. The other eye has shown no sign
ction.

ses are recorded of *diphtheritic conjunctivitis*, 1870, p. 91;
p. 240; 1896, p. 694; and 1897, p. 44.

rulent Conjunctivitis, 1865, p. 12; 1874, p. 242; 1890, p.
891, p. 236; 1897, p. 44; and 1893, p. 568.

achoma cases are recorded, 1870, p. 114; 1874, p. 238;
p. 148.

scellaneous. A rare form of ophthalmia granulosa asso-
with ichthyosis, 1887, p. 582.

berculosis of the Conjunctiva, 1896, p. 559.

cain Conjunctivitis is recorded in 1888, p. 30 and p. 155.

quirity Ophthalmia, 1884, p. 679.

rosis of the Conjunctiva, 1890, p. 626.

ngenital Pterygium, 1878, p. 386.

mor of Conjunctiva, Simulated Cyst, 1878, p. 430.

mma of the Conjunctiva, 1878, p. 415.

the case of cavernous angioma of the conjunctiva, re-

corded 1895, p. 372, J. A. Lippincott reports that in April, 1901, there has been no recurrence and the eye is perfectly normal.

Cases of Ocular Filaria are recorded, 1890, p. 727.

CORNEA AND SCLERA.

Keratitis. Regarding the case of Superficial Punctate Keratitis, recorded 1896, p. 706, B. A. Randall reports that the patient was seen six months later with the eye comfortable, little superficial opacity, and growing usefulness of its greatly lowered vision. Large type was read with a glass.

Of the case of Interstitial Keratitis, Congenital in Origin, recorded 1898, p. 371, H. F. Hansell reports that when last seen there was a small opacity that seemed to be permanent in the lower corneal limbus.

Cases of Trophic and Neuro-paralytic Keratitis are recorded, 1866, p. 19; 1868, p. 117; 1871, p. 138; 1894, p. 222; and 1897, p. 107.

Malarial Keratitis. Cases are recorded, 1880, p. 91; 1889, p. 331. Keratitis from Pressure of Obstetric Forceps, 1895, p. 454.

Suppurative Keratitis, 1885, p. 40; 1896, p. 716; 1898, p. 374.

Corneal Ulcers, 1888, p. 133; 1898, p. 423.

Oyster Shuckers' Keratitis, 1895, p. 313.

Opacities of the Cornea. In the cases of hereditary opacities recorded, 1892, p. 321, C. A. Oliver reports that four years ago they presented the same condition as at the time of the original report. Use of the Curette for Inveterate Pannus, 1889, p. 304.

Miscellaneous. Of the case of Dermoid Cyst of the Cornea recorded, 1880, p. 166, S. D. Risley reports that the eye has been under observation for several years without notable change. Other cases recorded are: Recurrent Papilloma of the Cornea-scleral Junction, 1879, p. 549; Gumma of the Sclera, 1874, p. 195; Kerato-Conus, treated surgically, 1898, p. 341; Gouty and Rheumatic Sclerotitis, 1873, p. 34.

IRIS AND CILIARY BODY.

itis. Regarding the case of persistent iritis recorded, 1895, 5, J. O. Tansley reports: "During the treatment of this nt I impressed upon him the importance of a correct mode e, and the result has been that he has had no gouty or matic attacks since, and he writes me as follows: 'Dear or, your favor of the 20th was received some days ago. In will say that I will call to see you some day next week. yes have been in fair condition for the past four years. I you have a record of it. I read a great deal every day, also write in the evening, which is a fair test for a lame eh? You may report my eyes in good normal condition. rely, S. B. R.'"

the case of Chronic Iritis treated by iridectomy, recorded p. 630, Hasket Derby reports that the patient died a few later, having become substantially blind.

egarding the clinical value of repeated careful corrections anifest refractive error in plastic iritis, 1892, p. 397, C. A. r reports: "Studies continued in a desultory way; still of opinion." Changes of refraction connected with iritis are reported, 1887, p. 599; 1888, p. 70.

liscellaneous. Division of Posterior Synechia is recorded, p. 67; 1871, p. 130.

ases of Gumma of the Ciliary Body are recorded, 1871, p. nd 1874, p. 174.

ases of Tuberculosis of the Iris and Ciliary Body are re-d, 1883, p. 472 and 474; 1885, p. 59; 1893, p. 510; and 1896, 1.

case of prolonged mydriasis is recorded, 1889, p. 408, re-ing which O. F. Wadsworth reports: "In November, 1899, n = 20/12 in either eye. The right pupil reacts well to and accommodation. The left pupil, usually 3 mm. in di-er, does not react even consensually, but reacts well to ac-modation. General health has been quite good." The l reflex in blindness, 1896, p. 671.

Pupil symptoms in brain tumor, 1891, p. 56; 1896, p. 594.

For cysts and other tumors of the iris see Intraocular Growths.

CHOROID.

In the case of chorio-retinitis in the macular region following a flash of lightning, recorded 1896, p. 613, C. A. Oliver reports the ultimate results as being slightly less than normal vision in each eye, with negative scotomata, but the patient is actively engaged as an artist.

Other cases of *choroiditis* recorded are: Disseminated Syphilitic, 1874, p. 196; Recurrent Irido-Choroido-Retinitis, 1890, p. 629; Choroiditis with Ring-scotoma, 1887, p. 435. This case, S. M. Burnett reports, has not been seen since the original communication. Metastatic Irido-Choroiditis and Panophthalmitis are recorded, 1882, p. 396; 1889, p. 314; 1896, p. 611; and 1899, p. 535.

Regarding the choroidal changes at the macula, noted 1891, p. 17, Hasket Derby reports: "The patient whose case is here detailed is still living at the age of 84, and retains peripheric vision, comparatively unchanged. I firmly adhere to my belief that the macular change in sclerotico-choroiditis posterior, characterized by a pigment deposit and local hemorrhage, and resulting in a permanent central scotoma, precludes a retinal separation in that eye." Another case of ophthalmoscopic changes is recorded, 1896, p. 606.

Sub-Choroidal Hemorrhage. The completion of the case recorded, 1882, p. 378, is reported by G. Hay. The patient had been quite well up to about 8 P. M., September 8, 1882. Then had headache, vomiting, and subsequently became unconscious, and died that night. A trace of albumen in the urine had been reported by the attending physician previous to the operation.

Cases of *ossification of the choroid* are reported, 1875, p. 306; 1878, p. 406; and 1883, p. 564.

SYMPATHETIC DISEASE.

In the case of *Sympathetic Neuro-retinitis*, 1883, p. 486; J. A. Spalding reports, under date of June 4, 1901: "Day before yes-

y the daughter of patient called and wanted me to see her
er, who had been suffering with the only remaining eye for
veeks. Examination showed right orbit vacant, cicatricial
nctival bands, no tenderness or pain on pressure in orbital
, and no sensation of pain in opposite eye from pressure
ht orbit. O. S. Pupil apparently adherent all around to
apsule, and symptoms of serous iritis. One-fifth per cent.
ine in twenty-four hours dilated the pupil fully without
g any adhesions, and the ophthalmoscope revealed lymph
light pigment on lens capsule (circular in shape), lens trans-
t, vitreous opacities very faint and fine and scarce, near
rior pole of lens. Optic nerve normal, except new con-
ve tissue. Vessels at upper margin projecting into vitre-
say 3 mm., in corkscrew-like form. Retina and choroid
ently normal. Patient is Danish and does not understand
etters, but with the letters for illiterate test she gets 0.3,
— 1. D. Sph. = 0.6. She had been able to read all she
ed to for years (ever since the enucleation or soon after) up
o weeks ago, when she had this "blur" over O. S. Had
using plus 3 D. Sph. with comfort. The iritis is slowly
nishing and permanent recovery seems assured."

case of Sympathetic Neuro-Retinitis ending in recovery
o recorded, 1898, p. 452.

egarding the case of sympathetic *inflammation following act operation*, recorded 1880, p. 26, F. M. Wilson reports she retained perception of light in both eyes up to the time r death two years later, but declined further operative inter-ce.

Regarding the case recorded 1894, p. 49, Dr. Wilson says: arles Hammill has been continuously under observation. last record is November 3, 1900. L. V. = 20/70. Eyes ."

Of the case of *doubtful Sympathetic Irido-Cyclitis*, recorded , p. 608, B. L. Milliken reports: "On July 19, 1897, he examined and gave the following history: In April, 1897, an attack of inflammation of the left eye, lasting some six

months, the same being of a mild type, not sufficiently severe to prevent him from doing his professional work. About May 23d he had a severe attack of inflammation in the right eye, which sent him to bed for two weeks. The cornea became extremely hazy and he was unable to see anything for four days. The attack gradually subsided, however, leaving the eye clear, and at the time of the examination the vision of both eyes was 6/6ths, and the ophthalmoscopic condition showed no positive changes in the eye-ground other than possibly a slight increase in the color and an atrophic crescent outward in each eye. No examination of this patient's eyes has been made since the above date, but in conversation I have learned that there has been an occasional attack in one or the other eye, not leading, however, thus far, to any serious trouble. He has been able to do his professional work steadily, and only occasionally when his general health becomes impaired, or he is nervously depressed, is he likely to have trouble."

Other cases of sympathetic ophthalmitis are recorded, 1874, p. 198; 1884, p. 700; 1898, p. 428; from dislocation of the iris under the conjunctiva, 1893, p. 513; from glioma of the retina, 1899, p. 485.

Cases of *sympathetic irritation* are recorded, from ossified choroid, 1868, p. 97, and from a foreign body in the eyeball, quiescent for thirteen years in 1874, p. 203.

Optico-Ciliary Neurotomy. 1881, p. 280.

INJURIES TO THE EYE.

Bruise of the Eye-Ball. The case of Commotio Retinæ recorded in 1883, p. 593, E. E. Holt reports: "Has remained cured. He is a successful lawyer in this city."

In the case of localized Edema of the choroid and the retina recorded, 1888, p. 68, Edward Jackson reports that the eye remained sound, with unimpaired vision, six years after the injury.

In the case of rupture of the choroid recorded, 1886, p. 291, B. A. Randall reports: "Lenticular opacity slowly formed, caus-

ss of all useful vision. Two years later the blow of a shin-
all couched his lens, and with plus 12 he had 6/12ths
as in the other eye, and read Jæger 3 with plus 15."
ipture of the Choroid is also recorded, 1873, p. 79. Of
se of traumatic rupture of a retinal vein, recorded 1896,
, C. A. Oliver reports: "When last seen, two years ago,
ound apparently normal and eye properly functioning."
emorrhage near the macula from indirect injury, 1881, p.
Rupture of the Iris. Of the cases recorded, 1896, p. 640,
Harlan reports that in Case IV the condition remains un-
ed, and the others have not been heard from. Another
s recorded, 1878, p. 430; also, 1899, p. 541.
slocation of the iris under the conjunctiva, followed by
l sympathetic ophthalmia, is recorded, 1895, p. 513.
ibluxation of the lens occurred in Randall's case of Rup-
of the Choroid above referred to.
case of multiple rupture of the sclera with partial disloca-
of the lens into the anterior chamber is recorded, 1896, p.
which Dr. Randall reports was seen several years later with
media, slight iris motion, medium pupil, and unaided vision
12ths with some accommodation.
case of contusion of the eyeball followed by intraocular
a is recorded, 1892, p. 335. Rupture of the lens by hang-
s recorded, 1866, p. 13; 1869, p. 272; 1875, p. 354. Sub-
nctival Dislocation of the Lens is recorded, 1885, pp. 140
47.
flex Nervous Phenomena relieved by abscission of an injured
re recorded, 1870, p. 110, and diabetes insipidus relieved by
eation of an injured eyeball, 1878, p. 506.
ases are also recorded of scleral wound, sutured, 1873, p.
iceration from the pin of an eye-glass, 1881, p. 223; Air in
Vitreous, 1885, p. 54; Gunshot Wounds of the Eyeball,
p. 275; cases of Mercurial Treatment of Traumatic Irido-
tis, 1898, p. 602; of Irrigation of the Anterior Chamber for
trating Wounds, 1889, p. 341.
Blindness from blows upon the orbit is recorded, 1891, p. 174.

Of these cases, P. A. Callan reports that in Case I, O. D. remains totally blind; Case II was lost track of six weeks after the injury; Case III O. S. counted fingers at eight feet three months after the injury; Case IV O. S. was totally blind four months after the injury. Dr. Callan writes: "In all, I have seen about twenty-odd such cases in the last eleven years. I have been on the lookout for them in the different hospitals with which I am connected, and I am safe in saying that the best resulting vision is the ability to count fingers at a few feet. Perhaps three, all told, have retained light perception, the best being the counting of fingers in one part of the field. All the other cases were totally blind. In all the cases, atrophy of the optic nerve was most marked. There is another class of cases following gunshot wounds, generally self-inflicted, with hemorrhages and exudations in choroid and retina and not necessarily due to fracture of the foramen opticum. I did not mean the latter class when I stated that I had twenty-odd. I only refer to the nipping of the optic nerve at the foramen."

Laceration of the Eyelids. Cases are recorded, 1880, p. 86.

INJURIES, INCLUDING THE RETENTION OF FOREIGN BODIES.

Foreign Bodies in the Cornea. Cases of difficult removal of such foreign bodies are recorded, 1874, p. 204; 1882, p. 384.

Foreign Bodies Spontaneously Expelled from the Sclera. Regarding the case recorded, 1890, p. 565, B. L. Millikin reports: "This patient has been seen occasionally. There has been no trouble with his eyes since."

With regard to the case recorded, 1898, p. 386, J. P. Worrell reports nothing new, the patient having been within his cognizance though not directly under observation.

Cases of foreign body lodged in the lens are reported, 1879, p. 595; 1882, p. 422; 1885, p. 97; 1897, p. 83. Of this last case, Wm. Thomson reports that when last seen, March 23, 1898, a correction of +9.50 sph. ◯ +1.50 cyl. ax. 50° gave V. = 6/6 +2.50 sph. was added for near. With these he was able to work at his trade as a weaver. The other eye was amblyopic.

Cases of foreign body in the iris are recorded, 1891, p. 70.

reference to the second of these, S. B. St. John reports that seen this year the eye remained quiet, a portion of the ecame opaque, but the rest remained clear. The ophthal- ope showed the fundus fairly well. The nerve was rather The vision was counting fingers at five feet.

reign Bodies in the Vitreous. Magnet Extraction. Regard- ses recorded, 1891, p. 65; 1893, p. 546; 1895, p. 435; E. lt reports that so far as known they have done well. "No f sympathetic inflammation in consequence of the accident peration has come to my notice. I see no reason to e the opinion expressed in the papers referred to as to the bility of the operation."

the case recorded, 1897, p. 154, C. A. Oliver reports vision restored. Last study made six months ago.

ses of use of the Roentgen Rays in diagnosis of such for- odies are recorded, 1896, pp. 708 and 711; 1897, pp. 86 8. Regarding the latter case, Wm. Thomson reports of R.: "At the present time there is no light perception, but e presents a fair cosmetic appearance. The commissure is y smaller than its fellow, and the ball deeper in the orbit, ie cornea is clear and bright. The iris is drawn down to ter side, and the pupil closed to a small black streak. The ll is soft, but there has been no pain or tenderness. The returned for occasional pain in his good eye, and a dull che, but there was no evidence of sympathetic trouble, the opia being due to a hyperopia of + 1.25."

ses of Diagnosis with the Electro-magnet, 1898, p. 456.

ldditional cases of Magnet Extraction from the Vitreous are led, 1884, p. 739; 1885, p. 100; 1889, p. 349; 1892, p. 328; p. 52; 1899, p. 571.

her cases of foreign body in the vitreous are recorded, pp. 104 and 108.

the sclerotic, optic disk, and iris, 1875, p. 303.

the retina, 1875, p. 308; 1882, p. 332.

ass embedded in the ciliary body, 1882, p. 375.

oreign bodies in the orbit, 1890, p. 569; 1894, p. 58.

GLAUCOMA.

Attacks Excited by Mydriatics. Of two cases recorded, 1867, p. 35, Hasket Derby writes: "It is scarcely necessary to refer to this subject, it being now generally admitted that the use of mydriatics may possibly bring on an acute glaucoma in an eye predisposed to this disease, and that it is desirable to avoid the use of mydriatics after middle age, certainly for purposes of examination of the refraction. I may, however, here make the claim that my paper on this subject was the first that ever conveyed the above warning. Wharton Jones (Medical Times and Gazette, Vol. 1, pp. 111, 112) had called attention to the fact that in acute glaucoma the symptoms might be aggravated by the instillation of a mydriatic; and Von Graefe (A. F. O. XIV Jahrg. Abth. II, S. 117) had mentioned a case in which the chronic pressure due to an intraocular tumor was changed into acute by atropine used for purposes of examination. But that a hitherto unsuspected predisposition to glaucoma might by use of a mydriatic be transformed into the actual disease had, so far as I know, never been pointed out before the publication of my paper."

Regarding the case of transient pulsation of the retinal arteries induced by application of homatropine, recorded 1890, p. 653, G. C. Harlan reports that the patient had an attack of well-marked glaucoma about two years later. Cases of glaucoma following the use of Duboisia are recorded, 1880, p. 148, and 1881, p. 273.

In regard to the case of *fulminating glaucoma* recorded, 1882, p. 421, S. B. St. John reports that it was followed for fifteen years. Vision was good for ordinary purposes and she kept the village post-office for several years.

In the case of *sudden blindness in a previously impaired eye after removal of the other*, for absolute glaucoma, J. A. Lippincott reports the patient never recovered sight. A similar case is recorded, 1885, p. 152.

Glaucoma from Various Causes. Malignant glaucoma and

ma with albuminuric disease are recorded, 1890, p. 634, 99, p. 526.

ses indicating that astigmatism is a factor in the causation ucoma are recorded, 1888, p. 126. The constitutional in the causation of glaucoma is indicated, 1892, p. 283; p. 408.

ses of hemorrhagic glaucoma are recorded, 1869, p. 46; p. 470; 1894, p. 98.

garding the case of chronic glaucoma recorded, 1896, p. . L. Randolph reports that the vision in the right eye is oths, and in the left eye 20/30ths. Ophthalmoscopically is no change.

nple chronic glaucoma cases are also recorded, 1889, p. 896, p. 723.

the case of primary glaucoma with coloboma of the iris olycoria recorded, 1891, p. 59, G. E. de Schweinitz reports: he time of the previous report there had been no glau- ous attack following the operation, but the lens had be- cataractous. Shortly afterwards the patient appeared a slightly increased tension in the eye, which yielded to e. Vision was reduced to light perception on the tem- side. A number of such attacks occurred, and in June, bullous keratitis of this eye developed. Enucleation was ed but declined. During the succeeding years, up to the xamination, on the 10th of May, 1900, there were numerous s of bullous keratitis, which always subsided under the nce of eserine, and the internal administration of bichloride ercury and iodide of potassium. Enucleation was repeat- advised but always declined. The right eye, which at the of the original report showed several spots of disseminated oiditis, continued to be in good condition and to retain nor- vision until December, 1895. Between that date and the of January, 1897, the patient not having been seen in the val, the choroiditis of the right eye very much increased. h splotches and yellowish exudation with streakings in the ula appeared. About this time albumin was discovered in

the urine, and gradually the patient developed the typical signs of interstitial nephritis, and associated with the disseminated choroiditis characteristic ophthalmoscopic appearances, namely, a low-grade retino-choroiditis and macular areas of degeneration. On the 10th of May, 1900, the date of the last examination, the left eye was entirely blind, but free from irritation, the cornea densely hazy, and the lens cataractous and calcareous. The vision of the right was 6/45ths, there were spots of exudative retino-choroiditis, and areas of fatty degeneration throughout the macular region."

Glaucoma occurring after cataract extraction is recorded, 1891, p. 120; 1898, p. 297. Operative treatment cases, 1880, p. 95; 1883, p. 528; 1889, 287. Taxis for glaucoma, 1897, p. 156. Prolonged acute glaucoma, 1896, p. 734. Glaucoma followed by brain diseases, 1882, p. 405. Spontaneous rupture of the eyeball, 1899, p. 488.

Cases of *Buphthalmus* treated by operation are recorded, 1880, p. 164; 1898, p. 308.

CRYSTALLINE LENS.

Cataract Extraction. In the case of cataract extraction with unusually large loss of vitreous recorded, 1894, p. 129, J. A. Lippincott reports that the patient was last seen September 10, 1894. O. D. plus 11, vision equal to 20/80, and with plus 15D. he could read good-sized print, and was able to work satisfactorily.

Regarding the case of expulsive intraocular hemorrhage recorded, 1899, p. 522, R. L. Randolph reports: "The eye is in about the same condition as it was immediately after paracentisis of the vitreous, *i. e.*, has retained its shape, is perfectly blind, and has never been painful since the paracentisis." Other cases are recorded, 1895, p. 448, and 1897, p. 136.

Cases and statistics of Cataract Extraction are recorded, 1873, pp. 50 and 70; 1874, p. 251; 1879, pp. 527 and 578; 1883, p. 497; 1885, pp. 28 and 149; 1886, pp. 298 and 342; 1887, pp.

and 421; 1890, p. 572; 1891, pp. 75, 80, and 85; 1892, p. 428; , p. 124; 1895, p. 403; 1897, p. 126.

Suture of Cornea in Cataract Extraction, 1867, p. 68. Anetics, 1881, p. 189 and 195. Irrigation of the Anterior mber, 1889, p. 341, and 1891, p. 85. Removal by suction, , p. 594. Delayed union after extraction, 1898, p. 390. ppearance of iris after extraction, 1882, p. 348. Jaeger's lschnitt operation, 1887, p. 505. Calcareous lens, 1888, p. 1898, p. 454.

Secondary Operations are recorded, 1891, p. 120; 1894, p. 133; , p. 398; 1898, p. 297; 1899, p. 563.

Artificial Ripening Operation, 1883, p. 566, and 1893, p. 523. Regarding these last cases, Edward Jackson reports that all inued to do well after extraction, but he regards the ripenoperation as generally unnecessary, and very rarely justified.

Cases of *dislocated lens* and its extraction with or without the nt are reported, 1875, p. 291; 1885, pp. 69 and 76; 1888, p. 1890, p. 598; 1894, p. 239.

Cases of nucleus in the lens of a child, 1880, p. 160.

Partial absorption, 1882, p. 363; 1884, p. 694.

The so-called cure of cataract by electricity, 1881, p. 305.

The rapid development of opacity in the lens, 1887, p. 601.

Hereditary cataract, 1890, p. 722.

Cholesterin crystals in the lens, 1897, p. 142.

Anomalies of the epithelium of the lens, and anterior polar ract, 1899, p. 478.

VITREOUS.

Cases of Serous Effusion into the vitreous, probably due to rial poisoning, are recorded, 1882, p. 345; 1885, p. 64. With rd to these cases, W. W. Seely writes: "As I never heard these cases again, I assume there was no return. I think ral cases have been put on record after it was found out t they were — effusion due to malaria, the same as in the panic cavity, etc.

Hemorrhage into the vitreous is recorded, 1873, p. 32; 1887, p. 542; 1895, p. 423. Regarding this last case, Chas. J. Kipp reports: "The patient has had no further trouble with his eye. He writes, July 11, 1901, that his eyes have remained in the same condition as stated in the original communication. He is able to use his eye as well as ever, and the sight remains very good."

Connective Tissue Growths, with or without vessels (Retinitis proliferans), are recorded, 1875, p. 304; 1879, p. 547; 1886, p. 355; 1887, p. 542; 1889, p. 426; 1897, p. 158.

Fluid vitreous, 1869, p. 8.

Pseudo-Glioma, 1887, p. 485.

Treatment of opacities by the Faradic current, 1882, p. 360.

Surgical Treatment of Membranous Opacities, 1888, p. 84.

RETINA.

Retinitis Pigmentosa. Regarding the possible retardation of this disease by treatment with electricity and the cases recorded, 1886, p. 217, Hasket Derby writes: "I have had no opportunity of examining these patients since I wrote the paper, and only know that they retain some vision. What part the electricity has played in this result I am unable to conjecture. But I still consider the method well worth trying." Other cases are recorded, 1887, p. 553; 1878, p. 495.

Leukemic Retinitis. Of the cases recorded, 1897, p. 212, C. A. Oliver writes: "All but the first patient are dead. Four of the eyeballs are in my possession, and studies almost completed show some extremely curious and interesting pathological changes, which I have in part prepared for early publication." A histological examination of the eye from a case of pernicious anæmia is recorded, 1896, p. 654.

Other Forms of Retinitis. Cases of albuminuric retinitis are recorded, 1878, p. 432; 1882, p. 423; 1886, pp. 184, 199, and 364; 1895, p. 391; 1898, p. 430; 1899, p. 526.

A case of diabetic retinitis is recorded, 1868, p. 61.

Cases of gouty retinitis, chorio-retinitis, and neuro-retinitis

ecorded, 1893, p. 473. Retinitis punctata albescens, 1893, 4. Retinitis circinata, 1897, p. 181. Central retinitis, 1897, 8.

egarding a case of double chorio-retinitis with partial de- ration of the optic nerve associated with Curious Lymph vasation into the Retina and Vitreous, recorded 1887, p. C. A. Oliver reports: "Condition as before."

iseases of the Retinal Vessels. Regarding the cases of em- m of the central artery, recorded 1882, p. 411, W. F. Mit- rf reports:

ase I. The lady is still living, left eye shows atrophy of and vessels (partial). It has some peripheral vision. II. Mr. S. died of cerebral apoplexy some ten years after ttack of embolism. He retained some peripheral vision in ft eye up to the time of his death. Other cases of embol- f the artery are recorded, 1884, p. 689; 1887, p. 548; 1888, ; 1890, pp. 669 and 672; 1894, p. 116; 1896, p. 585.

ther forms of interrupted circulation in the retinal vessels, mia, thrombosis, etc., are recorded, 1866, pp. 2 and 11; p. 579; 1880, p. 93; 1883, p. 73; 1886, p. 199; 1891, p. 200. nalous conditions of the retinal vessels are recorded, 1880, o and 54; 1887, p. 511; 1888, p. 117; 1891, p. 190; 1894, 8.

etachment of the Retina. Of the case of detachment in both with albuminuria of pregnancy and replacement of retina, ded 1887, p. 574, O. F. Wadsworth reports that in 1892 a n-months child was born, living. In 1898 the retina was in place. Vision, R. 20/40ths; L. 20/15th. She is now

f the case of detachment treated by repeated punctures, re- d 1888, p. 100, T. Y. Sutphen reports: "There has been eturn of the detachment in the right eye. The field of n is good and with —4.50 D. spher. he has central vision /30, and he reads Jaeger No. 1 at one foot, with +0.62 D. r. In the left eye there is a secondary cataract.

ther cases of detachment of the retina are recorded, 1866,

p. 36; 1871, p. 128; 1875, p. 284; 1878, p. 422; 1879, p. 544; 1880, p. 130; 1883, p. 513; 1891, p. 30; 1892, p. 306; 1894, p. 15.

Colloid disease in the macular region analogous in appearance to the so-called Drusen in the Nerve-head. Regarding the cases recorded, 1894, p. 212, G. E. de Schweinitz reports: "Case 1. Patient seen June, 1901, condition unchanged, vision normal. Case 2. Three years after the report vision continued normal, and the ophthalmoscopic appearances represented in the water color, reproduced in the Transactions, remained unchanged. The patient had, in the meantime, married and given birth to a healthy child. About a year after the birth of this child the patient died from nephritis. She had had, for many years, albumin and tube casts in the urine."

Angioid Streaks in the Retina. Regarding the case recorded, 1896, p. 650, G. E. de Schweinitz reports: "The patient has been examined many times since the original report, the last examination being on the 28th of October, 1899. Vision, at that time, was 5/60 in each eye, and the fundus changes very similar to those depicted in the water colors reproduced in the transactions, except that the pigment masses in the macular region were somewhat greater and the general atrophic changes in the eye-ground more marked. It is interesting to note that I have seen one brother of this patient with precisely the same condition of affairs, and have reported and figured his case in the *Ophthalmic Record.* Another brother has defective eyesight, and from lay descriptions it is probable that the same condition of affairs obtains in his case, but I have not had any opportunity of examining him with the ophthalmoscope."

Cases of the Zonular Grayish White Opacity around the Fovea in Amaurotic Family Idiocy are recorded, 1887, p. 572, and 1896, p. 661.

Miscellaneous Cases. Cases are recorded of cholesterin in the retina, 1873, p. 105. Hyperæsthesia of the retina, 1865, p. 51. For report on case of changes from lightning flash, recorded 1896, p. 613, see Choroid.

For glioma of the retina, see Malignant Tumors.

OPTIC NERVE.

ptic Neuritis. Regarding the case of double neuritis sup-
l to be due to aneurism, recorded 1896, p. 598, J. B. Emer-
eports: "The patient presented herself at the hospital De-
er 19, 1899. Said she had not been troubled with either
ılsions or the 'buzzing noise' for three years.

R. V. 6/200, not improved with glasses.

L. V. 20/40, not improved with glasses.

s of both eyes contracted, right more than left. Ophthal-
ope: right eye, nerve white, veins good size, spots of pig-
in retina and round nerve; left eye, nerve white, not so
ed as in right eye. Patient had no treatment."

ases of optic neuritis are also recorded, 1874, pp. 163 and
1888, p. 166; 1889, p. 378; 1891, p. 186; 1896, p. 589.
itis after measles, 1880, p. 125. Neuro-retinitis with sud-
ılindness, 1884, p. 654.

ongenital Swelling of the optic disk, 1884, p. 721.

ptic Atrophy. Cases of hereditary optic atrophy are re-
ed, 1882, p. 355; 1884, p. 662. Apparent optic atrophy
recovery, 1879, p. 571. Optic Atrophy with Myxœdema,
p. 725. Gray atrophy with tabes, 1885, p. 158. Optic
hy following traumatism is recorded, 1894, p. 215. Dr.
. Kollock reports that the condition of this patient has re-
ed unchanged. Atrophy from sexual excess is recorded,
p. 206.

upposed hemorrhage within the optic nerve sheath is re-
ed, 1866, pp. 2 and 11. Cases of hyaline bodies or drusen
e nerve-head are recorded, 1892, p. 349; 1895, p. 355.

TOXIC AMBLYOPIAS.

uinine Amaurosis. Regarding the case recorded, 1887, p.
D. B. St. John Roosa reports: "The patient is married and
g in Scotland. She has good central vision, visual field
l, is in good health." Other cases of Quinine Amaurosis
recorded, 1881, p. 262; 1885, p. 66; 1887, p. 602; 1891, p.
and 1898, p. 405.

Other Forms. Amblyopia induced by Osmic Acid is recorded, 1866, p. 34.

Amblyopia produced by salycilic acid, 1895, p. 405.

The autopsy and microscopical examination of specimens in a case of toxic amblyopia — tobacco and alcohol — are recorded, 1897, p. 186.

Optic Neuritis from lead poisoning is recorded, 1885, p. 50.

AFFECTIONS OF THE TRACTS AND CENTERS.

Hysterical Blindness. Regarding the cases recorded, 1897, p. 200, A. A. Hubbell reports: "Case I. Examined April 4, 1901, by Dr. Sherman Voorhees, of Elmira, N. Y., who reports that the vision of the affected eye (left) was nearly all of 15/15 or 15/20 easily, with a slightly hazy appearance of the letters; field of vision, normal; color-sense, normal centrally, but impaired peripherically in the visual field; optic disk pale at temporal side, nasal side of normal color; other parts of the eye normal in appearance. The lachrymal excretion on the left side is the same as on the right — normal, except when patient and eyes are tired, when it is in excess. A little over a year ago patient had an illness which began suddenly, by vomiting, lasting for two days, and this was followed by 'contraction' of the fingers of the right hand, and 'she had no use of them.' She had 'little use, also, of the left leg.' She was in this condition for several months, but has now recovered from it, and, although anæmic, says she feels 'better than in a long time.'"

Case II has continued in good health, with no visual disturbances.

Case III remained well a year after report to the society, with vision perfectly normal in every respect, according to statements of an intimate friend.

Other cases of hysterical Amblyopia are recorded, 1875, p. 295; 1882, p. 366; 1882, p. 400; 1884, p. 649; 1888, p. 80; 1889, p. 327.

Hemianopsia. Homonymous Hemianopsia is recorded, 1871, p. 22. Regarding this case, Wm. Thomson reports: "Last

October 1, 1885, in exactly the same condition as in 1871, r as half vision is concerned. His general health is good. s able to work all day as a puddler." 1889, p. 359; 1890, 70 and 479.

Iemianopsia with Malaria, 1889, p. 359; 1890, p. 640.

ector Defects are reported, 1875, p. 337; 1890, p. 479; 1892, 8.

itemporal Hemianopsia, 1875, p. 298.

nilateral temporal Hemianopsia, 1885, p. 115.

bsence of the optic chasm, 1886, p. 367.

Ionocular Diplopia. Regarding the case recorded, 1894, 3, G. E. de Schweinitz reports: "No further ocular exation obtainable. Patient died February, 1901, of pneuia. He is said to have been able to attend to his business rs, but complained much of pain in the head."

here are also recorded cases of hereditary amblyopia, 1892, 0. Amblyopia of squinting eyes, 1886, p. 287. Reflex lyopia, 1875, p. 325. Photopsies after enucleation, 1878, 9.

earing upon *binocular vision* and the education of the enare stereoscopic illusions, 1889, p. 449. The winking test, p. 551; and 1898, p. 434. Tests of binocular vision, 1890, o; and learning to see at 40, 1898, p. 460.

INTRAOCULAR GROWTHS.

arcoma of the Choroid. Of the cases recorded, 1874, p. 185, . Wadsworth reports: "Case I died in 1876 or 1877, with toms pointing to recurrence of sarcoma in the liver. Case as quite well June 23, 1900."

Regarding case recorded, 1893, p. 497, C. A. Oliver res: "No return; patient healthy and pursuing a large busi-."

n the case recorded, 1893, p. 503, Emil Gruening reports the patient came under observation again in 1900, seven s after the removal of the eyeball. There had been no reence in any part of the body.

In the case of Leuco-Sarcoma, with enucleation in the glaucomatous stage, G. E. de Schweinitz says: "On April 7, 1901, the patient reports as follows by letter: 'I have had no trouble whatever with the socket and have worn the artificial eye comfortably. My left is as good as it was at the time of operation, three years ago. With the exception of an attack of sciatica during the present year, my general health has been perfect.' It will seem therefore that there are no signs of recurrence in loco or symptoms of metastasis."

Regarding the case reported, 1875, p. 345, R. J. McKay reports: "The child died about fifteen months after the removal of the eye, from some form of brain disease, as stated by a member of the family. No autopsy was made." Of the cases recorded, 1883, p. 557, Chas. J. Kipp reports that Case II died in 1900, from some obscure disease of the liver. No local relapse. Case III. The patient died in 1890 from tumor of the liver. No autopsy. No local relapse of sarcoma."

Other cases of sarcoma of the choroid are recorded, 1867, p. 39; 1873, pp. 24, 26, and 31; 1874, pp. 190 and 193; 1879, pp. 560 and 594; 1881, p. 258; 1882, p. 393; 1885, p. 84; 1896, p. 538; 1897, p. 76; 1895, p. 374.

Sarcoma of the Iris. Cases are recorded, 1869, p. 14.

Sarcoma of the Ciliary Body. Of the case recorded, 1896, p. 532, S. D. Risley reports: "Two years later there was no recurrence of the disease."

Cases of *carcinoma* of the choroid are recorded, 1890, p. 654; 1896, p. 538; 1898, p. 313.

Enchondroma of the Choroid. Regarding the case recorded, 1897, p. 72, Edward Jackson reports that the patient is still enjoying good health. When last seen, September 24, 1900, the right eye was quite normal and the left orbit was free from any sign of recurrence, and was healthy in all respects. A specimen from a similar growth was exhibited before the society, 1873, p. 31.

Glioma of the Retina. Regarding the case recorded, 1890, p.

V. H. Carmalt reports: "Lost track of patient after 1894, hen no return of disease."

her cases are recorded, 1873, p. 11; 1870, pp. 70, 72, 73, 4; 1875, p. 349; 1880, p. 87; 1882, p. 364; 1883, p. 591; p. 717; 1887, p. 483; 1888, p. 106; 1892, p. 335; 1896, p. 1899, p. 485.

st of the Iris. Regarding the case recorded, 1890, p. 718, Risley reports: "No trouble with the other eye after the ation of the ball containing the cyst."

ses are also recorded, 1870, pp. 58 and 64; 1878, p. 385; p. 104; 1889, p. 326; and 1895, p. 393.

EXTRAOCULAR TUMORS.

ithelioma of the Lids. Regarding the case recorded, 1894, , G. E. de Schweinitz reports: "The patient was not seen after the original report was made, which, as the title states, ne year after the operation. A letter received on the 21st ril, 1901, from her husband states that she died four years that is to say, in 1898, from heart disease; that the eye ned during these years in perfectly good condition; that was no recurrence of the growth, and no untoward ocular of any character."

ther cases of epithelioma of the lids are recorded, 1885, p. 894, p. 137.

arious Lid Tumors. Adenoma of the Meibomian Glands is ded, 1895, p. 383.

arcoma of the Lid, Simulating Meibomian Cyst, is re- d, 1887, p. 517; 1893, p. 505; 1894, p. 91; 1899, p. 519.

egarding the congenital growth at the inner canthus, re- d 1896, p. 578, A. A. Hubbell reports that the child died a after the operation.

or vascular Tumors and Lymphoma, see Diseases of the

pithelioma. Regarding the case recorded, 1898, p. 324, in h the growth was seated in the caruncle, G. E. de Schwein- eports: "In June, 1898, fourteen months after the removal

of the growth, the physician who brought the patient to the hospital reported that there had been no return of the tumor, and that the patient and his eye were in perfectly good condition."

Cases of *Sarcoma of the Conjunctiva* are recorded, 1897, p. 538; 1890, p. 545; 1898, pp. 369 and 468; 1873, p. 28; 1882, p. 387.

Regarding the case of Melano-Sarcoma of the Conjunctiva and Cornea, recorded 1886, p. 264, W. F. Mittendorf reports: "The patient died about three years after the enucleation of the eye. There was no return of disease in the orbit."

Tumors of Orbit. In the case of partially Bony Sarcoma of the orbit, recorded 1891, p. 169, B. L. Millikin reports: "This case was examined in December, 1894, and there was no indication of any recurrence of the growth. I am quite sure this case would have returned if there had been any further development of the trouble since."

Regarding the case of Fibro-Sarcoma of the Orbit, recorded 1898, p. 291, F. M. Wilson reports: "Mrs. C. has been continuously under observation. The stretched upper lid now smoothly lines the whole orbit. The last record, March 5, 1901, is 'No sign of recurrence.'"

Other cases of sarcoma of the orbit are recorded, 1884, p. 696; 1894, p. 70; 1896, pp. 496 and 534; 1897, p. 31.

A case of Sarcoma of the lachrymal gland is recorded, 1882, p. 402. One of Angioma of the lachrymal gland, 1898, p. 331.

Of the tumor of the optic nerve, recorded 1896, p. 526, S. D. Risley reports: "The child died with involvement of the brain and viscera on September 20th following the operation."

Tumors of the optic nerve and its sheath are recorded, 1878, p. 383; 1879, p. 557; 1889, p. 457; 1894, p. 81; 1897, p. 185; 1899, p. 510.

Ivory Exostosis. Regarding the case recorded, 1890, p. 611, T. R. Pooley reports: "This patient soon moved to Europe. I have, however, often heard from her through her

s, wno report that there is no return of the tumor, no di-
, and vision remains as good as it was when I last saw her."
f the case recorded, 1897, p. 67, W. F. Norris reports: "I
ed a letter a year or two later thanking me for the opera-
nd subsequent improvement."
f the case recorded, 1878, p. 289, Edward Fridenberg re-
: "The case has been seen from time to time. There is
currence or tendency to recurrence. Sight is the same as
t report."
ther cases of Ivory Exostosis are recorded, 1896, p. 553;
897, p. 70; 1884, p. 698.
egarding Bony Tumor of the Orbit (Cystoid), caused by
nclosing a foreign body, recorded 1885, p. 90, B. E. Fryer
ts: "Complete recovery, with vision 20/20ths."
yperostosis and periostosis is recorded, 1879, p. 598; 1896,
3.
ases of dermoid cysts of the orbit are recorded, 1896, p. 687,
898, p. 281.
ases of Fibro-Lipoma and Lipoma of the Orbit are re-
d, 1898, pp. 281 and 294.
umors invading the orbit from adjoining cavities are re-
d, 1889, p. 368, and 1898, p. 286.
ysticercus is recorded, 1898, p. 281; also tubercular tumor.
case of Anophthalmos with Cyst of the Orbit is recorded,
p. 559.
case of Angio-Fibro-Sarcoma of the Orbit was originally
ded, 1882, p. 351, as one of non-pulsating exophthalmos,
recurring thrombosis of orbital veins. The further history
s case is reported by R. J. McKay, as follows: "The mass
ins to be felt, but not visible, in the orbital cavity; did not
e apex any more than is often observed after the enuclea-
of an eye, and it so remained until the fourth child was
January, 1889. Several months later there was a slight
gement of the orbital veins, and she had a slight subcon-
ival venous hemorrhage upon the central anterior surface

of the orbital contents, without any pain or tenderness attending it.

" No further change occurred until after the sudden and unexpected death of her husband in January, 1897, which was a terrible shock to her. Very soon thereafter the orbital veins began to swell and gradually enlarge, revealing an irregular and nodulated tumor, which was gradually filling the orbital cavity. At this time she had only occasional pain.

" The upper eyelid became greatly swollen and enlarged, and in the spring of 1899, after two years interval without menstrual flow, she had it twice with a month's interval, at which times she suffered great pain and swelling about the right orbit and right temple.

" June 2, 1899, she experienced an attack of left facial paralysis, with neuralgia of the left side of her head. She was unable to shut her left eye, and a slight abrasion of the corneal epithelium became troublesome and painful, and the vascular orbital tumor of the right side became very large, tense, and tender. Her constant sufferings were so great she reluctantly assented to an operation for removal of the tumor, ' Whenever you wished to do it.' I delayed two weeks to observe the manifestations of her left facial paralysis, which I felt was not due to the orbital tumor of the right side, but to taking cold. Within two weeks she began to close the left eye, and its corneal abrasion healed. The eye became comfortable.

" June 24, 1899, an exploratory puncture with a hypodermic needle was made, which indicated a solid tumor.

" Two days later, June 26, 1899, I removed the tumor at the Delaware Hospital, assisted by Dr. J. A. Ellegood and R. R. Tybout.

" A strong, tense, fibrous membrane covering the anterior surface of the tumor was divided with scissors, after which the dissecting out of the tumor progressed very satisfactorily. There was considerable welling up of thick dark venous blood towards the end of the operation, when the mass of veins were

The orbit was thoroughly cleared of all of its contents, to the periosteal surfaces, which appeared healthy.

The anterior and greater part of the tumor was irregular, lar, and of a tense, fibrous nature. The deeper part of the r which had occupied the apex of the orbital cavity was osed of a mass of large veins, whose walls were thick and ous when emptied of liquid and coagulated blood.

Dr. Jean Wilson, pathologist to the Delaware State Hos- for the Insane, at Farnhurst, Delaware, examined the r and reported it to be 'Angio-Fibro-Sarcoma.'

The patient recovered without any disturbing symptoms, oting a numbness of the right frontal region, which lasted six weeks. Her health generally improved and has con- d to do so up to the time of this report. The orbital cavity ge and irregular in shape, with a perfectly healthy appear- Her general health has been better the past year than wenty or more years."

DISEASES OF THE ORBIT.

f the cases of vascular disease of the orbit recorded, 1875, 7, G. C. Harlan reports that in Case I, about a year later, ulsating tumor spontaneously underwent complete consoli- n, after an attack of acute inflammation (see Transactions ternational Medical Congress, Philadelphia, 1876, p. 921). egarding the case of double vascular exophthalmos re- ed, 1888, p. 26, Chas. J. Kipp reports: "The patient died in No return of exophthalmos. With the exception of e choroidal changes, the eyes remained good till death. I cted cataract of left eye about a year after the operation ie right eye, with excellent result."

Other cases of pulsating exophthalmos are recorded, 1881, 08 and 312; 1888, p. 22; 1893, p. 605; 1897, p. 23.

Regarding the case of penetrating wound of the orbit, fol- d by exophthalmos and probably aneurism of the internal id artery, which recovered from the aneurismal symptoms out operative interference, as recorded, 1895, p. 395, B. E.

Fryer reports: "This case was seen up to four years subsequent to his injury. He had no intracranial or orbital bruit and no exophthalmos. There was marked drawing of the eyeball towards the inner canthus."

Of the case of traumatic enophthalmos recorded, 1895, p. 386, G. E. de Schweinitz reports: "No further information obtainable except that the patient remained in the hospital for about a month after the report, with practically unchanged ocular conditions."

Regarding the case of vaso-motor ataxia with eye symptoms simulating exophthalmic goitre, recorded 1895, p. 442, S. D. Risley reports: "Complete recovery."

Cases of Exophthalmic Goitre are recorded, 1875, p. 293; 1897, pp. 15 and 20.

Regarding the cases of orbital abscess recorded, 1884, p. 702, J. A. Lippincott reports: "Of Case I. At present, April 9, 1901, patient's both eyes are normal in every way. Vision O. D. 20/20, O. S. 20/20. Perfect balance of ocular muscles. Not the slightest difference in the appearance of the two eyes."

Cases of orbital cellulitis, one of which ended in death, are recorded, 1892, p. 295. Caries and Necrosis of the Orbit, 1889, p. 319. A case of bilateral recurrent inflammation of Tenon's capsule in connection with profound mercurial poisoning, 1892, p. 415.

Mucocele and abscess of the frontal and ethmoidal sinuses involving the orbit are recorded, 1884, p. 712, and 1885, p. 20.

DISORDERS OF OCULAR MOVEMENTS.

Recurrent Ocuolo-Motor Paralysis. Regarding the case recorded, 1895, p. 309, G. E. de Schweinitz reports: "The patient was again seen on April 9, 1901, and gave the following account: Since the last examination, six years ago, she had suffered from about thirty neuralgic attacks of the character described on page 310 of the original report. These attacks came irregularly. The longest interval between any two attacks has been

nonths. Each attack at the present time begins as a dull
ng pain in the forehead and temples, then travels across the
eye to the right side of the head in the mastoid and occip-
region. A few hours after the first attack begins, that is
ay, after the first forehead pains begin, and immediately
the height of the attack, vomiting sets in and the patient
mes utterly prostrated. This prostration lasts from one to
days. There are practically no prodromal symptoms.
occasionally, dizziness precedes the attack by a few hours.
ptosis of the right eye and the complete oculo-motor palsy
nally described remain unchanged. There never has been
otosis or any paresis of the external ocular muscles on the
ide. Vision of the right eye, 3/60th; ordinary print not
with any glass. Ophthalmoscopic appearances negative.
eye normal in visual and accommodative power after the
ction of a slight myopic astigmatism. No fundus lesions."
nother case is recorded, 1887, p. 460.

cular Palsies. In the case of congenital paresis of both ex-
l recti muscles recorded, 1885, p. 48, G. C. Harlan writes:
change since that report." A case of congenital paralysis
oth abducens and both facial nerves is recorded, 1881, p.
A case of congenitally inefficient external rectus with bin-
r vision is recorded, 1899, p. 503. Paralysis of lateral
ements is recorded, 1890, p. 644.

ases of paresis of the inferior oblique are recorded, 1879,
1, and 1880, p. 80. Ophthalmoplegia Externa, 1883, p. 680.
matic paralysis of the superior oblique, 1880, p. 76. Par-
s of Ocular Muscles treated with passive motion, 1887,
0.

onvergent Strabismus. The case of intermittent strabismus
low hyperopia recorded, 1881, p. 277, as reported by G.
Harlan, came to operation for strabismus some years later
nother surgeon.

trabismus with great limitation of movement is recorded,
p. 298.

Results of operation for Convergent Squint, 1895, p. 261.

Amblyopia from suppression is recorded, 1893, p. 551; 1895, p. 301.

Miscellaneous. Spastic Torticollis, apparently due to faulty position of the eyes and cured by tenotomy, is recorded, 1889, p. 381.

Vertical squint, 1870, p. 148; nystagmus with strabismus, 1875, p. 283.

Cases subjected to various operative procedures are recorded, 1878, p. 381; 1885, pp. 121 and 126; 1886, p. 345; 1891, p. 165. Penetration of the eyeball during the operation for strabismus, 1885, p. 33.

Of the cases of *heterophoria* and asthenopia, headache and other nervous symptoms recorded, 1891, p. 217, S. M. Burnett reports: "Case I was well when last heard from, three years after the operation. Case II has become another woman since the operation, with no return of trouble. Case III has not been heard from. Case IV lived for seven years, until the time of her death, in comfort, with free use of her eyes."

Of the cases of muscular asthenopia recorded, 1894, p. 144, G. W. Hale reports: "All but one have been under my observation ever since, and have remained cured as far as I know. One lived in Alabama, but I do not know what became of her."

Other cases of heterophoria treated by tenotomies are recorded, 1888, p. 176; 1889, p. 386; 1892, p. 446.

Other cases of heterophoria or insufficiencies are recorded, 1883, p. 479; 1889, p. 362; 1890, p. 483; 1892, p. 406; 1893, p. 587; 1895, p. 361.

A case of circumscribed hyperæmia with muscular insufficiency is recorded, 1887, p. 480.

Anomalous diplopia in cases of strabismus, 1894, p. 181.

PLASTIC OPERATIONS.

Regarding the case of ectropion treated by *transplantation of the skin*, recorded 1880, p. 46, Lucien Howe reports: "About two years after the report of this case was published the patient sent me a fairly good picture of herself. This showed that con-

rable contraction had taken place in the graft, but there was up to that time, any tendency to a return of the ectropion. the contrary, the lid of that eye was rather more full than corresponding lid on the other eye."

Regarding the case of Blepharoplasty, with a transplanted -flap, recorded 1883, p. 586, E. Gruening reports: "The was seen by me about ten years after the operation. The lt remained satisfactory."

Regarding the case of Transplanted Skin-flap after removal pithelioma, recorded 1884, p. 641, B. E. Fryer reports: "Two s from date of operation healing was complete. No return pithelioma. The transplanted flap had contracted to about third its original size. No eversion of the lid."

Other cases of transplantation of skin, Wolfe's Method, are rded, 1880, p. 43; 1884, p. 636; 1894, p. 135.

Of the case of ectropion of the lower lid relieved by a sliding operation, recorded 1890, p. 622, T. R. Pooley reports that emained cured.

Of the cases of restoration of the upper lid by a pedicle flap n from below the lower lid, recorded 1893, p. 597, S. B. John reports: "Case I. Result was as given in my illustra- till his death from typhoid fever about five years later. e II is today just as in the illustration; no shrinkage, no traction."

Other cases of operation for sliding flap are recorded, 1879, 78; 1891, p. 181. In the case recorded, 1896, p. 682, C. A. ver reports: "Patient dead one year later. Condition stead- bettered."

Operations for entropion are recorded, 1874, p. 249; 1880, 67; 1887, p. 496.

Case of Ectropion treated by the Italian method is recorded, 5, p. 141.

An operation for Symblepharon was recorded, 1890, p. 651.

A case of readjustment of the levator muscle is recorded, 1, p. 134.

Cases of skin-grafting upon the lid by Thiersch's Method are recorded, 1891, p. 183.

Cases are also recorded of Closing of the Orbit, 1870, p. 129.

Enlargement of the Orbit for Prothesis, 1897, p. 63.

Sponge-grafting in the Orbit, 1898, p. 411.

A CONTRIBUTION TO THE PATHOLOGY OF VASCULAR GROWTHS INTO THE VITREOUS.

By WILBUR B. MARPLE, M.D.,
New York City.

About two years ago the writer had the opportunity of examining ophthalmoscopically and subsequently microscopically one of those rare cases showing the development of blood vessels in an otherwise normal vitreous. The case presented so many uncommon and interesting features that I make no apology for reporting it in extenso.

The patient was a lady in good health, about 50 years of age, whom I had examined six years previously, at which time both eyes were normal, vision also normal, and simple reading glasses for presbyopia were given (plus 2D. s.). In February, 1899, the patient presented herself again, saying that about three months previously she had first noticed that the sight of the left eye was impaired, and the vision of this eye was found to be 20/70; with plus 1D. s. it was 20/40 plus. With plus 3D. s. she could read No. 8 Jaeger at 12 inches. Her right eye had vision of 20/20 plus, and with plus 2½D. s. she could read No. 1 Jæger at 12 to 16 inches. Careful examination ophthalmoscopically and otherwise showed the right eye to be in all respects normal. The external appearance of the left eye was likewise quite normal, and the ophthalmoscope revealed an interior which was everywhere normal, except in the region of the disc which could not be clearly made out in the indirect method. In the direct method and with no lens back of the aperture no details of the nasal half



Fig 1

Direct image seen with + 12. D.

e disc could be made out, as this region was evidently so far
ont of the rest of the fundus. But with a plus 12D. spherical
back of the aperture, a remarkable ophthalmoscopic picture
seen, and one which the writer had never before observed.
autifully interlacing system of blood vessels could be made
coming forward into the vitreous from the upper, lower, and
borders of the disc, while the temporal border was free and
rently normal. The vascular network reminded the writer
much of the system of vessels which he had often studied
e embryo of the chick, and the accompanying sketch (Fig.
ade at the time will give one something of an idea of its
arance and size. The outline of this growth was sharply
ed, and the vessels came directly from the disc, as in a
ar case described by Harlan of Philadelphia. There was
ther abnormality of the rest of the fundus, and the media
absolutely transparent. There was no cardiac disease, not
ce of albumen or sugar, and the urine was otherwise normal
pt for one or two hyaline casts to the slide after centrifuge.
physician reported that there might possibly be some
io-capillary fibrosis. She was in good physical condition.
was urged to return in three or four days so that the eye
l be watched further, but she was unexpectedly called from
ity shortly afterwards, and it was two months before I saw
gain. At the end of April, 1899, she visited me once more,
rting that the sight of her left eye had gradually failed,
markedly during the past three weeks; she can now see
ements of the hand over a small area at the extreme nasal
of her field, elsewhere there is no perception of light. By
ue illumination and with the pupil dilated a greyish mass
blood vessels running over it was seen back of the lens
tly like a detached retina, and there was no red reflex except
e extreme periphery above, and to the temporal side. The
on was normal. The patient was told that in all probability
was an intraocular growth, and enucleation was advised.
patient preferred to see a certain other oculist in the city
re deciding the matter of enucleation, and, accordingly, went

ERRATUM. — In fifth line from bottom, page 255, for *tem-* read *nasal.*

with a note from the writer to a well-known colleague of large experience, to whom a full history of the case was given, with a drawing of the disc made by the writer on the occasion of her first visit two months previously. After a careful examination, similar advice as to enucleation was given by this gentleman, and on the following day the eye was removed and placed in formalin solution.

Before leaving the clinical side of the case, the writer desires to say frankly that at the time of the removal of the eye he felt tolerably sure that he had to do with an intraocular growth, probably malignant, which opinion was likewise shared by the consultant. While the appearance of the patient's fundus on the occasion of her first visit two months before was merely that of a benign development of blood vessels in the vitreous, still the writer was entirely ignorant as to the changes which had taken place in the interim. It is quite possible for a malignant growth, for example, a sarcoma, to develop in an eye in which such a benign vascular growth previously existed, and the rapidly progressive and complete loss of sight in our patient was exceedingly suggestive of such a state of things. While the vision is not infrequently lost in retinitis proliferans, such loss is usually either very slow, coming on only after many months or years, or else is quite sudden, and the result of a large intraocular hemorrhage which can oftentimes be made out by oblique illumination. In our patient, however, there was no history of any sudden loss of sight, but merely one of rather rapidly progressive blindness, and the interior presented an appearance surprisingly like a detached retina, with no suggestion whatever of any connective tissue band or hemorrhages which are usually seen in retinitis proliferans. That it is possible for such a vascular membrane to form in such a case and resemble so very closely a detached retina is a point well worth remembering in cases of suspected intraocular growth.

Taking everything into consideration, therefore, neither the writer nor the consultant cared to assume the responsibility of leaving such a blind eye unmolested. Had the patient been

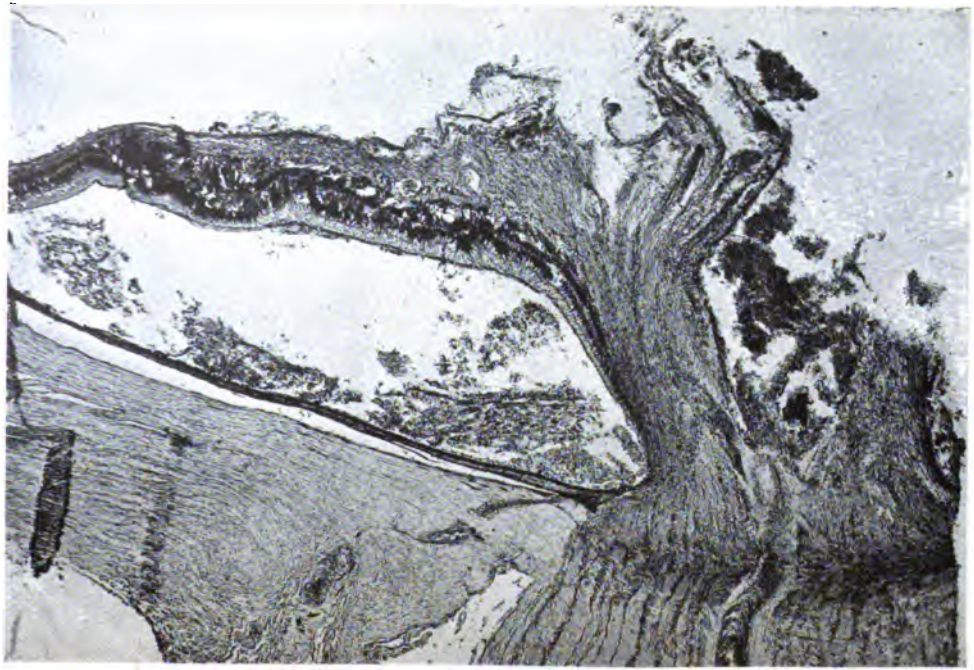

FIG. 2. Micro-photographs (×.85) through optic nerve entrance. Shows changes in retina near the disc; also the passing of the nerve fibers in wavy lines forwards from the papilla into the vitreous, with the central crater-shaped depression filled with blood corpuscles; also separation between retina and choroid near the disc, the space partly filled with exudation.

er continued observation during the two months which sed between her first and second visits it is needless to say a different course would have been pursued.

Whether or not the writer might have been able to discover real nature of the apparently detached retina, if he had made reful examination with a strong magnifying glass, it is im- ible to say. The fine translucent fibrillæ coming forward the vascular membrane might in this manner have been overed, certainly in a similar case he should not fail to avail self of this possible diagnostic aid.

Macroscopical Examination. The globe was bisected into a l and a temporal half; the latter was mounted in glycerine , the former was divided into an upper and a lower half (one ding all the nerve) and sections cut, stained in hæmotoxylin eosin and mounted.

The antero-posterior diameter of the globe was 23 mm., as also the equatorial diameter. The external appearance of eye is normal. There are some apparently recent clots of d in the vitreous chamber, especially in its equatorial and rior part. There is no evident abnormality of the cornea, a, iris, or ciliary body. The choroid is very thin, and the a is more opaque than normal, and does not appear to be ched. Throughout the vitreous there is much connective e which nowhere appears attached to the retina, except at the lla and in the region of the ora serrata. Viewed in a good and with a lens there is seen to be posteriorly a non- ular mass of connective tissue and a vascular membrane in t of this, the latter separating anteriorly about 4 mm. back he lens, and radiating in all directions towards the ora ata. From this vascular membrane numerous delicate and slucent fibrillæ pass forwards and laterally, and appear to h and envelop the lens. Microscopically we find, however, they do not reach the lens, but are attached to the retina at ora serrata.

Microscopical Examination. The cornea is normal, as is also sclera. Adherent to the posterior wall of the cornea is a

fibrinous homogeneous exudation reaching about half way to the anterior surface of the iris. The latter as well as the ciliary body is normal, and the iris angle is not closed.

Choroid. This membrane is very much reduced in thickness, being apparently made up of pigmented connective tissue in which very few vessels can be seen. There are apparently no hemorrhages in the choroid.

Optic Nerve. The nerve back of the lamina cribrosa, and more so in front of the latter, shows some round-cell infiltration, but there is evidently no inflammatory process nor swelling of this structure. On section, the calibre of the artery is much diminished by a fibrous thickening of the muscularis and adventitia. It will be remembered that a possible diagnosis of arterio-capillary fibrosis had been made by her family physician; otherwise the nerve section was normal.

Papilla. The most interesting features were found here. The optic nerve fibres, instead of turning laterally into the retina, proceeded directly forwards in undulating lines into the vitreous (Fig. 2). This is especially noticeable at either side of the papilla, while in the center the fibres do not advance so far. A crater-shaped depression is thus formed in the middle of the papilla, which is more or less filled with red blood corpuscles. As the nerve fibres of the papilla advance into the vitreous they separate into fibrillæ, among which numerous small blood vessels develop, many of which are here met with, some filled with red blood cells. These vessels are in direct communication with those of the papilla, and in one section the central artery can be followed directly forwards two millimetres. As the sections come towards the side of the papilla more numerous blood vessels are met with and the space between the nerve fibres is filled with blood cells. Practically the nerve fibres of the papilla alone advance in this manner into the vitreous, for the membrana limitans interna over the adjacent retina is undisturbed except to the extent that it has been dragged somewhat forward by the advancing papillary fibres. Uninterrupted strands of nerve fibres containing blood vessels can be followed forward fully

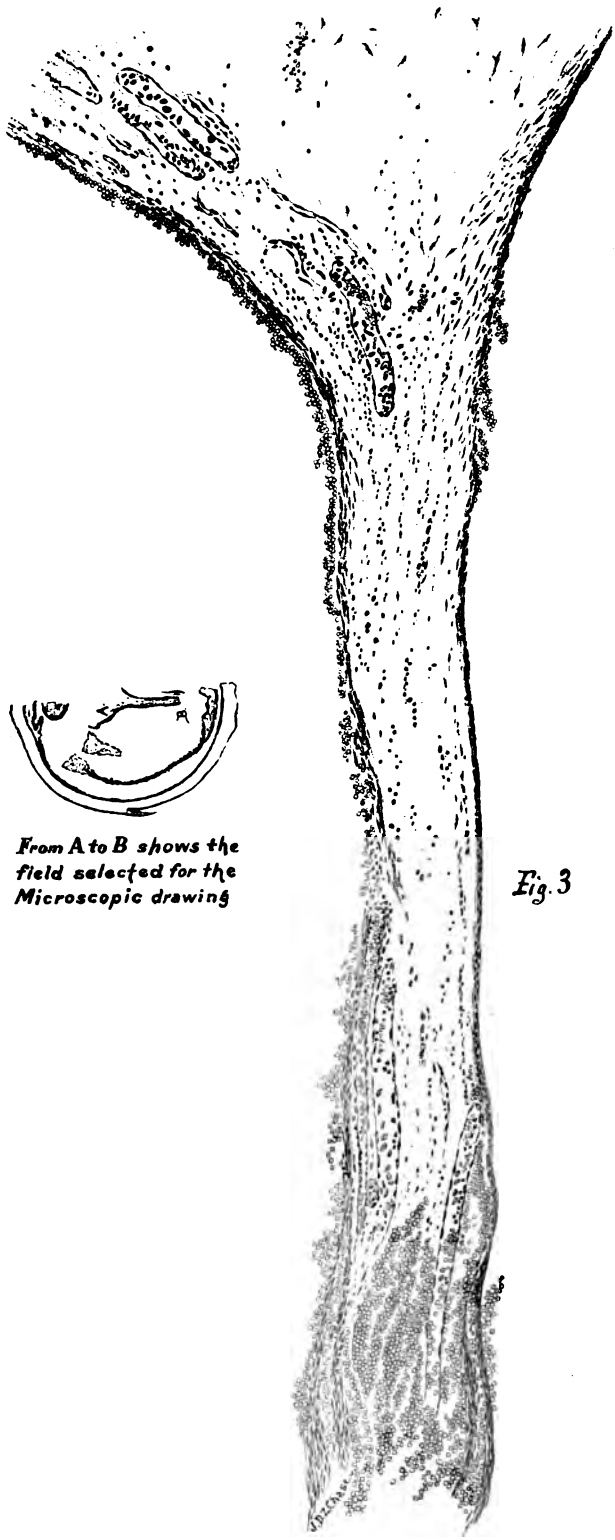

From A to B shows the field selected for the Microscopic drawing

Fig. 3

e mm. Further anteriorly there is a central stalk of new-
ıed and thin walled vessels supported in a stroma of most
ıate embryonic connective tissue. This advances as a tube-
vascular structure for about four mm. (Fig. 3), where at the
ınce of four mm. back of the lens this vascular membrane be-
to open out, funnel-like, in all directions. Here longitudinal
transverse sections of the finest capillaries are seen usually
ıging from a mass of red blood corpuscles or fibrin, and the
ıod of formation of the connective tissue can be seen. Here
there on the vascular membrane is a little round elevation
a bud, probably a fold in the vascular membrane, over the
ıce of which cross sections of numerous thin-walled vessels
met with. Between these vessels most delicate connective
e fibrillæ shoot out, forming a mass like a rosette, in which
erous formative cells of various shapes are seen; where no
ike prominences are seen the fibrillæ proceed from the fine
laries everywhere to be found (Fig. 4). Bands of this new-
ıed tissue proceed laterally and meet the retina at the ora
ıta, to which, for a distance of two mm., they are firmly ad-
nt; the contraction of these bands has apparently pulled
etina away from its attachment here, for a distance of about
e mm. (Fig. 5). At this point alone is the membrana limi-
interna disturbed and prolongations of Müller's support-
fibres can be seen intimately blended for a distance of less
one mm. with the connective tissue bands adherent here
ıe retina. For a distance of two and one-half mm. back of
point the retina is three times its normal thickness, and here
e are large spaces in the outer and inner reticular and in the
r nuclear layers, which are filled with red blood corpuscles.
e the retina is bent at a right angle, either an artefact or the
ct of traction, possibly of both, and its inner and outer sur-
is surrounded by red blood cells. For a short distance
) and one-half to three mm.) from the papilla the retina shows
ked changes (see Fig. 2). Its anterior layers (that is, the
re fibre and ganglion and inner reticular layers) are very
h thinner than normal. The outer and inner nuclear and to

a less extent the layer of rods and cones show many spaces, due probably to serous exudation; many of these spaces in the outer and inner nuclear layers are filled with red blood corpuscles (retinal hemorrhages). In some places where the distension of the two nuclear layers by these exudations and hemorrhages is greatest, much the largest part of the thickness of the retina is formed by these two layers. These changes are limited to that part of the retina close to the optic nerve, that is, two and one-half to three mm. from the latter. Beyond this the principal change is that the retina is much thinner than normal, due to its fibrous condensation; close to the disc it is separated from the choroid at least one or two mm. and this space is partly filled with a homogeneous exudate. This separation may be partly an artefact.

Literature. Cases of any kind in which the ophthalmoscope shows vessels running forwards into the vitreous are among the rarest to be met with. They may be classed in general as physiological or pathological. Among the former are those cases not so very infrequent in the literature (a), where there is a persistent hyaloid artery running through the vitreous, or other persistent foetal vitreous vessels, Kölliker's Vasa Hyaloidea. These are all congenital anomalies of the retinal vessels and do not concern us in our present investigations.

Among the pathological cases of vascular new formation in the vitreous, this is met with as Coccius (b) wrote as long ago as 1859: "Either as the new formation of vessels which are seen on the surface of white new-formed connective tissue masses in the vitreous or as that kind which is formed in transparent vitreous." This last condition alone is the one in which we are interested, viz.: the formation of vessels in an otherwise clear vitreous. In 1867, Mauthner (c) wrote: "A condition entirely different and of a much more remarkable character is that in which from the retinal vessels numerous newly-formed branches proceed which sprout into a relatively healthy vitreous. Up to the present (1867) there is only one such case in the literature." In 1876 Schweigger (d), referring to the formation of vessels in

FIG. 4. Micro-photograph (×.85). Section 4 mm. back of lens, and a little to one side of the central "tubular vascular structure" coming from disc; shows the development of the fine capillaries from the red blood cells (under the latter is a mass of fibrin), and the formation of the connective tissue bundles (fine wavy lines) from the capillaries. Numerous formative cells are present. These connective tissue

treous, said that at that time there were on record only bservations of this kind, that of Coccius and that of Jaeger. ee, therefore, how extremely rare is the condition. Care- arch through the literature by the writer has discovered llowing cases reported:

Coccius (b), in 1859. His case was as follows: Female, , seen in 1854. A number of vessels could be seen in the us, especially of the right eye, though to a certain extent n the left, proceeding from the vicinity of the optic nerve, orders of which were quite blurred. (A month previous had been suddenly a smoky haze in both eyes, which in- ed so that in four hours the patient had to be led.) The st vessel reached to the middle of the vitreous and ended ong white thread which moved up and down with the move- s of the eye. The retinal veins were engorged and in places completely covered with opaque tissue and the us was fluid and filled with fine punctate opacities. After weeks of antiphlogistic treatment, the latter cleared up. e hemorrhages were absorbed and the new vessels were to be connected partly with venous and partly with arte- retinal vessels. Vascularity of the retina extraordinary. n the eye moved, the ends of some vessels were seen to be e vitreous, which, when the eye was at rest, seemed to be e retina. When patient was discharged she could see to bout.

. Mauthner and Jaeger (c), 1867. Male, æt. 27. Left peculiar form of retinitis with considerable opacity of the a; after this had cleared up it was seen that from the papil- vessels other vessels penetrated into the entirely transparent ous at a sharp angle, some with a single loop, others with le loop, others forming a convolution like an injected Mal- ian corpuscle of the kidney and returning to the papillary els. While examining the patient on one occasion, Mauth- observed the development of a vascular branch; its com- ents stretched forwards like the fingers of the hand. The ent was treated by rigorous diet and finally by inunctions.

In four months all the vessels in the vitreous had disappeared. The vitreous had almost entirely cleared and the patient read Hebrew letters No. 5.

3. 1881. Charnley and Fox (e) report three cases: (1) O.D., girl, æt. 14; few small tortuous vessels below the disc, seen with plus 5D., vision 20/50, vitreous hazy, under potassium iodide improved. (2) girl, æt. 19; some keratitis, media hazy, spiral vessel coming forwards in the vitreous below and outwards. Several smaller vessels springing from the center of the disc suspended in the vitreous, forming at the anterior extremities a close spiral coil, then retracing their course to the disc. The patient was under mercurial treatment for one year, when the vessels had disappeared. (3) woman, æt. 51; no specific history; had had clots in the vitreous eight months previously, which had cleared up in nine months under tonics; then examination of the right eye showed the vitreous slightly hazy; below the disc is a small spot of connective tissue on the retina from which a bunch of vessels extend upwards and forwards into the vitreous like those in Jaeger's case. There were clots in the left vitreous; no albumen in the urine, no cardiac murmur. Vision at first improved to 20/30, two months later the vitreous was again hazy and the vision less than 20/200.

4. 1881, Carreras (Arago) of Barcelona (f); servant girl, æt. 23; O. D. multiple chorio-retinitis circumscripta both sides with some retinal hemorrhages in the equatorial region. From the right papilla delicate vessels proceed, dividing and subdividing into a finger-shaped vascular network ending in loops one mm. in front of the retina, which move up and down with the movements of the eye; media clear. Outcome not stated. Vision Sn. No. 6 at eight inches.

5. 1886, Hutchinson, J. Jr. (g); relapsing optic neuritis with development of new vessels in front of the papilla. (1) Male, æt. 28; seen June 4, 1884; vigorous physique, evident remains of optic neuritis (syphilitic?) in both eyes. In front of the right optic disc, covering a considerable part of its outer half, was a patch of small new vessels surrounded by lymph and project-

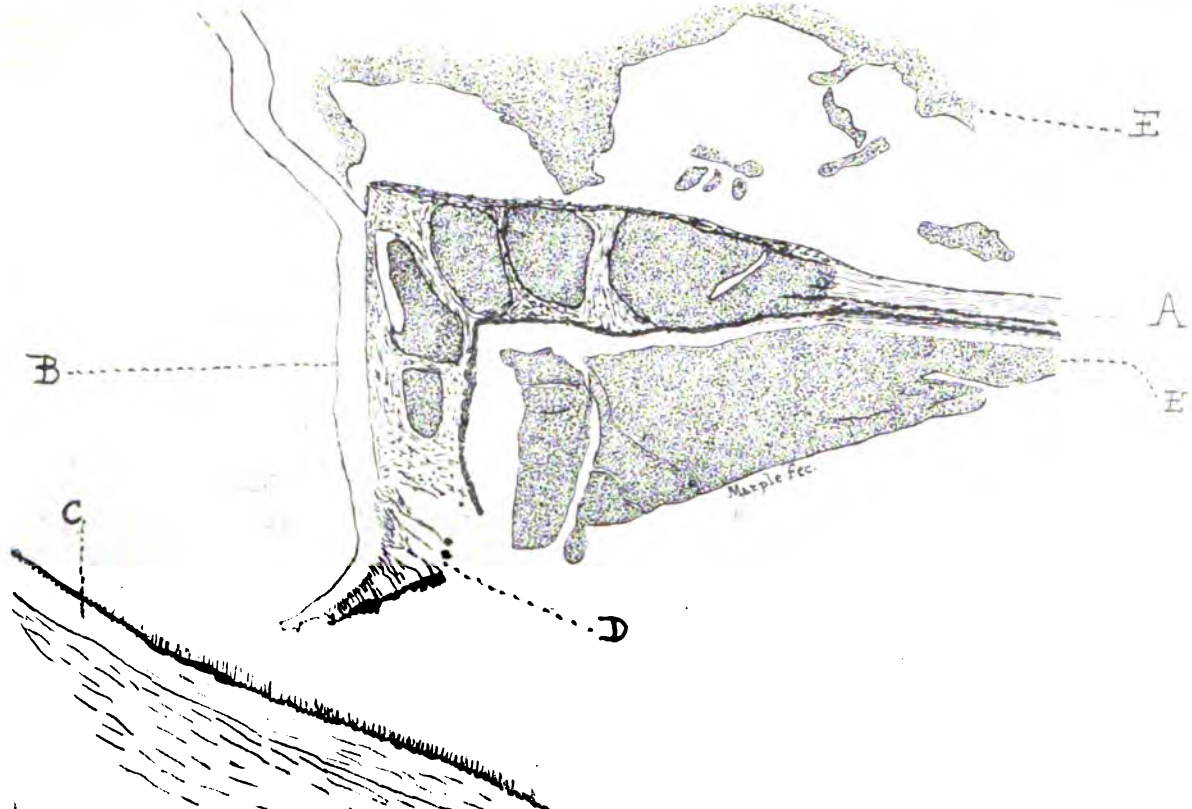
E
A
B
F
C
D
Marple fec.

to the vitreous; seen with plus 6D. In the left eye the ion was less marked and ultimately disappeared; no opaci- f the vitreous. The lymph disappeared and then the coil ssels like a corkscrew was seen coming from the arteria lis (which the patient could see like the tendrils of a vine). atient was under observation till July, 1886; under specific ent all the lymph disappeared from the disc and only a coil of vessels remained, which may disappear or be left white cord. He had several relapses of neuritis. When en, vision of the right eye was 20/40. (2) Male, æt. 33; contracted syphilis in 1884, no treatment; the right eye later the left; October, 1885, when first seen, the disc ns were blurred, the papillæ were swollen, a crescentic of vascular lymph placed nearly vertically over part of the n each eye to the outer side; narrow field; had phthisis; g the few weeks he was under specific treatment there was ange.

1887, Theobald (h): Woman; O. D. æt. 52; had recur- etinal hemorrhages near the disc. (Thrombosis of one of perior branches of the central retinal veins?) Extravasa- f blood into the vitreous, then there was an appearance of a h nebulous floating opacity in front of the disc. A month this had increased in size, nearly hiding the optic nerve, onsisted simply of a mass of small blood vessels held to- r and supported by semi-opaque tissue which presented ky appearance in contrast with the surrounding vitreous. s thought by Theobald to be an effort of nature to clear the débris of the repeated hemorrhages and to repair the ge which they had caused. In a recent communication Dr. Theobald he reports the eye as going from bad to , the media became cloudy, the retina apparently detached; there was a sluggish iritis and the lens became cataractous. 91 apoplexy supervened, followed by right-sided paralysis mpairment of speech. The right eye became quiet, though . Although she had at one time retinal hemorrhages in

the left eye, these disappeared and she retained good vision i this eye up to the time of her death in 1900.

7. 1887 (i), Carmalt, in the discussion of Theobald's cas reported a similar one, which he first saw in 1877; the patien a man, had vitreous hemorrhages first in the left then in the rig eye; there was a congeries of vessels, distinctly defined loo twined among each other, running from the retina nearly to t lens. The patient had attacks of hemorrhage into the vitreo every few months. In the same discussion (of Theobald's cas Wadsworth, of Boston, stated that in a case of recurrent hemo rhage partly retinal, but largely into the vitreous, he had se vessels develop in the latter; his patient was a man æt. 29 whom the vessels were visible seven years after they were fi discovered; some nearly transparent membranes in the vitreo contained vessels, some of which could be traced back to t retinal vessels; the other eye had a little peri-vasculitis whi disappeared; vision normal. When last seen there had been recurrence of hemorrhages for a year or so, and there we still some vessels in the vitreous, but not so many as previous Physical examination negative.

8. Nettleship (j), 1888; diabetic patient; male, æt. 48; S. blind from secondary glaucoma; in this eye there were se eral much enlarged vessels in the iris; O. D. Retinitis hemo rhagica. The retina œdematous and hazy; several spots of re nitis diabetica; retinal veins distended; close to the fovea the were two or three vessels of medium size which appeared in t retina, but could not be followed to the disc. (From the ch roid?) The largest of them followed upwards and outwar was found to divide into a network of minute vessels projecti forwards into the vitreous in the form of fine loops. The mo prominent ones are seen with plus 6D. On a few of the loo are appearances of small swellings, perhaps capillary aneurism R. V. sees very large objects. The patient was under observ tion from September to October, 1887.

9. Harlan (k), 1889; extensive vascular growth in the vitr ous; female, æt. 50; O. D. Fundus slightly hazy, several d

wish-white spots about the macula, the remains of old hem-
ages, but no recent extravasation. Vitreous quite trans-
nt and free from shreds; the disc obscured by a congeries
ntorted vessels, a beautiful vascular network forming a deli-
veil-like membrane stretching forwards and outwards at an
e of about 45°. The anterior margins were sharply defined
could be seen with plus 4D. The vessels which, by rapid
ivision and inosculation, formed this network came directly
the disc and seemed to have no connection with the retinal
els, which could be readily seen through the veil in their nor-
positions. There was nothing like a stroma. Not even an
ity, nothing but vessels, which offered but little obstruction
view of the parts beneath them. In the left eye there were
inosculating vessels stretching forward into the vitreous
the disc, but not nearly so numerous as in the right. The
ous was slightly nebulous; there were a few small uveal
s on the lens and the remains of a hemorrhage at the macula.
urine contained a trace of albumen, but no casts. There
subsequently several large retinal hemorrhages, but no dis-
ance of the vitreous. The patient was under observation
November, 1887, to July, 1889. When last seen there were
resh hemorrhages, and in the vascular membrane most of
smaller vessels had disappeared and the great part of those
aining seemed empty and reduced to dark lines, scarcely
gnizable as vessels. Dr. Harlan very kindly reported to the
er that he had recently seen his patient, June 3, 1901. Her
ition was as follows: The ophthalmoscope revealed entire
nce of any vascular growths in either eye. The left eye
s a lead-colored streak extending from the disc margin
ards and in a nasal direction, four disc diameters; flat and
ng a calibre the size of a large retinal artery or vein lying
the retina; probably the remains of a membrane. No
orrhages to be found. R. V. with correction, 20/30 plus.
. 20/40 with correction; about as good in either eye as she
had.

10. Inouye T. (l). Male, æt. 38; O. D. hemorrhages in the retina; most in the superficial layers, some in the deeper layers. Vitreous somewhat hazy. O. S. vitreous hazy; clear after mercurials and iodides. Then there was seen to be a retinal hemorrhage near the disc. This gradually became opaque, then took the form of lines. The opacity faded and then the formation of new vessels could be observed arising from the external border of the lamina cribrosa; small branches coming forward into the vitreous, the remnants of the hemorrhage lying in the central part of the new vessels. There were spiral loops returning to the retinal trunks which reached one mm. in front of the retina. The vessels disappeared after three weeks. Recurrent retinal hemorrhages. Visual power good. Sn. No. 10 at twenty feet.

11. de Schweinitz (m), 1898. Left eye; male; doubtful specific history; æt. 26. Vision corrected 6/5. Springing from the disc is a greenish white mass of the type usually seen in proliferating retinitis carrying a veil of anastomosing blood vessels, terminating in several clump-like dark bodies, one extending forward into the vitreous and seen with plus 7D.; several other similar patches varying in prominence. Vitreous clear. In immediate connection with one of the patches is an area of retinochoroiditis, and some of the blood vessels can be traced directly to this patch. No direct connection with the fundus could be seen in the other masses. The treatment was iodide of potassium and bichloride of mercury, but the patient was only under observation a few weeks.

12. Lawson, 1899 (n); vessels in the vitreous in a case of diabetes; patient male; æt. 54; had diabetes three and a half years. There is a dense haze in the vitreous, preventing a view of the fundus, probably diabetic chorio-retinitis with exudation in the vitreous. Ten weeks later the left vitreous much the same as it is now. General haze from exudation, which has undergone connective tissue formation, the latter appearing as feathery tufts issuing from a central stalk and approaching in places the back of the lens. These tufts are richly permeated with blood vessels; the patient was under observation for three

one-half months. Vision of the left eye began to fail five ths ago and was reduced to counting fingers at six feet.

efore analyzing the preceding cases a rare cause of the ation of vessels in the vitreous should be mentioned. er (o) saw such vascular development in a case of choroidal ss (probably a suppurating tubercle which penetrated the ous body). Subsequent anatomical examination showed they were connected with the retinal vessels. The same rver reports (l. c., p. 106) a case in which a vascularized mor- growth developed in the vitreous.

n studying the etiology of these various cases we will con- , first the immediate cause or local disease underlying the ition, and secondly the remoter cause in the shape of any sys- condition where any such can be demonstrated, what thner would call "die ætiologische momente der ersten zweiten Kategorie."

he first cause of a local nature is optic neuritis. In the cases alone of Hutchinson the vessels developed from the ation of lymph on the disc attending inflammation of the nerve. In one case the lymph disappeared and the coil of ls could then be seen coming from the arteria centralis on disc. As Hutchinson observed, it is very probable that would be more frequently met with if these patients did generally receive early treatment for their neuritis. One utchinson's cases had contracted syphilis and subsequently had failing vision in each eye for nearly a year before re- ng any treatment.

f the remaining (14) cases it is stated that in ten there was itis or chorio-retinitis with or without hemorrhages. In the vitreous was hazy, from which it is safe to infer that itis or vitreous hemorrhages were present in these two ; so that there remain only two cases, that of Harlan and ne of the writer, in which at the time of the first examina- there was apparently neither retinitis or hemorrhages pres- and these two cases in many other respects were the most esting of all, presenting as they did nothing except a con-

geries of blood vessels springing from the optic nerve into the vitreous. While at the time of the first examination in Harlan's case there was no evidence of any retinal hemorrhages, there *were* several dull yellowish white spots about the macula, the remains of old hemorrhages, and subsequently there were several large retinal extravasations, one just below the disc. So far as the writer's case is concerned, it is only necessary to recall the conditions found macroscopically and microscopically in order to appreciate the fact that had our patient been under continuous observation retinitis with retinal and vitreous hemorrhages would have been observed. We see, therefore, that in all fourteen cases retinitis with or without retinal extravasations was present and the changes incident to this condition must be regarded as the direct local causative process. From the fact that retinitis is so universally present, from the fact that in some cases (for example, Inouye's) there was originally vascular formation and whitish exudate, which latter disappeared, leaving only the congeries of vessels, and from the further fact that in some cases (for example, that of the writer) there was at first only a congeries of vessels, while subsequently extensive membranes developed, it is evident that we are dealing with one and the same process in all these cases, whatever combination of vessels or membranes, or both, that we encounter, and this process is retinitis proliferans. The picture which is presented will vary, therefore, at different times, the same case showing at one time merely the growth of vessels in the vitreous, at another time these with possibly retinal and vitreous hemorrhages, and again all of these with membranes may be discovered. It is matter of congratulation, therefore, to the writer that his case did present originally nothing but a congeries of vessels growing from the optic nerve into the vitreous, for this was just the picture if there was any among this class of cases, whose pathology was obscure. But the examination of this eye settles positively the identity of the process with that of retinitis proliferans, for both macroscopically and microscopically the specimen presented a typical picture of this condition. What has long been known

e true in regard to the formation of the membranes (well
d by Weeks (p)) is equally true in regard to the formation
ıe vessels alone in retinitis proliferans, viz.: "A fibrinous
ation or hemorrhage into the vitreous must first occur,"
' it is necessary first that a coagulum in the vitreous either
brin alone or of fibrin and blood corpuscles should be
ed." The formation of a bundle of vessels in just such a
ıer from a coagulum of fibrin and blood corpuscles was ob-
d by Theobald and Inouye ophthalmoscopically (l. c.), and
ıe writer's specimen wherever the connective tissue with
ls is met with there side by side with these and in imme-
proximity to the same could be found always the coagulum
rin and near by a mass or layer of blood corpuscles. It is
ıecessary to go further into the well-known changes char-
istic of retinitis proliferans except to observe that all of
changes can be beautifully seen in the various sections
the writer's specimens.

word or two as to the first step in the formation of the
ılar network from the disc in the present case will not be
s. It will be remembered that there was a condition of
itis with hemorrhages in the immediate vicinity of the disc.
fact as well as the observation by Harlan and Theobald (in
similar cases) of large retinal extravasations near the disc
es it probable that the original hemorrhage in the writer's
was from the vessels of the retina near the papilla, and not
the latter. Furthermore, from the fact that the membrana
ans interna is undisturbed over the retina but absent over
apilla, it would seem likely that the hemorrhage made its
for a short distance under this membrana to the region in
of the disc, where it broke through into the vitreous and
ed here the proliferation of vessels. Recurring rupture of
new vessels gave rise to recurring hemorrhages on the
ce of which the vessels and membranes continued to pro-
te, finally passing laterally along the anterior surface of
nass of fibrin and blood corpuscles to the region of the ora
ta where Müller's fibres pass directly into the recently

formed membrane. Back of this point for a short distance the retina is again the seat of large extravasations, principally in the outer and inner nuclear layers. It is impossible to say whether the detachment of the retina at the ora serrata is an artefact or the effect of traction from the membrane. The writer is disposed to think that the latter is partly the cause, the effects being exaggerated by the reagents employed.

As to the remoter causes, "die aetiologische momente der zweiten Kategorie," syphilis was present in eight cases, diabetes in two, and in the remaining six there was either a negative history or nothing was stated as to it. In other words, specific disease was present in fifty per cent. of the cases and diabetes in twelve per cent.

In five cases the right eye was affected, in four the left, while in four both were involved. In three cases, however, while only one eye showed the development of vessels, the second eye gave evidence of a similar degenerative process. Thus in almost half of the cases it was evidently not a local but a general condition. This and also its frequent occurrence in specific disease are further points of resemblance establishing its identity with retinitis proliferans.

Age. The youngest patient was 14, the oldest 54. It occurred five times each in the decades between 20 and 30 and 50 and 60, three times between 30 and 40, twice between 10 and 20, and once between 40 and 50. It occurred in nine males and eight females.

As to the amount of visual disturbance this will vary according to the location and size of the vascular growth. Where this latter consists merely of one or two small groups of vessels in the disc, or in some peripheral part of the retina, vision may be little if at all affected. Where, however, the growth is large, as in the cases of Coccius, Theobald, Harlan, and Carmalt, the sight may be very seriously impaired. In the writer's case the patient became practically blind within a very short time.

Prognosis. Where syphilis is present the prognosis is often

bad, for the new-formed vessels may entirely disappear, es-
ally if these are small, under specific treatment. In five cases
treatment was followed by a disappearance of the vessels,
in three by marked improvement, while in five nothing is
ed as to the outcome. In Dr. Harlan's remarkable case the
els have all disappeared with resulting unimpaired vision,
gh whether under specific treatment or not the writer can-
say. Where there is no specific history the prognosis is not
ood. Dr. Theobald's case eventuated in total blindness and
generated eye, and a similar outcome would in all probability
been the result in the writer's case if enucleation had not
performed. In the first place it is difficult to conceive of
possibility of the absorption of such a mass of connective
ie as was here present in the vitreous. Furthermore, the
d supply of the whole retina had been seriously diminished
veeks, inasmuch as it had been largely diverted into the mass
essels and connective tissue in the vitreous, and the marked
ning of the retina was an evidence as well as a result of
diminished blood supply. The effect of such a condition
ct must finally be similar to that attending embolism of the
ral artery of the retina. It is evident, therefore, that when
scular growth of considerable size springs directly from the
ral artery on the disc, as in the writer's case, vision will be
much more seriously and permanently impaired than in
e cases affecting a single isolated retinal vessel.

Treatment. Little need be said as to this, for it will depend
whether a general systemic cause is found for the condition
ot. If such cause is found, for example, syphilis or diabetes,
tment should be directed to this. If such cause is not found,
treatment can only be carried out on general principles,
gh tonics and the iodides are of the greatest service.

REFERENCES.

a. Centralbl. für Prakt Augenh., 1885, p. 14; also Wien.
l. Woch., 1896, p. 393.

b. Coccius, "Ueber Glaucoma, Entzundung, etc." Leipzig, p. 47.

c. Mauthner, Lehrbuch der Ophthalmoscopie, 1867, p. 327. Jaeger Ophthl. Hand Atlas, p. 117, plate 15, Fig. 72.

d. Schweiger, Handbuch, p. 398.

e. Royal London Oph. Hosp. Reports, Vol. 10, p. 193.

f. Centralb. für Prakt, Augenh., 1881, February, p. 89.

g. Royal London Oph. Hosp. Reports, Vol. 11, p. 191, July, 1886.

h. Trans. Am. Oph. Soc'y, Vol. 4, p. 542.

i. Trans. Am. Oph. Soc'y, Vol. 4, p. 545.

j. Trans. Oph. Soc. United Kingdom, Vol. 8, p. 159.

k. Trans. Am. Oph. Soc., Vol. 5, p. 426.

l. Sei I Kwai, Tokio, XII, p. 161.

m. Ophthalmic Record, January, 1898, p. 1.

n. Trans. Oph. Soc. United Kingdom, Vol. 19, p. 288.

o. Bericht de Wiener Augenklinik, 1867, p. 114.

p. Trans. Am. Oph. Soc., Vol. 8, p. 178.

DISCUSSION.

DR. DE SCHWEINITZ. — It may be interesting to show in connection with this paper two water colors portraying similar lesions. One of the cases which I have already reported is an instance of disseminated retinitis proliferans, characterized by masses of fibrin carrying blood vessels scattered through the vitreous. There was an indefinite history of syphilis. The vision was absolutely normal, and so far as I know, continues to be so until the present time; I saw the case in 1897. The second case is that of an epileptic woman aged about thirty-five, probably syphilitic. As may be seen from the water color, an irregular mass of bluish-white tissue stretches forward into the vitreous from the region of the optic nerve, and over it pass several small cord-like structures, undoubtedly the remnants of blood vessels, but which no longer, as in the previous case, carry blood. The vision of this eye was also not far from normal and there has been no degeneration of either of the eyes.

DR. MITTENDORF. — In connection with this case of Dr. Marple's it might be of interest to mention a case which I showed

he New York Ophthalmological Society some fifteen or six-
n years ago. In that case we had a beautiful development
lood vessels in both eyes and the vision was very much im-
ed when I first saw it. Four or five years later all the blood
sels had completely disappeared and the vision was restored
ost to normal. The case was one of specific origin.

Dr. Risley. — I have had under observation for the past
nteen months an eye presenting many of the features of Dr.
rple's case. There was no history of syphilis, but a careful
od count showed a relative deficiency of the red corpuscles.
e young man was weak and unable to attend to his college
rk. When he came to me there was a hemorrhage in both eyes
nwards and outwards from the disc and the veins were ab-
mally large. There was the same congeries of new vessels
ning in the right eye in the vitreous at site of the hemor-
ges very much as described by Dr. Marple. The case went
to almost complete loss of vision in the right eye, while in
other the hemorrhage absorbed and eye slowly improved
er ascending doses of iodide to V = 6/IX. . The tension has
n practically normal, as in Dr. Marple's case, throughout
whole course of the disease. It seemed to me the cause of
se hemorrhages was probably to be found in the condition
he blood.

Dr. Wadsworth. — I have seen a number of these cases,
as a general thing have been unable to discover any cause.
re have been a few cases in which the history of syphilis
eared, but it answers as a cause for almost anything. The
t case I recall occurred some twenty-five years ago in a
n who had repeated hemorrhages into the vitreous and
nges (thickening) in the walls of the retinal vessels in both
s, coming on without any apparent exciting cause, and who
l large vascular membranes in each eye. He was examined
h the greatest care without discovering any disturbance in
general condition whatever. The last time I saw him, fifteen
twenty years after my first examination, he had been free from
hemorrhages for two or three years, and the membranes,
ich had been extensive and persistent in both eyes, had
atly diminished, while vision was much improved. In three
four cases in old people with symptoms of simple glaucoma,
leep excavation of the disc with scarcely any increase of ten-
n, I have seen congeries of similar vessels formed in and

about the cup without evidence of hemorrhage. It seems to me there are quite a variety of cases with production of these vascular membranes in the vitreous and we cannot attribute them all to any one thing.

DR. THOMSON. — I saw a case about a year ago which was interesting in regard to the etiology. The man had been blind in the left eye from a large hemorrhage into the vitreous for the past six months, and in the right eye, towards the periphery of the fundus, on the line of the superior temporal artery, was a large mass of organized lymph with vessels penetrating from it into the vitreous. There was no history of specific trouble in this case, and the only condition we could conceive to be the cause was that of hæmophilia, the man having been a bleeder for years. At the end of six or seven months' alterative treatment I again saw the patient. The vitreous in the left eye had not cleared in the slightest degree, and the right eye was practically the same as at the examination made six months previous.

DR. MARPLE. — I merely want to say that Dr. de Schweinitz's case is included in my paper, but I did not read that part of it. I would like to emphasize the extraordinary resemblance here to the picture we may have in detachment of the retina. In my case it was difficult, if not impossible, at first to make the distinction.

A CASE OF MELANOTIC GIANT-CELL SARCOMA OF THE LIMBUS ASSOCIATED WITH AN IMPLANTED SECONDARY GROWTH IN THE LOWER EYELID.

BY OLIVER F. WADSWORTH, M.D.,

AND

FREDERICK HERMAN VERHOEFF, M.D.,

BOSTON, MASS.

Sarcomata of the corneal limbus and sarcomata of the eyelids, even when occurring alone, are comparatively rare. We have been able to find the report of but a single case similar to the following one in which a sarcoma of the limbus was associated with a sarcoma of the eyelid in the same eye. It seems well, therefore, that this case should be put on record.

Mr. N. B., white, aged 82, was admitted to the Massachusetts aritable Eye and Ear Infirmary November 21, 1900. One ır previously the patient had noticed a small red patch on left eye, which ever since had continued to increase in size, l had taken on an especially rapid growth during the two or ee months previous to admission. It had gradually impaired sight of the eye to the ability to count fingers at nine feet. ere had been no pain or other inconvenience, except a slight ling of irritation.

On examination there was found a large, fleshy, tongue-like nor, 12 mm. × 11 mm., reddish grey in color, somewhat ngular in shape, with contracted base, which covered the bus at the lower and outer side of the cornea and spread r more than the lower and outer half of the latter. It was ndantly vascularized on all sides. The upper half of the nea was fairly clear. On account of the size of the tumor the could not be tightly approximated, and the lower lid was dis-ced somewhat downward. There was decided congestion and ckening of the whole lower conjunctiva, and on the lower directly opposite the corneal tumor, there was an oval vation about 10 mm. in its long, horizontal diameter, with newhat granular surface, which suggested a metastasis by nsplantation of the corneal growth. A small piece of the rneal tumor was excised for diagnosis, and on examination ved to be sarcomatous. Enucleation was then advised.

Under ether the globe was enucleated with the tumor intact. e thickened area in the lower lid was also removed. With exception of some exuberant granulations which sprang up m the wound in the lower lid, and which were removed later, ling was uneventful, and the patient was discharged on De-nber 19th.

Macroscopical Examination of the Enucleated Eye. Except for presence of the tumor the globe is apparently normal. The nor is soft in consistency, and resembles the head of a mush-om in shape. It has no stalk, but is attached at its periphery ectly to the globe. Its surface is smooth and shiny, dirty

brown in color, and is dotted over with a few comparatively large darker areas, evidently blood extravasations. On the surface a few small gray spots are also noticeable. The main body of the tumor measures 13 mm. in its longest horizontal diameter, 10 mm. in its vertical diameter, and at its highest point it is 4 mm. above the surface of the cornea. It has extended over the cornea to a point 7 mm. from the limbus, thus occupying more than half the corneal surface. On bisecting the tumor and globe after hardening in formalin, the cut surface of the former is found to be light in color, with here and there a few lighter and darker areas. There is an ill-defined lighter zone about 1 mm. wide running parallel with, and within a short distance of the base of the tumor. Red streaks, no doubt blood vessels, can be seen throughout the tumor, but they are largest and most noticeable at the corneal attachment 1½ mm. from the limbus. The conjunctiva is lifted up and reflected over the tumor in such a way as to render it impossible to determine the attachment of the latter when viewing it from in front, but on looking through the cornea from behind the attachment of the tumor does not seem to extend beyond the limbus. The tumor is so symmetrical that a good idea of its shape and position is given by the photograph of the sectioned eye.

Histological Examination. As already mentioned, the tumor was hardened in formalin. A median portion was then placed in Marchi's osmic acid fluid for eight days. The entire tumor was finally imbedded in celloidin and sections made through it at various levels. Sections were stained in alum hematoxylin and eosin, lithium carmine, Mallory's iron hematoxylin, Van Gieson's stain, and Weigert's fibrin stain. On microscopic examination the tumor is seen to be attached to the cornea, but not to the sclera. It is difficult to determine the exact position of the limbus, but, using the distance between the filtration angle and the ending of the subjunctival tissue on the opposite side as a guide, there is little question that the tumor also involves the limbus. The tumor, however, has its firmest hold in the true cornea a short distance from the limbus. At and beyond the

WADSWORTH. — Melano-sarcoma of limbus.

bus there are great numbers of plasma cells, and a less num- of lymphoid cells packed in the episcleral tissue. Above se cells there is a large amount of loose œdematous nnective tissue, much more than is normally present neath the conjunctiva. This œdematous tissue may dily be seen in the photograph as a darker triangular a with its apex at the limbus, and bounded above by the nor and below by the sclera. The still darker tissue to the ht is hemorrhagic subconjunctival tissue disarranged during enucleation of the eye. The bulbar conjunctiva is continued r the œdematous tissue, and then over the tumor. For quite istance from the main tumor the cells of the latter have grown ng under the conjunctiva. Mixed in with these cells there great numbers of lymphoid, plasma, and pus cells, which are o present beneath the conjunctiva elsewhere. Near the mar- of the tumor the epithelium of the conjunctiva changes its rmal character, becoming more distinctly squamous and send- projections downward, thus resembling true skin. On the nmit of the tumor, the epithelium is greatly infiltrated with s cells, and is so necrotic that its individual cells cannot be cognized. It finally becomes continuous with the corneal thelium.

For the most part the tumor is growing immediately upon wman's membrane. In many places, for instance, near the nbus, as already indicated, the membrane has disappeared, and e tumor cells are growing in the corneal lymph spaces. In ners, the membrane has simply been lifted up and the cells are owing under it, while still in others it has been partially torn ay and carried far out into the tumor. In some situations the nellæ of the cornea have been carried out into the tumor in a nilar manner. Some of the sections show the cornea pene- ated to one-third of its depth by the tumor cells. The tumor highly vascular. Most of the larger blood vessels reach the mor from the neighborhood of the limbus, but a number of irly large vessels have penetrated first into the cornea, and en into the tumor. Within the tumor there are many large

spaces containing a few red blood corpuscles, pus cells, and a small amount of fibrin, which, no doubt, represent the situations of blood extravasations. In different parts of the tumor there are little islands of epithelial cells, in all probability the remains of down growths of the surface epithelium separated off during the growth of the tumor. Van Gieson's stain shows a considerable amount of connective tissue running through the tumor. It arises from the blood vessels from which it radiates in strands.

The tumor cells vary in size and shape, but the majority are extremely large, and possess a number of nuclei. Many of them are identical in appearance with the giant cells of tuberculosis. The multinucleated cells are often 80 microns in diameter, while many of the cells with single nuclei reach a diameter of 60 microns. The giant cells frequently show as many as 8 nuclei, but they are characterized by the size rather than by the number of the latter. Some of the giant cells contains large vacuoles. The largest giant cells are collected around the spaces left by blood extravasations. Large spindle cells are also present in the tumor, and occasionally a cell is seen with a horseshoe shaped nucleus, which gives it the appearance of a greatly enlarged pus cell. Karyokinetic figures are frequently met with.

There is a considerable amount of yellowish brown pigment in the tumor, which does not give the reaction for iron with potassium ferri and ferro-cyanide followed by acid alcohol. It is usually in very fine granules, and is most commonly within cells. There is no special type of cell to which its presence is limited. Within the giant cells it is always in the finest granules. Under the high power it can be seen in almost any part of the tumor, but under the low power it does not seem to have such a general distribution, and is perhaps most noticeably collected near the cornea where the latter has been most deeply invaded. Compared to the melanotic sarcomata of the choroid, the tumor is only slightly pigmented. The portion of the tumor treated with Marchi's fluid shows fat present in the surface epithelium and in the epithelial islands included in the body of the tumor. Under

immersion, many of the tumor cells are also found to con-
ı fat droplets. The tumor is greatly infiltrated with pus cells,
l near the advancing margins there are a number of plasma
s and an occasional eosinophile. There are a greater num-
of eosinophiles in the subconjunctival tissue near the tumor.

Tumor of the Eyelid. The tumor after hardening in formalin
asures 9 mm. × 6 mm. on the surface, and has a depth of
ım. On microscopic examination the limits of the tumor
seen to be sharply defined, though it has no definite cap-
e. The surface of the tumor is covered by a continuation
he conjunctiva which in some places has the thickness of
y one cell. Both over the site of the tumor and elsewhere
subconjunctival tissue is greatly infiltrated with lymphoid
sma, and pus cells. Around the subconjunctival blood vessels
re are nodular collections composed entirely of lymphoid
s. The tumor, though similar to the tumor of the cornea,
iceably differs from it in several respects. While the cells are
remely large there is not the same tendency to form multinu-
ıted giant cells, and the nuclei of the latter are more apt to
ng themselves out in long rows rather than in circles. In the
ɔebral tumor, too, the cells in general have a greater tendency
ɔecome spindle shaped. An especially striking difference be-
en the two tumors is the presence of large masses of lym-
ɔid cells in the palpebral tumor. The latter is also diffusely in-
ated with lymphoid cells, while plasma cells are comparatively
equent. Another important difference is that the palpebral
ıor contains no pigment.

Diagnosis. Melanotic giant-cell sarcoma of the limbus.
ıco-sarcoma of the lower eyelid.

It is difficult to determine the exact relationship of the two
ıors to one another. They are sufficiently similar in struc-
e, however, to warrant the view that they are not entirely in-
ɔendent of each other. It is possible that one represents a
tastasis of the other by means of the lymphatics, but their
ative positions renders this improbable. It seems more likely
ıt the palpebral tumor was the result of the implantation of

tumor cells by the corneal tumor which was constantly rubbing against the lower eyelid. The relative positions of the two tumors was not such as to suggest that the implantation occurred in the opposite way, that is, from eyelid to cornea. The facts that the tumor of the limbus was first noticed, and that the palpebral tumor is much smaller than the other, are also against this latter assumption. Another objection to it is that the palpebral tumor is unpigmented. It is more reasonable to suppose that a pigmented growth should give rise to an unpigmented secondary growth than that the reverse should occur. The other differences between the tumors can perhaps be explained by the fact that one of them is growing upon a hard resistant surface, while the other is infiltrating a loose tissue. The presence of the enormous numbers of lymphoid cells in the palpebral tumor can be explained by the fact that lymphoid tissue is always very abundant in the lids.

There is no reason for thinking otherwise than that the corneal tumor started in the connective tissue of the limbus. It is certainly impossible to demonstrate that it took its origin from true corneal tissue.

The similar case already referred to was described by Szulislawski* in 1896. The patient was a man aged 55. The tumor of the limbus had been present on the eye for about one year, and had grown to the size of a hazel nut. It was dark gray to dark brown in color, and was diagnosed as a melanotic sarcoma, although it was not stated that a microscopical examination of the growth was made. The tumor was removed by the knife, followed by the galvano-cautery. Four months afterwards the patient noticed a thickening of his upper lid, and five months later he applied for treatment, presenting a tumor mass 23 mm. × 22 mm. in size, growing under the conjunctiva of the upper eyelid. This was extirpated, examined microscopically, and found to be a melanotic, small-cell sarcoma. It was thought possible that the tumor of the eyelid was present at the

*Szulislawski. Ueber das Auftreten multipler Neubildungen der Horhaut und Bindehaut. Centralblatt f. Augenheilkunde, 1896, p. 301.

e of the first operation, but was overlooked. Szulislawski arded it as most probably due to an implantation from the neal tumor. He thought that the rarity of sarcomata of the pebral conjunctiva, taken with the fact that the second tumor le its appearance shortly after the first tumor had been re-ved, was strong evidence against the two tumors being in-endent. His evidence, we think, would have been stronger this point if he could have compared the microscopical appear-es of the two tumors. He excluded metastasis by the blood sels by the fact that there were no other secondary growths. tastasis by the lymphatics was not regarded as probable be-se the researches of Waldeyer went to show that there was e if any communication between the lymphatics of the bulbar palpebral conjunctiva.

The subject of sarcomata of the eyelids was brought to the ntion of the society in 1894 by Wilmer, who collected thirty-published cases, by Veasy in 1899, who collected thirteen ad-onal cases, and by Friedenwald in 1900, who, including his n case, added six more cases to the list.

A case of sarcoma of the limbus was reported before the iety in 1898 by John Green and Ewing, and another case by B. St. John in the same year.

The subject was treated of in a general way by Noyes* in 79, but he did not draw very close distinctions between sarco-ta and epitheliomata. Strouse,† in 1897, including his own e, collected twenty-five published cases. From a study of se cases he reached the conclusion that " Radical procedures, ucleation, or exenteration are unjustifiable, except in those es in which the growth has attained extensive proportions, in which vision has been destroyed." He also concluded that tastases practically never occur, but that recurrences are fre-ent. It seems to us, however, hazardous to draw such far-ching conclusions from the reported cases, because a con-

* Noyes. Arch. of Oph., 1879, p. 145.
† Strouse. Arch. of Oph., 1897, p. 217.

siderable interval of time might elapse before metastases developed. That a melanotic sarcoma of the limbus, even when fairly small, can recur and produce fatal metastases after simple extirpation and cauterization is proven by a case reported by Fuchs.* In this case the tumor recurred several times after extirpation, and enucleation was finally performed, but the patient died about three years later from metastases in the internal organs.

DISCUSSION.

DR. HOLT.— This case reminds me of one I had last year. A young lady teacher came to see me. She had a great many pigmented spots over the body, but there was a little point on the lower lid which I advised her to have removed, because it looked like a commencing melanotic sarcoma. She was taken ill, and had scarlet fever about that time, and when she recovered the growth had increased in size to about 5 mm. in diameter. I removed it, and microscopic examination showed it to be a giant-cell melanotic sarcoma. I have removed several such tumors, but never have had them examined microscopically.

DR. DE SCHWEINITZ. — In this connection I would like to show specimens of two cases of sarcoma of the limbus without making a detailed report on them at the present time. One is a large sarcoma of the limbus with secondary deposits in the face and neck, all of which were removed, occurring in a woman of 38. The second case is one of pigmented spindle cell sarcoma, also of the limbus, and I have just removed the eye because of a recurrence. In both of these cases growths originated in a nævus.

DR. RISLEY.— I would like to ask, Mr. President, if it was your idea that the deposit on the lid was one of implantation from direct contact?

DR. WADSWORTH. — Yes, sir; and it was that which made the case so rare.

---

* Fuchs. Text-book of Ophthalmology (Trans. by Duane), 1898, p. 119.

TOLOGICAL DESCRIPTION OF AN EYEBALL WITH DROPSICAL DEGENERATION OF THE ROD AND CONE VISUAL CELLS OF THE RETINA WHICH CLINICALLY SIMULATED GLIOMA.

By G. E. DE SCHWEINITZ, A.M., M.D.,
AND
E. A. SHUMWAY, M.D.,
PHILADELPHIA, PENN.

The following case presents features, both clinical and patho-al, of sufficient interest to render its record worthy.

A boy aged two years was brought to one of us (Dr. de veinitz) on the 20th of January, 1900, by his physician, Dr. iam L. Estes.

History. The boy is the youngest of six children, all the rs being girls. He has always been puny, but has never red from any serious illness; he has much trouble with his stion. The cause of death of the child's paternal grand-ner is not known, except that it occurred from some acute se. His maternal grandmother is said to have died of ustion "from many cares and much child-bearing." paternal grandfather died of renal and hepatic lesions, e the maternal grandfather, now over seventy-five years of is in excellent condition, suffering only from occasional ks of gout. The child's father is a healthy, active business ; his mother is somewhat nervous, but in fair condition. and one daughter suffer from chronic blepharitis, and there additional indications in other members of the family of a fulous taint.

About two weeks prior to the child's visit for ocular exam-ion it was noted that the pupil of the right eye was slightly ted and that through it a yellowish-brown mass was visible. re was no history of injury and no history of any affection

local or general to which this change in the eye could be attributed.

Examination. The child was distinctly under-sized, exceedingly pallid, the complexion being almost pasty, an appearance all the more pronounced on account of the reddish hair which thinly covered his scalp. Physical examination, however, failed to reveal chronic disorder of any of the organs of the body, with the exception of the diseased eye, and the only constant menace were the attacks of indigestion, which doubtless were frequently brought on by ill-considered diet.

Examination of the Right Eye. Vision was apparently lacking and light perception could not be demonstrated. The external appearance of the eye presented no anomalies. The pupil was semi-dilated and fixed, but the iris was of good color, resembling that of the opposite side; synechiæ and inflammatory deposits were wanting. The iris responded to a mydriatic, although the pupil did not dilate ad maximum. Well forward in the vitreous chamber and behind the pupil space could be seen a yellowish or rather yellowish-pink mass, over which some large vessels could be detected. This apparently filled the entire ophthalmoscopic field and no red reflex could be demonstrated, nor was there any sign of undetached retina. The tension of the eye was normal, or about equal to that of the eye upon the opposite side. The clinical appearances were those of glioma, and the opinion was expressed that the eye should be enucleated. The patient was also examined by Dr. Herman Knapp, who thought the disease was probably glioma, and in any event, recommended the enucleation of the eyeball.

Examination of the Left Eye. This was normal in all respects.

The eyeball was enucleated on the 27th of January, 1900; chloroform narcosis. The healing was prompt and there was absolutely no unfavorable sign at any period of the convalescence. After the original shock attending the operation of enucleation had passed away, and the necessity for frequent dressings of the eye had disappeared, the child seemed to gain in nutrition. This improvement was in a measure attributed to the removal o

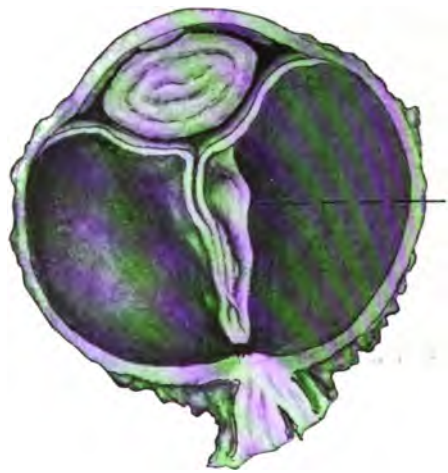

Fig. I. Detached and thickened retina.

eye. A recent letter, however, from Dr. Estes, the child's
sician, states that "he has not improved in nutrition or
wth markedly since the operation." He further states, how-
r, that much of the child's indigestion, from which he still
ers, is due to injudicious feeding and indulgence in sweets.
re has been no sign of recurrence *in loco* and no metastasis.
e for a short time a small œdematous swelling appeared at
bottom of the orbit. This, however, has entirely passed
y and was probably due to the pressure of the edge of the
icial eye. At the present writing, eighteen months after
operation, the child appears to be normal in all respects.
The enucleated eye was immediately placed in a solution of
alin, and, after hardening, divided and submitted to macro-
ic and microscopic examination.

PATHOLOGICAL REPORT.

Macroscopical Examination. The eyeball measured twenty-
mm. in its antero-posterior and twenty-two mm. in its
ical and horizontal diameters. It was divided into halves
section passing, in a horizontal plane, through the center
ne cornea and the optic nerve. The retina was folded closely
ther in the center of the globe, attached only at the optic
e entrance and at the ora serrata. It was moderately thick-
d, but presented no distinct trace of tumor formation. Fig. I.
subretinal space was filled with a grayish-white exudate; the
oid was in its normal position and showed on its inner sur-
, on the temporal side, a narrow linear pigment mass. Aside
this no cause could be seen for the retinal detachment.
-half of the specimen was mounted in glycerine jelly, the
r half imbedded in celloidin for microscopic sections.

Microscopical Examination. The cornea, anterior chamber,
ry bodies, choroid, and sclera are entirely normal. The iris
artly adherent to the lens, but is otherwise normal, and shows
sign of previous infiltration. The retina is in close apposi-
to the posterior surface of the lens, and the very small vitre-
cavity contains a few fine, homogeneous bands, crossing

between the inner surfaces of the retina, which include an occasional oval cell.

The subretinal space is filled with a homogeneous exudate, which stains pink with eosin. Imbedded within it are a large number of enormously swollen cells, each of which possesses a shrunken, distorted nucleus, coarse, highly refractive granules, and masses of pigment. The pigment is in fine rods and distinctly of the type peculiar to the retinal pigment cells. In many places all that can be recognized of the cell is a large oval vacuole in the exudate, which contains an isolated nucleus and scattered pigment granules. These cells are especially numerous on the temporal side. They have remained attached to the outer edge of the exudate, and consequently have been separated from the choroid by the shrinking of the former, but they evidently represent the line of pigment described on the surface of the choroid in the macroscopical report. The retinal pigment cells form a regular layer, which has remained adherent to the surface of the choroid.

The optic nerve is partially atrophic, but the majority of the nerve fibres retain the Weigert nerve sheath stain.

The *principal changes* occur in the retina. It is moderately thickened. The nerve-fibre layer is œdematous and the supporting fibres of Müller are prominent. The ganglion cells are in an advanced condition of chromatolysis — they are distorted and shrunken, their processes are broken abruptly off, the Nissl granules are absent, and the cell bodies show numerous vacuoles. The rods and cones have entirely disappeared, and the fibres of Müller extend in the form of fine arcades a short distance beyond the limitans externa, and in places show the presence of nuclei similar to those in the external nuclear layer. (Compare Deutschmann's[1] article, Archiv. f. Ophthalmologie, XXV, 3, and Tartuferi's[2] in Centralbl. f. die med. Wissenschaften, 1882, XX, p. 801.)

In the nasal leaf of the retina, commencing one mm. from the nerve entrance and running for a distance of about 1.5 mm., is a series of cyst-like spaces, each measuring .16 to .25 mm. in

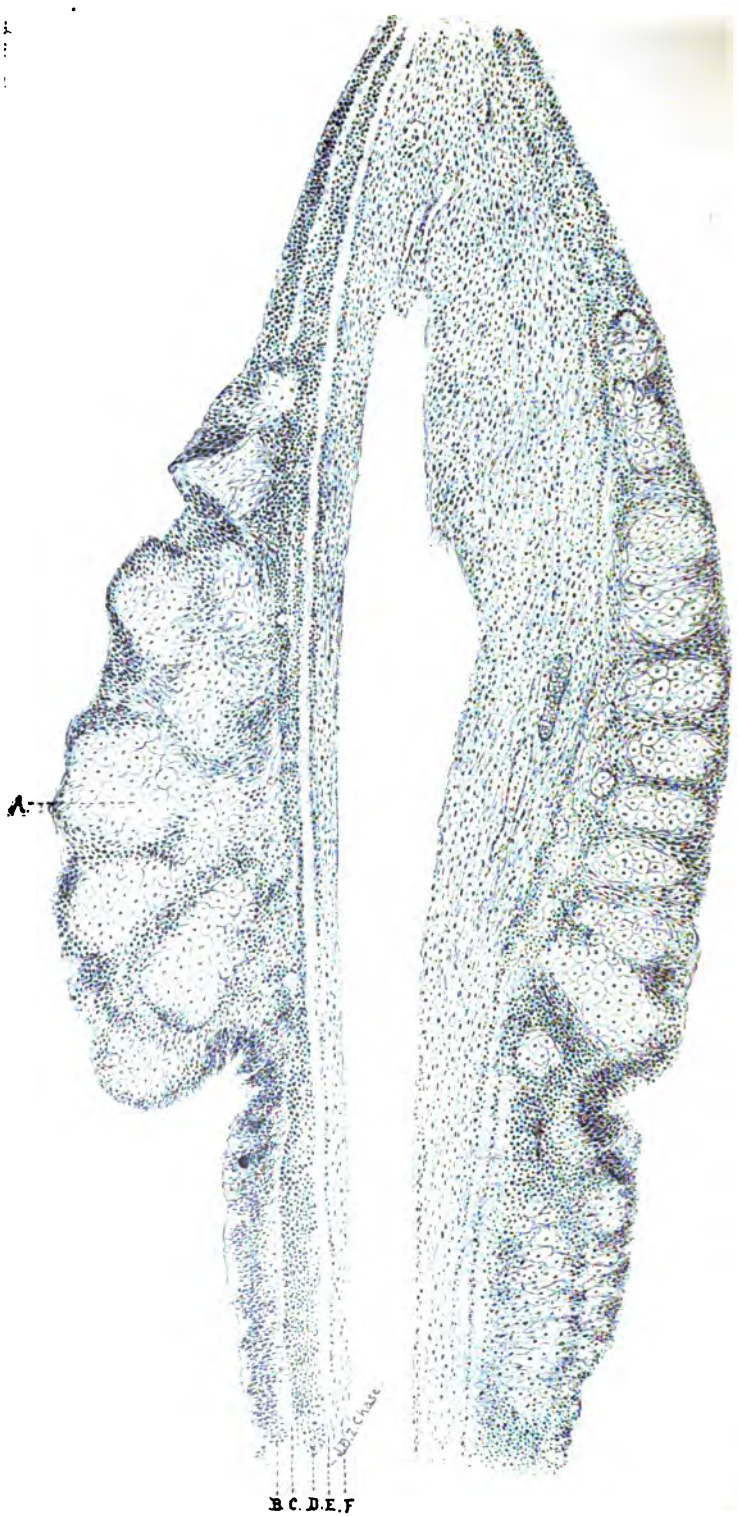

Fig. II. A, Cavities in the external nuclear layer of the retina. B, External nuclear ...r. C, External granular layer. D, Internal nuclear layer. E, Internal granular ... F, Ganglion and nerve fibre layer. Obj. 3. Ocular 3.

ımeter, situated in the position of the external nuclear layer, ıich is here absent. A similar series begins in the temporal f three mm. from the nerve entrance, and extends for a dis- ıce of four mm. (Fig II. For convenience, these spaces have en represented in the drawing as being exactly opposite). In ese positions the retina is thickened to nearly double its nor- l width. The cavities are bounded laterally by the thickened res of Müller and externally by the limitans externa retinæ. ıey are crossed by a fine reticulum which at first glance gives e appearance of a network of anastomosing fibres of support- g connective tissue. More careful examination, however, ows that this reticulum represents the walls of large flat cells, easuring between fifteen and thirty micro-mm. in diameter, ch of which contains a distorted and degenerated nucleus her at the center or near the periphery; the cell body has a e granular appearance, more prominent in some cells than in ıers, but contains no large refractive granules (Fig. III). In ctions stained by the Weigert fibrin method the cell outlines do t retain the stain. The half of the eyeball which was mounted the jelly for a macroscopic specimen was subsequently re- oved from the cup and a portion of the retina was stained with mic acid, but the cells were not blackened. The condition ıs traced through a series of sections and the same changes ere found in approximately the same position. The retina hibits no sign of inflammatory process.

The explanation of these changes is difficult. The follow- g possibilities have been suggested:

1. *They represent a fine network of fibrin, such as has been equently described in retinitis albuminurica.* The entire absence, owever, of signs of inflammation in the retina, of round-cell in- tration about the vessels, of exudation or hemorrhage, and e negative reaction of the fine network to the Weigert stain, well as the complete difference in the appearance of the cavi- es, render this theory untenable.

2. *The condition is due to œdema of the retina, the spaces repre- nting cavities between the separated fibres of Müller.* Such

cystic cavities have been very frequently described in the fibre layer of the retina in detachment of this membrane by Leber,[3] Müller,[4] Nordenson,[5] Poncet,[6] Caudron,[7] etc. But in only two cases have there been found in the outer layers changes similar to those existing in our specimen. In 1882, Tartuferi[2] described in a case of hemorrhagic glaucoma "vacuole formation in the cones, due to œdema, which later may widen out and communicate through openings in the limitans externa with spaces in the external nuclear layer, which are likewise filled with serum and surround the cone nucleus on all sides, so that the latter is separated from the neighboring elements." In a case published by Webster,[8] in 1887, Van Gieson speaks of "numerous small spheroidal cavities in the outer nuclear layer, filled with fluid and containing delicate flattened connective tissue fibres, with wing-like anastomosing processes. These are the fibres of Müller, exposed by the disappearance of the outer nuclei. These small cysts are inclosed between the limitans externa and the inner nuclear layer. There are smiliar cavities in the inner nuclear layer, but fewer in number." No plates accompany either paper. In our case, however, the minute spaces do not represent cavities formed by the separation of the fibres of Müller, but are distinct cellular elements. In this opinion we are supported by Professors Simon Flexner and George A. Piersol of the University of Pennsylvania, who have studied the sections carefully. The cellular nature of the process is shown especially where the peculiar formation begins. A few isolated, swollen cells appear in the midst of the cells of the outer nuclear layer, and they gradually become more numerous, until they fill out the large spaces described above.

3. *They are fat granular cells, such as are found in the degenerative lesions of the central nervous system (in softening of the brain, etc.).* They contain, however, no refractive granules, and are not stained by osmic acid.

4. *They are inclusions in an obliquely cut and folded retina of the cells described in the subretinal fluid.* Now, although they are of much the same size, they represent an entirely different

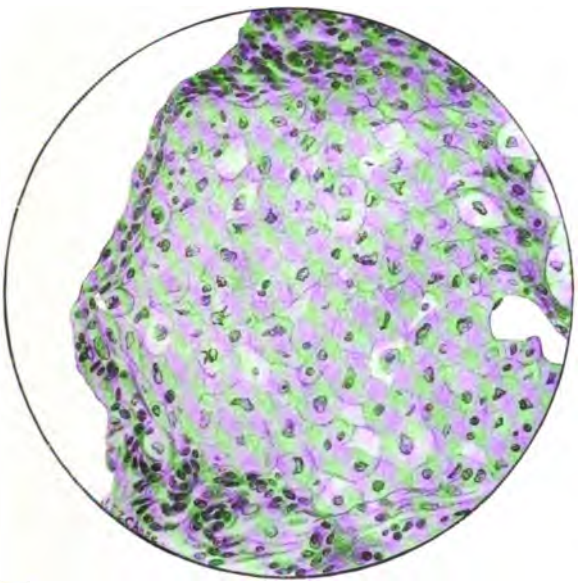

Fig. III. Detail of structure from A, Fig. II, showing large flat cells with degen rated nuclei.— Leitz-Wetzler. Obj. 7. Ocular 3.

earance. They contain no highly refractive granules and y rarely any pigment, although the two forms of cells are arated in some places only by the limitans externa retinæ.

5. *They are due to the burrowing of these cells into the retina, ere they have undergone secondary proliferation and lost their ment and refractive granules.* Such a process, however, would hard to understand.

6. *They are a proliferation of the nuclei of the external nuclear er and represent a true tumor formation.* Such a condition is ecially suggested by the overlapping of portions of the retina, though from an active cell proliferation. The change, how- r, has occurred in two remote portions of the retina, at the ne time, and the cells with their degenerated nuclei do not e the appearance of actively proliferating cells. A tumor of s character would be unique.

7. *They are due to an œdematous or dropsical degeneration of nuclei of the external nuclear layer.* The latter are the nuclei the rod and cone visual cells — modified epithelial cells de- ed from the embryonic epiblast, and would be subject to the nges observed in such cells. That the condition is not a ty metamorphosis is shown by the absence of granules and negative reaction to osmic acid. *Myxomatous* degeneration y be likewise excluded, as the cells do not stain typically h hæmatoxylin or thionin. Œdema of the retina is one of the st frequently described conditions in detachment, and in this pect our case forms no exception to the rule. Therefore it possible that we have here *a localized dropsical degeneration of nuclei and surrounding protoplasm of the visual cells.* This we ieve to be the most probable explanation of a change which certainly of great rarity, if it is not unique. At the same time cannot exclude entirely the possibility that it is a true tumor rmation, and must leave the matter for time and future ob- rvation to decide.

A word may be said in regard to the diagnosis from the clin- l standpoint. 'As is well known, and as has been particularly inted out by Mr. E. Treacher Collins, the following conditions

may be mistaken for glioma: persistence of the posterior part of the fœtal fibro-vascular sheath of the lens, masses of tubercle in the choroid, and inflammatory or purulent effusion into the vitreous following retinitis or cyclitis, usually with detachment of the retina. Although well-marked differential diagnostic points have been established between these affections and glioma of the retina, it is frequently very difficult to come to a definite decision, and therefore it is an excellent surgical rule that the eye should be enucleated in case of doubt.

In June, 1889, Dr. De Wecker called the attention of the Society of Ophthalmology of Paris[9] to a danger to which young subjects attacked with white degeneration of the retina, or retinitis circinata, are exposed, inasmuch as the disease may be mistaken for glioma. He believes that this disease is not necessarily confined to the eyes of adults, but may be seen also in infants. Among three observations he cites the case of a young girl, aged six years, under his care for two years, during which time, although the lesions resembled glioma of the retina, they had not increased and the intraocular tension had not been augmented. This eye was afterwards enucleated by one of De Wecker's confreres, who, in addition to the plaques of atrophied choroid and degenerated retina described by De Wecker, found a small ossifying fibroma. In the present instance the clinical appearances were exactly those of glioma, and, although, fortunately for the child, this malignant form of growth was not discovered with the microscope, in the light of the report already cited it is not absolutely sure that tumor formation is entirely absent. The enucleation, therefore, was a wise procedure.

BIBLIOGRAPHY.

1. Deutschmann. Archiv. f. Ophthal., XXV, 3.

2. Tartuferi. Ueber einige Krankhafte Veränderungen der Neuro-epithelschict der Netzhaut. Centralbl. f. d. med. Wissenschaften, 1882, XX, 801.

3. Leber. Bericht u. d. Versammlung d. Ophth. Gesellsch., Stuttgart, 1882, XIV, 18.

4. Müller. Archiv. f. Ophthal., IV, 1, p. 363.

5. Nordenson. Bericht u. d. 17 Versamml. der Ophth. esellsch., 1885.

6. Poncet. Mémoires de la Société de biologie, 27 Octo- er, 1873; Gaz. hebdomadaire, 1873, p. 703.

7. Caudron. Le décollement de la rétine. Rev. gen. Ophth., Paris, 1886, V, 241-289; 337-360.

8. Webster. A Case of Complete Detachment of the etina, with Œdema and Formation of Cysts. N. Y. Med. ourn., 1887, XLV, 544.

9. De Wecker. Du danger auquel sont exposés les jeunes ujets atteints de dégénérescence blanche de la rétine ou rétinite rcinée. Archiv. d'Ophth., February, 1900, p. 110.

ONCERNING THE TREATMENT OF THE APPARENTLY UNAFFECTED OR AT MOST BUT SLIGHTLY INVOLVED EYE IN CASES OF MONOLATERAL GLAUCOMA.

By G. E. de SCHWEINITZ, A.M., M.D.,

Philadelphia, Penn.

This paper deals only with cases of *primary* glaucoma when ey appear as (1) acute glaucoma, (2) sub-acute or chronic con- estive glaucoma ("glaucoma irritatif," chronic inflammatory laucoma); (3) chronic non-inflammatory glaucoma (usually nown as simple chronic glaucoma); (4) absolute glaucoma.

Acute glaucoma, although a disease of sudden onset, may ive warnings for weeks and even months prior to the attack. hese warnings are alterations in the amplitude of accommoda- on, temporary obscurations of sight, iridescent vision, that is, ne phenomena of rainbows around artificial lights, and periods f increased intraocular tension. The attack itself is character- ed by severe pain, sudden, almost complete loss of vision, ilatation and immobility of the pupil, shallowness of the an-

terior chamber, steaminess of the cornea, and great increase in intraocular tension.

Chronic congestive glaucoma may have the same prodromal signs which have just been enumerated, but these are repeated and progress until they, with several added ones, become the salient symptoms of the disease: Steamy cornea, shallow anterior chamber, semi-dilated pupil, degenerating iris, cupping of the optic disc, pulsation of the retinal vessels, and contraction of the visual field, most often on its nasal or supero-nasal approach. Exacerbations are common, and then chronic congestive glaucoma resembles acute glaucoma, although it should be regarded as a different clinical manifestation.

Chronic non-inflammatory glaucoma, ordinarily known as simple chronic glaucoma, presents no active symptoms. Instead there are progressive failure of vision, particularly of the field of vision; excavation of the optic disc; crowding of the vessels to the nasal side; halo around the nerve head, and *increased intraocular tension*, which may not be constantly present. It is difficult to fix the date of onset in this variety, because of the absence of the pronounced prodromal symptoms which may precede the other types of the disease.

It is important, as De Wecker insists in his admirable Rapport sur la Valeur de l'Iridectomie dans le Glaucome, presented to the Congrès de la Société française d'Ophtalmologie in May 1901, to separate from each other these three great clinical types of glaucoma if one wishes to obtain the best results from therapeutic measures. Furthermore, it seems inadvisable, at least in the present state of our knowledge, to exclude simple glaucoma from the catalogue of the glaucomas, but it should be carefully distinguished from progressive optic nerve atrophy with excavation and other types of progressive optic nerve disease unassociated with increased intraocular tension.* The chronic congestive variety of glaucoma sometimes resembles simple

*Czermak (quoted by De Wecker, loc. cit.) typifies a school which holds to an entirely different definition of chronic simple glaucoma, inasmuch as he admits in this class only those cases in which he has never been able to establish an increase in the tension of the ocular globe.

ronic glaucoma and *vice versa*. If, as De Wecker has pointed t, in the affected eye corneal involvement is made evident by bulous vision, halos, etc., or, in other words, by irritative at-cks, the case ceases to be one of simple glaucoma, and is to be ouped with the congestive types.

All of these varieties may pass into the stage which we dinarily know by the name *absolute glaucoma*, with its char-teristic symptoms of fixed and dilated pupil, discolored iris, eenish reflex from the lens, obliterated anterior chamber, and zy cornea.

From the times of Von Graefe to the present day experienced hthalmic surgeons have held that some form of surgical in-rvention most frequently gives the best and most permanent sults in the treatment of glaucoma, and that the more nearly ch intervention approaches the onset of the disease, the more ely is the ultimate effect to be a good one.

The reasons for promptness in surgical interference are not rd to find. As Rochon-Duvignaud tersely puts it: the ex-etory apparatus of the eye (iritic angle) is intact at the time the first attack of glaucoma, but it is obliterated at a more lvanced period of the affection. Iridectomy will be efficacious performed *before the root of the iris is welded to the cornea; other-ise not.*

The bilateral character of glaucoma is well known, and has een commented upon by Von Graefe and all succeeding writers. ll cases of acute primary glaucoma which have come under y own care during the last fifteen years have sooner or later een bilateral, the shortest interval being about six hours, and e longest two years and ten months, that is to say, all that I ave been able to trace. The same is true of cases of chronic ongestive glaucoma. Of chronic non-inflammatory glaucoma e may say with Von Graefe, "glaucoma simplex affects almost ithout exception both eyes successively;" or with E. T. Drake-Brockman,* "persons suffering from chronic glaucoma are sually attacked in both eyes simultaneously, or at very brief

* Ophthalmic Review, Vol. IV, 1885.

intervals of time between the two eyes;" or with Nettleship, "
something like two-thirds the disease is sooner or later sy
metrical;" or with Priestley Smith, "in the large majority
cases primary glaucoma is a bilateral affection." I need n
burden the pages of this paper with further quotations illustra
ing the same point.

Occasionally the interval of time between the beginning
the disease in one eye and its development in the second is ve
long. Thus, Mr. Nettleship,* referring to chronic glaucom
says: "In twenty-six cases at least a year was known to ha
elapsed since the disease in the first eye; in thirteen of the
twenty-six five years or more had elapsed without the seco
eye being attacked." But immunity for five years does not co
fer complete immunity, and it is impossible to state that a
specified interval insures to the second eye entire freedom fro
risk. Ten-year intervals have been reported by Schweigg
and other observers. The most notable instance of delay in t
appearance of glaucoma in the second eye, viz., twenty yea
has been contributed by Mr. Priestley Smith.† These cas
however, are the exception. The bilateral character of gla
coma, or a comparatively short interval before the second e
is affected, is the rule.

To introduce the subject, and I hope to stimulate discussio
I wish to propound certain questions:

I. *What shall be done with the apparently sound eye after t
first eye has been operated upon for acute glaucoma?*

It is a well-known fact that iridectomy upon one eye f
acute glaucoma is frequently followed by a speedy outbreak
the same disease in the opposite eye. Therefore a good rul
and one usually followed, is to keep the non-affected eye und
the influence of a myotic until the eye upon which the operatio
has been performed is entirely healed and free from irritatio
A case of this character is the following:

CASE I. A woman, aged 30 +, came to the Jefferson Medic

* Royal London Ophthalmic Hospital Reports, XII, 1888-1889.

† Ophthalmic Review, 1885, X, pp. 261-266.

ollege Hospital with typical acute glaucoma of the left eye, hich had existed for five days. Iridectomy was immediately rformed under general anæsthesia; no reaction; wound closed twelve hours. Forty-five hours later an attack of acute glau- ma occurred in the right eye, which was controlled by eserine. here was a repetition of this attack one week later, when a oad peripheral iridectomy was performed; healing without re- tion; ultimate vision in each eye 6/6.

Outbreaks of glaucoma during the first two weeks after an dectomy has been performed upon one eye are especially re- rred to by Von Graefe,* who noted that they were very apt to ppen (in 30 per cent. of his cases) when the operation had been ade on an eye with primary acute glaucoma during the period high grade inflammation, especially if it previously had ex- bited prodromal signs of glaucoma. A good example of this aracter has been recorded recently by Dr. Risley.†

The cases described by Von Graefe are typified by the follow- g instance from my practice:

CASE II. On September 3, 1900, a woman aged 70 came th typical acute glaucoma of the right eye, vision being reduced shadows. In the left eye were peripheral lenticular opacities, slightly congested disc containing no cup, and full veins de- essed and crossed by arteries undergoing endarterial changes; nsion and field normal; refraction hypermetropic, 5 D. The ght eye was iridectomized on September 7th; no complication cept much hemorrhage in anterior chamber, which was slow in sorbing; complete relief of pain and reduction of tension to rmal. On the twenty-eighth of September, that is, eleven days ter the iridectomy, while the patient was quietly sitting in her wn room, she began to notice at four o'clock in the afternoon bscuration, halo-vision, etc., before O. S.; tension + 2; cornea eeply hazy. A typical attack of acute glaucoma was cut ort with pilocarpine and large doses of salicylate of sodium. ridectomy was proposed the next morning, but positively de-

* Arch. f. Ophthal., XV, 1869, 3 abt., p. 116.

† Ophthalmic Record, March, 1901.

clined. The patient continued to use pilocarpine in that eye until the day of her death eight or ten months later.

Sometimes the interval between the attacks is very long. A case in point is the following:

CASE III. A woman, aged 50, with constitutional syphilis, and who had suffered from plastic iritis, which, however, had entirely disappeared, was attacked in the left eye with typical acute glaucoma on October 10, 1895. An iridectomy was at once performed; the wound healed with entirely satisfactory results, and vision equaled 6/9, which degree has remained until the present day. The right eye was apparently healthy; only a few pigment flecks on the lens capsule; refraction hyperopic, 2 D. On the 21st of December, 1898, the right eye was iridectomized for an attack of acute glaucoma, which had lasted twenty-four hours, and had appeared with the usual prodromes; normal healing; ultimate vision 6/6. The interval between the two attacks was two years and ten months.

It is not germane to the present inquiry to discuss the causes which contribute to the second attack; predisposition, dilatation of the pupil under a covering bandage, shock, worry, and nervous apprehension, all have been given a rôle in this respect. Doubtless two are potent, viz., apprehension in a predisposed subject.*

Are there any signs by which one may reasonably infer that the apparently sound eye will suffer an acute glaucomatous attack like its fellow eye within a comparatively short time?

(*a*) Shallowness of the anterior chamber and beginning opacity in the lens with swelling, a high degree of hypermetropia and smallness of the corneal diameter.

(*b*) The mydriatic test suggested by Edward Jackson,† C

* The disposition of the first patient whose history is recorded (Case I) entirely changed after the second iridectomy. Prior to this she was apprehensive to the point of nervous irritability; her expression gave the impression which is best described by the word "hunted." Asked in regard to the change in her mental attitude, she replied "Ah, you see the terror is gone." This anecdote is recorded because it well illustrates the potency of apprehension; De Wecker makes similar references.

† American Journal of the Medical Sciences, April, 1898; also International Clinics, Vol. I, Eleventh series.

C. Harlan,* and W. Brailey.† This consists of the instillation f a solution of homatropine into an eye which is under sus-icion, and noting whether it produces any rise in intraocular ension, or pulsation of the blood vessels of the fundus.

(*c*) The palpation test, that is, an observation is made whether finger pressure on the globe so slight that in a healthy ye it does not cause pulsation of the blood vessels of the undus, does cause them to pulsate in the eye under suspicion.‡

(*d*) The history of prodromal glaucomatous phenomena.

If all or any of these tests are positive, the correct answer o the question originally propounded would seem to be: *An ridectomy§ should be performed upon this eye as soon as the anterior hamber is restored upon the opposite side, that is to say, as soon s the wound has closed; in the meantime the eye should be kept nder the influence of a myotic.*

Doubtless many will at once say, "Certainly, who teaches therwise?" I do not know that any one teaches otherwise, ut I also doubt if in any well-known modern textbook this ad-ice is given in so many words, although now and then the tatements are fairly positive. Thus Fuchs|| says: "In in-ammatory glaucoma an operation should be performed in the rodromal stage, provided the patient will consent. If the opera-on is deferred until the inflammatory attack is developed, the urgeon cannot foretell how severe it will be, and, moreover, e operates under less favorable conditions." I am inclined to hink we may advance even beyond this position under the ircumstances which I have detailed, especially if the patient is to ass from under expert observation, and be placed under con-itions not favorable for obtaining competent advice.

II. *What shall be done with the apparently sound eye after he first eye has been operated upon for chronic congestive glau-oma?*

* Ophthalmic Record, January, 1898.
† Trans. Ophth. Soc., U. K., XX, 1900, p. 258.
‡ It is needless to point out how difficult it is to apply this test with accuracy.
§ Some surgeons would prefer sclerotomy.
‖ Lehrbuch der Augenheilkunde, Achte Auflage, Wein, 1900, p. 432.

The situation can best be described by detailing the history of a case which I examined by the courtesy of Dr. Myles Standish of Boston, whose notes, somewhat condensed, I append:

CASE IV. A man, aged 42, was examined first in January, 1896, and had a compound hypermetropic astigmatism of the right eye and a mixed astigmatism of the left eye corrected, vision rising to normal. He complained of a rainbow ring around artificial lights at times, the phenomenon being present only before the right eye. There was absolutely no other sign of increased intraocular tension. He was forbidden to do close work for prolonged periods at a time (he was an architect by profession), and was given a solution of eserine with instructions to use it in case the signs of acute glaucoma appeared. In the fall of the same year his eyes were again examined; the rainbows had increased in frequency, and sometimes persisted for several days. Vision was still entirely normal on clear days. The central depression of the nerve head occupied about two-thirds of its center, and there was venous pulsation; the tension was noted as very doubtfully increased. The field of vision was absolutely normal. Six months later the condition was still unchanged, that is to say, when the examination was made in June, 1898. He was not again seen until February, 1901, when the vision of the right eye was .2, and the tension + 1; there was loss of the nasal field, and the nerve head was typically cupped. Before the left eye, which previously had exhibited absolutely no sign of trouble, rainbows had begun to appear, but vision and field of vision were normal; tension was doubtfully increased. Three months later his visual fields appeared as in the diagram (Figs. I and II).

This is a case of chronic congestive glaucoma, although there never were any very violent manifestations. It is a type of the cases to which De Wecker refers so eloquently in his report, and which nearly approach in their clinical history simple glaucoma, and therefore may be debarred from the most desirable treatment, or, in other words, there may be unnecessary delay in surgical intervention. Had it been possible for the patient whose

story has just been detailed, to be under constant observation, had he permitted himself to be examined by his ophthalmic rgeon at suitable intervals, the decided change from the odromal to the more fully developed glaucomatous stage ould have been prevented by an iridectomy. But this is e very point of the whole matter. How soon dare we inter- e in these cases, and if we interfere surgically where may we int for authority for such early surgical interference? In such case iridectomy would seem to be indicated as soon as the inbow vision was certainly associated with attacks of increased raocular tension. It illustrates further, as has so often been

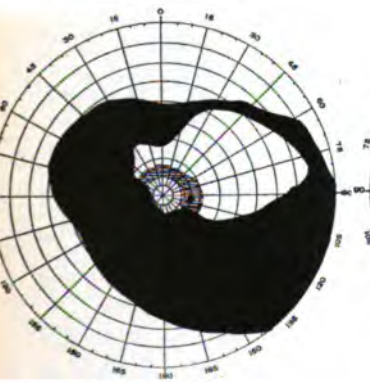

FIG. I.— RIGHT.
nost complete loss of nasal and lower eld; semi-circular scotoma. Case 4.

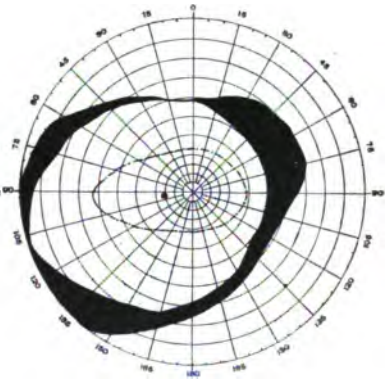

FIG. II.— LEFT.
Beginning contraction of field, particularly on nasal approach; dotted line represents red field. Case 4.

ted before, that even the most intelligent patients cannot be isted to report at suitable times and in season; *an eserine ex- ence is not a safe one.* Now, of course, a successful iridectomy the right eye should be followed by an iridectomy on the left e before vision fails, and *while the iritic angle is intact.* This an has, I believe, been pursued with satisfaction to surgeon and tient.

Doubtless all of us remember Laqueur's article on "*The Pro- omal Stage of Glaucoma,*"* with its accurate description of the sual obscurations, the colored rings around lights, the nebu- us cornea, and the increased intraocular tension, and perhaps e also remember his recommendation that at this period the

* Archiv. f. Ophth., XXVI, 1880, abt. 2, 1–28.

treatment should consist of eserine and careful attention to the patient's general condition, particularly his diet, but that if after a time any anatomical change in the eyeground, any excavation of the optic nerve, or any obscuration of any portion of the visual field, or any sign of the same disease in the opposite eye should appear, then an iridectomy should at once be performed. He refers to the brilliant results which Von Graefe obtained with iridectomy in this very prodromal stage, and says that his own experience can confirm them, and yet he hesitates. Why should one wait for the excavation, or for a permanent obscuration of a part of the visual field, when a clinical history definitely shows that there have been periods of rainbow and nebulous vision and increased intraocular tension, and particularly when it can be proven that these were dissipated by the use of a myotic? Why should one wait until the damage is done? Would it not be better to anticipate both the agglutination of the root of the iris to the cornea in a firm adhesion, and the destruction either of areas of ganglion cells of the retina, or of the optic nerve fibres by making what E. Treacher Collins* has termed a *preventive iridectomy*, which he thinks under certain circumstances is justifiable? Perhaps you may say: "Who acts otherwise?" and yet authority for such a surgical procedure is hard to find. I have already quoted Fuchs's opinion.

III. *What shall be done with the apparently sound eye after the first eye has been operated upon for chronic simple glaucoma?* This is confessedly more difficult to give an answer, but also less frequently necessary, because so many cases of chronic non-inflammatory glaucoma are bilateral almost from the start.

If this type of chronic glaucoma is bilateral, operation upon the more affected eye followed as soon as it is safe by iridectomy (or sclerotomy, or a combination of both) upon the other eye is a nearly universal surgical procedure, and gives the patient the best chance.†

Frequently, however, one eye is pronouncedly glaucomatous

* Royal London Ophthalmic Hospital Reports, XIII, 1890-93, p. 166.

† I am aware of the fact that Mr. Nettleship doubts the propriety of operating upon poorer eye first, but begins at once upon the better or less affected eye.

nd the other eye, although presenting the ophthalmoscopic ap-earances of glaucoma of this type, retains perfectly normal entral and peripheral vision, and the patient would be greatly urprised if operative interference with this eye were proposed. A case in illustration is the following:

CASE V. A man, aged seventy, of typical gouty antecedents, nd with many gouty manifestations, and who had had many ttacks of influenza, came with typical chronic glaucoma of the ight eye. Vision equaled large letters seen only excentrically. The field of vision is illustrated in the diagram (Fig. III). The

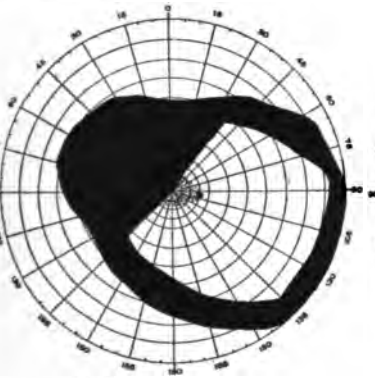

FIG. III.—RIGHT.
Almost complete loss of nasal half of visual field, with scotoma encroaching on central area. Case 5.

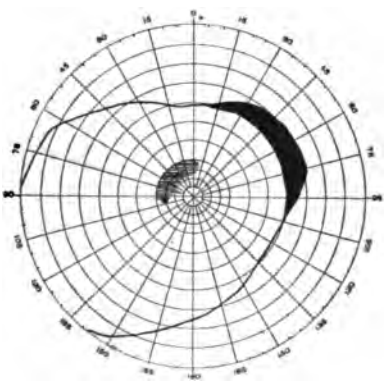

FIG. IV.—LEFT.
Just beginning contraction of nasal field; scotoma extending from blind spot in a semi-circular manner upward and inward. Case 5.

erve head was typically cupped; the vessels were pushed to the asal side; there was slight increase in intraocular tension. The ision of the left eye was normal after the correction of its hyper-ietropic refraction, + 1.50 D; the media were clear; the disc was ypically cupped; there was no positive increase of tension; the eripheral field was perfectly normal. A more careful field aken a few days later still showed that the periphery was normal, ut that a scotoma existed in the position marked on the diagram eginning at the blind spot and passing upward and inward Fig. IV). Iridectomy on the right side was proposed and de-lined. The treatment consisted of eserine, strychnia, and nitro-lycerine. Eighteen months later, although central vision in the eft eye is perfectly normal, the scotoma has progressed, and

become ring-shaped (Fig. V). The right eye remains as before; tension, if anything a little greater. Vision, only hand movements. Operation is still declined.

This is a type of many cases in which, in spite of the normal vision and practically normal peripheral field, it would seem proper to urge iridectomy, or at least some form of operative interference; the evidence of what will happen is afforded by the other eye.

Less frequently this type of the disease is truly monolateral, or as nearly monolateral as these cases ever are. Are there any signs by which one may reasonably infer that the apparently

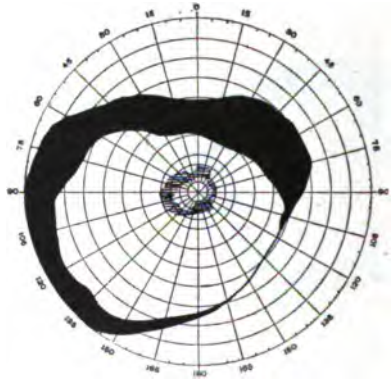

FIG. V. – LEFT.
Visual field of Case 5 eighteen months after Fig. 4 was drawn; greater contraction scotoma now ring-shaped.

sound eye will pass gradually, to be sure, into a condition resembling the one upon the opposite side?

(*a*) Ophthalmoscopic evidence furnished by the formation of a cup beginning to be pathological on the temporal side.

(*b*) Periods of increased intraocular tension detected with the educated finger tips placed, as Coccius and Schweigger advise, upon the sclera itself. Such examinations should be made at different hours on the same day and repeated in the evening, as it is well known that in this disease increased intraocular tension is not constantly present, and may be absent for hours and even days at a time. There is no reason why we should not place the patient under circumstances where expert examination can be made very frequently; no reason, for example, why he

hould not be watched exactly as the general surgeon causes ases suspected of Jacksonian epilepsy to be watched for days t a time until he establishes or does not establish localizing ymptoms.

(*c*) Alterations in the visual field. In typical cases restriction begins on the nasal side, and contraction of the white eld corresponds with that of the colors. That this rule meets ith exceptions, and perhaps frequent ones, I am sure.* It cannot then be utilized alone as a safe guide of action.†

Again, the visual field might be contracted for one examiner nd uncontracted for another, as there is perhaps no examination ophthalmology which is surrounded by so many possibilities r inaccuracy. But, if on successive days, under the same circumstances, controlled, if necessary, by separate examiners, and specially if the test-objects include squares of gray paper Ward Holden's tests, for example), the visual field is found ontracted, it may be on the nasal side, or it may be concentrically, it is fair to assume a beginning pathological change, and to ct accordingly.‡

But it is not sufficient to trust to the periphery of the visual field r information. I am convinced that the study of scotomas in onnection with chronic glaucoma furnishes a prognostic guide. here is no difficulty in finding them, either by the method suggested by Bjerrum, who uses a small test object at a much reater distance than that ordinarily employed, or by ordinary erimetric methods, when care is taken to investigate each eridian, and suitable test objects are employed under varying egrees of illumination. Doubtless, as Bjerrum has pointed out, ese scotomas are the result of the destruction of the fibers of ne papilla at the margin or sides of the excavation, but some-

* Annals of Ophthalmology, VIII, October, 1899.

† I am aware that Mr. F. R. Cross (The Treatment of Chronic Glaucoma, British edical Association, August, 1900), referring to the field of vision in chronic glaucoma, ates that he is satisfied "that diminished vision on the nasal side (or in the upper or wer quadrant of the nasal side) is the most important evidence that we can obtain for e early detection of chronic simple glaucoma, while the retention of vision in the temoral and infero-temporal portion of the field is equally characteristic as the disease rogresses."

‡ Even De Wecker is willing to use eserine as long as vision and the visual field remain normal, but at the very first sign of depreciation or contraction, he operates. This ecessitates a constant and faithful attendance of the patient, difficult to secure.

times they are to be accounted for by alterations in the inne retinal layers. These scotomas are topographically differen from those which occur in simple atrophy, and may be utilized a a differential test between the two conditions, as Bjerrum ha already suggested.*

As I have pointed out elsewhere,† scotomas are often th forerunners of subsequent defects in the peripheral visual field The following diagrams illustrate this, and are taken from th paper already referred to (Figs. VI, VII). Therefore I woul

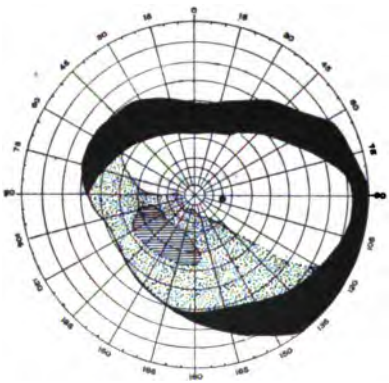

FIG. VI.—RIGHT.
Chronic glaucoma, female, æt. 55. Visual field of right eye, showing the mechanism of the loss of the lower and inner portion of the field with preceding development of scotoma, which gradually extends.

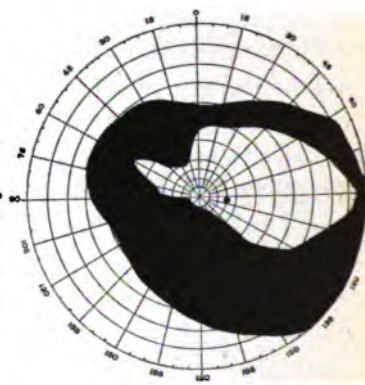

FIG. VII.—LEFT.
Later stage of Fig. 41. Visual field com pletely dark below.

warn against the conclusion that the field of vision is norma because its periphery has its full extent. No field is mappe until each meridian has been examined from fixation point t periphery when dealing with cases of chronic glaucoma.

(*d*) De Wecker's sclerotomy test. This surgeon has sug gested the performance of anterior sclerotomy in doubtful case — an operation which he thinks is harmless. If the symptom are ameliorated, especially if the visual field enlarges, the sus picion is confirmed, and an iridectomy may be performed.

* It will be remembered that Bjerrum has frequently detected central or paracen tral scotomas in chronic glaucoma, and believes that they are peculiar in that the spread over the periphery in all directions, sometimes more in one direction than i another, except outward, where they never pass beyond the blind spot. In other words the defective area wherever situated is in direct continuity with the blind spot. I hav not always found this direct continuity, but the scotomas are certainly very commonly present.

† Annals of Ophthalmology, VIII, No. 4, October, 1889.

Absolute glaucoma may be an unilateral disease. Generally one eye is blind from glaucoma of this type, the question when an operation shall be performed upon the opposite eye is answered with the statement: Not until there are some manifestations of glaucoma. On this point Fukala* is very emphatic, being one of the few writers who seems to have the courage to state his convictions exactly. He says: "In case the glaucoma of the first eye is already absolute, one should perform an iridectomy upon the second eye before the outbreak of the disease, at least, when the suspicion that there will be an outbreak exists." He does not forget to discuss in this connection the chances of failure, and whether an iridectomy is a positive preventive of future attacks of glaucoma, reaching the conclusion that the former are slight and the latter, while not absolutely certain, furnishes the patient with the best protection.† The patient must submit to the risk which all operations entail of inflammatory and infective processes, the danger of the development of cataract, especially if cataract has already begun to develop, the temporary disturbance of vision caused by the changing from a circular pupil to a key-hole-shaped aperture, the astigmatism, which even the best placed iridectomy temporarily produces, and the danger that the operation may be followed by malignant glaucoma. These chances must be taken because, apparently, the risk is greater without than with the surgical interference, and taking all things into consideration, it seems probable, as De Wecker has so forcibly pointed out in his recent report, that surgical interference is, even at the present time, too frequently delayed rather than too frequently recommended. What is the best surgical procedure is not part of the present discussion. Personally I have expressed, and am glad to do so again, my preference for iridectomy. Others think differently. We have not yet sufficiently far advanced in our knowledge of sympathectomy to give it its proper place among surgical procedures.

I would make the following recommendations subject to

* Berliner klin. Wochenschrift, 29, 1891, p. 1248.
† De Wecker prefers sclerotomy followed by iridectomy.

alteration suggested by the discussion which I trust will fol low:

(1) In cases of acute glaucoma the apparently unaffected ey should be operated upon as soon as the anterior chamber is re stored in the opposite eye, that is to say, as soon as the woun is closed, provided the history of the case and an examinatio of the eye afford indications that it is likely to suffer an acut glaucomatous attack like its fellow. If the patient is so situate that he or she will pass from observation and from the resource of expert examination, it might be justifiable to suggest "preventive iridectomy," even in the absence of the signs pre viously described.

(2) In cases of chronic congestive glaucoma the same lin of advice applies, and the operation is to be urged if clear in formation can be obtained that the apparently unaffected ey has suffered attacks of nebulous or iridescent vision associate with increased intraocular tension.

(3) In cases of chronic simple glaucoma, if any periods, how ever temporary, of increased intraocular tension can be demon strated according to the methods already suggested, operatio should be performed even if central and peripheral vision are per fectly intact. Even when these are normal careful perimetri examination may reveal a scotoma of the character already de scribed; if so operation should not be postponed.

(4) In cases of absolute glaucoma the same line of advic expressed under No. 1 and 2 is applicable.

DISCUSSION.

Dr. Bull.— I felt that it would be necessary to apologize fo the non-presentation of my paper on the same subject, but th apology has been rendered unnecessary by this brilliant paper b Dr. de Schweinitz.

I agree with almost everything Dr. de Schweinitz has sai in his paper, but there are two or three points which I wish t emphasize: First, I believe that iridectomy, which is the opera tion I prefer, is only useful very early in the disease and befor the iris has become adherent to the periphery of the cornea. also agree absolutely with what the author says in regard to th

ilateral character of the disease, which is the rule with very rare xceptions. Of course most of us agree with the statement that fter operation upon one eye the other should be kept not nly under observation, but under the influence of a myotic. I ave seen too many cases of the influence of mental apprehension pon the patient between the attack upon one eye followed by peration and the attack in the second eye. I am very glad to gree with Dr. de Schweinitz's observation upon the question of peration upon the second eye as to when it shall be done, and I ould not better state my views on that point than he has ex- ressed them in presenting his own views.

Another point which he has elaborated is the question of peration in the prodromal stage, and I feel like saying with him n regard to the prodromal stage or even before the attack has ccurred in the first eye, but with prodromal symptoms, why hould we wait until excavation of the disc has occurred? I lso agree with Dr. de Schweinitz in regard to the value of requent examinations of the visual field, and especially of that ortion of the field where we may expect to find scotomata. I ave seen many cases in my own experience in which there has een no doubt in my mind that the detection of the central cotomata, of varying shape, sizes, and position, has marked hem as forerunners of the disease.

Perhaps what I have said will help to dissipate from the mind f the members of this society the belief that I am on the sub- ect of operation in chronic glaucoma a pronounced pessimist.

Dr. Risley. — In answer to the inquiry that has been made, why should we wait until the manifestations of glaucoma have resented themselves in the fellow eye," I can conceive of but ne reply, and that is the obvious dangers which surround surgi- al interference in an apparently healthy eye, and yet I do not esitate for an instant to say that, as compared to the dangers f delay, the dangers which cluster around surgical interference re small. I therefore do not hesitate at all to place myself horoughly in accord with the conclusions of Dr. de Schweinitz' aper. It seems to me cruel to the patient, after the opinion he as received about the threatened dangers to the second eye, to ubject him to this ever present fear for months, or it may be for ears.

It is in my judgment justifiable to do an iridectomy as soon s the convalescence from the operation on the glaucomatous ye is complete, and thus save the patient from protracted appre- ension of danger.

DR. GRUENING. — One very important form of glaucoma has not been considered, and that is hemorrhagic glaucoma. This form is not improved by iridectomy. In every case of this kind where I had performed iridectomy I observed that the tension continued, the pain became excessive, and the vision was not improved. Therefore, before we propose operation in every case of glaucoma we should know our cases very well indeed and we must know whether at any time a hemorrhage had taken place. Of course we all know what is meant by hemorrhagic glaucoma, it is a glaucoma following intraocular hemorrhage and not a glaucoma with hemorrhage following iridectomy. Some appear to have the opinion that hemorrhagic glaucoma exists when after an iridectomy hemorrhagic spots appear in the retina, but that condition is very common, and is no hemorrhagic glaucoma. I am fully in accord with Dr. de Schweinitz in regard to operation in all other cases.

Dr. de Schweinitz asks whether we should operate on both eyes or upon the better instead of the worse eye in some cases. In New York the practice on this point is not uniform, some prefer to operate on the one, some on the other eye. My practice has been to operate on the better eye first, and for this reason. Formerly I operated upon the worse eye, the patient became discouraged at the result, and never had an operation performed upon the other eye, and I became convinced that if the operation were done upon the better eye first the patient could note the greater improvement, and since I have adopted this plan my patients have always presented themselves for operation upon the second eye.

DR. HARLAN. — When both eyes are involved, but one more than the other, what is the objection to operating upon both at the same sitting?

DR. GRUENING. — I never perform a double operation on the eye, for we can never tell what is going to happen. I have lived long enough to see a number of cases of hemorrhagic glaucoma not diagnosed before operation, but give a great deal of trouble after the operation.

DR. THEOBALD. — There is one thing that influences me in a measure in deciding whether or not to operate on the second eye in which there are no definite signs of glaucoma, an iridectomy having been done on the first eye. I am persuaded that errors of refraction, and especially astigmatism against the rule, are factors in the causation of glaucoma; and when I find a con-

iderable amount of astigmatism in the second eye, and I have ontrolled the inflammatory trouble in the first eye by operation, put the second eye in a position of safety, comparative, as I be-eve, by the careful adjustment of glasses, and let the question of peration remain in abeyance. Of course where there are defi-ite signs of glaucoma it is another matter; but in such cases as ave been referred to I feel justified in correcting the error of efraction and watching the case.

Perhaps I did not understand Dr. Bull correctly, but I nought he said that iridectomy is only valuable in the early tages of glaucoma. Surely he did not mean that, for we have ll seen the vision improve in what may be called the later stages f glaucoma by this operation.

Another point I want to speak of concerns glaucoma simplex, nd what Dr. de Schweinitz said about operation on the second ye. I confess I should hesitate to operate on the second eye ith good vision and no definite signs of glaucoma. However, should be guided by the result of the iridectomy on the first ye. I have always taken the worse eye for the experiment, for it s certainly an experiment, and if the result is satisfactory that ould influence me in favor of operating upon the other eye.

Dr. Kipp. — I suppose all who have operated for many years ill agree with Dr. de Schweinitz on what he says in regard to cute or subacute glaucoma, but different opinions exist with egard to simple glaucoma. In my experience simple glaucoma as been but rarely improved by iridectomy, and has in many ases failed to arrest the progress of the disease. My unfortunate xperience has often made me think that I could give up iri-ectomy entirely in such cases and rely on myotics. But as these ave failed me as well, and as I know of no other remedy that as arrested the progress of this disease, I have gone back to ny former practice, and now perform iridectomy in simple glau-oma as long as the visual field is fairly good. I might mention n this connection that I have recently had made an excision of uperior ganglion of the cervical sympathetic nerve in a case which failed under myotics and iridectomy. Since this operation was made there has been no further deterioration of sight, al-hough I cannot say that there has been an increase in the field or acuity of vision. The eye looks better, however, and the man undoubtedly has less pain than before, and, as he says, he is in every respect better.

DR. CALLAN. — Dr. de Schweinitz is entitled to the thanks
this society for presenting his excellent paper. Dr. Kipp ha
anticipated me on one point as to whether simple glaucom
should be operated upon. I believe it should be, but I find that
large majority of my confreres depend upon myotics. I thin
the reason is that the results have been in the main so u
satisfactory; but the eye becomes blind if we do not operate, an
furthermore, the teaching of Von Graefe and others have be
to make a large iridectomy. I believe that this produces too mu
traumatism, and causes some of the failures. For four or fi
years I have been making very small incisions in the sclera two
three mm. from the limbus, and making a coloboma three
four mm. at most, and I think my results have been more sati
factory. With regard to the question of operating on hemo
rhagic glaucoma I am fully in accord with Dr. Gruening, but,
the same time, I have operated upon one patient of the kind wi
a good result.

The interesting point in Dr. de Schweinitz's paper is ho
soon we shall operate on the second eye. I think the patien
will not permit it very early, and I have not only to select t
bad eye for the first operation, but have to do a certain amount
teaching to get to do that operation.

DR. POOLEY. — I am very much disappointed that we did n
have the advantage of hearing the paper by Dr. Bull, as t
title was suggestively catching. The post operative history
fifty cases would go a great way in settling the question in m
mind if they came from such a man as Dr. Bull. I should al
want a report on fifty cases, not treated by operation, from so
careful observer. I am convinced that simple glaucoma shou
not be operated upon, but I am willing that the operation shou
be done by somebody else. I have never been able to convin
myself of the curative effects of the operations I have done f
simple glaucoma, no matter how careful I was.

DR. STANDISH. — The cases of simple glaucoma that ha
given me the greatest number of gray hairs have been the cas
that had rainbow rings, and no other symptoms. Every no
and then a patient reports seeing rainbow rings around the ele
tric lights, seen for a few minutes or hours, then disappearin
for a few months only to reappear again later. I have examine
two cases where this continued for several years, one wer

ound the world with his pockets filled with eserine, and with-
t any disaster. On the other was the case which Dr. de
hweinitz referred to, which gave me a great deal of anxiety; a
ight young man of thirty-five, very intelligent, and very care-
, had had nothing but rainbow rings for two years. He had
lepression of perhaps 1/3 of the central part of the nerve head,
t nothing that could be called pathological. Two years later
ck with tension, a shallow anterior chamber, a diminished
ld, and everything to indicate glaucoma. Another case that
ve me many regrets was an intelligent gentleman who had
attack of acute glaucoma while abroad, and one eye was
erated upon with disastrous results. I operated upon the
ıer eye on account of transitory rainbow rings, using the
aefe cataract knife, and the iridectomy was done carefully,
d without any slip, but during the night the lens was forced
t of the wound, and vision was lost. I operated under
caine in that case, but I never shall do so again, and when I
erate in glaucoma I shall use ether.

Dr. Williams. — What I shall say refers simply to simple
ıucoma where one eye has been lost, and it is a question what
ıll be done with the other eye which still has good vision. I
ow that my father, after many years of practice, and as the
ult of his own experience, concluded not to operate in those
ses. My own feeling is that the surgeon should tell the
tient that the operation may possibly check the progress of the
ease, that it is not likely to improve the vision permanently,
d may make it worse. If under such circumstances the patient
quests an operation I should perform it, but I should not ad-
e it.

Dr. Jackson. — Dr. de Schweinitz confined himself to a
nsideration of primary glaucoma But in practice it is a
tter of some difficulty to determine which cases are strictly
mary, and which are not. I recently saw a case where there
s no history of any active disease or injury, but one lens had
en opaque for some time. This eye had an attack of acute
ıucoma, and the lens came out in the course of the iridectomy,
hough the operator did not intend to extract it. The patient
me to me with pain and congestion of the other eye, and a very
allow anterior chamber. It was treated as one of commencing
tis, a diagnosis that was justified by applying the mydriatic
st without increasing the tension. In this case the glaucoma-

tous attack was probably secondary to changes accompanyin the cataract, although there was no history of such change

If an eye was unaffected, as shown by careful testing, I thir I would not operate. As long as there is no distinct eviden that the second eye is pathologic I should wait. With refe ence to the subjective symptoms I would not accept them alo as sufficient evidence of glaucoma to justify operation unle they were clearly relieved by a myotic; and then I think the e dence is positive and sufficient. It seems to me that prima glaucoma is not bilateral in all cases, a sufficiently large pr portion of cases to justify us in operating on one eye simply b cause the other has been affected by glaucoma. I recall tv cases of primary glaucoma in which the second eye has remain normal after several years.

I should in simple glaucoma rather advise the earliest po sible operation where the second eye showed any distinct e dences, such as limitation of the visual field, increase of tensi under mydriatic, etc., but I should want to explain the situati to the patient, and have him take the responsibility.

DR. KOLLER. — I know a case of inflammatory primary gla coma where fifteen years has intervened before the second e was attacked, and that was only a prodromal attack which w controlled by myotics, and a number of years has again elaps without any further trouble. I think many of us may kn of similar instances.

DR. HARLAN. — It seems to me the question brought forwa is very much one of terms. We are speaking of simple gla coma with and without tension, but it always appears to r that glaucoma without increase of tension is very much li Hamlet with Hamlet left out.

DR. RANDALL. — I think we of small experience owe a de of gratitude to Dr. de Schweinitz for bringing out this d cussion this afternoon. I have been trying to recall from my e perience the number of cases in which the glaucoma has be bilateral, and I cannot think of a single instance. The presen of rainbow rings without other symptoms is very common, a I have certainly had it myself for a long time without thinki that it means glaucoma, although astigmatism against the rule appearing. I differ with Dr. Theobald, however, in regard to t refraction in that I believe its existence and change is in ma

f these cases secondary to the increase of tension. Java's astig-
natism was changing for years before the onset of his glau-
omatous symptoms.

Dr. Wadsworth. — The discussion has taken a somewhat
ide range from the point referred to in the title of the paper.
he point that interests me chiefly is the matter of operations
what is called simple glaucoma, but I do not feel that I know
xactly what many of the gentlemen who have spoken think
bout it even now. I do not feel sure that we mean exactly the
ame thing. What I should call simple glaucoma is a condition
which the anterior chamber is not shallow, the pupil is freely
ovable, and there is but very slight and temporary increase of
nsion if, indeed, there is any. There may be halos, but the
ain point is the cupping of the disc, and the failure of sight
eripherically or centrally or with scotoma. In such cases as
at it has seemed to me that iridectomy is of practically no
alue, and is likely to do more harm than good. Whether this
efinition of simple glaucoma is a correct one may perhaps be
uestioned, but if it is I should not be operated on myself for
mple glaucoma, and could not advise it for others. Such cases
ay go on for many years before blindness ensues, and although
ne eye may be lost by the disease the other may show no dis-
rbance for many years.

Dr. Gruening. — I think after what has been said by the
hairman it is our duty to define our positions. I accept the
efinition given, and declare that I would operate in every such
ase, being guided by the patient's color perception. I make a
areful examination of the field, and if I find a scotoma and an
mpairment of color perception then I do not operate, but if the
olor perception is good I do operate, and from my observations
find that the vision often improves, the field is at times not
iminished any further, and useful sight remains frequently
hroughout life.

Dr. Harlan. — On what principle do you do the iridectomy?

Dr. Gruening. — On the principle that practical observation
as taught me that it benefits the patient, and until something
etter is proposed I shall do it. I have tried sclerotomies, and
ound them of no use whatsoever.

DR. THEOBALD. — Do you make a large or small iridectomy

DR. GRUENING. — I do a large one, and if the case is not im proved I do a second iridectomy adjoining the first. In on case I have performed five iridectomies on one eye. There ar several gentlemen present who know this case, and, althoug he now has no iris, he has vision of 1.

DR. RISLEY. — My own understanding of simple glaucom has been accurately defined by the admirable grouping of th symptoms given by the chairman. The first patient upon who I ventured to operate for this condition came to me in 188 Good vision has been maintained until the present time. In number of patients where it was necessary to operate upon bot eyes, but where the disease had made more progress in one tha the other, have seen blindness ensue from atrophy in the wors and vision preserved in the better eye by the iridectomy. It fair to suppose that the same favorable result would have bee witnessed in the worst eye if the operation had been performed the same stage of the disease. I am of the opinion that operatio is fully justifiable in patients presenting the symptom group outlined by the president.

DR. WADSWORTH. — Dr. Risley means when there is distin cupping of the disc.

DR. RISLEY. — Yes, if there is distinct cupping, even thoug it be limited to one side of disc margin.

DR. CALLAN. — Some years ago one of Haab's assistants r ported about sixty cases of simple glaucoma where the tensio had been taken several times a day, and it was found that th tension went up during the evening. Since then I have i structed some of my patients how to take the tension then selves, and they invariably tell me that from ten in the mornin until four in the afternoon they are fairly comfortable, bu toward evening the eyes become uncomfortable, and if the awaken during the night and take the tension it is found to b high. Some of those patients I can rely upon. Because patient has no tension when seen in the office is no reason fo saying it does not exist at times. There must be increase o tension at some time, otherwise how can we explain the excava tion of the nerve.

DR. DE SCHWEINITZ. — I have been very particular to stat that my paper deals only with primary glaucoma; hemorrhagi

glaucoma, with all due respect, is secondary glaucoma. To reiterate my reason for bringing so trite a subject before the society, I have to say that it was done with the hope that in the discussion some definite statements would be made as to how early one should operate in the cases of glaucoma, and if an operation had been done upon one eye, how soon it was justifiable to interfere surgically with the second eye, and I endeavored, believing that the disease is practically always bilateral, to point out certain signs which indicate, to my own mind at least, that the second eye was likely to be affected as was the first one. In the presence of these signs I believe, with many other surgeons, that surgical delay is unfortunate, and that the patient's chances are greatly enhanced by operative interference before the disease has declared itself, but I would like to point out that I am far from advocating operation, simply because a glaucoma has existed upon one side. Dr. Jackson has, I think, misunderstood me; I would operate only when any of the recognized tests showed that there was danger (and I quoted these tests), that the second eye would follow, or was following, the pathological course of the first one. I heartily agree with the chairman that it is most important that we should understand what is meant by chronic glaucoma, and in the opening of the paper particularly pointed out by means of definitions my own conception of this disease. In order that there shall be no misunderstanding on this point permit me to read again these definitions (here read definitions). While not in accord with Dr. Pooley's pessimism, I entirely agree with him that it is often useless to operate on chronic glaucoma when it has already reached late stages, and when the degenerative changes in the optic nerve and ganglion cells of the retina are far advanced, and I should in every case want the operator to be very sure that he was dealing with chronic glaucoma, and not optic nerve atrophy before he operated. Dr. Theobald says he thinks Dr. Bull could not have intended to say that iridectomy was valueless in the later stages of glaucoma. If I understood Dr. Bull, this is not what he said, but he agreed with me in the statement that an iridectomy which is to be permanently valuable should be done early, that is to say, before the iritic angle is abolished. If the case does not come at this favorable time temporary checking of the process, the relief of pain, and many other indications may be fulfilled by an iridectomy or other operation, even when the disease has long since passed the most favorable time for operative interference. I fully agree with Dr. Standish that the proper

anæsthetic for glaucoma operations is a general one, that either ether or chloroform. Colored rings of themselves are, course, not a sufficient indication for operative interference. Th occur under various circumstances, even physiologically, a are common when mucus fogs the cornea, or in iritis. They a one of the indications for operation only if they have the cha acteristics of glaucoma rings, and if they are proved to be in a sociation with increased intraocular tension. I desire to e press my high appreciation of the many courteous expressio which those who discussed my paper have been kind enough use.

METASTATIC CHORIOIDITIS OCCURRING IN TH COURSE OF PNEUMONIA, DUE TO GRIPP BASED ON A STUDY OF SIX CASES WITH TW AUTOPSIES.

BY CHARLES STEDMAN BULL, A.M., M.D.,

NEW YORK, N. Y.

The few remarks accompanying the reports of these cases are confined to the subject of metastatic ophthalmia curring in the course of pneumonia and endocarditis, due influenza, and have no application to other forms of metasta inflammation in the eye, due to the puerperal state or to gene septic poisoning, or to the epidemic form of cerebro-spi meningitis.

The diplococcus is known to be the cause of epiden cerebro-spinal meningitis, and it is probably the cause of t inflammation of the uveal tract so often met with in this disea These cases do not end in panophthalmitis, and I believe accurate report has ever been published of any microscopical e amination of such eyes.

Metastatic ophthalmia was first observed in cases of puer ral fever. It was subsequently met with in other forms of sep fever, and was described as pyæmic or phlebitic ophthalmia. 1856 *Virchow* discovered in a metastatic panophthalmitis cap lary emboli in both retina and chorioid. This discovery esta lished the fact that purulent chorioiditis does occur as a met

atic affection, and experience has since satisfactorily proved at both eyes may be attacked, one shortly after the other. he disease is always due to septic infection, and micro-organms can nearly always be found when the opportunity occurs to earch for them. The lesion in the eye is often closely depend- nt upon a general septic condition of the system, which is often tal, and which is always of such gravity as to overshadow the cal condition. The micro-organisms which have been found such cases are the staphylococcus albus and aureus, the reptococcus pyogenes, and the pneumococcus. Bacterial rombi have been demonstrated in the vessels of the uveal tract, tina, conjunctiva, ocular muscles, and orbital tissue.

We know that in very acute sepsis there is an absorption of large amount of the chemical products of decomposition, and mbolic suppurations are apt to occur. The septic embolism is pidly followed by suppuration, which may extend to the en- re eye in the form of panophthalmitis. The thrombosis some- mes comes from a microbic area, as in endocarditis or pneu- onia. Whether the obstruction occurs in a chorioidal or a tinal vessel can only be determined by the ophthalmoscope at he very commencement of the ocular symptoms. Later this fact an only be determined by microscopical examination.

Goh makes a rather fine-drawn distinction between septic tinitis and septic chorio-retinitis. He says that in septic tinitis there are no acute inflammatory phenomena present, for is not caused by the local infiltration of bacteria, but by a eneral blood disturbance of a toxic nature. By this blood dis- ntegration either the capillaries suffer by being deprived of their ndothelium and diapedesis occurs, or else marantic thrombi are ormed in the veins of the chorioid and retina. Such a throm- osis, however, he thinks is rarely the cause of septic retinitis hen occurring in the retina, but if it occur in the chorioid it nay favor the development of a metastatic inflammation by isturbances in the circulation, especially in the bilateral form f the disease.

Before *Goh* published his article it was well known that the

retina is peculiarly susceptible to pathological changes in dis-
eases of the general system, due to an alteration in the blood
and that the changes in the retinal vessels were secondary to th
alteration in the blood. Septic retinitis is more frequently me
with than panophthalmitis, and its course is relatively favorable
The foci are small and circumscribed, and the chorioid is rarel
involved. It is not due to the formation of emboli, for ob
structions of the retinal vessels have never been found. Hence
the retinal foci are dependent on some chemical change in th
blood. In cases of thrombosis, however, the heart's action i
very weak; and the vascular wall, in consequence of the change i
the quality of the blood due to the septic process, loses its norma
condition, and this is what we find in the chorioidal veins in on
or both eyes, the lesion being defined as marantic thrombi. Th
frequent bilateral character of metastatic chorioiditis is explaine
in part by the narrowness of calibre of the capillary vessels, an
in part by the disposition to clot-formation.

Large infectious plugs, which cause a stoppage of the large
vessels, are only occasionally thrown off into the circulation dur
ing the course of a pyæmia. The smaller embolic material i
much more commonly spread through the general circulation
and takes its own course independently of the method of divisio
of the larger or smaller arteries. The smaller the vessels th
greater the danger of these smaller clots being arrested. In th
region of distribution of the carotid arteries it has been assume
that metastases are generally rarer than in the internal organ
of the body and in the extremities, and the ophthalmic artery
would naturally share in this assumption. Only about one
eighth of the amount of blood in the ophthalmic artery goe
to the eyeball, which is therefore an organ poor in blood com-
pared to its size. The eye seems less receptive of more com-
pact plugs, and more disposed to the occurrence of capillary em-
boli.

It has been assumed that the occurrence of metastatic oph-
thalmitis signifies that the general disease has taken on a par-
ticularly severe type, but this is doubtful, for if true, the ocular

metastasis must then be regarded as of peculiar and unusual importance, and would have a marked prognostic significance.

The frequent bilateral appearance of metastatic chorioiditis, like all bilateral internal ocular lesions, must be regarded as a symptom of a general constitutional condition. In such cases we should expect to find numerous metastases in other parts of the region of distribution of the carotid arteries.

We possess almost no satisfactory anatomical investigations as to what part is played by the eye in the development of metastases. We know that metastatic ophthalmia is met with in influenza, scarlatina, measles, diphtheria, variola, varicella, parotitis, and more rarely in erysipelas and typhoid fever. Of late we have known that it is still more frequently met with in pneumonia and endocarditis. The irido-chorioiditis, which sometimes occurs in recurrent fever and in rheumatism, is an infectious disease, and may be suppurative, but it never leads to suppuration of the eyeball. The same may be said of the so-called gonorrhœal metastases. Most of these patients do not die, but recover their general health. Hence, we have no opportunity for anatomical investigations.

Unilateral isolated metastatic ophthalmia differs in no way from similar isolated purulent foci in other parts of the body, and is not of such vital significance as the bilateral form of the disease. In the rarer form of metastatic inflammation, orbital cellulitis, the exciting cause is the pneumococcus, which has been found in great numbers in the orbital cellular tissue. If the pneumococcus enters the eyeball, the inflammation excited usually runs a mild course, and the cocci, which have formed foci of disease, subsequently disappear.

The disease, as presented in the six cases which form the basis of this paper, is characterized by pain in the eye and head, intense vascular congestion, with the usual symptoms of chorioiditis, or irido-chorioiditis, and rapid and total loss of sight. It may be ushered in by severe headache and vomiting, rise of temperature, and general febrile symptoms. The intraocular tension is at first increased, but subsequently sinks much below

normal, even when no perforation of the eyeball occurs. The course of the disease is from three to six weeks, and the prognosis is always bad, the case ending in total blindness with a shrunken eyeball. Enucleation of these eyes is not advisable in the acute stage of suppuration, especially if the capsule of Tenon or the orbital tissue be involved, owing to the possible danger of meningitis developing from entrance of the micrococci into the channels leading to the brain. In these cases evisceration of the eyeball will often give relief from the severe pain.

CASE I. The patient was a boy, aged 14, whom I first saw on January 7, 1901. Three months before he had a severe attack of grippe with high fever, which, on the third day, culminated in pneumonia of the right lung. He was delirious for several days, and when he regained consciousness he was blind in both eyes, and remained so for four days. The sight then began to return in the left eye, and rapidly improved, but the vision in the right eye has never been restored. He consulted an oculist who told him that the right eye had been lost by suppuration and a yellow reflex was noticed from the pupil. Two days before I saw him the blind eye became red and very painful, and for this he came to the eye infirmary. There was then marked ciliary injection, the iris was irregularly dilated and immovable with posterior synechiæ on the nasal side, and was discolored and of a greenish hue. The cornea and lens were clear, except at the periphery of the latter. The tension was —2. There was a very shallow anterior chamber, and the iris bulged at the periphery. There was a yellow reflex from the fundus, with several large vessels running over it. Under the ophthalmoscope the vitreous was seen to be clear of opacities, and the infiltration involved the chorioid, and probably the retina also throughout the entire fundus as far forward as could be seen. Vision in the left eye was 20/40, and the ophthalmoscopic picture was negative. Assuming that the cause of the chorioiditis was the occurrence of one or more arterial or venous obstructions of microbic origin, the comparatively short duration of the blindness in the left eye may possibly be explained by the fact that the vascular obstruction

n the left eye may have been of small size, and that it broke p into smaller masses, and passed on in the circulation before ny suppurative process began.

CASE II. The patient was a man, a machinist by occupation, ged 32, whom I first saw on January 22, 1901. On Decem- er 18th he was taken ill with symptoms of grippe, which, in wo days, rapidly developed into pneumonia of the right lung. On the eighth day of his illness, the right eye became in- amed with severe pain, great swelling of the lids, and rapid oss of sight. In three days the vision was completely abolished, nd there has been no perception of light since. The left eye emained intact, and the vision, when tested, was normal. When first saw him the swelling of the lids had nearly disappeared, nd the eyeball was somewhat flattened and shrunken. There as no perception of light, and the tension was —2. The cornea as slightly hazy, the iris was discolored and sluggish, and the ens was clear. There was a dense yellow reflex from the fundus, hich extended forward to the ciliary region, over which the etinal vessels could be distinctly traced. The eyeball had per- orated below in the inferior quadrant, just back of the ciliary egion, and some thin pus was discharged from the inferior cul- e-sac. This pus was examined microscopically, but no bacteria ere found in it.

CASE III. This patient was a gentleman, aged 42, of frail hysique and delicate health, whom I first saw in February, 1899. He was attacked with grippe, which rapidly assumed a serious spect. Pneumonia developed on the third day, and advanced so apidly that in forty-eight hours the whole right lung became onsolidated. On the morning of the fifth day from the com- nencement of the attack the vision of both eyes became affected, nd I was sent for. I saw him within two hours after this was oticed, and in both eyes discovered a focus of disease in the horioid just above the region of the macula, the media still being erfectly clear. Six hours later I saw him again, and found the vitreous of the right eye so cloudy that no details of the fundus could be made out. The vitreous of the left eye was clear, and

remained so until the end, but, instead of one focus of chorioidal disease, there were four foci in different parts of the fundus, all posterior to the equator. The next morning I found the right eye entirely involved, with iritis, pus in the field of the pupil, conjunctival chemosis, and the general appearances of a panophthalmitis, with severe pain, and no perception of light. In the left eye the entire fundus presented a yellow reflexion as far forward as could be seen with the ophthalmoscope through a dilated iris. The iris itself was not involved, and the picture presented was that of a purulent chorioiditis, with a clear vitreous. In the afternoon of this day the left lung became involved, and the patient rapidly sank, and died early the next morning, seven days after the attack of grippe began, and five days after the right lung first became involved. By the kindness of the family I was permitted to remove the right eye for examination. The eyeball was enucleated in the usual manner, and, after being hardened, was divided nearly in the vertical meridian, the incision passing vertically through the optic nerve. The two halves of the eye were then embedded, and about fifty sections were made, stained and mounted for examination. All the tissues of the eye, with the exception of the lens, were filled with pus cells. In the sclera, chorioid, retina, and optic nerve were numerous lacunæ filled with blood cells.

Numerous veins and arteries in the retina, chorioid, and sclera were plugged with emboli. This was especially noticeable in the retina. There were only a few recognizable rods and cones in the bacillar layer, but the nuclear layers were greatly thickened. The retinal pigment cells were scattered in groups of varying size in the midst of masses of granular exudation. There were groups of pus cells all through the ciliary body and in the vitreous. The chorioid and retina were practically but one layer, as the line of union between the two was obliterated. The micrococci present were the staphylococcus aureus and the streptococcus, and they were found in large numbers in all the tissues, not only in the purulent areas, but also free in the

vessels where they formed the main constituent of the thrombotic and embolic plugs of obstruction.

CASE IV. This patient was a gentleman, single, aged 42, who had always enjoyed excellent health, and being a man of means had led a healthful, out-of-door life. He was a man of very temperate habits, and denied ever having had any venereal disease. About six months before I saw him, after exposure for many hours to a cold rain storm while on a hunting trip, he contracted an acute inflammatory arthritis of both knee-joints and the left shoulder joint, which confined him to his bed for six weeks. He had rather a mild endocarditis, which had yielded to treatment, but left him with a mitral murmur. I saw him early in March, 1898, and he then had a rather aggravated conjunctivitis with moderate secretion. This yielded slowly to treatment, but two weeks later he contracted influenza, whch showed a high temperature, and on the fifth day pneumonia of the right lung developed. The disease rapidly extended to the entire lung, and his heart began to labor painfully, with decided irregularity and marked intermissions of the beat. On the fifth day after the pneumonia first appeared, the right eye became red and very painful with swelling of the lids and chemosis of the ocular conjunctiva. On the sixth day three foci of suppuration were discovered in the chorioid in the vicinity of the posterior pole, the anterior chamber became shallow, and the aqueous humor turbid. The foci of chorioidal exudation rapidly grew larger, coalesced, and in twenty-four hours the whole fundus was involved, and gave back the characteristic yellow reflex. The next day the whole uveal tract was involved, and there were a number of hemorrhages on the surface of the iris. The tension was at first very much increased, but as soon as the iris and chorioid were involved the tension sank below the normal, and continued about T — 2 until the end. There was a trace of exophthalmus, but no other evidence of orbital cellulitis. The patient rapidly sank into a septic condition, and finally died of failure of the heart's action. The left eye remained intact throughout. No autopsy was allowed. The marked feature in the case was the very

rapid extension of the suppurative process in the chorioid after the appearance of the three foci of disease, and this feature seems to be characteristic of this form of chorioiditis.

CASE V. This patient was a young lad, aged 15, whom I first saw in December, 1899. He had always shown a marked tendency to contract the various contagious diseases of childhood, and had suffered from measles, whooping cough, mumps, diphtheria of a mild type, and scarlatina, which left him with diseased kidneys, and albumen and casts in his urine. He contracted grippe for the third time early in December, 1899. It was a rather mild attack, except for a high temperature (104⅖°). There were no thoracic symptoms, except a bronchial cough, until the eleventh day, when consolidation was discovered over a limited region at the base of the right lung. The pneumonia pursued an asthenic, sluggish course, but the consolidation gradually extended to a larger area of the lung, and the patient grew weaker. On the sixth day after the appearance of the pneumonia, the patient complained that the sight of both eyes was affected, and I was sent for. There was a slight ciliary injection and a muddy iris on both sides, but the aqueous and vitreous were clear. The ophthalmoscope showed a large focus of infiltration in the chorioid just above the macula in the *left* eye, and four distinct foci of disease in the chorioid of the *right* eye. These latter rapidly coalesced, and in about fifty hours the entire fundus of both eyes showed the characteristic yellowish reflexion. There were no signs of orbital cellulitis, but in two days both eyes were entirely blind. The high temperature persisted from the beginning, but the process of consolidation was apparently confined to the lower lobe of the right lung. The heart's action was feeble throughout the attack, but there were no signs of endocarditis. The lad slowly sank, and died on the ninth day after the pneumonia was discovered. No autopsy was permitted.

The case is interesting from the marked difference shown in the inflammatory process in the lung and in the eye. The pneumonia was confined to the lower lobe of one lung, and pursued

ts course slowly and without any very marked symptoms except he high temperature. The metastatic chorioiditis showed the apid progress characteristic of the lesion, ending in total destruc-ion of the vision in both eyes in forty-eight hours.

CASE VI. The patient was a man, aged 40, whom I first saw n March, 1897. He had had a rather mild attack of influenza, nd was supposed to be convalescing when, on the ninth day, a uspicious rise of temperature occurred, and he began to cough. An examination of the chest showed some consolidation at he base of the left lung. He was kept in bed and carefully vatched, but the area of consolidation rapidly extended, and in hree days involved the whole of the lower lobe, and had in-vaded the upper lobe. On the sixth day after the pneumonia leveloped he complained of failure of vision in the right eye. saw him about six hours later, and found three small foci of nfection in the chorioid, one on each side of the optic disc, and one directly at the macula. The media were perfectly clear, the ris was normal in appearance and reaction, and the fundus of he left eye was normal. I examined him again the same even-ng, and found that two of the foci had increased in size, and coalesced. The media were still clear, and the rest of the fundus showed no infiltration. The left eye was still intact. The next morning there was a marked change. In the right eye the whole chorioid was infiltrated nearly to the ciliary processes, and the vitreous was slightly cloudy in its posterior part. The iris was not involved, but there was a vivid ciliary injection and engorge-ment of the deep episcleral vessels as far back as the equator. In the left eye there was a well marked iritis with adhesion to the lens capsule on the nasal side, and a very large focus of infection in the chorioid in the equatorial region on the nasal side. The disease pursued a very rapidly destructive course. In the left eye the pupil was blocked by exudation on the next morning, and by the evening of this day there were all the signs of a septic panophthalmitis with some exophthalmus, and very severe pain. In the right eye there was no iritis, but the whole chorioid was involved, and the vitreous was very cloudy. On the

fourth day after the beginning of the chorioiditis the left eye perforated in the ciliary region below, and the pain then became less severe. There was no perception of light in either eye. The whole left lung was involved, and the patient died comatose on the twelfth day after the first development of the pneumonia. An autopsy was made twenty-four hours after death, and I was permitted to remove the posterior portions of both eyeballs together with the optic nerves and chiasm. There was a very general congestion of the blood vessels of the brain both on the base and the convexity, but no exudation, and no signs of meningitis.

After hardening the halves of the eyeballs and optic nerves the latter and the chiasm were first carefully examined macroscopically, but there was no exudation within the sheath, nor any signs of optic neuritis, and this was confirmed by microscopical examination of many sections. Numerous plugs were found in the smaller vessels of the chorioid and retina in the right eye, and in the left eye every section showed these plugs all over the field in almost every chorioidal vessel. The autopsy also revealed a septic endocarditis, which had not been suspected and here were found numerous streptococci and pneumococci.

In this case the left lung and heart were the seat of the infection. The right eye became first involved, presenting the picture of infectious chorioiditis, while in the left eye the first lesion was an iritis rapidly followed by a general chorioiditis and panophthalmitis with perforation.

DISCUSSION.

DR. MITTENDORF. — I would like to ask whether severe pain has been one of the most prominent features of these attacks. I remember that I have been obliged once or twice to enucleate an eye on account of the extreme suffering of the patient.

DR. KNAPP. — I think this paper is of great importance as it adds a new disease, so far as I know, for the development of metastatic chorioiditis, and it is not strange that it should, for it has been shown that grippe is one of the diseases that is prone to produce metastatic inflammations.

DR. POOLEY. — I would like to ask if Dr. Bull became acquainted with any cases in which metastatic chorioiditis occurred in grippe without pneumonia?

DR. BULL. — In all of these cases there was pneumonia, the chorioiditis following. Very severe pain was not a characteristic symptom in four of these cases, in two it was severe.

DR. WADSWORTH. — I would like to ask Dr. Bull if he has seen lighter cases of ocular affections following the grippe? I have seen in the last two or three years several cases of exophthalmus coming on a week or two after the initial attack of grippe without pneumonia, in two occurring in both eyes, one being affected after the exophthalmus of the other had begun to subside. The cases recovered, and the eyes were left normal.

DR. BULL. — I have seen one case in which there was bilateral exophthalmus with no other symptoms except, possibly, a little ocular chemosis, but no interference with the media of the eye, and a subsidence without leaving any permanent symptoms. I think we have all seen cases of simple iritis and corneal complications in grippe which subsided leaving the eyes more or less intact.

DR. KOLLER. — I wish to say that years ago when the first grippe epidemic swept this country I saw a case of exophthalmus and chemosis where the ophthalmoscopic picture was one of neuro-retinitis, but the case healed all right with perfect vision. I reported that case with two others at a meeting of the New York Academy of Medicine as cases of neuro-retinitis due to grippe. It may be that some of these lighter cases which Dr. Wadsworth had in mind may be a lighter form of the same disease that Dr. Bull has described today as a metastatic chorioiditis.

DR. BULL. — These are not the first cases of metastatic chorioiditis following pneumonia that have been reported, and I make no such claim. There are a number scattered through the literature of the last few years. The important fact in these cases to me was that I had the opportunity of securing post mortem examinations.

DR. GRUENING. — I think another important feature of these cases is the fact that Dr. Bull had the privilege of studying them in their early stages. I have seen only one case in which there was any pain.

DR. BULL. — I think in the cases where pain is severe the condition is usually a panophthalmitis, and if the trouble is confined to the chorioid there is little or no pain.

DR. WADSWORTH. — In regard to Dr. Koller's remark I think it is quite possible that the cases of exophthalmus may be light forms of sepsis, but in the case which I saw there was no disturbance in the interior of the eye.

A CASE OF ADENOMA OF THE MEIBOMIAN GLAND WITH A SYNOPSIS OF WHAT IS KNOWN ON THAT KIND OF TUMOR.

BY HERMAN KNAPP, M.D.,
NEW YORK CITY.

About two years and a half ago I was struck by the peculiar aspect of a tumor of the right upper eyelid in a woman, 4 years of age, of 201 Canal St., Brooklyn, N.Y. The upper lid was thickened and partly coarsely, partly finely nodular. The skin was normal, thin, elastic, movable over the tumor. The substance of the latter had the hardness of cartilage, was mostly of a peculiar *yellowish-white* color, not unlike old ivory. It was, at that time rather anæmic; the yellowish nodules shone through the skin having replaced the orbicular muscle. The nodules were gathered in irregular, smaller, round, or oblong masses; the larger ones, however, had no even surface, but were divided and subdivided into smaller ones. On turning the lid it was clear that the whole mass was an aggregation of hypertrophied meibomian glands. The bunches of acini around a larger duct themselves again dividing into secondary and tertiary bunches, reproduced the picture of the normal glands, which, from uniform resistance from the eyeball, presented an even surface. On the inner surface the lack of vascularity was more conspicuous than on the outer. The degeneration was not uniform over the whole tarsus, but more pronounced in some places than in others forming little tumors projecting over the others. At different

imes I excised those that were most prominent. This did not mprove the condition, as the neighboring portions grew slowly, nd occupied the place of the others.

About a year ago I removed a larger piece of the outer part f the lid, nearly one-third of the whole mass, yet left so much t the inner surface (which was less involved than the outer, and till covered with healthy conjunctiva), as to support the lid and rotect the cornea. The relief was only temporary.

Seeing that the growth of the tumor was irresistible, I re- noved radically the whole mass June 5, 1901. The entire tarsal ortion of the upper lid was taken away, which left only a arrow strip of skin and mucous membrane behind. The mass as rigid and curved, and, on looking at it from below, it pro- ected over the healthy cornea like the stiff curved visor of a elmet. In order to protect the cornea, I pared the outer half f the free margin of the lower lid and stitched it to the upper; urthermore I kept the lower lid over the cornea in stitching it to ne upper, but without paring its margin. In four days I re- noved the stitch from the latter portion, and in seven days the utures from the temporal half, as there now was a firm organic nion between the two lids. There has been no ulceration of ne cornea. I had to cut away some granulation tissue from the ree edge of the nasal portion of the upper lid. Thus far, July 5, 1901, no relapse of the growth has been visible, but the time s too short to know whether there will be none later.*

YNOPSIS OF CASES OF ADENOMA OF THE MEIBOMIAN GLANDS.

1. *E. Fuchs* Gräfe's Arch. f. Oph., XX, p. 158, 1878. Adenoma of sebaceous or meibomian glands. Tumor the size of pea from upper lid. Capsule septa penetrating into the tumor, he acini filled with degenerating cells, like the sebaceous or milk glands.

2. *Baldauf*, Inaug. Dissertation, München, 1870 (quoted in Klin. Mon. für Aug., 1890, p. 396). Woman, aged 59. Tumor after growing four years occupied two-thirds of the tarsus of the

* None has occurred up to Oct. 18, 1901.

right lower lid. Examination warranted the diagnosis of a true adenoma, according to Förster. "A perfectly benign neoplasm, consisting of simple hyperplasia of glandular structure."

3. *Bock*, Wien. Med. Woch, 1888, No. 59. Woman, aged 62. On the inner surface of the upper lid a pale red, nodular, doughy tumor, found under the microscope to be an adenoma originating in the meibomian glands.

4. *Rumschewitsch*, Klin. Mon. f. Aug., 1890, p. 401. Growth of twenty years, temporally from the right lower lachryma punctum, a roundish tumor the size of a small pea, of four years standing, united to the tarsus and skin, immovable, pale yellow rather hard. Miroscopic structure of glandular tissue, but without a lumen.

5. *Rumschewitsch*, l. c., p. 407. Tumor size of a pea, 4 mm above free border of lid. Structure of meibomian glands (with fatty degeneration in the acini), and an excretory duct into which lateral ducts enter.

6. *Maxim. Salzmann*, tumors of the lids. Arch. of Ophth. 1891, p. 380, with five figures (Germ. Ed. — Arch. f. Aug., Vol XXII). Woman, 80 years; after a year's growth, large tumor hanging down beyond the margin of lower lid. Uneven surface yellowish, hard in some places, soft in others. Neighboring glands not enlarged. The tumor was removed. It involved the inner and middle thirds of the upper lid, 3 cm. high, 5 × 2 cm broad. The wound was covered with a quadrilateral flap from the cheek. Healing normal.

The tumor is situated between skin and tarsus, replacing the orbicular muscle. It consists of irregular, anastomosing lobules separated by fibrous septa, the whole encapsuled. The lobules are much larger than the normal meib. acini. The tumor has the structure of the meibomian glands, its cells are round or oval mostly polygonal from pressure, with no intervening substance and no blood vessels.

7. *O. F. Wadsworth.* An adenoma of the Meib. Glands Trans. Am. Ophth. Soc., XXXI, 1895, p. 383. Lad of eighteen years, operation for removal four years previous to admission to

lass. Char. Eye and Ear Inf. 1894; since that time growth grad-al. The tumor was situated at the middle of the upper lid, in-olved considerably more than half its width, the whole height of ıe tarsus, and overhung the lower lid. About half the tumor lay elow the level of the cilia. It measured 25 mm. vertically, 20 ım. horizontally, and 15 mm. in thickness. Anterior surface, overed with fairly normal skin, irregularly nodulated; the nodules f slightly yellowish color, and faintly umbilicated. The whole ımor was cut out, and the large gap covered by a lateral sliding ap. Wound healed by first intention. Microscopically the rowth consisted of a great number of glands resembling se-aceous glands. Many of them were dilated into larger or naller cysts containing the remains of degenerated cells. Diagnosis: "An adenocystoma originating in a meibomian gland July 18, 1901, at the meeting of the Am. Ophth. Soc., Dr. Vadsworth said that the patient had been lost sight of so that ıe further course of his case was unknown)."

8. *Herman Knapp*, the case detailed above.

9. *Jackson M. Mills'* case, not yet published. About eighteen ıonths ago I saw a case like my own at the ophthalmic clinic of ıe N. Y. College of Phys. and Surgeons. It was under the are of one of the assistants, Dr. Jackson M. Mills, who con-dered it to be a sarcoma. I had no doubt that in its nature it as identical with mine, but being in a more advanced stage. Dr. Iills removed the tumor, which occupied the whole upper lid. The cornea was ulcerous, soon sloughed, and the eyeball had to e removed. Later smaller and larger disseminate tumors de-eloped around the eye and on the same side of the neck. They ere removed at the Roosevelt Hospital, but soon relapsed. Under the microscope the original palpebral tumor, as well as ıe metastatic ones, showed the structure of sarcoma and car-inoma into which the lachrymal, parotid, and other glandular umors usually degenerate.

A CASE OF SARCOMA OF THE CHOROID, FOLLOWED BY PHTHISIS BULBI, AND TWENTY YEARS LATER BY PERFORATION OF THE ANTERIOR PART OF THE GLOBE AND RAPID GROWTH OF THE NEOPLASM.

BY CHARLES J. KIPP, M.D.,
NEWARK, N. J.

The patient from whom this eye was removed was first se by me in 1877, twenty-two years before I enucleated the e The patient was at that time sixty-four years old and in go health. A few days before she consulted me she had notic for the first time that she was unable to see with her right e Some weeks before, this eye had suddenly become very red, b as she had no pain she paid no attention to it and the redn passed away in a few days. When I saw her there was no inj tion of the conjunctiva and there were no other inflammato symptoms. The cornea was clear, the anterior chamber of n mal dimension, the iris normal in appearance. The pupil w small. After dilating the pupil by atropine the retina was fou to be detached totally, but still transparent, and in the posteri part of the eye were seen two semi-globular masses of dark col one springing from below and inwards and the other from o ward and above. Each projected toward the axis of the eye wi its convexity. Vessels could not be made out on the surface the dark colored masses. The disk could not be made out, a only a red reflex could be obtained from the parts not hidden the dark masses. The tension of the eye was normal. The oth eye was healthy. I made the diagnosis of tumor of the chor and told her to come again soon for another examination. S returned in about three months. At this time several opaq bands with smaller vessels on them were seen in the anterior p of the vitreous by oblique illumination. The detached reti

vas now opaque and the dark masses could no longer be seen. Otherwise there was no change in the appearance of the eye. I advised enucleation, but my advice was not accepted. Sixteen years later the patient consulted me again because her left eye was becoming blind. The notes made at this time stated that the right eye was atrophic, the cornea opaque and flat, that this eye is often painful but is not tender to the touch. The left eye I found to have incipient cataract, and the vitreous was full of floating membranous opacities. The disk and retina, as far as could be made out, were normal. Vision was reduced to 1/60. I was unable to ascertain from her just when the shrinking of the right eye had commenced. All that I could learn was that her eye had been very red and painful about a year after I saw the patient, that the inflammation had lasted many months, and that the eyeball had been smaller since then. It is therefore impossible to say whether a secondary glaucoma or iridocyclitis caused the shrinking of the globe, and the appearance of the cornea did not enable me to make out whether it had been perforated or not. I again advised enucleation of this eye and prescribed iodide of potassium for the other. After this consultation I did not see the patient again for six years. She returned in November, 1899, and her reason for visiting me was that she was fast losing strength in consequence of persistent hemorrhage from the right eye. At this time I found a large fungoid mass, somewhat of the shape of a mushroom, protruding through the palpebral fissure of the right eye, which on closer examination was found to be adherent to the anterior part of the shrunken globe and to move with it. The left eye was in fairly good condition. The cataract had not progressed much, and the vitreous was much clearer than at the previous visit. On inquiry I learned that a darkish mass was seen on the anterior part of the eye about a year before, that is, twenty-one years after her first visit to me; that it had grown steadily since that time, and that it had bled a good deal for the last three months. She was now willing to have the eye removed. I enucleated under ether on the following day. The wound healed in a week,

and since then there has been no local relapse (July, 1901). She had an attack of hemiplegia last year, but has partially regained the use of the paralyzed arm since then and is otherwise in fair health. Since the operation she has been entirely free from the pain in the head from which she had suffered for more than twenty years.

The anatomical examination of the enucleated globe shows it to be greatly shrunken, most so in its anterior portion.

The sclera is in part greatly thickened and wrinkled and the lamina cribrosa is also much thickened. The cornea, iris, and ciliary body are totally destroyed, and no trace can be found of the retina and choroid. The short globe is completely filled with a melanotic mass which seems to have perforated the sclero-corneal junction and spread out on the exterior part of the globe in the shape of a mushroom. The growth is a melanosarcoma in which spindle cells prevail. A more detailed microscopical examination will be published.

We have here, then, a case of sarcoma of the choroid which caused phthisis bulbi. There is of course a possibility that the dark colored semi-globular mass projecting into the vitreous chamber from the sides of the fundus which I saw on her first visit to me may have been masses of blood, but it is much more probable that it was a new growth. I do not think that blood clots would have that shape and be situated behind the detached floating retina. The case throws no light on the cause of the phthisis, and it must remain unsettled whether it was due to secondary glaucoma or an iridochoroiditis or to perforation of the cornea. Whether the growth of the neoplasm was hindered by the phthisis is also uncertain. It certainly was of an uncommonly slow growth for over twenty years, though it grew with great rapidity after it had perforated the anterior part of the globe.

It is not my intention to review the literature of this subject at this time, but shall only mention that Leber and Krahnstöver (Archiv. für Ophthalmologie, Band 45, p. 64) have lately studied the cause of phthisis of eyes containing sarcoma, and while they

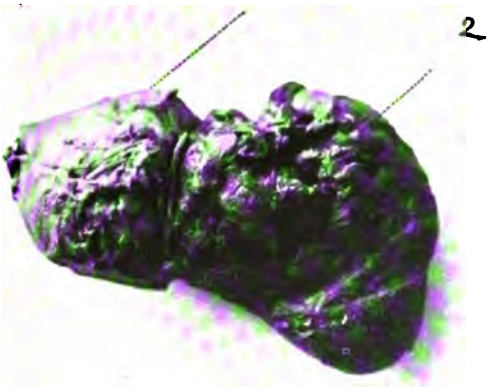

1 — Globe. 2 — Tumor.

Lower half. Globe and extra-ocular tumor.

KIPP. — Sarcoma choroid (⅔ natural size).

re inclined to the belief that it is due to an iridochoroiditis which is caused by the products of decay and degeneration of the neoplasm and by micro-organisms, they say that further evidence s necessary to prove this. As yet no one has been able to prove he presence of micro-organisms in such cases. Evetzky (ibid, . 563), who studied this subject about the same time as Leber nd Krahnstöver, but independently of them, holds similar opinons as to the cause of the phthisis. His fifth case was somewhat similar in its history to the one related here, but the growth ad caused greater destruction of the eyeball when it was removed.

DOUBLE PANOPHTHALMITIS AND SEPTICEMIA FROM ABSCESS OF THE KNEE.

BY EDWARD JACKSON, M.D.,
DENVER, COLO.

It is rare in rapidly fatal disease to have the ocular symptoms vershadow all others, and give the most positive and valuable vidence of the impending danger to life. The following case as of this character. It occurred at the Arapahoe County Hosital during my last term of service, and was at first regarded by he interne and others who saw it as a case of purulent conunctivitis, a diagnosis that had a good deal to excuse it.

P. P., female, aged about 45, a light mulatto, a native of outh Carolina, was admitted to my service January 25, 1901. The only history obtainable was of inflammation beginning imultaneously in both eyes nine days previously. Within five ays she had become absolutely blind. She was said otherwise ot to have been sick; but we subsequently learned that she had een ailing for a couple of weeks. The left knee was somewhat wollen and painful; and there were several large blebs on the ight foot and ankle. There was a fetid, purulent discharge from he vagina, but the patient denied any history of venereal disease.

Repeated examinations failed to reveal the gonococcus in either the conjunctival or vaginal discharges. On admission her temperature was 99.5°, and pulse 120°. The pulse did not rise above this; respiration continued at 24, and her temperature did not again go above normal until a few hours before her death, when it rose to 102°.

There was no rigor, and no excessive sweating. The urine contained some pus and some granular casts, had a specific gravity of 1014, and was fairly abundant. The patient's mental condition was apathetic. She continued conscious until just before death, and answered rationally, but quite sluggishly, the questions put to her. She insisted that there was very little the matter with her, except her eyes; and blamed the doctor who had first attended her for her loss of sight. She gave no evidence of pain, except when the swollen knee or one of the eyes was pressed upon.

The lids were moderately swollen. The conjunctiva was extremely chemotic, folds of it protruding between the lids. Both eyes were absolutely blind, with all the evidence of panophthalmitis. The conjunctival discharge was quite moderate. The corneas were but slightly turbid. But there was some hypopyon and extensive suppuration back of the lens. The right eye showed tension plus 3. The left eye was soft, the cornea having perforated near its lower margin, allowing free exit to pus from the interior of the eye.

The inflammation had so clearly arisen from the posterior segment of the eyeball, indicating a probable embolic or septic origin, that my colleague, Dr. J. N. Hall, was asked to see the patient. His careful examination revealed only a few minute petechial hemorrhages, which he regarded as also pointing strongly to a septicemia. The treatment of the eyes was confined to cleansing with a two per cent. solution of protargol. Her condition remained practically unchanged until the morning of the 28th, when the signs of commencing septic pneumonia were found by Dr. H. B. Whitney. She died at 2 P. M. that day.

Post mortem examination made by Dr. J. A. Wilder showed decided hypostatic pulmonary congestion, but no solidification. The heart and great vessels were normal. The uterus and appendages were normal. The only origin discovered for the septicemia was in the left knee joint, which was filled with pus. The right kidney was normal, the left slightly enlarged, and the capsule stripped with some difficulty.

In this case, although it came into the hospital as one of purulent ophthalmia, the appearance of the eyes at once demonstrated that it was a purulent retinitis or choroiditis, which, from its character and simultaneous involving of both eyes, must almost certainly have arisen from grave septicemia. Although the temperature and general symptoms gave little assistance in the diagnosis, the eye symptoms seemed sufficient to make it fairly certain from the first.

The origin of the sepsis, however, was only cleared up at the post mortem examination. Up to the time of death, although no physical signs of it were discovered, a septic endocarditis seemed the most probable explanation. A possible focus of infection in the genital organs was also thought of. The absence of distinct uremic symptoms and the fairly good general character of the urine led us rather to exclude kidney disease as an important factor in the case; and the post mortem examination showed no grave organic changes in the kidneys. The microscopic examination showed the absence of the gonococcus from the pus contained in the knee joint.

PRIMARY TUBERCULOSIS OF THE IRIS.

BY N. J. HEPBURN, M.D.,
NEW YORK CITY.

The chief reason for reporting this case is the apparent comparative rarity of the affection, and the extreme difficulty of tracing the possible source of infection.

R. A. D., aged four years, was brought to me on November 10, 1900, with a note from his medical attendant that the patient had been suffering from keratitis in the right eye for about two months, which was very obstinate, and had refused to yield in any degree to the ordinary methods of treatment. The boy was apparently in good condition, bright and active, living in the country, parents in fair circumstances, and no history of tuberculosis in the family. On examination there was found to be considerable conjunctivitis both of lid and globe, and with difficulty could a view of the cornea be obtained, when its surface was found to be vascular, almost resembling pannus, with deeper seated opacities of the cornea.

Internal administration of syrup of the iodid of iron was advised, together with the local use of a two-grain solution of atropia, and a wash of sol. hydrarg. bichlorid 1 in 10,000.

The case, living in a neighboring town, was only seen about once in three or four weeks, and the fleshy appearance of the cornea rather increased in spite of treatment until the beginning of February, when the inflammatory symptoms began to subside, the cornea became whiter, and the patient very comfortable, and by the middle of March all the active symptoms had disappeared, leaving a somewhat soft and slightly shrunken eyeball, with a decided corneal staphyloma. Early in April some irritation of the other eye alarmed the parents and the physician, and enucleation was advised and consented to, and the operation performed at the Manhattan Eye and Ear Hospital on April 16th last.

Since that time the patient has been quite comfortable, and has suffered no inconvenience, no artificial eye having up to this time been fitted, and at the present time there appears to be a nodule beginning to show at the site of the optic nerve, which it is possible may be a recurrence of the trouble in the stump, but I have not been able so far to obtain a section for examination.

The sections show the iris tissue substituted by giant cells with here and there a tubercle bacillus, only some pigment of the iris remaining, and in many of the sections it is difficult to find the cornea at all.

A CASE OF SCLERO-CORNEAL CYST.

BY EMIL GRUENING, M.D.,

NEW YORK CITY.

F. L., a girl of fourteen years of age, was seen at the New York Eye and Ear Infirmary on December 2, 1900. She had lost the use of her right eye in infancy, and had an iridectomy performed on that eye two years ago. Shortly after the operation the eye became much changed by the appearance of a tumor. The resulting disfigurement caused the girl to seek advice.

The examination shows that the eye is blind. On the anterior aspect of the eye a cyst-like growth forms an elevation encircling three-fourths of the periphery of the cornea, encroaching upon this membrane, and extending into the adjoining scleral tissue. The mass measures eight mm. in height, and ten mm. in width. It starts with a pouchlike dilatation at the horizontal meridian on the temporal side of the cornea, passes along its upper edge and down its nasal side to the horizontal meridian. Here the cyst shows a constriction, and then continues in its former size along the lower nasal border of the cornea until it reaches the vertical meridian. The infero-temporal quadrant of the cornea is free. The cyst is translucent, bluish in color,

and soft and elastic to the touch. Its anterior wall is traversed by numerous blood vessels. The whole mass resembles an inflated intestine. A considerable part of the cornea is clear, and permits inspection of the iris and its coloboma. One pillar of the coloboma is free, the other is lost in an adherent leucoma in the infero nasal quadrant of the cornea. The accompanying water color, Fig. 1, which I owe to the kindness and skill of Dr. Percy Fridenberg, gives a faithful representation of the condition.

The anterior chamber is deep. The pupillary space is occupied by an opaque membrane. An incision was made into the cyst, and a clear and colorless liquid evacuated. The cyst collapsed, but the anterior chamber remained full, demonstrating that no communication exists between the anterior chamber and the cyst. The swelling reappeared within twenty-four hours, and no cosmetic result was obtained by the operation. The patient now consented to have the eyeball removed. The specimen was given to Dr. Geo. S. Dixon, assistant pathologist of the New York Eye and Ear Infirmary, for microscopic study. His report and a photograph of the section of the eyeball through the cyst Fig. 2, are appended, and show that we have to deal here with a sclero-corneal cyst in an eye which had been injured, and whose iris had become adherent to the cornea.

DR. DIXON'S REPORT.

The right eye was enucleated under chloroform. The globe measured 23 mm. vert. × 23.5 mm. trans. × 23 mm. ant. post.

The cyst was in two portions, a large sac above and to the temporal side beginning near the horizontal meridian and passing around in the line of the limbus (which was about the center of its long axis) to about the middle of the upper inner quadrant. There was a slight constriction at this point, from whence the smaller sac began. It increased slightly in width, continued in the same general curve, and ceased below a short distance to the inner side of the vertical meridian, or at a point corresponding to 30° to nasal side.

Fig 1

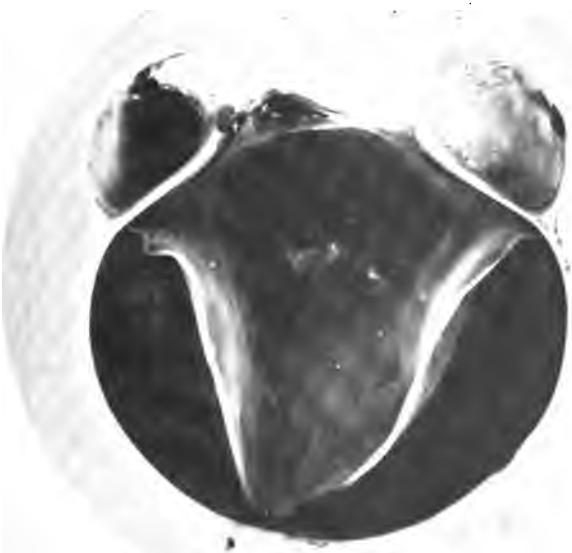

Fig 2.

The vertical diameter of the free cornea was 5 mm., the horizontal 9 mm.

The length of the larger sac in a direct line was 19.5 mm. to the constriction. Extreme width at base was 10 mm., extreme elevation 8 mm. At the constriction the elevation was 6.5 mm.

The length of the smaller sac was 13.5 mm., its width at base 11 mm., with an extreme elevation of 7 mm.

The general appearance of the external walls was bluish slate color, translucent, and covered with a fine network of vessels.

Instead of dividing the globe in the horizontal plane, as is usually done, the division was made in such a manner as to cut through the middle of both sacs.

When the division was made the retina was found to be detached from the disc to the ora, and as there was no subretinal exudate, mechanical detachment was assumed. Macroscopically no lens was apparent. The remains of the anterior chamber was very shallow — 1 mm., and was contracted laterally to 5 mm. Very little of the iris was to be seen.

Stained sections showed the middle layers of the cornea to have separated, and the sac to have been formed by pressure of fluid forward into the cornea and backward into the sclerotic. The anterior wall had become quite thin. The posterior wall appeared to be of about the same thickness as at the beginning of the process, being supported by the structures behind. The walls of the cysts were found to be lined irregularly by a thin layer of endothelium. Some of these cells were noticed in a few locations to have been arranged in small masses protruding slightly into the cavity as though about to be thrown off. In the corneal, and also in the scleral portions, ends or margins, reinforcing fibres were thrown out, which effectually limited the extension of the process. Increased tension would have acted only to further distend the outer walls, already very thin and dangerously near the point of rupture.

The outer surface of the walls was covered with corneal and conjunctival epithelium.

The walls were fairly well supplied with vessels. The fluid contents of the cavity were lost at the time of division, but some blood remained (mostly adhering to the walls), and a little fibrin but no iris tissue, and no pigment.

Careful examination of the sections failed to show any solution in the posterior walls; but further inspection of the macroscopical half revealed two very small canals passing from the posterior chamber to what appears to have been the larger of the cysts. The position of these are indicated by the two white crosses in the photograph. They are about 0.5 mm. below the cut surface.

The free portion of the cornea showed healthy epithelium and normal, well marked Bowman's membrane. There were few vessels near the margins of the cyst. A few wandering round cells, and some transition connective tissue cells were present. Descemet's membrane could be made out but indistinctly.

The iris remaining was œdematous where free, but atrophied where anterior synechia had occurred.

The lens, ciliary processes, ciliary muscle, and choroid were markedly atrophied, the lens remaining being but little thicker than a normal iris.

The retina (detached as above) presented nothing very unusual. The rods and cones were in excellent condition. The external reticular layer was slightly œdematous, and the inner layer thickened a little.

There was slight cupping of the disc, but not more marked than would be regarded as physiological. A marked change, however, had occurred in the inner layers of the lamina cribrosa. Instead of its usual compact appearance its fibers were separated, and appeared as a loose mesh or network. The balance of the nerve was comparatively healthy.

Diagnosis, sclero-corneal cyst.

SARCOMA OF THE IRIS.

BY EMIL GRUENING, M.D.,
NEW YORK CITY.

The boy, T. C., eleven years of age, presented himself at Mt. Sinai Hospital in March, 1901. In his left eye a reddish-yellow mass was seen, growing from the iris. This mass was composed of three yellow nodules which sprang from a common red base (Fig. 1). The pupil was dilated, atropia having been instilled into the eye. There was slight circumcorneal injection, all the media were transparent, the fundus showed no anomaly, and vision was normal. The accompanying sketch, which I owe to the skill of Dr. P. H. Fridenberg, shows the condition of the eye at this time. According to the boy's mother, the yellow spot had been noticed by her four weeks previously.

The absence of inflammation excluded a diagnosis of gumma. In order to establish the nature of the growth it was decided to remove enough of the mass for microscopic examination. Accordingly an incision was made at the sclero-corneal margin and the tumor seized with forceps. It was so soft that only small shreds of tissue could be removed. These were given to the pathologist of the Mt. Sinai Hospital, Dr. F. S. Mandlebaum, who reported as follows:

"The neoplasm removed from the iris shows, upon examination, a loose stroma containing small round cells and spindle cells. Here and there are areas of inflammation, with quite a number of leucocytes and newly formed capillaries. I cannot find any evidence of tuberculosis in the sections. There is a possibility that only a superficial part of the tumor was removed and that the deeper parts may present an entirely different structure. I should not care to make a positive diagnosis from the small portion removed, though the probability of its being a connective tissue growth seems to me very strong.

(Signed) "F. S. MANDLEBAUM."

The sclero-corneal wound through which the portion of th mass was removed did not close. The mass grew through th lips of the wound, became visibly larger and more vascula There was no pain in the eye at any time, but the eyeball b came injected, the pupil small, in spite of the use of atropi The mother now gave her consent for the removal of the ey ball. This operation was performed and the enucleated eye w handed to Dr. Geo. S. Dixon, assistant pathologist to the N York Eye and Ear Infirmary, for microscopic examination. I reports as follows:

In the macroscopical specimen the process appears to ha begun in the head of the ciliary body.

Microscopically the growth is quite vascular, some of t vessels being well formed and some without walls. The form may possibly be vessels of the iris carried outward by the grow The mass is composed of small round cells with a moderate te dency to assume ill-defined spindle forms, more frequent witl the structure of the iris than in the wholly new tissue. T greater part of the iris has been invaded and a cyclitis excit

The cornea internal to the operative incision shows a f round cells; externally the invasion is more marked, but n sufficiently so to obscure the line of extrusion. The lens sho a trace of cortical cataract. The retina was not much disturb though there was evidence of slight detachment a short distan behind the ora on the side opposite the tumor. The inner lay seemed to be slightly swollen and the cells rather indistinct. T vessels were larger than usual. The choroid was atrophi The growth has doubtless been modified by the operati The appearances are in favor of sarcoma.

The accompanying photograph (Fig. 2) of the section of t eye shows the changes in the ciliary body, the iris, and corn

DISCUSSION.

DR. KIPP. — I saw this case of sarcoma from the very l ginning. When the boy was brought to me there was a v

Fig I

Fig 2.

GRUENING. — Sarcoma, iris.

ıe circumcorneal injection and he complained of some pain. 'e found at the lower iris angle a small yellowish mass that emed to push the iris before it like a curtain. The pupil was lly dilated by atropia, and by oblique illumination I could see whitish mass on the posterior surface of the iris correspond- g to the seat of the new growth. The case differed mate- ılly from what I had previously seen, and I may say I have en a number of cases of sarcoma of the iris and am familiar ith syphilitic growths and tubercles of the iris; it looked more ke an exudate from the ciliary body which had pushed the iris ward, although the absence of inflammatory symptoms owed that it could hardly be that. The boy had an eruption over his body which a skin specialist pronounced to be abies. I watched the case and saw the mass coming out more ıd more, and after two weeks concluded that it must be a ma- gnant growth of some kind and advised that the eye should removed. The mother was so shocked that she left me and ent to Dr. Gruening.

ARGE FOREIGN BODY IN ANTERIOR CHAMBER REMOVED WITH PRESERVATION OF PERFECT VISION, WITH PHOTOGRAPH OF FOREIGN BODY IN SITU.

BY S. B. ST. JOHN, M.D.,
HARTFORD, CONN.

I venture to bring before the society this case, because it seems me to be unique in more than one respect, as to the size of the reign body which entered the eye, the slight amount of irrita- on caused while it was present, the readiness with which it was xtracted, the good vision which was subsequently preserved, ıd the fact that I was able to get a photograph of the foreign ody in situ. I think it is the only photograph taken of a oreign body while in the eye (excluding radiographs).

The man was sitting by the side of a comrade who was cut- ng off bicycle spokes, snipping off little pieces, which were

flying in all directions, and with considerable force. A pie
struck this man's eye, and penetrated at the sclero-corneal jun
tion, and in such a direction as to pursue a course exact
parallel to the plane of the surface of the iris. The internal li
of the wound retained their hold upon the fragment at its e
ternal end, while the internal end, reaching nearly to the oth
side of the anterior chamber, was free. He came to the offic
not because of any pain or discomfort, but because his frien
told him there was something the matter with the eye. M
assistant, Dr. Waite, thought it was an excellent chance to get
photograph of a foreign body while in the eye, as the polish
steel gave such a beautiful reflection. The man was taken to
neighboring photographic establishment, and this excellent pi
ture obtained.

Upon passing a strong electro-magnet over the eye it w
found that this foreign body, which was seven and one-half m
in length and one and one-fourth mm. in diameter and of cyli
drical shape, could be caused to travel across the pupil, but cou
not be withdrawn through the wound of entrance, because
end was pointed and sharp. I was, therefore, obliged to make
new wound of exit, and with the Graefe knife I made an ope
ing in the bottom of the anterior chamber, and by introducing th
point of the Hirschberg magnet it was easily turned and draw
out. There was no prolapse, nor reaction, and when the anteri
chamber was restored it could not be made out that there wa
even any abrasion of the epithelium of the iris. The man mad
a perfect recovery, it being difficult to keep him in bed for th
whole day, and in the house for two days, and he presented him
self at my office with 20/20ths vision, and no visible lesion.

ST. JOHN'S case of foreign body in anterior chamber.

ASE OF FOREIGN BODY LODGED WITHIN THE EYEBALL AND REMOVED EIGHTEEN YEARS AFTER THE INJURY; SYMPATHETIC INFLAMMATION THREE TIMES WITHOUT LOSS OF VISION.

BY ALVIN A. HUBBELL, M.D., PH.D.,
BUFFALO, N. Y.

Many cases of retention of a foreign body within the eyeball a considerable period of time without serious consequences on record, but the following seems to present some unual features, and I therefore venture to report it.

G. T., an American, thirty-six years of age, a sailor, has been ployed on vessels for many years as an engineer. In Noember, 1881, the boat, Corsair, to which he was then attached s anchored at Spezia, a naval station in Italy. While making ne repairs there on the 23d of that month, he had occasion to sel some castings of the engine, and while doing so, a piece iron struck his left eye. He was at once sent to Paris and ced under the treatment of Dr. de Wecker. The doctor exined his eye carefully and told him that he thought there s no foreign body in the eyeball. After five or six weeks the e became quiet and comfortable and the patient was disarged.

Since that time the eye has had several attacks of inflamtion which subsided in a few days, or, at most, in two or ee weeks, and in the intervals it was tolerably comfortable, ving scarcely any pain or distress; but it was always more or s "weak," and became easily irritated. In November, 1897, d in March, 1899, I treated him for what I believed to be a rneal ulcer. After two or three weeks' treatment each time s eye again became comfortable as usual.

When first coming under my observation, in November,

1897, I found the left eye normal in size and with normal tension, but with divergent squint. Midway between the center and outer margin of the cornea was a brownish, ulcerated spot one and one-half millimeters in diameter. The iris was adherent to the cornea at this point, posteriorly, and the pupil was small and drawn outward toward the adhesion. The pupil dilated slightly under the influence of atropia, and through it could be seen portions of opaque lens-capsule, apparently separated at one or two points. The patient could count fingers at twenty to thirty centimeters with this eye when the pupil was thus dilated. The eye becoming quiet in a few days, no thought was entertained of the presence of a foreign body. The same was the case in March, 1899, when the same conditions presented themselves.

Previous to these attacks there had been, he said, several others of about the same character, for which he had been treated.

Another feature of this case was that at two different times since the injury, he had had inflammation of the uninjured eye. At one time, the date of which he could not fix definitely, he was treated by Dr. Dennis, of Erie, Pa. There was pain in the eye and the inflammation was quite severe, but he does not remember distinctly about its duration. Afterward, in 1892, he had another attack of inflammation of this eye, which was very severe. At that time he was under the treatment of Dr. Schneider, of Milwaukee, Wis., who called it, he said, "iritis." He recovered from this, after five or six weeks, and in a short time the vision of this eye was as good as ever. Each time, before the onset of the inflammation of the right eye, the injured eye was tender and painful.

On October 27, 1899, the patient came to me the third time, bringing a message from the marine surgeon, Dr. Stoner, whom he had consulted, that there was a "cinder" in the corneal scar of the left eye. I cocainized the eye and on examining it with a cataract needle I found a dark-colored, metallic substance in the tissues of the cornea. Ordinary efforts at dislodging it failed.

ssisted by Dr. L. B. Dorr, who happened to be present in my ffice at the time, I proceeded to take further steps toward its moval. I incised the cornea somewhat, from side to side, and refully separated the foreign body from the tissues, to which seemed quite adherent. Attempts to grasp it with forceps iling, and as the substance seemed to be a piece of iron, I tried e electro-magnet, but there was no attraction. I then took a licate, sharp-pointed hook and passed it along the side of the dy into the eye to a depth of two or three millimeters, and, ding a place where the hook would hold, I gently drew the dy out with some shreds of tissue adhering to it. A small nount of vitreous humor oozed through the opening. The ueous humor, of course, had already escaped.

The wound was cleansed with one to three thousand solution bichloride of mercury, atropia solution was instilled, and the e bandaged. The wound healed rapidly. The aqueous humor d reformed and was retained after two days, and the normal nsion of the ball had become restored. In ten days the eye as practically well.

An iridotomy or iridectomy would undoubtedly have given eful vision.

The foreign body proved to be a piece of cast-iron which had come considerably oxidized. It was somewhat pointed in ape, measuring four millimeters in length and one and one-lf millimeters at its widest part. It was lodged in the eye ith one extremity in the posterior layers of the cornea, its dy in the iris and capsule of the lens, and the other extremity the vitreous humor. The crystalline lens had become ab-rbed. The iron was undoubtedly too near the optic axis of e eye to injure the ciliary body.

The removal of the foreign body, however, was not the end f the case. On October 29th, two days after the operation, the ther eye began to redden somewhat, but I did not regard it as f any consequence. On October 30th, however, the redness nd sensitiveness were increased, and, although there was no istress and vision equaled 5/5+, I began to suspect trouble.

October 31st there was pronounced inflammation with photophobia and some pain, and the patient complained that the vision was a little hazy. At this time the vision was 5/9 with a +0.50D. lens. The pupil was somewhat contracted, the iris discolored; and the eyeball was very tender in the ciliary region. I then ordered a solution of atropia to be instilled into the eye, and salicylate of soda to be taken internally.

November 1st. There was some pain and the eye was very red. The pupil was well dilated, except at two points where there were small adhesions to the lens. Vision was 5/24 with +0.50D. The patient was now put to bed in a darkened room and the same medicinal treatment continued, the salicylate of soda being given in large doses.

November 3d. Patient was more comfortable and the eye appeared better; same treatment continued.

November 4th. Was still better and from this time the eye improved rapidly. On November 9th he was able to use colored glasses and come to my office. Vision had increased to 5/6+ with +0.50D. The atropia was then discontinued, and boracic acid solution instilled in its stead for a few days. The salicylate of soda was continued for ten days longer. Recovery was rapid and complete, and vision was fully restored to 5/5 in about two weeks.

The undoubted veracity and intelligence of the patient makes the history of this case trustworthy, and furnishes another instance of a foreign body being retained in the eye for a long period of time without destructive inflammation or degeneration of the organ. Another interesting feature of the case is that during this time and immediately following the extraction of the body, there were at least three attacks of uveal inflammation of the other eye. The first attack was, probably, iritis or irido-cyclitis, judged by the symptoms described by the patient. The second attack was, undoubtedly, iritis or irido-cyclitis, judged also by the symptoms and by the diagnosis pronounced by a competent oculist in attendance. The third attack was under my own observation, and it was certainly iritis with pos-

sibly an accompanying cyclitis. Admitting, then, that this patient had three distinct attacks of uveal inflammation, were they of sympathetic origin? I am disposed to believe that they were; first, because there was no history of rheumatism or syphilis in the case; second, because there was a sufficient cause in the presence of the foreign body in the other eye; and third, because each attack was immediately preceded by a process of irritation and inflammation of the injured eye. The third attack, which I watched closely, seemed, most decidedly, to be induced by the temporary disturbance of the injured eye caused by the removal of the foreign body.

I grant that more serious results generally follow sympathetic uveal inflammation, but there are many cases on record where useful and even perfect vision has been preserved in the sympathizing eye. The fortunate result, therefore, in this case does not, it seems to me, invalidate the sympathetic character of these attacks.

I may add, here, that I attribute the rapidity and completeness of the recovery in the last attack in a large measure to the use of salicylate of soda internally. It has served me well in another typical case of sympathetic irido-cyclitis, in which useful vision was preserved, and also in many cases of idiopathic iritis which were not syphilitic.

To summarize, then, here is a case in which a piece of cast-iron penetrated the left eye on November 23, 1881, which was retained within the ball, lodged in its anterior portion, in the lens, iris, and cornea, until October 27, 1899, a period of eighteen years, lacking one month. During this time the lens had become absorbed, and there had been occasional attacks of inflammation and "corneal ulceration" in this eye, and sympathetic inflammation appeared twice. The foreign body was successfully removed, with a possibility of serviceable vision. Immediately after its removal, sympathetic inflammation again developed. Each attack was duly controlled and perfect vision was preserved in the sympathizing eye. Incidentally, emphasis is placed on the value of large doses of salicylate of soda in sym-

pathetic irido-cyclitis, as well as in other uveal inflammations of non-syphilitic origin.

DISCUSSION.

DR. KIPP. — It is well known that some eyes may retain foreign bodies for almost any length of time without producing irritation. I have seen a case of foreign body remaining in the eye thirty-one years without doing any harm. I have a patient under observation now who was struck in the eye with a gun cap in 1870, the piece of cap passing through the lens and lodging in the retina, where it can still be seen. In regard to foreign bodies coming forward, I have seen two cases in which pieces of copper, one after five and one after ten years, were spontaneously discharged.

RESULTS OF X-RAY DIAGNOSIS AND OF OPERATION IN INJURIES FROM FOREIGN BODIES.

BY WILLIAM M. SWEET, M.D.,
PHILADELPHIA, PENN.

At the meeting of this society in 1897 I described a method of locating foreign bodies in the eyeball and orbit by means of the Roentgen rays. The apparatus then exhibited has been employed by me during the past four years, most of the patients being sent from the Wills Hospital and the Jefferson Medical College Hospital. Through the courtesy of the surgeons for whom I made the X-ray examinations, I have been present at many of the operations for the extraction of the foreign bodies, and have been able to follow the subsequent history of the majority of the patients. A number of the earlier cases have been previously reported in detail, but, in order to exhibit the results of treatment at a considerable period after operation, these have been incorporated in the statements here given.

The cases in which the X-rays were employed for purposes of

diagnosing the presence or absence of foreign bodies in the eye numbered 102, of which 65 showed a foreign body in the eyeball or surrounding tissues, while in 37 cases the result of the examination was negative. Of the bodies in these 65 cases, one was glass, five were copper, six were small shot, and 53 were iron or steel. The positions occupied by these bodies were as follows: One in the eyelid, three in the orbit outside the eyeball, one in the iris, three in the crystalline lens, and 57 in the vitreous, the retina or choroid, or imbedded wholly or in part in the optic nerve.

Of the 61 cases in which the body was situated in the eyeball, an attempt was made in 45 cases to extract the substance, and was successful in 38 cases, and failed in 7 cases. In 32 instances the metal was extracted by the Hirschberg magnet, once with the Haab magnet, and five times with forceps. In 5 of the cases of failure to extract the body, enucleation was at once performed, while in the other two the eyeball was not removed. In 6 cases in which the body was successfully extracted, enucleation was required at a later date. In no instance was sympathetic inflammation present at the time of operation, nor did it subsequently occur.

In 16 cases extraction was not attempted, the eyeball being enucleated in 9 cases, of which 3 contained steel, 3 small shot, and 3 copper. In 4 cases the steel still remains in the eyeball, while in 3 cases the patients refused operation, and their subsequent history is unknown.

Causes of Enucleation after Extraction. The causes which necessitated enucleation in the 6 cases in which the steel was successfully removed is shown in the following brief histories:

CASE 7. Piece of percussion cap in the vitreous for three months. Removed with forceps. Eyeball painful six months later, with attacks of photophobia in the other eye.

CASE 23. Piece of boiler steel entered vitreous, which was filled with blood when examined twenty-four hours later. Body weighed 27 cgms., and was removed by first insertion of small magnet. Man returned five months later with history of at-

tacks of inflammation in eye, with great tenderness over ciliary region.

CASE 26. Large piece of steel from a sledge entered through cornea; anterior chamber filled with blood. Magnet removed body through opening in sclera. Enucleation seven days later on account of recurring hemorrhages into anterior chamber.

CASE 45. Piece from hammer penetrated cornea, wounding iris and lens. Body removed through entrance wound twenty-four hours later. Weighed 23.5 cgms. Eye never became quiet, and was enucleated two months later.

CASE 46. Piece of steel entered through cornea, iris, and lens ten weeks before examination. Body removed by forceps, with a mass of exudate in which it was imbedded. Eyeball painful and shrunken three months later.

CASE 58. Piece of tool steel penetrated cornea, iris, and lens five days before. Original wound opened, and body removed by magnet. Three days later eye painful, and chemosis increased. Upon enucleation eyeball showed evidence of beginning panophthalmitis.

The percentage of successful extractions, with preservation of useful vision, would undoubtedly have been greater had the foreign body been located and removed a few hours after the injury. Unfortunately, a majority of patients are encouraged to wait until the immediate effects of the injury have subsided, in the hope that vision will improve, and no body will be found to have entered the eye. Much valuable time is thereby lost, the wound of entrance closes, and the body becomes imbedded in firm exudate that renders its extraction by any form of magnet uncertain if not fatal to the usefulness of the eyeball. Prompt operation will not succeed in every case, but it is rational treatment, free from serious effects, and gives the patient the best chance of saving some sight or securing at least a serviceable eyeball cosmetically considered.

Were the cases of iron or steel in the eye seen before the wound of entrance had closed, and the position of the metal determined, the employment of the Haab or similar form of large

magnet to withdraw the body along the path it entered would be the ideal treatment. In a certain proportion of cases where the metal has passed through the cornea, wounding the iris and lens, less damage will be caused by making a new opening in the sclera for the removal of the body than to withdraw it through the structures it passed in entering the globe.

In a majority of cases of bodies in the choroid and vitreous, extraction was through a scleral opening between the external and inferior recti, or the internal and inferior recti. Before making a scleral incision it is advisable to dissect up a flap of conjunctiva, and stop all hemorrhage before opening into the vitreous. The stitching of this flap in place serves to cover the scleral opening, and prevent the escape of vitreous.

In five cases in the tables an attempt was made a few hours after the injury to remove the steel with a small magnet, the probable situation of the body having been determined by the nature of the wound, its direction, and the position of the eye at the time of injury. In every instance the attempt failed. Subsequently, the location of the steel was determined by the X-rays, but in four cases the metal was so firmly imbedded in new tissue that the small magnet failed to dislodge the steel, and the eyeballs were lost.

The situation and direction of the wound of entrance is not a safe guide as to the position of the foreign body in the eye. Sometimes the force with which the steel strikes is sufficient to cause it to pass in a straight line from the entrance wound across the eye, and lodge on the opposite side. In other instances the body, after penetrating the external structures, drops to the bottom of the vitreous. Thus, in cases 50 and 51, the metal, after penetrating the cornea and lens, lodged at the posterior portion of the ball, while in cases 13 and 24, with similar injuries to the anterior structures, the steel was found at the bottom of the vitreous, back of the ciliary body. It is in cases similar to the last two that the use of the large magnet to withdraw the body through the original wound, when the position of the steel is not known, is likely to cause more damage than would follow ex-

traction through a scleral opening close to the previously determined position of the metal. The majority of the foreign bodies were in the lower half of the eyeball, only eight being situated above the horizontal plane.

The use of the small magnet is never justifiable unless the position of the body is determined with some degree of accuracy. Since the magnet point must come in contact with the particle of

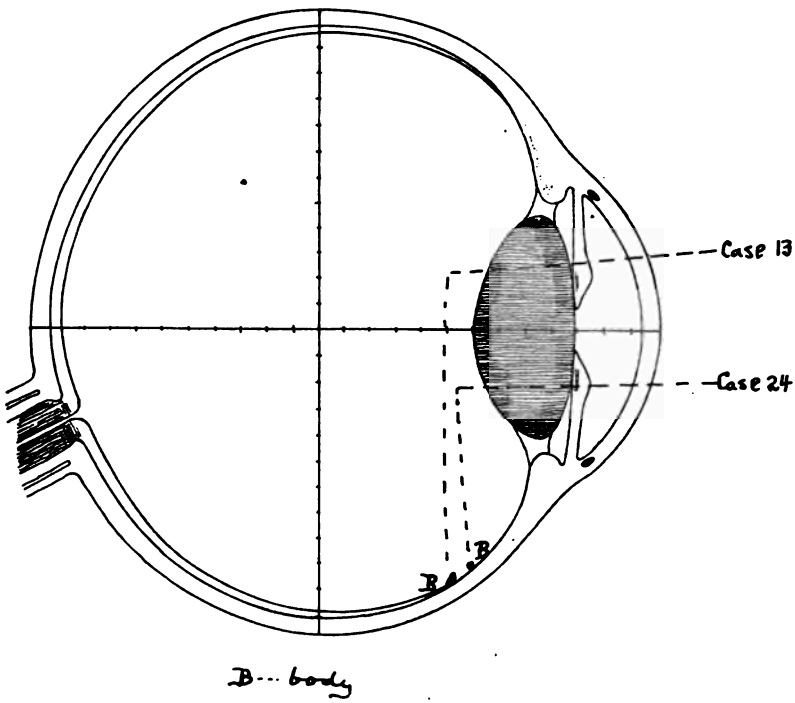

steel to insure its removal, some definite knowledge of the position to place the magnet must be had to prevent the injury which results from its frequent passage through the vitreous. It is even a question whether the insertion of any magnet into the vitreous is not more harmful than the use of a larger magnet to draw the metal to an opening made in the sclera. It is interesting in this connection to note the excellent visual results in the several cases in which no attempt was made to extract the steel, but it must be remembered that eyes containing foreign bodies

are never free from danger. This is shown by a few cases in the tabular statement of metal remaining quiet in the eye for long periods, but ultimately compelling operative intervention. In two cases the steel was in the eyeball eighteen years, one twelve years, one ten months, and one eight months. I believe that the best results in the future in those cases seen after the entrance wound is healed will be secured by first accurately determining

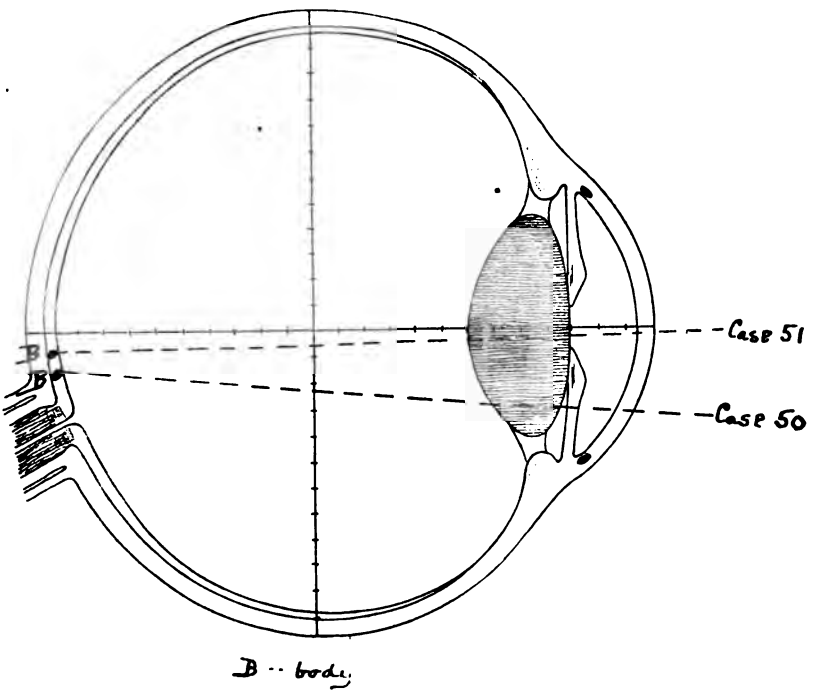

the position of the steel, and removing it through an opening in the sclera, employing a magnet similar to the Johnson or Lippincott of sufficient power to attract the body when the point of the magnet is at an opening in the sclera, and is not entered into the vitreous.

When the metal has been in the eye for several months or years there is very little chance of removing it by the magnet unless situated in the iris, the lens, or the vitreous. If in the choroid a firm exudate soon forms that resists the attempts of any

magnet to dislodge the metal, although the body may sometimes be secured with forceps, the vitreous lost being replaced by normal salt solution. While the operation may not give any vision, the preservation of the eyeball justifies the procedure. Cases 20, 44, and 50 are instances of forceps extraction, the latter case, four years after operation, showing an eyeball which, although slightly atrophic, is still superior to an artificial one.

Accuracy of X-Ray Localization. So far as the findings in the cases here given could be verified by the extraction of the foreign body or after enucleation, the substance was in every instance situated at the spot indicated by the radiographs. The method of localization employed is simply the triangulation of the shadow of the foreign body from two different positions in relation to the shadows on the photographic plate of two known points, so that accuracy in the results must follow with proper care in working. Thus, in two cases (Nos. 8 and 54), the knife in making the scleral opening at the indicated point struck the steel, while in Case 61 it was possible to indicate that the body was partly imbedded in the optic nerve, from which situation it was removed by forceps.

The injury was to the right eye in twenty cases, and to the left eye in forty-one instances. The relative greater frequency of injury to the left eye is to be expected, since most workmen are right-handed, and in chipping or striking metal usually stand with the left side to the work. For a similar reason left-handed workmen are more liable to injury to the right eye.

The fifty-seven cases in which the foreign body entered the vitreous chamber have been classified in the tabular statement into three divisions: (1) those in the ciliary region; (2) near the equator; and (3) at the posterior part of the globe.

IN THE CILIARY REGION.

Under this head are included all cases in which the body was in or close to the ciliary body. Of the 24 cases, iron and steel was in 22, glass in 1, and copper in 1. No attempt was made to extract the body in 6 cases, the eye being enucleated in 3, while in the other 3 the steel remains in the eyes. The magnet

failed in 6 cases, in 5 of which the eyeball was enucleated. In each of these cases the body was firmly surrounded by fibrocellular tissue, having been in the eyes, respectively, 18 years, 10 months, 3 months, 12 days, and 4 days. In the last case an unsuccessful attempt to extract the body a few hours after the accident increased the difficulty of securing the metal at the second trial 4 days later. In one case the eyeball was painful two months after the magnet extraction, but the man refused to have it enucleated. The following is a summary of the 24 cases:

Magnet not tried, enucleation,		3
Magnet failed, enucleation,		5
Magnet successful, enucleation later,		3
Magnet successful, painful eyeball,		1
Magnet successful,	V—6/60,	1
	Light projection,	5
	Light perception,	1
	Atrophic eyeball,	1
Magnet not tried,	V—6/6, partly,	1
	V—5/30,	1
	Light projection,	1
Magnet failed.	V—5/50	1
		24

NEAR THE EQUATOR.

In the second classification are all foreign bodies at or 3 mm. in front or 3 mm. behind the equator. Of the 21 cases included in this list, 2 were small shot, and 3 were copper. Of the 16 cases of iron and steel, magnet extraction was successful in 11 cases, failed in 1 case, and in 4 cases no operation was done. The results in the cases are summarized as follows:

Extraction not attempted, enucleation,		3
Magnet successful, enucleation later,		2
Magnet successful,	V—6/6, partly,	1
	V—6/9,	1
	V—5/7,	1
	V—5/10,	1
	V—6/60,	1
	Light projection,	3
	Light perception,	2
	Atrophic eyeball,	1
Magnet failed.	V—6/15,	1
No operation,		4
		21

POSTERIOR PART OF EYEBALL.

The third subdivision includes all cases in which the body was in the posterior portion of the eyeball, including the optic nerve. The total number of cases was 12, of which one was small shot, and one was copper, both being in the optic nerve, and in both the eye was enucleated. Of the 10 cases of iron or steel, extraction was successful in every instance, 7 with the Hirschberg magnet, and two with forceps (Cases 50 and 61). The results were as follows:

Extraction not attempted, enucleation,		2
Magnet successful, enucleation later,		1
Magnet successful,	V—6/5,	1
	V—6/48,	1
	Light projection,	2
	Light perception,	2
	Atrophic eyeball,	2
	Partial retinal detachment,	1
		12

IN THE CRYSTALLINE LENS.

In three cases the foreign body was in the lens. In Case 1 the lens containing the steel was removed, and the man had normal sight with correcting lenses. In the second case no operation has been performed, the lens being streaked with opacities, but otherwise the eye suffers no discomfort. In the third case the metal had remained in the lens for eight years. The iris was glued to the yellowish opaque lens at the point of injury. One week before operation the eyeball became painful and congested. Lens with the steel removed with forceps. V, with correction, = 5/15.

OUTSIDE OF EYEBALL.

In three of the cases in which the radiographs indicated that the body was situated outside the eyeball there were opacities of the vitreous from the impact of the metal against the globe. In Case 63 the eyeball was uninjured, but the paralysis of all the muscles supplied by the third nerve rendered of interest the location of the shot.

CONCLUSIONS.

From a study of the group of cases here given, the following conclusions may be drawn:

1. The Roentgen rays offer the most certain method of detecting and locating foreign bodies in the eye.

2. The position of the foreign body should be determined in all cases before magnet extraction is attempted. Frequent insertion of the small magnet into the vitreous in the hope of finding the metal injures the eye, and renders later attempts at extraction difficult, while the employment of the large magnet is not without danger when the position of the body is not known.

3. Early extraction offers the best chance of saving the eye. When the track of the body is through the cornea and lens, its position in the vitreous will indicate whether less damage will be done by removing the metal through the open entrance wound or through a new opening in the sclera close to the indicated position of the body.

4. The more extended use in the future of the larger magnet in cases of steel in the vitreous chamber to draw the metal to an opening in the sclera, after its position has been accurately determined, will probably achieve better visual results than have been obtained in the past with the small magnet introduced into the vitreous.

5. Iron or steel which has remained in the eyeball until a fibro-cellular covering envelops it cannot be dislodged with the magnet. Extraction with forceps, and the employment of normal salt solution to replace any vitreous lost, has resulted in several instances in eyeballs of good cosmetic appearance, and is an operation worthy of trial. Forceps extraction must also be employed when the body is of copper or glass.

6. Extraction is a safe operation, and under proper precautions it is free from the dangers of panophthalmitis or meningitis.

SUMMARY OF CASES OF FOREIGN BODIES LOCATED BY ROENTGEN RAYS.

Case.	Surgeon.	Eye.	Time between Injury and Operation.	Time between Operation and Last Examination.	Condition at Last Examination.
1	W. Thomson	L.	3 months	1 year	V=6/6.
2	de Schweinitz	R.	No operation	.....	.....
3	Oliver	R.	8 years	3 months.	V=5/15.
			IN IRIS.		
4	Hansell	L.	1 day	6 months	V=6/9.
			IN CILIARY REGION.		
5	Hansell	L.	8 days	2 months	Good light projection.
6	Strawbridge	L.	5 weeks	....	Magnet failed. Enucleation.
7 a	Hansell	R.	3 months	.....	Enucleation 6 months later.
8	Berens	R.	2 weeks	Magnet not used	Enucleation.
9	W. Thomson	R.	12 years	" " "	"
10	W. Thomson	L.	3 weeks	" " "	"
11	Sweet	L.	1 month	9 months	V=6/60.
12	Ellegood	L.	2 days	11 "	Good light projection.
13	Ellegood	L.	13 "	1 year	" " " Cataract.
14	Hansell	L.	10 "	20 months	" " " "
15	de Schweinitz	R.	18 years	.....	Magnet failed. Enucleation.
16	Oliver	R.	No operation	....	V=5/30 1 year later.
17	Norris	L.	4 days	.....	Magnet failed. Enucleation.
18	Risley	L.	No operation	.....	V=6/6 partly.
19	Norris	L.	1 month	2 months	Eye painful. Refused enucleation.
20 c	Sweet	L	3 "	9 "	Slight atrophy of eyeball.
21	Norris	L.	3 "	6 "	Magnet failed. V=5/50.
22	de Schweinitz	R.	10 "	.....	" " Enucleation.
23	de Schweinitz	L.	1 day	.....	Enucleation 5 months later.
24	Schwenk	L.	6 days	2 months	Good light projection. Cataract.
25	Risley	L.	12 "	.....	Magnet failed. Enucleation.
26	de Schweinitz	L.	1 day	.....	Enucleation 7 days later.
27	Risley	L.	No operation	.....	Eye quiet 2 months later. Cataract.
28	Oliver	R.	18 years	3 weeks	Light perception.
			NEAR THE EQUATOR.		
29	de Schweinitz	L.	3 years	... .	Magnet failed. V=6/15.
30	Sweet	L.	6 days	2 years	V=6/9.
31	Love	L.	2 weeks	2 "	No L. P. Slight atrophy of eyeball.
32	Hansell	L.	4 "	2 "	V=6/60. Slight retinal detachment.
33 a	Norris	R.	3 "	.....	Enucleation.
34 a	de Schweinitz	R	No operation	.....	Enucleation.
35 b	Hansell	L.	" "	.....	No light percep.
36	Zentmayer	L.	Refused operation	.....	Disappeared.
37	Schwenk	L.	5 days	3 months	V=5/7½.
38	Hansell	L	4 days	20 "	V=6/6 partly.
39	de Schweinitz	L.	No operation	.....	Disappeared.
40	Shoemaker	L.	" "	.....	Good light proj. Cataract.
41	de Schweinitz	L.	1 day	1 year	Light proj. temp. side. Cataract.
42	Oliver	L.	6 days	3 months	V=5/10.
43 b	Harlan	R.	4 "	.....	Enucleation.
44	Hansell	L.	2 months	4 months	Good light proj.
45	de Schweinitz	L.	1 day	.....	Enucleation 2 months later.
46	Hansell	L.	2 months	....	Enucleation 3 months later.
47 a	de Schweinitz	R.	No operation	.....	Refused enucleation.
48	Love	R.	4 weeks	3 weeks	Light perception.
49	Radcliffe	R.	8 days	3 "	" "

SUMMARY OF CASES. — CONTINUED.

AT POSTERIOR PART OF EYE.

Case.	Surgeon.	Eye.	Time between Injury and Operation.	Time between Operation and Last Examination.	Condition at Last Examination.
50	W. Thomson	L.	8 months	4 years	No L. P. Eye slightly atrophic.
51	de Schweinitz	L.	2 days	3 "	Good light projection. Cataract.
52 a	Turnbull	R.	In optic nerve	.....	Enucleation.
53 b	Hansell	L.	In optic nerve	No operation	Enucleation 3 months later.
54	Harlan	L.	3 weeks	6 months	No L. P. Eye slightly atrophic.
55	Oliver	L.	0 days	12 days	Light perception.
56	W. Thomson	R.	8 "	6 months	V=6/48.
57	W. Thomson	R.	19 "	8 "	Retinal detachment temporal side.
58	Crosky	L.	4 "	.....	Enucleation 3 days later.
59	de Schweinitz	R	4 "	2 months	V=6/5.
60	Posey	L.	10 "	6 "	Good light projection. Cataract.
61	Oliver	R.	1 week	1 month	Light perception.

OUTSIDE OF EYEBALL.

62 b	de Schweinitz	R.	No operation	.....	Small shot above eyeball.
63 b	Hansell	L.	" "	.....	" " at optic foramen.
64 b	Sweet	L.	.....	.....	" " in eyelid, removed.
65	Schwenk	L.	.....	.....	Piece of steel close to eyeball.

a. Copper. b. Small shot. c. Glass.

DISCUSSION.

DR. STANDISH. — I want to say a few words in favor of the Haab magnet. We have had it in use now for three or four years at the Massachusetts Charitable Eye and Ear Infirmary, and while our first experiences were not very satisfactory, as we have learned to handle it better our results have been more fortunate. In my last service of four months I had five or six cases of steel driven through the cornea and iris or lens into the vitreous chamber. These were mostly among granite cutters, as most of our foreign body cases are. In the examination to determine the relative position of the foreign body we take note of the cut in the cornea and lens, and if possible the wound of exit from the lens, and if possible the position of the body in the posterior tissues of the eye. The use of the X-ray apparatus has not been a success with us, because we have been dependent upon a neighboring institution for such examinations, which entailed much loss of time. The patient in bed or in a chair has been brought to the point of the magnet, and his head manipulated so as to have the line of traction as nearly as possible the same as the line of entrance of the foreign body, and this is repeated time and again

until the patient is no longer afraid to have the eye approached to the magnet point. Then bringing the point of the magnet directly to the lips of the wound, the current is turned on with great slowness, the man manipulating the handle naming the amount of current as he proceeds. Generally you note the impact of the foreign body soon against the posterior surface of the lens. The steel can usually then be drawn easily through the lens into the anterior chamber, and in perhaps two-thirds of the cases it jumps to the corneal wound; in about one-third of the cases it drops into the anterior chamber, and I remove it with the smaller magnet. In all of our cases, with one exception, the patients have recovered useful vision, and the lens has absorbed as in soft cataract. In one case, a man 55 years of age, the lens did not absorb, but became hard, and an attempt to remove it excited considerable inflammatory reaction.

Dr. Holt. — In one of my series of cases I was unable, in nine out of twelve, to determine the location of the foreign body. Whatever the location of the foreign body in the eye I have always opened the eye in the outer inferior quadrant near the equator. I have never sutured the sclerotic, although I have made an incision as long as 15 mm. I suture the conjunctiva with catgut. I do not think it is necessary to locate the foreign body in the vitreous, for in the cases where I did locate it I have had as much or more difficulty in getting it out as in the others where I did not locate it. I have never used the Haab magnet, but have been lately using the Johnson magnet, and have been much pleased with it.

Dr. Sweet. — My stitches were not used in the sclera but in the conjunctiva.

THROMBOSIS OF THE CAVERNOUS SINUS.

By EDWARD JACKSON, M.D.,
DENVER, COLO.

The symptom-picture of this condition must necessarily vary somewhat with the general disease that it may attend, and the local conditions, particularly the point at which the thrombotic process begins. Since, in the following case, the anatomical condition was ascertained by post mortem examination, it seems worthy of record.

J. C., male, aged 26, a native of Ohio, suffering from pulmonary tuberculosis, was admitted to the Arapahoe County Hospital, medical service of Dr. H. B. Whitney, January 3, 1901. He had suffered from a pulmonary hemorrhage in 1897, and with a cough and expectoration since that time. He had been somewhat worse the last few months — was weaker, and had suffered from asthma. But he was not greatly emaciated, and gave no indication of an early fatal termination of his case.

During the first five days in the hospital his temperature did not rise above 99.5°. Respiration ranged from 24 to 42, and pulse from 100 to 138. His urine was rather concentrated, specific gravity 1030, but otherwise normal. On the night of January 8th the lids of the right eye began to swell. There was slight muco-purulent conjunctival discharge, and severe pain in the region of the right orbit.

January 9th. The patient was transferred to my charge, and when I saw him in the afternoon there was great swelling of the right lids, some protrusion of the eye, severe muco-purulent conjunctival discharge, no marked impairment of the ocular movements, cornea normal, and vision apparently unaffected. The left eye had already been protected by a Buller's shield. It appeared normal in all respects, and remained so throughout the case. The temperature, which had risen the preceding

night to 101°, had dropped again to normal; pulse 130; respiration 30. Repeated microscopic examinations of the conjunctival discharge failed to reveal either the gonococcus or the Klebs-Loeffler bacillus. The patient made no complaint except of severe aching in the region of the orbit.

January 10th. The swelling of the lids, chemosis, prominence of the eyeball and conjunctival discharge had increased. Temperature rose to 100.5° in the afternoon, with pulse 108, respiration 20.

January 11th. The swelling still greater. The cornea remained clear, vision apparently good, and no impairment of the ocular movements, other than would be accounted for by the general swelling. The temperature, 101.4 in the morning, rose to 102.5 in the evening. There was continued complaint of pain, and slight delirium. The patient died on the 12th, quite suddenly, shortly after midnight, having responded rationally to questions a few minutes before.

The treatment employed was frequent washing of the eye with a two per cent. solution of protargol, and the application of a twenty per cent. solution of protargol once daily. Internally, calomel and a saline were given, with morphia to diminish the pain.

The post mortem examination was made fourteen hours after death by Dr. J. A. Wilder, pathologist to the hospital. It showed old lesions and scattered tubercles in the upper lobes of both lungs, with moderate recent congestion and œdema. The heart, spleen, and kidneys were normal; there was a nutmeg liver. The cerebral meninges showed miliary tubercles scattered over both hemispheres, but none at the base of the brain. In the right cavernous sinus was an organized clot, about one-eighth of an inch in diameter, extending into it from the orbital vein.

In the early part of its course this case looked more like one of purulent conjunctivitis than anything else, although the excess of swelling and rather moderate discharge caused me at first to think it might be diphtheritic. The movements of the

eye showing no impairment, except such as would be expected from the swelling, at first seemed to exclude thrombosis of the cavernous sinus. Later, the swelling of the orbital tissue, showed that it was in some way involved; but not until the case had run its course did I conclude that it was a case of sinus thrombosis.

The clot found extended into the cavernous sinus from the orbital vein. But even allowing for post mortem contraction it had probably not filled the sinus, and it presented no prolongations extending into other cerebral sinuses. It seems probable that the process began in some vein in the orbit. This would account for the absence of any early paralysis of the extraocular muscles. The vision retained until the time I last saw him, a few hours before his death, showed that the thrombosis had not then involved the retinal vessels.

AN UNUSUAL CASE OF CHRONIC INFLAMMATORY HYPERTROPHY OF THE LID MARGINS.

By FREDERICK E. CHENEY, M.D.,
Boston, Mass.

The patient whose case I have to report is a boy twelve years of age, born in Germany, and of Jewish extraction. He entered the Massachusetts Charitable Eye and Ear Infirmary April 8, 1901. The history obtained from the father is as follows: In his second year the boy developed a skin trouble, described as pimples varying in size from a pin's head to a silver dollar, and distributed over the entire body. These pimples continued to form for about six years and some of the larger ones on the back of the neck were operated upon. Four years ago, at about the time the skin trouble ceased, a pimple was noticed on the right upper lid and also that the lid was enlarged. It has gradually increased in size up to the present time and now falls over the front of the eye and interferes with vision. There have been

periods of inflammation, though as far as can be judged the inflammation has at no time been severe or caused great discomfort. Upon examination, the right upper lid margin was found to be greatly enlarged, the thickening being somewhat more marked over the outer two-thirds. There was moderate redness, numerous encrusted areas, and superficial points of suppuration, mostly around hair follicles, and a very general and fairly abundant distribution of cilia over the entire thickened surface. To the touch the growth seemed uniformly infiltrated and in no way suggested the condition resulting from a numerous chalazion formation. The thickening seemed confined entirely to the margin, the integument of the lid being uninvolved. The lower edge of the tarsal plate was well defined and perfectly normal in outline. The inner surface of the tarsus and the conjunctiva appeared normal with the exception of two or three small superficial points of suppuration just back of the lid margin. A moderate degree of hypertrophy was found in the other lid margins. The cilia were very abundant and were distributed over a surface four or five times as wide as the area normally occupied. There was no redness, crust formations, or suppurating points; in fact nothing in the appearance of these lids or in the history that suggested an inflammatory process. An ophthalmoscopic examination showed lamellar cataracts of moderate density which reduced the vision to five-tenths. In other respects the eyes were normal. The right upper lid — the one of extreme hypertrophy — was treated with peroxide of hydrogen, a pad of absorbent cotton wet with the solution being frequently applied and held in place by a roller bandage. At the end of two weeks the lid was entirely free from suppurating areas and crust deposits, but there was no decrease in its size.

May 20th, under ether, the hypertrophied tissue was removed. The first incision was made parallel to the lid margin just in front of the edge of the tarsus and the second at the upper border of the growth, the two incisions uniting at the outer and inner limit of the lid. The edges of the wound were brought into good apposition and the healing process was perfectly normal.

For pathological examination a thin vertical section was made before the growth was removed, including the lower part of the tarsus, at the junction of the middle and outer third of the lid. The Pathological Report by Dr. Frederick H. Verhoeff, pathologist to the infirmary, is as follows:

Pathological Examination. A circular piece of tissue, six mm. in diameter and one mm. in thickness, removed in vertical section from the lid margin, was submitted for examination. Macroscopically the cross section shows a gelatinous looking but quite firm material which is slightly striated and which occupies the marginal portion of the lid and extends upward for a distance of about three mm. On microscopic examination the lid structure is seen to be involved in a diffuse formation of young granulation tissue. This grows in between and separates the old connective tissue fibers and even penetrates the bundles of striated muscle. It does not differ essentially from the granulation tissue seen in other situations, but the enormous number of plasma cells is especially striking. Lymphoid cells are comparatively infrequent and are apt to occur in nodular collections. Polynuclear neutrophiles are also scantily present. Eosinophiles are comparatively numerous. The tissue is highly vascular, but it is not congested. There are no areas of softening or degeneration anywhere present. No particular structures of the lid seem to be the starting points for the new tissue, but the latter is abundantly present within the tarsal plate. The ducts of Meibomian glands to be seen are free and do not seem to be especially involved in the growth of new tissue. No Meibomian glands can be found in the specimen, probably because the latter did not extend sufficiently high into the lid. In general, the appearance presented is highly suggestive of a diffuse chalazion formation. No micro-organisms can be found in sections stained by the Gram-Weigert method, by the stain for the tubercle bacillus, or in sections stained for twenty-four hours in carbol-fuchsin and decolorized in seventy per cent. alcohol. The other tissue removed during the operation shows nothing

additional. Diagnosis: Chronic inflammatory hypertrophy of the lid margin.

As Dr. Verhoeff suggests in his report, this condition of hypertrophy may have resulted from a diffuse chalazion formation. Clinically there is nothing indicating such a process in the growth itself or on the inner surface or border of the tarsus. Neither am I inclined to believe that suppuration was in any way a causative factor, but regard it rather as a secondary process. This view seems reasonable when the condition of the other lid borders is considered. They were markedly hypertrophied, but there was nothing in the history or in their appearance to suggest past or present inflammation. It is, nevertheless, probable that they are involved in the same pathological process as the right upper lid, and that the degree of hypertrophy will gradually increase.

As to the etiology, very little can be said. The extensive and long continued inflammation of the skin might perhaps suggest a syphilitic taint, but there was nothing in the teeth or other tissues of the body that would favor this view.

ANOPHTHALMUS CONGENITUS.

By J. HERBERT CLAIBORNE, M.D.,

New York City.

It has been my fortune to see two cases of anophthalmus congenitus; in one instance the deformity was bilateral and in the other unilateral.

Case I. Female infant, two months of age, German parentage, of the tenement class. The mother stated that there was no consanguinity between herself and husband. The child was carried to full term and delivered in the natural manner. Inquiry concerning pre-natal impressions developed nothing of much importance. The mother said, however, that in the be-

ginning of pregnancy she had been frightened by a lightning stroke and had hysteria in consequence. When the child was two months "under way" the mother saw a small boy run over by a wagon; she screamed and fell but did not swoon. This child was the fourth; two had been normal and the third still-born after eight and one-half months of carriage.

Status. Child is marasmic, arms and legs very thin but otherwise normal. Anterior and posterior fontanelles both widely open. Head rather small, face decidedly prognathous. Hair is very scanty. Blood vessels of the scalp fill on the slightest disturbance, showing want of tension of the arterial system. There was no sign of an eyeball in either socket.

Right Side. Lid could be parted slightly and through the slit mucous membrane of normal color could be seen glittering and apparently slightly moving, indicating the possible presence in the depths of a rudimentary eyeball.

On the left side the palpebral slit was so narrow that it was impossible, without injuring the lids, to see the bottom of the sac. The lids on this side were very much more sunken than on the right. I concluded that there was no eyeball present.

Nose. On the right side there is a nostril, the aperture being about the size of a large knitting needle. On the left side there is an imperforate nostril, the blind depression being lower than the site of the nostril on the right.

Right Ear. Auricle is small, external auditory canal very small. There were two fleshy teats situated just in front of the tragus.

On the left side the auricle was crumpled, lobe imperfect, auditory canal a blind pit. In the concavity of the concha there was a deep depression as if there had been an attempt at formation of an eccentric auditory canal.

A large teat over the ramus of the jaw, about half an inch in front of and to the left of the site for the auditory canal, completed the picture.

The tongue was apparently thickened and there was a small

ranula underneath. The throat was apparently normal, but the vault of the mouth was high and narrow. Slight blepharitis on each side.

The mother of the child was very sensitive about its deformity, and it was impossible to get the father to present himself for examination. As far as could be seen the mother was a normal, healthy woman; she said she had always been healthy and that her husband was a healthy man. She was requested to return to the Vanderbilt Clinic in order that photographs of the child might be taken, but she failed to appear, and one of my assistants, Dr. L. Buerger, went to Jersey City for the purpose of taking the photographs. After many difficulties he succeeded in getting pictures of the child in four positions. He had to hold the child himself and have a friend focus the camera, so that the pictures are not as satisfactory as one might wish.

No. 1 shows a front view, full face, and gives a fair representation of the difference between the two sides. The left lids can be seen to be more sunken than the right. With the aid of a magnifying glass the imperforate nostril can be made out. Nos. 2 and 3 give a fair idea of the crumpled auricle and the teats. The child died two weeks after I saw her for first time.

CASE II. X, child six months old, was brought to me for expert opinion as to whether there existed an eye in the left socket. The child had been carried to full term. There was some difficulty in delivery, instruments being employed. The midwife and physician attending the case thought that possibly the left eye had been destroyed in the process of delivery. Examination revealed an extraordinarily well built, well nourished child. The head was well formed and apparently normal in every respect except the left eye. The lids of this side were healthy and well formed, the lashes long and abundant. The conjunctival sac was normal in color and quite deep. At the bottom of the sac there was a bluish-white substance, evidently underneath the mucous membrane. This white patch moved synchronously with movements of the other eye. Palpation with the finger revealed practically nothing, the conjunctiva

CLAIBORNE. — Anophthalmos congenitus.

moved easily under the finger, but no hard substance could be felt, although a fair amount of pressure was used.

I gave it as my opinion that it was a case of anophthalmus congenitus, and was inclined to the notion that the whitish substance underneath the conjunctiva was either a rudimentary eyeball or the remnant of an eyeball which had been lost through intra-uterine inflammation.

At the first blush it would appear that anophthalmus congenitus is a very rare condition, but von Hippel has collected sixty-four cases of bilateral and twenty-three cases of unilateral anophthalmus. A number of others have been added to these so that the literature on the subject is quite abundant. Late literature of this subject can be found in E. von Hippel's paper on Congenital Anophthalmus in von Graefe's Archives, Vol. XLVII, page 227, and in an article entitled Malformations and Congenital Anomalies of the Eye in the new edition of Graefe-Saemisch. In Knapp's Archives, January of this year, two cases are reported, one by Zimmerman and the other by Brose.

This subject presents to me several points of interest. The first is the theories which exist in explanation of anophthalmus. It has been assumed by some that the proton of the eyeball is not formed at all in embryonic life and by others that the eyeball, at first well developed in utero, is destroyed by disease antecedent to birth. In the case reported by Brose there was congenital anophthalmus on one side, associated with microphthalmus. I can see that this fact is evidence in favor of the theory that the proton was not formed at all in the one case and that although formed on the other side, the development did not go to full fruition. A number of cases have been reported that would seem to support the theory that the eye well formed — or at least fairly well developed — has been destroyed by intra-uterine inflammation.

I am strongly inclined to think that all three of these conditions may exist, and that we should not look to any one cause to explain all cases. It seems not improbable that the proton of

the eyeball at times may not be formed at all — or, if primary and secondary optic vesicles are formed and the eye goes on to development, at some period of its development it may be arrested, just as there is arrested development in other organs of the body. Then again, it seems not improbable to me that intra-uterine inflammation may cause destruction of the eye.

Hippel has referred to some experiments which were made upon guinea pigs in which it was discovered that the animals, the eyes of whose parents had been inoculated with tuberculous material, had been born with malformation of the eyes. He also hints at the possibility of intra-uterine syphilis being the cause. I do not think that sufficient attention has been paid to these two diseases as the possible explanation of some cases of anophthalmus. It is to be hoped that further investigation along this line will be made. There have been a number of instances in which anophthalmus has occurred in several children of one family, as reported by Morano in the Italian annals of ophthalmology, Annale di Ophthal., XV, p. 70. According to this author, five cases were observed in one family.

The assumption that there has been a bacteriological destruction of the eye in utero can only be given weight by bacteriological investigation; at present there is little or no evidence in support of this view. Histological examination of a number of these eyes has shown the existence of a scleral and a choroidal tissue. Zimmerman, loc. cit., had the advantage of being able to examine, post mortem, the head of an adult man in which there was unilateral anophthalmus. It seems to be pretty well shown that it is rare for persons with anophthalmus to reach adult life, and his case, therefore, presented a peculiar opportunity for investigation. Zimmerman found degeneration of the left optic nerve corresponding to the anophthalmus, and his observations also showed interesting changes in the chiasm. The fact that the optic nerve had become much more reduced in size than the optic tract of the same side was additional proof of the well established fact of the partial decussation of the optic nerves — the left optic nerve being found

smaller than the right optic nerve, and the right optic tract smaller than the left optic tract. He found also deficient configuration of the left side of the skull, particularly with reference to the orbit.

I come now to the second point which I wish to make. At the meeting of the Ophthalmological Society of the United Kingdom, November 8, 1900, Dr. W. Ernest Thompson read a paper on the determination of the influence of the eye on the growth of the orbit with experimental investigations on one eye in young animals.

In this connection I desire to call particular attention to the deformity which existed in the nose and the ear — the imperforate auditory canal and the imperforate nostril — in the first case which I presented. Dr. Thompson's investigations were undertaken in order to determine whether removal of the eye in early life produces any fault in development of the orbit afterwards. It has been asserted that such takes place and also that it does not.

He conducted a series of experiments on a number of rabbits, one eye being enucleated under ether at the twentieth day of life. After six or eight months the animals were killed and the orbits and skulls carefully examined. A very marked difference was found between the anophthalmic side and the normal side. The deficiency was uniformly distributed over all the dimensions of the orbit, amounting to ten per cent. in the macerated skull and ten to fifteen per cent. in others.

He found there was greater diminution in the bony structures than in the soft parts.

In the second case to which I referred I ordered the use of a plumper in the conjunctival cavity in order not only that the conjunctiva might become used to the presence of a foreign body, but in order that the orbital tissues might be made to shrink a little and the bony structures in the neighborhood induced to grow and enlarge by pressure from within.

The investigations of Dr. Thompson point directly in the line of thought that I, at that time, entertained, and it has been

my habit ever since my first case of anophthalmus, and in very young persons whose eyes are removed, to introduce as quickly as possible either an artificial eye, or, in case the person is too young to wear an eye with safety, to suggest the use of a plumper.

It is then my purpose to definitely suggest that in all very young persons who have lost an eye through operative interference or congenital defect, even infants, plumpers be employed until such a time as an artificial eye can be worn with safety and comfort, the distinct purpose being to produce a growth of the skull, particularly of the orbit on the affected side, that the asymmetry of the face which almost invariably results may at least be somewhat modified. I think it may be concluded that anophthalmus congenitus is a well recognized condition, that it is bilateral at times, and at others unilateral, that there may be no evidences from external observation of the existence of an eye at the bottom of the sac, and that there may be at the bottom of the sac a semblance suggestive of a rudimentary eye; that in one-sided anophthalmus the condition may be coupled with a perfectly developed eye on the opposite side or with a microphthalmic eye on the opposite side; that the explanation of the condition may possibly lie in non-formation of the proton in embryonic life, or that there may be arrested development of a well formed eye, or that the eye may develop normally to a certain point and be subsequently destroyed — possibly by the microbes of suppuration — or by localized tuberculosis or syphilitic lesion.

THE EYE COMPLICATIONS IN A CASE OF ANCHYLOSTOMIASIS.

By HOWARD F. HANSELL, M.D.,
PHILADELPHIA, PENN.

At the request of Dr. Hermann B. Allen I examined the eyes of A. O., an Italian boy, fifteen years of age, a patient under his care in the medical wards of the Philadelphia Hospital, to determine what lesions, if any, could be traced to the presence of the intestinal parasite, the anchylostoma duodenalis. The boy came to America March 26, 1901, from Marsino, near Naples, Italy, and spent the two months intervening before his admission to the hospital in the western part of Pennsylvania. He had been employed before leaving Italy as a laborer in a brick yard. His father and mother and their other children were free from the disease.

He was apparently in good health until about two months ago, when he commenced to complain of general muscular weakness, abdominal pain, headache, spots before the eyes, and constipation. The symptoms increased in severity until he was obliged to take to his bed. During June his body temperature ranged between 97° and 102⅗°.

The blood count made June 4th gave red cells 871,875; white cells, 6,212; hemoglobin, 15 per cent.; on June 15th, red cells, 1,062,500; white cells, 2,620; hemoglobin, 15–20 per cent.

June 5th, general condition: The patient was lying in bed, too weak to raise his head from the pillow, profoundly anemic, skin yellowish-white, mucous membranes pale. The flesh was well preserved, the limbs and trunk showing no particular emaciation.

Ocular condition: The conjunctiva was transparent, the sclera white and bloodless, the cornea clear, the musculature unaffected, the lens and vitreous clear. The fundus reflex was light pink in hue, like that seen in pronounced blondes, although the patient was a decided brunette. Both optic papillæ were

œdematous, their outlines indistinct or lost, and the retinæ infiltrated with serum in a small zone surrounding each disk. In the right eye, to the lower nasal side of the papilla, were two small linear extravasations of blood, evidently in the fiber layer of the retina. In the left eye in the neighborhood of the fovea was a round hemorrhage, probably subretinal, and a few scattered flame-shaped extravasations. The retinal arteries were distinguished as nearly transparent lines. Their coats were not thickened, nor were the vessels contracted. The loss of coloring matter in the blood gave them a peculiar appearance. It seemed as though they were filled with water rather than with blood. The veins were tortuous and darker in color than the arteries, but much lighter than in health. The blood current could be distinctly seen as it coursed through the veins. Where the vein was inclined toward the observer the contained blood appeared dark, but in the horizontal part of the vessels the blood column reflected much more light. The blood extravasations were, I believe, not because of ruptured vessels, but rather a transudation, made possible by altered constituency of the blood.

June 22d. There is no change in the grade of the neuroretinal œdema. The hemorrhages, previously noted, have been absorbed, and no new ones have appeared.

Anchylostomiasis, an exceedingly common and often fatal disease in Egypt, Asia, India, and Southern Europe, is comparatively unknown in North America. The first reported case, as far as I can learn, is that of Dr. W. L. Blickhahn in the *Medical News* December 9, 1893, who describes the well-known anemia, but makes no mention of eye complications. Other reporters in the United States are Tebault, Chabert, and Duncan of cases in Louisiana, Lyell in Alabama and Georgia, Hensinger and Geddings in South Carolina, Little and Leatherman in Florida, and Clayton in Virginia. The affection has been thoroughly studied and extensively described by Eastern and European clinicians, such as Perroncito, Hogg, and Turner, MacDonald, Thornhill, and others, but with few exceptions they pay no attention to the eye. Fischer (Versamm. d. Ophthal. Gesells., Heidelberg, 1892)

reports the first case of neuro-retinitis with hemorrhages. In the discussion that followed the reading of his paper, Samelsohn queried whether the retinal hemorrhages were not produced by the toxin of the worm rather than by the condition of the blood. Leichterstern, who has had a large experience in cases of anchylostoma, made no statement about ocular complications in the published report of his cases in 1885. He studied the epidemics among the brick yard laborers in the vicinity of Cologne where the worm had been brought by Belgian mountaineers who worked in their own country during the winters. Perroncito, who was the first to determine that the cause of the illness and death of many of the diggers of the St. Gotthard tunnel was anchylostomiasis, found no retinal hemorrhages or œdema. Nieden also examined many cases, and saw no signs of involvement of the eyes. He considers the hemorrhages as an important incident, but in no way characteristic of the disease.

The worm is about 1 cm. long, 1 m. thick, and is round (on this slide, which I pass around, you will find an average specimen). It lives and thrives in the intestinal tract, where it clings by means of its sharp hooks with great tenacity to the mucous lining, particularly of the duodenum. It is constantly reproduced from the ova, and collects in great numbers. The important symptom of its presence is profound anemia. The parasite can be detected only by an examination of the feces for the ova, or in suspected cases after the administration of an effective anthelmintic, for the worm itself. Infection is easily possible among those of filthy habits of life through their food and water.

Thymol and felix mass separately in large doses or in combination are the best expulsive remedies when administered after twenty-four hours fasting.

Dr. Allyn has reported in full the history, from the medical standpoint, of the patient who is the subject of this paper, in *American Medicine*, July 13, 1901, with illustrations, and gives references to the literature. I am indebted to him for the courtesy of the permission to publish this paper.

CYST OF VITREOUS.

BY CARL KOLLER, M.D.,
NEW YORK CITY.

A rare and interesting intraocular condition was found accidentally in the right eye of the patient while he was coming under observation for a corneal erosion of the left eye. He is a healthy man of 32 years and knew nothing of the anomaly; he had noticed that the right eye was weaker, and attributed his visual defect to striking the eye against a door knob when a child.

The eye is outwardly of normal appearance. Vision = 6/6. Color perception good. Field of vision defective in a way presently to be described. The nasal and lower two-thirds of the disk appear to be hidden by a dazzling white body of egg shape, whose axis is almost vertical, slightly oblique (the upper more pointed pole leaning towards the nose). The general appearance of this body can best be likened to an egg-shaped pearl of dazzling white luster, with a tint reminding one of sea green and a faint bluish steel gray; some spots have a white, opaque, chalky look. As said above, the cyst covers the nasal and lower two-thirds of the disk completely, only the upper and nasal margin of the disk showing from under on a small spot. The cyst has three processes, of which two short ones end not far from the upper part of the disk, each pointedly drawn out, as it were, into the sheath of a blood vessel. The third one, starting from the anterior surface, not far from the lower pole, presents the well-known appearance of a persistent hyaloid artery, and ends blind near the nasal lower quadrant of the lens. The field of vision is defective, only the lower nasal quadrant, including the center, being preserved. It shows a striking resemblance to the fields in thrombosis of a principal branch of the central artery. In this case the defect is most likely due to pressure atrophy of a part of the optic nerve fibers. The cystoid body described is evi-

KOLLER — Cyst of Vitreous.

dently a widening of the hyaloid artery and its connective tissue sheath at its posterior extremity, where it emerges from the optic nerve. There are very few observations of this kind to be found in literature.

There are some cysts described at the head of the optic nerve, others more anteriorly situated, some immediately behind the lens, all of which owe their origin to some irregularity in the development, or in the disappearance of the hyaloid artery. However, the connection of these cysts with a persistent hyaloid was not evident, except in the two cases of Hill Griffith, which seem exactly the counterpart of my own. He says:*

"The remains (of the hyaloid artery) may assume a cystic appearance, either as small, round, steel-gray bodies attached to the disk, or as much longer globular formations. I have seen two remarkable examples of the latter variety, in each of which a large, bluish, cyst-like body in shape very much like a Florence oil flask lay with its base adherent to the posterior pole of the eye concealing the disk and surrounding parts for a considerable extent, the neck stretching far forward towards the lower ciliary organ. In one of the patients, a boy of seven years, there was no perception of light, and the defect was attributed to a severe blow on the eye. In the other, a girl of fourteen, it was said to be due to a recent illness, but the true explanation was arrived at only after watching the case for a long period, and finding that no change took place."

It is remarkable that in the first of Griffith's cases, as in my own, traumatism is given as the cause.

Closely related to these cysts of the vitreous body is a typical formation, for whose understanding we are indebted chiefly to the endeavors of Hirschberg;† he has given it the name: Angeborene schlauchfoermige Bindegewcosbildung ib Glaskœrper (congenital, funnel-shaped, connective tissue formation in the vitreous). Hirschberg, Mitvalsky, and others have described cases

* System of Diseases of the Eye by Norris and Oliver. Chapter on the Diseases of the Choroid and the Vitreous.

† Hirschberg Einfuehrung in die Augenheilkunde 1901, Zweite Haelfte, erste Abtheilung, page 202, where also look for the literature of the subject.

of funnel-shaped connective tissue, rooting in and around the head of the optic nerve, and fastened to the retina by tent-like processes. This formation likewise owes its origin to anomalies in the formation and disappearance of the hyaloid artery. The first of these cases were described by Liebreich and von Graefe as encysted cysticercus. The erroneous view that cysticercus could be encysted in the vitreous body, and thus made innocuous, passed in the text-books until the error was cleared up and corrected by Hirschberg.

For the drawing of the ophthalmoscopic picture, the writer is indebted to the skill of Dr. Percy Friedenberg of New York.

DISLOCATION OF LACHRYMAL GLAND.

By W. F. MITTENDORF, M.D.,

New York City.

The patient to whom this accident happened is a young lady about twenty years of age. Her brother tried to mesmerize her, and she, making believe that he had succeeded, fell forward and in this way struck his outstretched hand in such a manner that his index or his middle finger struck the upper part of the outer corner of her left eye. She experienced severe pain, but her brother-in-law, who is a physician, residing in my neighborhood, found that the eye itself was not injured, and had ice applications made for several hours. The eye appeared to be perfectly relieved, and nothing unusual was discovered until the next day, when the young lady found that there was a swelling on the upper and temporal part of the eyeball, which hardly showed with the lids in the normal condition, but became very apparent on raising the upper lid. As the swelling did not diminish or change, the young lady came to my office with her brother-in-law. The eye showed apparently no signs of the injury except a slight scratch of the fingernail near the inner corner and a

perfectly white almondlike swelling at the upper and outer part of the eyeball, over which the conjunctiva was freely movable. The latter showed no signs of irritation, and the rest of the eye appeared perfectly normal and so was the vision of the eye, nor was the mobility interfered with in any way. The tumor itself was slightly painful to the touch and could be pushed upward a little, but descended immediately as soon as the pressure exerted upon it was relaxed. The upper and outer part of the orbit felt a little tender, but no perceptible difference of the two sides could be made out. Yet the diagnosis, a dislocation of the lachrymal gland, suggested itself immediately to me. The treatment of the case was simply expectant, as pressure failed to replace the swollen part and as it caused no visible deformity.

The swelling has remained practically in the same condition up to date, which is nearly three months after the accident, and as the tumor is still a little tender, and as a subconjunctival hemorrhage as well as a dislocation of a part of the adipose tissue of the orbit could easily be excluded, I think that the diagnosis of a dislocation of the lachrymal gland could be made with reasonable certainty, although the lachrymal secretion of the affected side does not differ apparently from that of the right side.

HUNTERIAN CHANCRE OF CARUNCLE, RIGHT EYE.

By N. J. HEPBURN, M.D.,

New York City.

The following case is reported chiefly on account of its infrequency among the extra-genital primary lesions and as an example of the difficulty of tracing the source of infection.

K. B. first called at the office on December 13, 1900, with the following history: About three weeks previously she had been struck in the inner corner of the right eye and on the

nose by a package thrown carelessly. The eye was sore for a few days, but got entirely well, as she says, in a week. A week later, however, it began to get red again at the inner corner, and became so uncomfortable that she was unable to work, and consulted Drs. Lewis and Van Fleet at the Manhattan Eye and Ear Hospital. They recognized the character of the affection, but, frightened by the examination and close questioning, she did not return there for treatment, but consulted me instead.

The eyelids at that time were much swollen, particularly the nasal half, and the lower more than the upper lid. There was much chemosis of the ocular conjunctiva, also more marked on the nasal side and below. The caruncle was swollen and excoriated, and at its folding over on the conjunctiva below there was an erosion without much evidence of secretion. Under repeated applications of cocaine and supra-renal extract the swelling of the conjunctiva subsided until it appeared as if there could be felt a parchment base to the erosion, the rest of the caruncle being somewhat swollen but containing no deposit.

The diagnosis of Hunterian chancre was made, the patient not being informed of the conclusion reached, and constitutional treatment at once commenced, with soothing local treatment. The lesion healed up in less than three weeks without any trouble whatever, but the patient, feeling perfectly well, ceased to report and stopped treatment, and came back on April 21, 1901, with marked secondary eruption and circumscribed patches of alopecia in both eyebrows and the right upper eyelid and enlarged post-cervical and epitrochlear glands. She was again put on constitutional treatment and still continues it irregularly.

DISCUSSION.

Dr. Pooley. — It is rather strange that Dr. Hepburn in his researches did not find any other cases where primary infection of this kind occurred in the caruncle. Some years ago, when writing a chapter on venereal diseases of the eye for a textbook on genito-urinary diseases, I found that the most com-

mon seat of these lesions about the eye, next to the lids, was the caruncle.

DR. RING. — I reported a case in the *Medical Record* about eight years ago very similar indeed to this, which occurred in the caruncle.

DR. HARROWER. — I have here some photographs of a case of primary infection of the lid in a girl thirteen years of age.

DR. HEPBURN. — In regard to the frequency of infection of the caruncle, I want to say that I inquired of Dr. Bulkeley, who has made a study of extra-genital chancres, and he appeared to be quite positive that there was nothing of the kind on record.

A CORNEAL LOUPE.

BY CARL KOLLER, M.D.,
NEW YORK CITY.

I wish to demonstrate the model of a little instrument which I have constructed for a more thorough and easy examination of the cornea and of the anterior segment of the eye in general.

As in present use, oblique illumination is practiced by concentrating the light of a candle or an argand gas burner by means of a two or two and one-half inch lens. As a rule no enlargement is used, but occasionally a second lens is used as a magnifying glass.

It has occurred to me that it would be of advantage to combine condenser and magnifying lens in such a fashion that the light is concentrated upon the focus of a magnifying lens. For magnifier I have used a one inch lens, at one side of which a parabolic reflector is attached, so that the axis passes through the focus of the lens, intersecting the optical axis of the lens at an angle of 80°. A little incandescent lamp in the focus of the paraboloid acts as source of light. The illumination is to come from the temporal side and therefore is made reversible for use on either eye. A dry cell battery supplies the electricity for the incandescent lamp.

The enlargement obtained is about 12 – 14 compared with ordinary reading distance. Its field of vision is very large. The handling is simple, and the cost cannot be very great considering the simplicity of construction.

After I tried the instrument on a number of patients I was struck by the wealth of detail to be observed, which I had never

thought of before as obtainable. I hope that it will be of practical use in diagnosis and operations, and that besides it will be instrumental in enlarging our knowledge of pathological conditions and developments.*

I have to render my thanks to Mr. E. B. Meyrowitz for his collaboration in the mechanical construction and for his putting at my disposal the means of his well-known establishment.

*I intend by using a weaker magnifying glass to fit the instrument also for use in minor operations. After I had constructed this instrument and even demonstrated it to a few colleagues I happened to find in the report of the 27th meeting of the German Ophthalmological Society, held at Heidelberg in 1894, the description of a corneal composite microscope with illumination, which had been constructed by Schanz in conjunction with Czapski of the Zeiss Institute in Jena, and which had been changed by Barkan of San Francisco, into a stereoscopic binocular microscope. From the description and picture it seems to be quite a formidable affair and from the statements of Schanz cannot accomplish more than this little instrument. I can only assure you that I have worked quite independently of these authors.

INCANDESCENT ELECTRIC LAMP FOR OPHTHALMOSCOPIC EXAMINATION.

BY CHARLES H. WILLIAMS, M.D.,

BOSTON, MASS.

The glass globe of this lamp is about three inches and a half in diameter, frosted on its front half and made with a silvered mirror on its posterior half. In this way the incandescent film

is not seen, but the whole frosted surface is a source of light, which is much increased by reflection from the mirrored surface behind it.

In the stand which carries the lamp is a small rheostat in which the coils of resistant wire are wound on metal tubes and covered with enamel, like those used in the base of an electric fan; there are six loops of wire, each with a resistance of twenty-five ohms, and by placing more or less of these loops in the circuit the intensity of the light can be controlled without changing the area of the lighted surface in the lamp.

The lamp is attached to the vertical rod by a spring, so that it can be easily raised or lowered, and in comparing it with an argand burner it has seemed to give a better light for ophthalmoscopic work than the gas. On testing it with a Bunsen photometer disc it is found to give more light with the full current than the argand burner with the gas turned on full, and with the rheostat the intensity can be controlled as desired.

A NEW INSTRUMENT FOR TESTING THE POSITION OF THE AXES OF THE EYES.

BY CHARLES H. WILLIAMS, M.D.,
BOSTON, MASS.

This instrument consists of four hollow tubes arranged in the shape of a cross. Inside the tubes are a series of incandescent electric lamps, and on the front of each tube is a slot half an inch wide covered by red glass and extending the whole length of the tube, each tube being eighteen inches long from the point of their crossing. When a person looks at it he sees a red cross, when all the lights are glowing, one arm being vertical, the other horizontal.

In front of this red cross, and pivoted at its center, is a framework of wire strong enough to carry a series of tin cylinders about four inches long and an inch and a half in diameter. Within each cylinder is a small electric light and attached to its end is a green glass painted so as to show a green number.

If all the lights in the instrument were lighted at one time

we should see a red cross and over it a series of green numbers placed at such distances from the center of the instrument as would correspond to the deviation produced by a prism of corresponding number when held before the eye at a distance of twenty feet from the instrument.

To use the instrument a pair of spectacles is placed before the patient's eyes, one side of the spectacle being filled with a



In taking the photograph of the above instrument the camera was placed a little to one side so as to give the construction, but in use the patient is placed directly in front of the instrument, so that the line of numbers comes directly over the corresponding arm of the cross below it.

red and the other with a green glass; if the red glass is before the right eye the patient will see only the red lines with this eye, and only the green numbers through the green glass which covers the left eye.

By means of a switch the lighting of the instrument is controlled so that at first only the vertical red lines and the horizontal green series of numbers are lighted at the same time.

On looking through the spectacles the right eye sees the vertical red line and the left eye sees the horizontal green figures, and if the red line appears to stand to the left of the center of the instrument, say over number 5, it would show that there was a divergence in the position of the axes of the eyes equal to a prism of five degrees. On the other hand, if the red line appeared to stand to the right, say over number 4, it would show that there was a convergence equal to a prism of four degrees. If the red line appeared in its normal position between the 1 and 2, and nearer the 1 than the 2, it would show that there was no abnormal divergence or convergence of the axes. The switch is then turned so as to light only the horizontal red line and the vertical green figures, and if the person sees the red line as apparently standing between the 1 and 2 there is no abnormal deviation of the axes up or down, but if the red line appears at number 3, below the center of the instrument, it shows that the axis of one eye stands above that of the other, equal to a prism of three degrees, or if the red line stands near number 4, above the center, it would show that the axis stood below that of the other an amount equal to the deviation caused by a prism of four degrees.

The switch is now turned so as to light only the vertical red line and the vertical series of green figures, and if the patient sees the line and figures as coinciding, or as standing parallel to each other, there is no torsion; that is, the vertical meridian of each eye is in its normal position, but if the line of figures and the red line are crossed, or if they stand at an angle to each other, then the vertical meridians of the two eyes are not parallel, and the number of degrees which it is necessary to turn the frame carrying the green numbers, in order to make the red line and the line of figures appear as parallel, will show the degrees of torsion, and this can be measured on the scale at the bottom of the instrument.

AN IMPROVED LANTERN FOR DETECTING COLOR-BLINDNESS, TO SUPPLEMENT THE WOOL TESTS.

BY WILLIAM THOMSON, M.D.,

AND

ARCHIBALD G. THOMSON, M.D.,

PHILADELPHIA, PENN.

The present model is a more simple form of the one described a year ago in the last edition of Nettleship's book on Diseases of the Eye, and exhibited at the meeting of the American Ophthalmological Society in Washington.*

The lamp chimney and two discs are unchanged in form. Instead of ten holes there are now but seven, and the English measure is used in place of the French. The holes are one-half inch, except the small opening one-twelfth of an inch, which is equal in size to an angle of one minute at XX feet, and are to be viewed from the standard distance of twenty feet.

The lower disc contains the red, white, plain and ground, green, and blue glasses, similar to those used in railroad signals. The upper disc is for a "cross examination," and has white, ground white, the three "confusion colors," viz.: London smoke, pink, and blue-green, which appear white to the ordinary color-blind, and cobalt, which to him appears and is called blue, having much red in it to the normal eye.

The letters of the alphabet designate the upper holes, and the figures the lower ones, when an accurate record is needed.

The examination is made in a dark room, the chimney being placed on its lamp, on an Argand burner, a spring candlestick, or over an electric light. The small opening may be taken as the standard of color perception at twenty feet, and the large one would be therefore ten times in size. The color-blind make gross mistakes and can have their defects briefly stated on a

*See Transactions for 1900, p. 189.

record or blank by the examiner, using the letters and figures for this purpose.

A lantern of some kind has long been in use, that of Prof. Donders having been employed in all my examinations for years past. This one is of great value and should be used in connection with all of the wool tests hereafter by not only the ophthalmic surgeon but by all lay examiners.

The uncertainties of Holmgren's generally-used test wools

are pointed out by Eldredge-Green in the London *Lancet* for April 13th, in a paper which should be consulted and which calls attention to the necessity of using transmitted light in lanterns. Of Holmgren's test he says: "If there be at the present time any specialist who is in doubt about its efficacy I shall be only too pleased to give him an opportunity of examining a case which has passed the test even under the most rigid and careful examination."

There are doubtful cases that all have encountered when using wools alone, and I am led to report the details of several of these.

I was aided in the first case by a young ophthalmic surgeon who suffers from *green*-red blindness, the form of color defect which I have found the most difficult to detect by the wool test of Holmgren and its varieties. Two years ago this young man had spent much time in trying Holmgren's test, but he always made an average of five failures. With the color stick he promptly selects the reds and the pinks, and half of the greens, making mistakes only in the group of light greens, which, with their confusion colors he sees as yellowish-brown. With the new wool test arranged for these difficult cases, the red colors being left out entirely, he does not select any blues with the rose or pinks, but reveals his real defect by confusing them with the greens. He so nearly passes the wool test that it is seen why practical examiners say that the Holmgren test does not succeed except in the hands of ophthalmic experts and cannot be used by a lay examiner. The secret of his difficulty is revealed by the use of the spectroscope. Like all color-blind, the spectrum of this green-blind man presents to him but two colors, yellow and blue. This coincides with the usual spectrum of the red-blind man, whose spectrum is shortened at the red end. To show that there is a red perception in this case, a violet color screen, composed of red and blue, was placed in front of the spectroscope, when he lost all of the yellow and green part, but clearly saw the red end. A red screen also cut off his entire spectrum except the red portion, as it does in persons of normal color perception. This seems to show that he is dichromic, and partially color-blind, having the red and blue sensations only, but lacking the green. That he sees red objects is proved also by his having the acquired red-blindness when looking at red objects through a peacock-green glass, a defect which is also induced in a normal eye. When tested with wools he sees the reds too well to fail in selecting them, as he also does the red in the pinks, for he never matches them with

blue. He does not fail to see changes in the fundus oculi, nor in pictures of it — nor does he ever confound red with black ink, as the *red*-green blind may do. He seems able to distinguish the diseases that cause changes of color in the eyes of patients. He classified the wools of a full set of Holmgren, placing the various colors together fairly well, making mistakes mainly with the greens, which for him appeared as gray. He is therefore classed as a *green*-red color-blind. Attention is called to his selections preserved from the skeins, with their names, on this card of bristol board.

Next an engineman from a railroad was seen soon after, whose symptoms were so similar as to need no further description. He had been examined by a doctor employed by his road, and found not defective. By another doctor he was considered as partly color-blind. He had been so carefully trained by his two daughters in the wool tests that he felt sure he would pass my examination. With the stick he made no mistakes with the red or rose skeins. He said a large imitation strawberry in my box, three by two inches, with red flannel body and yellow-green calyx, looked like a pear. When confronted with my lantern, however, the ophthalmic scholar and the trained veteran engineman were both helpless, and failed on every test by transmitted light. Red was called green or white; green was called red or white; the blue-green was called white or blue; the pink, gray; and the cobalts, blue. Any tyro could have decided these cases with the lantern.

The ophthalmic surgeon, although calling red and seeing it correctly generally, yet had but one name for the spring grass; that he was sure was red. His defect was first revealed by his insisting that a green ribbon on a lady's neck was red.

A similar case gave me much trouble and discussion on the P. R. R., where a signalman, a member of a labor union, refused to acknowledge his color defect, detected by the stick by a lay examiner, and spent much time and money in being coached with the color stick and wools by a local doctor, and by his wife with Holmgren's wools. My use of colored lights put his case

beyond dispute, much to the credit of the lantern. He confused the green and red glasses from the test case when held one meter away. His selections of skeins from Holmgren are preserved on the card of bristol board.

He was re-examined several times, and had the sympathy of his division superintendent, who used the stick himself, and seemed unable to understand how a color-blind man could pass the red and rose examination without a fault. The man seemed more anxious to overturn the wool tests of the road than to gain any advantage for himself. He finally, at the last interview, refused to submit to any test but the stick, and cut short his examination, refusing to look at any of my lights, where he knew he would be detected. He concluded by requesting me to sell him my sets of Oliver and Holmgren to continue his education. His card of wool selection indicates *green*-red defect.

May 31, 1901. Examination of applicant for navy. C. C. C., æt. 18, was found color-blind by wools and rejected.

R. = 7/5.

V. L. = 7/5.

Never conscious of any defect. With the spectroscope he sees but two colors, yellow and blue, each fading to dark, with a gray band where they mingle. With Pole's pictures of spectra he says he sees some red in the normal one. Of his three squares of color, pink, green, and gray, he says they are alike in color, but the pink one is the most green. With my lantern he fails to call the red except in the ten mm. size. He calls it green and red; and calls my three "confusion colors," viz.: pink, green, and gray, all a shade of white, or off white, without color. He calls the cobalt blue, and the same when made pink by the blue of lower disc. He calls the blue light correctly and has a fine perception for this color. The greens he does not recognize. Has feeble color sense.

With the color stick he selects seven greens and three browns with the green skein, and makes but one mistake with the red. He makes no mistakes with rose, and is therefore not red-blind.

With Holmgren's wools he divides them into ten piles. The fact of mixing the pinks and greens indicates green-red blindness. The results are interesting. His grays are combined with light pink and light green. The lantern gave prompt and decided results and was superior to the wool tests. He is dichromic, seeing nature with the red and blue sensations only. His selection of wools preserved on the card indicates *green*-red blindness.

These cases are rare and give rise to disputes when tested with wools alone. On the color stick they pass the red and rose tests, since their red perception is enough to guide them, and fail only on perhaps five of the green and confusion colors for green. An examiner without the clue to the green-red blindness hesitates and does not decide against a man who is so good on his reds. These cases form a sharp contrast with the usual ones of red-green blindness — with a shortened spectrum at the red end, where red perception is absent, and all the startling and fantastic phenomena of color-blindness are found — viz.: red matched with green in wools, rose with blue, inability to distinguish red fruits or flowers from their leaves, mistaking blood stains for ink, and speaking of the heavenly blue of the cheek of the best girl.

Mrs. S., the only color-blind woman of whom I have a record, I now mention to enable me to place before you her card as the best record of her defect in the wools selected and placed together from a Holmgren set. Her selection is a contrast with the others mentioned, and indicates the *red*-green blindness so commonly met with.

She was 50. Had been corrected for hypermetropia; full acuity of vision. From childhood color-blind. Two sisters were the same; her father and his brother, and her mother's brother were all color-blind. Of five sisters, three are color-blind. Two sons are color-blind. One was tested by me with the spectroscope and had, like his mother, a spectrum of yellow and blue, both shortened at the red end, with a neutral band at the center. The mother tells me she had once bought a red

dress for a black one, and could not distinguish one color from the other. Once her little daughter ran to her with blood on her white dress from a wound in the hand, and Mrs. S. exclaimed, "Who has thrown that ink on your dress?" Her card of preserved wools tells the story and indicates by its confusion colors with red and blue the *red*-green defect, which is her form of defect.

One more interesting record of a *red*-green railroad man



The long thread indicates the color to be matched, those below it those selected. The Figures I. Red; II. Yellow; III. Green; IV. Blue; V. Gray.

remains. His selections are those usually met with in the use of the Holmgren and kindred wool tests. He was detected by the color stick, was one of the doubtful cases that demanded an expert examination, and furnished this valued record. His red indicates, as does his pink, an absence of red sensation.

Should color photography ever be perfected, such records as these, consisting of cuttings of wool selected by the five color-blind described, could be not only preserved but presented for

study to all interested in the subject as unique and faithful records of each case.

The use of the lantern here also disposes of all doubt of the presence of color-blindness with promptness and certainty and condemns the applicant; but the diagnosis of *green*-red blindness requires the spectroscope, aided by a number of color screens or glasses, to settle any controversies or doubts.

To conclude, it appears that we may hope to render more clear the defects of the various wool tests. This seems desirable if we favor the use, where it seems proper, of non-professional examiners. My experience leads me to keep down the number of skeins in a set, and to insist on the use of tags with numbers that can be put on a written record and submitted to the supervision of an expert on the subject. This has been done with the color stick and the new wool test, both simple forms of Holmgren's test. Holmgren's test and instructions as usually employed presuppose that the examiner shall be able to furnish an infallible decision himself, which might be difficult for an expert of high training.

I am now of the opinion that the use of colored lights can be made by the layman to the saving of much time and needless discussion. My own conclusions have for years been formed from transmitted lights of various kinds, and I have offered a simple and effective form of a lantern for your consideration.

Queen & Company supply the lantern, accompanied by a certificate, signed by Dr. Thomson, of its accuracy.

TWO NEW INSTRUMENTS.

By SAMUEL THEOBALD, M.D.,
Baltimore, Md.

In one of his papers upon operations for cataract, Dr. Knapp, if I am not mistaken, has pointed out that in comparing the relative advantages of the simple and the combined methods of extraction it must not be lost sight of that incarceration of the

iris in the corneal wound is a complication not wholly limited to the operation without iridectomy; but that, in spite of our efforts to avoid it, it occurs occasionally in, and measurably mars the results of, combined extraction as well.

If the outcome of an iridectomy done under such circum-



FIG. 1.— About three-fourths actual size.

stances is not invariably all that could be desired, it goes without saying that when it is performed upon an inflamed or degenerated iris — for the control, perhaps, of glaucoma or iridocyclitis — we are still less sure of securing the classical result which we find pictured in the books. In a word, I think it will be admitted that our iridectomies are not always just what we



FIG. 2.— About two-thirds actual size.

might wish them to be. They are seldom the keyhole affairs which the illustrators have made us familiar with; and, though extensive incarceration may not be of frequent occurrence, it

is not uncommon to find one margin of the coloboma different in shape from the other or lying in a different plane, indicating, at least, a slight adhesion between the iris and the inner lip of the corneal section.

Some months since the idea suggested itself to me that by reversing the usual curve of the iridectomy scissors, so that instead of the convex surface the concavity of the blades should be applied to the convexity of the corneal border, a better mechanical effect might be obtained, and a cleaner, more perfect coloboma be secured.

I intrusted the carrying out of this idea to Mr. Neuhaus, one of our Baltimore instrument makers,* and the scissors shown you, made after a model which I furnished him, are the result of his handicraft (Fig. 1). He has also made me a pair with the ordinary scissor handles, and doubtless they could be made in the fashion of De Wecker's scissors, if desired.

They are not well adapted to the making of an iridectomy by several successive cuts; but for the purpose for which they were intended — the removal of a piece of iris by a single cut — I have found them to be all that I anticipated. I have used them in cataract extractions and in iridectomies for glaucoma and for various other purposes, and have been convinced that a more perfect coloboma was obtained; that the iris was more cleanly removed up to its ciliary attachment, and that adhesions between the iris and the corneal wound were to a great extent obviated.

The other instrument which I wish to bring to your notice is a lachrymal probe, contrived for a special purpose and intended to supplement the large probes which I have employed for many years.

As I have had occasion to point out heretofore, in the later stages of the radical treatment of strictures of the lachrymal duct, when the interval between the probings has been increased to several weeks, it occasionally happens that a contraction occurring at the juncture of the canaliculus and the lachrymal sac

* Chas. Neuhaus & Co., 510 N. Eutaw St., Baltimore.

makes it difficult to insinuate into the sac the large probe which had been passed previously without difficulty.* I have also dwelt upon another class of cases, in which the existence of a firm constriction at this same point complicates and retards the early stages of the probing treatment, making it difficult or impracticable to introduce other than a quite small probe into the sac, though a considerably larger one, could it be gotten through this constriction, might be passed easily through the strictures in the duct itself.

The probe (Fig. 2) which I show you was devised solely to meet the conditions existing in these two classes of cases — to accomplish the rapid and effectual dilation of strictures or contractions at the juncture of the canaliculus and the sac, and thus permit the passage of the ordinary probes. For probing the duct itself, it is manifestly unsuited. For several mm. from the tip, as you will see, it is quite slender and then dilates rapidly to a much larger size. The exact size is not a matter of much moment; but I have fixed upon No. 12 and No. 14 for the larger portions and No. 3 for the slender part near the ends. It bears some resemblance to the well-known conical probe of Weber, but a comparison of the two will show that they differ materially. Weber's probe increases in size so gradually that its whole length must needs be passed into the duct to accomplish what this one will effect when introduced but a third as far.

It remains but to add that an experience extending over some months has convinced me that it meets the conditions for which it was contrived, and that it has proved distinctly helpful.†

* Diseases of the Lachrymal Apparatus. Norris and Oliver's System of Diseases of the Eye, Vol. III.

† The Chas. Willms Surg. Instrument Mfg. Co., Howard and Saratoga Sts., Baltimore, have made this probe for me in a very satisfactory manner. Mr. E. B. Meyrowitz, 104 East 23d St., New York, also has undertaken to make both the iris scissors and the probe.

EXHIBITION OF PHOTOGRAPHS OF CASES.

BY WALTER EYRE LAMBERT, M.D.,
NEW YORK, N. Y.

CASE I.

CONGENITAL COLOBOMA OF LID.

On July 13, 1901, a very poorly-nourished, delicate-looking child, female, aged seven, was brought to see me at the New York Eye & Ear Infirmary on account of a defect in the upper lid of left eye, which had existed since birth. An examination showed it to be a case of congenital coloboma of the upper lid, with a symblepharon extending from the margin of the cornea upwards and inwards, corresponding to the defect in the lid, and attached at its base to the cutaneous surface of the lid at what would have been the inner canthus (see Fig. 1). The child also had other evidences of congenital malformation, namely, web fingers on both hands, and web toes on both feet. The operation was made under ether, the symblepharon dissected out, orbital conjunctiva undermined and brought together with fine sutures, the edges of coloboma denuded and brought together with sutures, external canthoplasty made to relieve tension of sutures, and bandage applied. All except the lower portion of the wound healed by first intention, very much improving the condition, leaving, however, a small triangular coloboma.

The patient was re-admitted in two weeks and a second similar operation was made, the edges of the coloboma being denuded and sutured. The result was most satisfactory.

DISCUSSION.

DR. GRUENING. — I have had a similar case of congenital coloboma on the lid and operated in the same way except that I had better success by using what is called an intramarginal suture.

LAMBERT. — Coloboma lid.

DR. KOLLER. — I have operated also on a case and in order to avoid this difficulty I have used such a suture as is used in treating hare-lip cases.

CASE II.

HYPERTROPHY OF LACHRYMAL GLAND.

During my service at the New York Eye & Ear Infirmary last summer a young woman, aged nineteen, presented herself for treatment on account of a very extensive swelling on both upper lids, which she first noticed six years ago and which has been gradually increasing since.

Fig. 1 gives a very good idea of the appearance of the patient.

On examining the lids it was found that a very extensive tumor existed, which increased very much in size when the patient leaned forward, depressing the head.

The tumor gave the impression on palpation of being an angioma, and was supposed to be such. Operation was advised and consented to by the patient. The right eye, in which the tumor seemed to be larger than the left, was first operated upon, a horizontal incision being made in the upper lid and the tumor carefully dissected out, which was very soon discovered during the operation to be, not an angioma but a glandular tumor, extending very deeply back into the orbit.

The wound in the lid was sutured and bandage applied, and in a few days the patient was discharged cured. A certain amount of ptosis followed the operation and remained for about two weeks, but subsequently entirely disappeared.

The left eye was operated upon a few weeks afterwards, with similar satisfactory result.

Fig. 2 is a picture taken about one month after the operation, and shows the very satisfactory result of the operation. The specimens were referred to Dr. George S. Dixon, Assistant Pathologist of the New York Eye & Ear Infirmary, who submitted the following report:

"In the matter of Miss Mary McQ., nineteen years, No. 20,049, operated on by you in September, 1900, I beg leave to

say that the bulk of the tumor consisted of lachrymal gland tissue. The remainder appeared to be orbital fat, which was quite vascular. Nothing was observed pointing to malignancy, and the diagnosis of hypertrophied lachrymal gland stands."

CASE III.

PAPILLOMA OF ORBITAL CONJUNCTIVA AND CORNEA.

In July, 1900, a man fifty-one years of age came to the New York Eye & Ear Infirmary with a very large warty growth on the left eye, which he stated had been coming on for the past six months.

A large fungous mass was found protruding between the eyelids and preventing their closing. The growth extended from the median line of the cornea to the inner canthus, and was attached to the sclero-corneal margin by a small pedicle about a quarter of an inch in diameter, the remaining portion of growth simply lying on the surface of the globe. Fig. 1, taken from a photograph, gives a very good idea of the appearance of the growth.

The diagnosis of papilloma was made and its removal advised. The operation was made under ether, the growth carefully dissected out from the conjunctiva and cornea, and the base thoroughly cauterized with the actual cautery.

His recovery was rapid and uninterrupted, leaving but a slight opacity on the corneal margin, where it had been attached. The growth was submitted to Dr. Dixon, Assistant Pathologist of the New York Eye & Ear Infirmary, who gave the following report:

"In the case of Mr. A. B., fifty-one years old (No. 22,686), operated on by you in July, 1900, I beg leave to say that the growth was composed of epithelial and fibrous connective tissue arranged in the form of papilloma. There was some superficial necrosis. A mild infection was present, but it did not extend to any considerable depth. It was due apparently to a staphylococcus, which in the deeper portions of the growth were in distinct colonies. A few diplococci were seen near the surface. Diagnosis, infected papilloma."

FIG. 1.

Fig. II

LAMBERT. — Hypertrophy lachrymal gland.

FIG. 1.

FIG. 2.

LAMBERT. — Papilloma of conjunctiva.

Fig. 2 shows appearance of eye thirty-two days after the removal of growth. The patient was seen a few weeks after the operation and the eye was then in very good condition, without any indication of a recurrence. Several efforts have been made to see the patient since that time, but without success. So, unfortunately, I am unable to report subsequent history of the case.

The special point of interest in this case is the situation of the growth, for, although papilloma of the conjunctiva is not very uncommon, but few cases have been reported in which the cornea was affected and only in very rare cases is it primarily the point of origin.

In the Reports of the New York Eye & Ear Infirmary, January, 1896, Dr. Weeks reports two cases of papilloma of the conjunctiva and one of the conjunctiva and cornea. In the latter case the disease had advanced to such a stage that the eyeball had to be enucleated. It is very important that the surface from which the papilloma is removed be thoroughly cauterized.

I am indebted to Dr. Weeks, who was present at the operation, for suggesting a more vigorous use of the cautery than I probably would have otherwise employed.

TRANSACTIONS

OF THE

AMERICAN

OPHTHALMOLOGICAL SOCIETY.

Thirty-eighth Annual Meeting.

NEW LONDON, CONN., 1902.

Vol. IX, Part III.

HARTFORD:
PUBLISHED BY THE SOCIETY,
1902.

BOSTON MEDICAL
MAR 6 1903
LIBRARY.

Press of The Case, Lockwood & Brainard Company.

CATALOGUED
MAR 6 1903
E. H. B.

TABLE OF CONTENTS.

	PAGE.
List of Members,	411
In Memoriam Henry D. Noyes,	415
Minutes of the Proceedings,	423
The post-operative history of fifty cases of Simple Chronic Glaucoma; Dr. C. S. Bull,	429
Notes of cases of simple Glaucoma treated by resection of the superior ganglion of the cervical sympathetic, with a report of the microscopical examination of the excised ganglia; Dr. John E. Weeks,	441
A case of Endothelioma of the orbit; Dr. C. A. Veasey,	464
Melano-sarcoma of choroid and orbit; Dr. S. B. St. John,	469
Congenital orbital cyst with microphthalmos; Dr. G. C. Harlan,	474
Case of metastatic carcinoma of one optic nerve with peculiar degenerations of both nerves; Dr. Ward A. Holden,	477
Case of double metastatic carcinoma; Dr. E. E. Jack,	488
A histologic study of the crystalline lenses of a hanged criminal; Dr. C. A. Oliver,	490
A preliminary study of the ocular changes produced by the injection of pure cultures of the bacillus typhosus into the vitreous chambers of rabbits and guinea-pigs; Dr. C. A. Oliver,	494
The conjunctival flap and the cataract wound; Drs. F. M. Wilson and H. S. Miles,	503
A simple use of the circle of diffusion in the correction of ametropia; Drs. Wm. Thomson and A. G. Thomson,	512
Two unusual complications following cataract extraction, (1) Death, after cataract extraction, from diabetes, (2) Delirium tremens following extraction of cataract; Dr. T. R. Pooley,	518
Two cases of detachment of the retina, traumatic in origin, treated by drainage incision; Dr. W. K. Rogers,	525
A methyl-alcohol debauch and its results; Dr. H. W. Ring,	529
A case of color-blindness in a railroad employee due to tobacco amblyopia, failing to be recognized by any of the wool tests but immediately detected by lamp; Dr. A. G. Thomson,	540
A case of cavernous-sinus thrombosis following grippe — autopsy; Dr. E. E. Jack,	545
Treatment of epithelioma of the eyelids by X-rays; Dr. W. M. Sweet,	550
The ideal result to be kept in view in the operative treatment of strabismus in children; Dr. S. Theobald,	556

PAGE.

The extraction of metallic fragments from the vitreous chamber; Dr. S. D. Risley, ... 562

The value of partial resection of the tarsal cartilage in the operative treatment of congenital ptosis; Dr. E. Gruening, ... 574

Acute circumscribed exudative chorio-retinitis; Dr. H. Friedenwald, 577

A contribution to the knowledge of ossification occurring in the eye, with clinical report of cases occurring in the service at Lakeside Hospital; Drs. B. L. Millikin and J. C. Darby, ... 589

Improvement of vision in amblyopia from non-use; Dr. H. Friedenwald, ... 612

A point in the Dioptrics of astigmatic refraction, illustrated by a new model; Dr. H. Knapp, ... 620

The desirability of a uniform notation of the meridians of the eyes and those of the visual field; Dr. H. Knapp, ... 622

Tumor of the optic nerve with intra-cranial complications; Dr. F. Buller, ... 629

Temporary ligation of the canaliculi as a means of preventing wound infections in operations on the eye; Dr. F. Buller, ... 633

Progress toward greater uniformity in the examination of the vision, color-sense, and hearing of railroad employees; Dr. C. H. Williams, ... 639

On the confusion in methods of numbering and using prisms; Dr. L. Howe, ... 654

Additional notes on a case of high astigmatism; Dr. B. L. Millikin, . 657

Permanent left hemianopsia, sequel of puerperal eclampsia; Dr. H. Woods, ... 659

The use of subconjunctival injections of sublimate in cases of orbital cellulitis; Dr. C. S. Bull, ... 664

On the primary insertions of the ocular muscles; Dr. L. Howe, . 668

A case of unilateral hemianopsia in which the Wernicke hemianopsic pupillary reaction was present; Dr. C. J. Kipp. 678

MEMBERS

OF THE

American Ophthalmological Society.

1902-1903.

ACTIVE MEMBERS.

The (*) indicates *Associate* Members.

NAME.	RESIDENCE.	PLACE.
Dr. A. E. ADAMS,	44 Grand Street,	Newburg, N. Y.
*Dr. J. L. ADAMS,	24 East 46th Street,	New York, N. Y.
Dr. L. A. W. ALLEMAN,	64 Montague Street,	Brooklyn, N. Y.
Dr. A. N. ALLING,	199 York Street,	New Haven, Conn.
Dr. G. W. ALLYN,	515 Penn Avenue,	Pittsburg, Pa.
Dr. A. ALT,	3036 Locust Street,	St. Louis, Mo.
†Dr. J. A. ANDREWS,	107 Madison Avenue,	New York, N. Y.
Dr. S. C. AYRES,	14 East 7th Street,	Cincinnati, Ohio.
Dr. WM. T. BACON,	75 Pratt Street,	Hartford, Conn.
Dr. H. W. BRADFORD,		Jamaica Plain, Mass.
*Dr. H. D. BRUNS,	Gas Co. Building,	New Orleans, La.
Dr. CHARLES S. BULL,	47 West 36th Street,	New York, N. Y.
Dr. F. BULLER,	123 Stanley Street,	Montreal, Canada.
Dr. SWAN M. BURNETT,	916 Farragut Sq. (17th St.),	Washington, D. C.
Dr. PETER A. CALLAN,	35 West 38th Street,	New York, N. Y.
Dr. F. P. CAPRON,	118 Angell Street,	Providence, R. I.
Dr. W. H. CARMALT,	87 Elm Street,	New Haven, Conn.
*Dr. JOHN T. CARPENTER, JR.,	1419 Walnut Street,	Philadelphia, Pa.
Dr. H. B. CHANDLER,	34½ Beacon Street,	Boston, Mass.
Dr. WM. CHEATHAM,	303 West Chestnut Street,	Louisville, Ky.
Dr. F. E. CHENEY,	120 Marlborough Street,	Boston, Mass.
Dr. J. H. CLAIBORNE,	39 West 36th Street,	New York City.
Dr. C. F. CLARK,	188 East State Street,	Columbus, Ohio.
*Dr. ANTON COE,	1110 F Street,	Washington, D. C.
Dr. DAVID COGGIN,	7 Chestnut Street,	Salem, Mass.
*Dr. WM. E. COWEN,	35 E. 60th Street,	New York, N. Y.
Dr. C. M. CULVER,	36 Eagle Street,	Albany, N. Y.
*Dr. C. W. CUTLER,	36 East 33d Street,	New York, N. Y.
Dr. W. S. DENNETT,	8 East 49th Street,	New York, N. Y.
Dr. HASKET DERBY,	182 Marlboro Street,	Boston, Mass.
Dr. RICHARD H. DERBY,	9 West 35th Street,	New York, N. Y.
Dr. LEWIS S. DIXON,	232 Clarendon Street,	Boston, Mass.

† Temporarily residing at Santa Barbara, Cal.

NAME.	RESIDENCE.	PLACE.
*Dr. ALEXANDER DUANE,	49 East 30th Street,	New York, N. Y.
Dr. J. B. EMERSON,	20 East 30th Street,	New York, N. Y.
Dr. ARTHUR E. EWING,	2670 Washington Avenue,	St. Louis, Mo.
Dr. T. H. FENTON,	1319 Spruce Street,	Philadelphia, Pa.
Dr. GEORGE F. FISKE,	100 State Street,	Chicago, Ill.
Dr. EDW. FRIDENBERG,	242 Lenox Avenue,	New York, N. Y.
*Dr. PERCY FRIDENBERG,	114 West 126th Street,	New York, N. Y.
Dr. H. FRIEDENWALD,	1029 Madison Ave.,	Baltimore, Md.
Dr. B. F. FRYER,	Cor. 9th and Cherry Streets,	Kansas City, Mo.
*Dr. G. M. GOULD,	119 South 17th Street,	Philadelphia, Pa.
*Dr. H. Y. GRANT,	414 Delaware Avenue,	Buffalo, N. Y.
Dr. JOHN GREEN,	2670 Washington Avenue,	St. Louis, Mo.
Dr. EMIL GRUENING,	36 East 57th Street,	New York, N. Y.
Dr. G. W. HALE,	Wilcox Building,	Nashville, Tenn.
Dr. WM. D. HALL,	10 Arlington Street,	Boston, Mass.
Dr. H. F. HANSELL,	254 South 16th Street,	Philadelphia, Pa.
Dr. GEORGE C. HARLAN,	1515 Walnut Street,	Philadelphia, Pa.
*Dr. HERBERT HARLAN,	516 Cathedral Street,	Baltimore, Md.
Dr. DAVID HARROWER,	9 Elm Street,	Worcester, Mass.
Dr. N. D. HARVEY,	262 Benefit Street,	Providence, R. I.
Dr. GUSTAVUS HAY,	383 Marlborough Street,	Boston, Mass.
Dr. NEIL J. HEPBURN,	317 West 23d Street,	New York, N. Y.
*Dr. WARD HOLDEN,	43 West 48th Street,	New York, N. Y.
Dr. E. E. HOLT,	723 Congress Street,	Portland, Me.
Dr. LUCIEN HOWE,	87 West Huron Street,	Buffalo, N. Y.
Dr. A. A. HUBBELL,	212 Franklin Street,	Buffalo, N. Y.
Dr. D. W. HUNTER,	80 West 40th Street,	New York, N. Y.
Dr. J. W. INGALLS,	874 Lafayette Avenue,	Brooklyn, N. Y.
Dr. E. E. JACK,	215 Beacon Street,	Boston, Mass.
Dr. EDWARD JACKSON,	McPhee Building,	Denver, Col.
Dr. B. JOY JEFFRIES,	15 Chestnut St., Beacon Hill,	Boston, Mass.
Dr. W. B. JOHNSON,	170 Broadway,	Paterson, N. J.
*Dr. H. W. KILBURN,	192 Marlborough Street,	Boston, Mass.
Dr. CHARLES J. KIPP,	560 Broad Street,	Newark, N. J.
Dr. H. KNAPP,	26 West 40th Street,	New York, N. Y.
Dr. CARL KOLLER,	715 Madison Avenue,	New York, N. Y.
Dr. CHAS. W. KOLLOCK,	Cor. Wentworth & Com'g Sts.,	Charleston, S. C.
Dr. W. E. LAMBERT,	8 West 35th Street,	New York, N. Y.
*Dr. W. B. LANCASTER,	101 Newbury Street,	Boston, Mass.
*Dr. F. N. LEWIS,	35 W. 36th Street,	New York City.
Dr. J. A. LIPPINCOTT,	Arrott Bdg., Wood St. & 4th Av.,	Pittsburg, Pa.
Dr. F. B. LORING,	1420 K Street,	Washington, D. C.
Dr. D. B. LOVELL,	32 Pearl Street,	Worcester, Mass.
Dr. F. W. MARLOW,	731 University Block,	Syracuse, N. Y.
Dr. W. V. MARMION,	1110 8th Street, N. W.,	Washington, D. C.
Dr. W. B. MARPLE,	35 W. 53d Street,	New York, N. Y.
Dr. ARTHUR MATHEWSON,	139 Montague Street,	Brooklyn, N. Y.
Dr. CHAS. H. MCILWAINE,	264 Willis Avenue,	New York, N. Y.

NAME.	RESIDENCE.	PLACE.
Dr. R. J. McKAY,	Cor. 9th and Market Streets,	Wilmington, Del.
Dr. C. S. MERRILL,	23 Washington Avenue,	Albany, N. Y.
Dr. B. L. MILLIKIN,	278 Prospect Street,	Cleveland, Ohio.
Dr. HORACE GEO. MILLER,	262 Benefit Street,	Providence, R. I.
Dr. J. LANCELOT MINOR,	14 Randolph Building,	Memphis, Tenn.
Dr. W. F. MITTENDORF,	140 Madison Avenue,	New York, N. Y.
Dr. RUSSELL MURDOCH,	418 Cathedral Street,	Baltimore, Md.
Dr. CHARLES A. OLIVER,	1507 Locust Street,	Philadelphia, Pa.
Dr. H. S. OPPENHEIMER,	16 E. 32d Street,	New York, N. Y.
Dr. R. J. PHILLIPS,	123 So. 39th Street,	Philadelphia, Pa.
Dr. THOMAS R. POOLEY,	107 Madison Avenue,	New York, N. Y.
Dr. WILLIAM C. POSEY,	1831 Chestnut Street,	Philadelphia, Pa.
Dr. M. H. POST,	Beaum't St., cor. Wash. Av.,	St. Louis, Mo.
*Dr. L. A. PREFONTAINE,	1317 Main Street,	Springfield, Mass.
Dr. H. R. PRICE,	163 Hancock Street,	Brooklyn, N. Y.
Dr. J. S. PROUT,	29 Schermerhorn Street,	Brooklyn, N. Y.
*Dr. WALTER L. PYLE,	1806 Chestnut Street,	Philadelphia, Pa.
*Dr. ALEX. QUACKENBOSS,	71 Newbury Street,	Boston, Mass.
Dr. ALEX'R RANDALL,	1717 Locust Street,	Philadelphia, Pa.
Dr. R. L. RANDOLPH,	816 Park Avenue,	Baltimore, Md.
Dr. WILLIAM RANKIN,	23 Cedar Street,	Newark, N. J.
Dr. J. M. RAY,	423 West Chestnut Street,	Louisville, Ky.
*Dr. R. G. REESE,	56 East 25th Street,	New York, N. Y.
Dr. R. A. REEVE,	22 Shuter Street,	Toronto, Canada.
Dr. O. H. REIK,	5 W. Preston Street,	Baltimore, Md.
Dr. STEPHEN O. RICHEY,	732 17th Street,	Washington, D. C
Dr. CHARLES E. RIDER,	53 South Fitzhugh Street,	Rochester, N. Y.
Dr. WHEELOCK RIDER,	53 South Fitzhugh Street,	Rochester, N. Y.
*Dr. G. O. RING,	1900 Chestnut Street,	Philadelphia, Pa.
Dr. H. W. RING,	46 Elm Street,	New Haven, Conn.
Dr. SAMUEL D. RISLEY,	1824 Chestnut Street,	Philadelphia, Pa.
Dr. EDMUND C. RIVERS,	1632 Welton Street,	Denver City, Col.
*Dr. WM. K. ROGERS,	188 East State Street,	Columbus Ohio.
Dr. D. B. ST. JOHN ROOSA,	20 East 30th Street,	New York, N. Y.
*Dr. DUNBAR ROY,	Grand Opera House Block,	Atlanta, Ga.
Dr. JOHN D. RUSHMORE,	129 Montague Street,	Brooklyn, N. Y.
Dr. ROBERT SATTLER,	7th and Race Streets,	Cincinnati, Ohio.
Dr. T. B. SCHNEIDEMAN,	112 South 18th Street	Philadelphia, Pa.
Dr. G. E. DE SCHWEINITZ,	1401 Locust Street,	Philadelphia, Pa.
Dr. P. N. K. SCHWENK,	810 North 7th Street,	Philadelphia, Pa.
Dr. W. W. SEELEY,	4th Street and Broadway,	Cincinnati, Ohio.
Dr. HENRY L. SHAW,	19 Commonwealth Avenue,	Boston, Mass.
*Dr. WM. T. SHOEMAKER,	2031 Chestnut Street,	Philadelphia. Pa.
*Dr. WM. A. SHOEMAKER,	1006 Carlton Building,	St. Louis, Mo.
*Dr. F. D. SKEEL,	58 E. 25th Street,	New York, N. Y.
Dr. J. A. SPALDING,	627 Congress Street,	Portland, Me.
Dr. MYLES STANDISH,	6 St. James Avenue,	Boston, Mass.
*Dr. E. W. STEVENS,	421 McPhee Building,	Denver, Col.

NAME.	RESIDENCE.	PLACE.
Dr. GEORGE T. STEVENS,	22 East 46th Street,	New York, N. Y.
Dr. SAMUEL B. ST. JOHN,	68 Pratt Street,	Hartford, Conn.
Dr. GEO. STRAWBRIDGE,	202 So. 15th Street,	Philadelphia, Pa.
Dr. T. Y. SUTPHEN,	999 Broad Street,	Newark, N. J.
*Dr. WM. M. SWEET,	1205 Spruce Street,	Philadelphia, Pa.
Dr. J. OSCROFT TANSLEY,	28 West 43d Street,	New York, N. Y.
Dr. LEWIS H. TAYLOR,	41 South Franklin Street,	Wilkes-Barre, Pa.
Dr. SAMUEL THEOBALD,	304 West Monument Street,	Baltimore, Md.
Dr. CH. HERMON THOMAS,	1907 Chestnut Street,	Philadelphia, Pa.
Dr. A. G. THOMSON,	1426 Walnut Street,	Philadelphia, Pa.
Dr. WILLIAM THOMSON,	1426 Walnut Street,	Philadelphia, Pa.
*Dr. JAS. THORINGTON,	120 South 18th Street,	Philadelphia, Pa.
Dr. JOHN VAN DUYN,	111 South Salina Street,	Syracuse, N. Y.
Dr. C. A. VEASEY,	116 South 19th Street,	Philadelphia, Pa.
Dr. O. F. WADSWORTH,	526 Beacon Street,	Boston, Mass.
Dr. LEROY P. WALKER,	26 West 91st Street,	New York, N. Y.
Dr. DAVID WEBSTER,	327 Madison Avenue,	New York, N. Y.
Dr. J. E. WEEKS,	48 East 57th Street,	New York, N. Y.
*Dr. CASSIUS D. WESTCOTT,	31 Washington Street,	Chicago, Ill.
Dr. J. A. WHITE,	200 E. Franklin Street,	Richmond, Va.
Dr. W. H. WILDER,	103 State Street,	Chicago, Ill.
Dr. CHAS. H. WILLIAMS,	1069 Boylston Street,	Boston, Mass.
Dr. WM. H. WILMER,	1610 I Street N. W.,	Washington, D. C.
Dr. F. M. WILSON,	834 Myrtle Avenue,	Bridgeport, Conn.
*Dr. WILLIAM L. WOOD,	412 Oregonian Building,	Portland, Oregon.
*Dr. HIRAM WOODS,	842 Park Ave.,	Baltimore, Md.
Dr. J. P. WORRELL,	20 South 7th Street,	Terre Haute, Ind.
Total, ...		155

HONORARY MEMBERS.

Dr. C. SCHWEIGGER, ...		Berlin, Prussia.
Dr. F. P. SPRAGUE,	229 Commonwealth Avenue,	Boston, Mass.
Whole number, ...		157

Henry D. Noyes

DR. HENRY D. NOYES.

BY DR. C. S. BULL OF NEW YORK.

The death of Dr. Henry D. Noyes of New York has removed from the roll of membership of the American Ophthalmological Society one of its founders and most conspicuous members.

Henry Dewey Noyes was born in New York city in 1832. He was educated in the schools of his native city and at the New York University, from which he received the degree of A.B. in 1851, and A.M. in 1854. He began the study of medicine at the College of Physicians and Surgeons, from which he graduated, receiving the degree of M.D. in 1855. He then served three years on the resident staff of the New York Hospital, and subsequently passed a year abroad in England, France, and Germany. He returned in 1859 and settled in practice in New York city, making a specialty of diseases of the eye and ear. He became connected with the New York Eye and Ear Infirmary in 1859, serving as assistant ophthalmic surgeon from 1859 to 1864, and as ophthalmic surgeon from 1864 till 1900. He was appointed executive surgeon of the Infirmary in 1875, and served continuously until his resignation in 1898. He was made consulting surgeon in 1900. He was professor of ophthalmology and otology in the Bellevue Hospital Medical College from 1868 till 1892, and professor of ophthalmology from 1868 till his death in 1900. He was one of the founders of the American Ophthalmological Society in 1864 and its first secretary. He served as secretary until 1874, and as president of the Society from 1878 till 1884. He died at Mt. Washington, Berkshire Co., Mass., on Nov. 12, 1900, in the 69th year of his age. Dr. Noyes was the type of a progressive specialist who never lost his interest in nor his knowledge of general medicine. He was a man of rare talent and with a broad general education, especially

in matters pertaining to his own language. His broadly conservative mind made him a sound counsellor, and his rare qualities of skill, sound judgment, and insight, and perfect honesty and truthfulness made him a man to be trusted in the fullest sense of the word. Dr. Noyes was a frequent contributor to our transactions and to ophthalmic literature, and his contributions were always of the best. He had a style of his own, which was both finished and terse, and his knowledge and use of the English language was exceptionally good. He was a graceful and forcible speaker, and a brilliant clinical teacher. He was a very keen observer, an excellent operator, and was rarely at a loss in operative procedure. His text-book on Diseases of the Eye is one of the best in the English language, and is a testimony to the author's extensive personal experience and profound knowledge of the literature of his subject.

Dr. Noyes had many interests in life in addition to his fondness for his own profession, and to all of them he gave of the best that was in him. But he was especially active in and devoted to all measures looking to the advancement of medical science and the welfare of the profession.

No memorial of Dr. Noyes, however full, would be complete without reference to his devotion to and love for the New York Eye and Ear Infirmary. During his forty-one years of active connection with the Institution, as assistant surgeon, surgeon, executive surgeon, and member of the board of directors, he gave to its management his best thought, knowledge, and experience, and no labor was ever too great, no time too valuable, to devote to its interests. If the success of any charitable institution is ever due to the labors of one man, the New York Eye and Ear Infirmary today owes its success to the love and devotion of Dr. Noyes.

LIST OF CONTRIBUTIONS TO OPHTHALMIC LITERATURE BY HENRY D. NOYES, M.D.

1860. Sclerotico-choroiditis posterior.
N. Y. Journal of Medicine, VIII.

1865. Specialties in medicine.
Monograph.
Remarks on asthenopia.
Trans. Amer. Ophth. Soc.

1866. Amblyopia caused by osmic acid.
Trans. Amer. Ophth. Soc.
Cases of sub-retinal effusion. Puncture.
Trans. Amer. Ophth. Soc.

1868. Observations in astigmatism.
Trans. Amer. Ophth. Soc.
Retinitis in glycosuria.
Trans. Amer. Ophth. Soc.
Remarks on the modified linear extraction of cataract.
Trans. Amer. Ophth. Soc.

1869. A modification of the ophthalmoscope.
Trans. Amer. Ophth. Soc.
An improved eye speculum.
Trans. Amer. Ophth. Soc.
A new form of cataract knife.
Trans. Amer. Ophth. Soc.

1870. Cases of foreign bodies in the vitreous humor.
Trans. Amer. Ophth. Soc.
Ectropium — exophthalmus — extirpation — plastic operation.
Trans. Amer. Ophth. Soc.

1871. A scheme to aid in recording and examining cases of asthenopia.
Trans. Amer. Ophth. Soc.
An apparatus for testing the perception of color.
Trans. Amer. Ophth. Soc.
Detachment of the retina with laceration at the macula.
Trans. Amer. Ophth. Soc.
Paralysis of the fifth cerebral nerve, and its effects.
Trans. Amer. Ophth. Soc.
Two cases of detachment of the vitreous humor.
N. Y. Medical Record, May 15th.
Report on Ophthalmology for 1870.
N. Y. Medical Journal, XIII.

1872. Report on Ophthalmology for 1871.
N. Y. Medical Journal, XIV.

Ophthalmoscopic examination of sixty insane patients in the State Asylum at Utica.
Amer. Journal of Insanity, XXVIII.

Note respecting the first recorded case of astigmatism in this country for which cylindrical glasses were made.
Amer. Jour. Med. Sciences. 63.

The relation of diseases of the eye to other diseases.
N. Y. Med. Record, August 15th.

1873. Cancerous ulceration of the surface of the globe.
Trans. Amer. Ophth. Soc.

Sclerotitis depending on gouty or rheumatic diathesis.
Trans. Amer. Ophth. Soc.

Left Herpes Zoster Ophthalmicus, causing loss of corresponding eye and subsequent loss of fellow eye.
Trans. Amer. Ophth. Soc.

The Camera Lucida applied to the ophthalmoscope.
Trans. Amer. Ophth. Soc.

Supposed disseminated sclerosis of brain and spinal cord.
Arch. of Scientific and Practical Medicine, January.

The relative frequency of certain ophthalmic affections.
Fourth International Congress of Ophthalmology, London.

1874. A case of irritation of the Chorda Tympani nerve.
Trans. Amer. Otol. Soc.

Syphilis of the Eye. Being a Chapter in Van Buren and Hayes' Treatise on the surgical diseases of the genito-urinary organs and syphilis.

Astigmatism produced by tenotomy of recti muscles.
Trans. Amer. Ophth. Soc.

A case of extreme myopia.
Trans. Amer. Ophth. Soc.

Two new Instruments.
Trans. Amer. Ophth. Soc.

1875. Improvements in spectacle frames.
Trans. Amer. Ophth. Soc.

Cases of disease in the orbit.
Richmond and Louisville Med. Jour., June.

Remarks on subretinal effusion.
Trans. Amer. Ophth. Soc.

1876. On the use of a Naso-buccal flap for Blepharoplasty.
Fifth International Congress of Ophthalmology. Transactions.

Additional means for relieving pressure of the eyelids in diseases of the cornea.
Fifth International Congress of Ophthalmology. Transactions.

The optical error of conical cornea.
Fifth International Congress of Ophthalmology. Transactions.

Analysis of 1,079 recorded cases of Asthenopia and Muscular Weakness, with deductions respecting Asthenopia.
Fifth International Congress of Ophthalmology. Transactions.

Iridotomy by Wecker's forceps-scissors.
N. Y. Med. Record, January 15th.

Diagnosis of those diseases of the eye which can be seen without the ophthalmoscope.
N. Y., G. P. Putnam's Sons.

1877. Diseases of the general organism in relation to Vision.
Richmond and Louisville Med. Jour., p. 121.

Retinitis apoplectica and embolic inflammation of the retina.
Amer. Jour. Med. Sc., p. 357.

1878. Epithelial Cancer of the inner canthus. Plastic operation.
N. Y. Med. Jour., XXVIII.

Eye troubles in general practice.
N. Y. Med. Rec., April.

Ophthalmology in the last Quarter-century.
Trans. Med. Soc. of State of New York.

A Case of Melanotic Epithelioma of the front of the eye, extirpation with preservation of globe and sight.
Arch. of Ophthal., VIII, p. 145.

Case of Spontaneous Irido-Cyclitis, followed by sympathetic ophthalmia.
Detroit Lancet, II, p. 104.

1879. Statistics of extractions of cataract by the flap operation and by Von Graefe's method.
Trans. Amer. Ophth. Soc.

Plastic operations of the inner canthus.
Trans. Amer. Ophth. Soc.

Paresis of inferior oblique muscle.
Trans. Amer. Ophth. Soc.

1880. Case of Double Glioma retinae — death — autopsy.
Trans. Amer. Ophth. Soc., Med. Record, XVII.
Blepharoplasty by Wolfe's method.
N. Y. Med. Jour., XXXI.
Formation of an eyelid by transplantation of skin without pedicle.
N. Y. Med. Record, XVII.
Cases of Lacerations of the eyelids.
Trans. Amer. Ophth. Soc.
A Modification of Loring's Ophthalmoscope.
Trans. Amer. Ophth. Soc.
Case of Buphthalmos cured by total removal of the iris.
Trans. Amer. Ophth. Soc.

1881. A Treatise on Diseases of the Eye.
N. Y., Wm. Wood & Co.
Acute Myelitis with double optic neuritis.
Arch. f. Augenheilk., X, 3.
Cure of Cataract by electricity.
Trans. Amer. Ophth. Soc.
Pulsating Exophthalmos.
Trans. Amer. Ophth. Soc.
Modification of Snellen's Forceps for eutropion operations.
Trans. Amer. Ophth. Soc.

1882. Removal of foreign bodies from the cornea.
Trans. Amer. Ophth. Soc.
Three cases of tumor of the eye.
Trans. Amer. Ophth. Soc.
Optico-Ciliary Neurotomy or Neurectomy.
Trans. N. Y. State Med. Soc.
A Case of lodgment of a foreign body in the cavities of nose, orbit, and cranium. Removal by operation — abscess of brain — death — autopsy.
Amer. Jour. Med. Sc.

1883. On Eye troubles which may be erroneously attributed to lesions of the brain and nervous system.
N. Y. Med. Jour., XXXVII.
Transplantation of the conjunctiva of the rabbit to human eye.
N. Y. Med. Record.
Föerster's operation for ripening immature cataracts.
N. Y. Med. Rec., XXIV.

1884. On the tests for muscular asthenopia, and on insufficiency of the external recti muscles.
Trans. Internat. Med. Congress. Copenhagen.
Muriate of Cocaine as a local anaesthetic.
N. Y. Med. Rec., XXVI.

1886. Antiseptics in Eye surgery.
N. Y. Med. Jour., XLIII.
Extraction of hard Cataract — death on fifth day — autopsy.
Trans. Amer. Ophth. Soc.

1887. Gliosarcoma of Retina — enucleation — no recurrence after fourteen years.
Trans. Amer. Ophth. Soc.
Pseudo-Glioma from traumatism — enucleation.
Trans. Amer. Ophth. Soc.
Spontaneous prolapse of the lachrymal gland.
Trans. Amer. Ophth. Soc.
An operation for entropion of lower lid.
Trans. Amer. Ophth. Soc.

1888. Memorial of Cornelius R. Agnew, M.D.
Trans. Amer. Ophth. Soc.

1889. Enucleation during suppurative Panophthalmitis.
Trans. Amer. Ophth. Soc.
Considerations on extraction of hard cataract, with an analysis of 309 cases.
Trans. N. Y. State Med. Soc. & N. Y. Med. Rec., XXXV.

1890. The Therapeutic effect of Prisms in ophthalmic practice.
Trans. Amer. Ophth. Soc.
Tumor of Medulla and left Anophthalmos.
Boston Med. & Surg. Jour., CXXII.
N. Y. Med. Rec., XXXVIII.
A new Text-Book on diseases of the eye.
N. Y., Wm. Wood & Co.

1891. Hemianopsia.
N. Y. Med. Rec., XXXIX, p. 389.

1894. Text-book on diseases of the eye, Second edition.
N. Y., Wm. Wood & Co.
The formation of a central pupil by excision in cases of occlusion with Aphakia.
Trans. 7th Internat. Congress of Ophthal., Edinburgh.

1895. Severe hemorrhage following cataract extraction.
Trans. Amer. Ophth. Soc.
Traumatic keratitis caused by Forceps in delivery.
Trans. Amer. Ophth. Soc.

1896. Two cases of cancerous tumor of the chorioid.
Trans. Amer. Ophth. Soc.

1898. Discussion on Antiseptics in eye surgery.
Brit. Med. Jour., June 3d.
Remarks on cases of high myopia.
Trans. Amer. Ophth. Soc.
Removal of a calcareous cataract.
Trans. Amer. Ophth. Soc.

MINUTES OF THE PROCEEDINGS.

THIRTY-EIGHTH ANNUAL MEETING.

PEQUOT HOUSE,
NEW LONDON, July 16, 1902.

Meeting called to order at 10.15 by President O. F. WADSWORTH, who announced the following committees:

Committee on Bulletin — Drs. J. E. WEEKS and H. B. CHANDLER.

Committee on Membership — Drs. JNO. GREEN, G. C. HARLAN, W. H. CARMALT, E. GRUENING, S. THEOBALD.

Auditing Committee — Dr. H. G. MILLER.

Drs. Peck of Norwich, Jack of Boston, Haight of Texas, N. L. Wilson of Elizabeth, N. J., Eagleton of Newark, and Hayden of Galveston, Texas, were invited to sit as guests of the Society.

The Committee on Bulletin reported and the following papers were read:

1. Post-operative history of fifty cases of simple glaucoma, Dr. Bull.

2. Notes on some cases of simple chronic glaucoma treated by resection of the superior ganglion of the cervical sympathetic, with sections of ganglia, Dr. Weeks.

Discussed by Drs. Bull, Gruening, Theobald, Pooley, Chandler, Standish, H. W. Ring, and Weeks.

3. A case of endothelioma of the orbit, Dr. Veasey.

Discussed by Dr. Howe.

4. Melanosarcoma of choroid invading the orbit, with macroscopic and microscopic specimens, Dr. St. John. (Pathological report by Dr. A. J. Wolff.)

Discussed by Drs. Andrews, Mittendorf, Howe, Theobald, Ring, and St. John.

5. Report of case of congenital orbital cyst with microphthalmos, Dr. Harlan.

Discussed by Dr. Holt.

6. A case of metastatic carcinoma of one optic nerve with peculiar degenerations of both nerves — clinical and pathological report, Dr. Holden.

7. A case of double metastatic carcinoma, Dr. Jack. (Pathological report by Dr. Verhoeff.)

8. Histologic structure of the lenses of a hanged criminal, Dr. Oliver.

9. Study of the ocular changes produced by the injection of pure cultures of the bacillus typhosus into the vitreous chamber of rabbits and guinea pigs, Dr. Oliver.

10. The conjunctival flap and the cataract wound, Dr. Wilson.

Adjourned to 3 P. M.

Afternoon Session, 3 P. M.

11. Some recent experiences with subconjunctival injections in orbital disease, Dr. Bull.

12. On the insertions of the ocular muscles, Dr. Howe.

13. A simple use of the circle of diffusion in the correction of ametropia, Drs. Wm. and A. G. Thomson.

14. The use of models in the teaching of ophthalmology, especially as to refraction and convergence, Dr. Randall.

Discussed by Dr. Howe.

15. Two unusual complications following cataract extraction, Dr. Pooley.

Discussed by Drs. Knapp, Risley, Harlan, Wadsworth, Post, and Pooley.

16. On the confusion in methods of numbering and using prisms, Dr. Howe.

17. Additional notes of a case of high astigmatism, Dr. Millikin.

18. Demonstration by Dr. Kipp of an instrument for testing pupillary reaction.

19. Two cases of detachment of retina, traumatic in origin, treated by drainage-incision, Dr. W. K. Rogers.

20. A methyl-alcohol debauch and its results, Dr. H. W. Ring.

Discussed by Drs. Holden, H. Woods, A. G. Thomson, Ray, Ingalls, and Howe.

21. A case of color blindness in a railroad man due to tobacco-amblyopia, Dr. A. G. Thomson.

Discussed by Drs. Williams, Rogers, and Oliver.

22. A case of cavernous sinus thrombosis, Dr. Jack.

Discussed by Dr. Randall.

23. Treatment of epitheliam of the eyelids by X-Ray, Dr. Sweet.

Discussed by Drs. Theobald, Oliver, St. John, Callan, Wadsworth, and Ray.

Adjourned to meet in executive session at 8 P. M.

Executive Session at 8.30 P. M.

The chairman of the Membership Committee reported favorably on the following names, and they were all duly elected associates:

Dr. William T. Shoemaker, Philadelphia, Pa.; Dr. Wm. A. Shoemaker, St. Louis, Mo.; Dr. C. W. Cutler, New York city; Dr. W. B. Lancaster, Boston, Mass.; Dr. J. L. Adams, New York city; Dr. Percy Friedenberg, New York city; Dr. Alexander Duane, New York city; Dr. F. Hotz, Chicago, Ill.; Dr. W. L. Pyle, Philadelphia, Pa.

Treasurer's report was read, accepted, and ordered on file.

The Society voted to favor the plan of having a "general smoker" as the social event of the next meeting of the Congress of American Physicians and Surgeons, at Washington next year.

Voted, to accept proposition of Committee of International Medical Society to be represented at Madrid in 1903 by our President, and to appropriate $25 for expenses of the committee.

Dr. Howe made the following motion:

WHEREAS, A uniform method or methods of making tests of muscular anomalies would enable ophthalmologists to understand each other better, would tend to give more uniform results of examination and probably better results of treatment, therefore

Resolved, That this Society appoint a committee who shall endeavor to have attention called to the subject in National Societies of Ophthalmology, and in the Section of Ophthalmology of the International Medical Congress in Madrid next April, in order that, if deemed advisable, a plan for such uniformity of method may be formulated and acted upon by the International Ophthalmological Congress in Switzerland in 1904.

Motion adopted, and a committee consisting of Dr. L. Howe, Dr. S. D. Risley, and Dr. C. H. Williams was appointed.

Voted, to lay an assessment of $5.00 for the ensuing year.

The Executive Committee reported the following names for officers of the Society for the ensuing year, and they were duly elected:

President — Dr. C. S. BULL.

Vice-President — Dr. A. MATHEWSON.

Recording Secretary and Treasurer — Dr. S. B. ST. JOHN.

Corresponding Secretary — Dr. J. S. PROUT.

Committee on Publication — Dr. W. S. DENNETT, Dr. D. W. HUNTER, and the Secretary (*ex officio*).

For Member of the Committee of Arrangements of the Congress of American Physicians and Surgeons, 1903 — Dr. S. O. RICHEY.

Adjourned.

Thursday, 10 A. M.

Called to order.

24. The ideal result to be kept in view in the operative treatment of convergent strabismus in children, Dr. Theobald.

Discussed by Drs. Johnson, Callan, Gruening, Mittendorf, Risley, and Theobald.

25. Extraction of steel from the vitreous chamber, Dr. Risley.

Discussed by Drs. Knapp, Kipp, Callan, Millikin, Williams, Johnson, Holt, Wadsworth, and Risley.

26. The value of partial resection of the tarsal cartilage in the operative treatment of congenital ptosis, Dr. Gruening.

Discussed by Drs. Pooley, Harlan, Mittendorf, and St. John.

27. Circumscribed exudative choroiditis, Dr. Friedenwald.

Discussed by Drs. Kipp, Gruening, Risley, and Friedenwald.

28. On improvement of vision in amblyopia from nonuse, Dr. Friedenwald (title).

29. A point in the dioptics of astigmatic refraction illustrated by a new model, Dr. Knapp.

30. The desirability of a uniform notation of the meridians of the eye and the field of vision (with a proposition), Dr. Knapp.

Discussed by Drs. Harlan and Knapp.

31. Two cases of total uræmic amaurosis, with complete recovery, Dr. Mittendorf (by title).

32. Temporary ligation of the canaliculi as a means of preventing wound infection from the lachrymal sac, Dr. Buller.

Discussed by Drs. Hepburn, Mittendorf, St. John, Andrews, Gruening, Kipp, and Buller.

33. A case of permanent left hemianopsia, sequel of puerperal eclampsia, Dr. H. Woods (title).

34. The extension of more uniform method and standards for examining the vision and color perception and hearing of railroad employees, Dr. Williams.

36. An improved instrument for measuring the position of the eyes for distant and near vision, Dr. Williams.

Discussed by Drs. Rix, Buller, and Williams.

37. Tumor of optic nerve with intracranial complications, Dr. Buller (title).

38. A contribution to the knowledge of ossification occurring in the eye, with clinical report of cases occurring in the service at Lakeside Hospital, Dr. Millikin (title).

Dr. Risley appointed to read memorial of Dr. W. L. Norris at next meeting.

Adjourned.

S. B. ST. JOHN, *Secretary.*

Present at the Thirty-eighth Annual Meeting:

Dr. R. J. Phillips,
Dr. S. B. St. John,
Dr. C. A. Oliver,
Dr. J. D. Rushmore,
Dr. H. O. Reik,
Dr. Jno. Green,
Dr. Wm. M. Sweet,
Dr. J. O. Tansley,
Dr. C. A. Veasey,
Dr. C. J. Kipp,
Dr. P. N. K. Schwenk,
Dr. Wm. T. Bacon,
Dr. N. J. Hepburn,
Dr. W. D. Hall,
Dr. J. A. Andrews,
Dr. Jno. E. Weeks,
Dr. C. S. Merrill,
Dr. W. B. Johnson,
Dr. H. H. Harlan,
Dr. H. G. Miller,
Dr. Harry Friedenwald,
Dr. E. E. Holt,
Dr. C. S. Bull,
Dr. L. A. W. Alleman,
Dr. Wm. F. Mittendorf,
Dr. H. B. Chandler,
Dr. Myles Standish,
Dr. S. Theobald,
Dr. A. Quackenboss,
Dr. D. B. Lovell,
Dr. H. W. Ring,
Dr. F. M. Wilson,
Dr. E. Gruening,
Dr. O. F. Wadsworth,
Dr. P. A. Callan,
Dr. S. I. Richey,
Dr. F. N. Lewis,
Dr. A. N. Alling,
Dr. D. W. Hunter,
Dr. L. S. Dixon,
Dr. W. C. Posey,
Dr. Geo. C. Harlan,
Dr. H. Knapp,
Dr. J. S. Prout,
Dr. W. A. Holden,
Dr. J. M. Ray,
Dr. E. E. Jack,
Dr. H. Woods,
Dr. M. H. Post,
Dr. S. D. Risley,
Dr. B. A. Randall,
Dr. L. Howe,
Dr. Edw. Fridenberg,
Dr. D. Coggin,
Dr. A. G. Thomson,
Dr. L. A. Prefontaine,
Dr. T. R. Pooley,
Dr. B. L. Millikin,
Dr. J. W. Ingalls,
Dr. W. H. Carmalt,
Dr. E. C. Rivers,
Dr. W. K. Rogers,
Dr. W. S. Dennett.

THE POST-OPERATIVE HISTORY OF FIFTY CASES OF SIMPLE CHRONIC GLAUCOMA.

BY CHARLES STEDMAN BULL, A.M., M.D.,

NEW YORK CITY.

The fifty cases of glaucoma which form the subject of this paper were all cases of simple, non-inflammatory, chronic glaucoma, occurring in private practice. They all showed increased tension, narrowing of the field of vision, especially on the nasal side, and impairment of central vision. None of the cases, while under observation, ever showed any signs of irritation or inflammation. They were all under my personal observation for a varying length of time, and in all the cases the examinations of the field of vision, visual acuity, condition of tension, and of the fundus were made by myself.

The operative procedure in all cases was iridectomy, and was done on ninety-four eyes. The incision was made sometimes with a very broad lance knife, and sometimes with a narrow cataract knife, the aim being to make the incision at a distance of two millimeters back of the sclero-corneal margin, so as to include the root of the iris. In other words, a long incision was made and a broad piece of iris was removed. In no case was a second iridectomy done upon either eye of a patient.

Age of the patient. The age of the patients varied between 26 and 84 years.

In	the	decade	between	20	and	30	years,	there	were	2	cases.
"	"	"	"	30	"	40	"	"	"	4	"
"	"	"	"	40	"	50	"	"	"	6	"
"	"	"	"	50	"	60	"	"	"	5	"
"	"	"	"	60	"	70	"	"	"	17	"
"	"	"	"	70	"	80	"	"	"	14	"
"	"	"	"	80	"	90	"	"	"	2	"

Sex of the Patients. Of the fifty patients, 23 were men and 27 were women.

Race. Of the fifty patients, only two were Hebrews, the remainder being native Americans of English, Scotch, French, or Dutch ancestry.

Existing Refractive Condition. Of the fifty patients, 22 were hypermetropic, 12 had simple hypermetropic astigmatism, 7 had compound hypermetropic astigmatism, 4 were myopic, 3 had simple myopic astigmatism, 1 had compound myopic astigmatism, and 1 had mixed astigmatism.

Unilateral or Bilateral. In 44 cases the disease involved both eyes, either simultaneously or at a varying interval of time. In 6 cases but one eye was involved, the other remaining intact as long as the patient was under observation.

Operation. Iridectomy was done on one eye alone in 6 cases, on both eyes at a varying interval of time in 31 cases, and on both eyes simultaneously in 13 cases.

Field of Vision before Operation. The condition of the field of vision before operation was an interesting study, and varied materially in the different patients, and in the two eyes of the same patient.

There was concentric narrowing of the field, most marked on the nasal side, in 44 eyes.

There was concentric narrowing on the nasal side only in 21 eyes.

There was concentric narrowing of the field with central or paracentral scotomata in 14 eyes.

There was narrowing on the nasal side only in 21 eyes.

There was loss of the entire nasal half of the field in 10 eyes.

The field was reduced to a quadrant in 3 eyes.

The field was telescopic in 2 eyes.

The scotomata showed a varying shape, size, and even location at different times, and in some cases entirely disappeared before operation.

In the cases in which the operation was done on both eyes,

but with an interval between them, the *length* of time that *elapsed* between the two operations was as follows:

In	1	case,	24 hours.
"	1	"	5 days.
"	2	"	1 week.
"	2	"	2 weeks.
"	2	"	3 weeks.
"	4	"	1 month.
"	1	"	6 weeks.
"	2	"	2 months.
"	3	"	2 years.
"	2	"	6 months.
"	7	"	1 year.
"	1	"	26 months.
"	1	"	3½ years.
"	1	"	4 years.
"	1	"	6 years.

Length of Time under Observation. The cases were under observation a varying length of time, ranging from one to twenty years, as follows:

5	cases	were	under	observation	for	1	year.
10	"	"	"	"	"	2	years.
11	"	"	"	"	"	3	"
6	"	"	"	"	"	4	"
5	"	"	"	"	"	5	"
1	"	"	"	"	"	6	"
1	"	"	"	"	"	7	"
3	"	"	"	"	"	8	"
2	"	"	"	"	"	9	"
1	"	"	"	"	"	10	"
1	"	"	"	"	"	11	"
2	"	"	"	"	"	12	"
1	"	"	"	"	"	18	"
1	"	"	"	"	"	20	"

Effect of Iridectomy on Central Vision. Special care was observed in testing the central vision of these cases at various times after the operation, and the results were carefully tabulated, and the following is a brief résumé of these data:

There was a temporary improvement in central vision in 7 eyes; permanent improvement in central vision in 3 eyes; immediate failure in central vision in 2 eyes. (These were the eyes with telescopic fields.)

There was a gradual failure in central vision in 58 eyes; maintenance of the existing vision at the time of operation while under observation in 24 eyes, as follows:

In	1	eye	for	2	years.
"	7	"	"	3	"
"	3	"	"	4	"
"	1	"	"	5	"
"	1	"	"	7	"
"	7	"	"	8	"
"	2	"	"	12	"
"	2	"	"	18	"

Condition of the Intraocular Tension after Operation. There was immediate diminution of tension in 89 eyes; permanent diminution of tension in 18 eyes; no effect on the tension after operation in 5 eyes.

Condition of the Color Fields after Operation. There was no change in the color fields in 3 eyes. There was continuous narrowing of all the color fields in both eyes of 18 patients, and in one eye in 26 patients; there was loss of the entire color fields in both eyes of 10 patients and of one eye in 9 patients.

Condition of the Field for Form after Operation. There was loss of the entire nasal half of both fields in 4 cases, and of one field in 5 cases; there was loss of the entire field in both eyes in one case, and of one eye in 12 cases. The field was reduced to a quadrant in both eyes in one case, and in one eye in 6 cases. Continuous concentric narrowing of both fields in 8 cases, and one field in 9 cases. The field was unchanged in both eyes in

one case, and in one eye in 2 cases. The field was widened in one eye in 1 case.

In eleven eyes the final result was absolute glaucoma.

Brief Résumé. In *seven* cases, under observation for a period ranging from 15 months to 11 years, the fields remained as they were at the time of operation. In *six* of these *seven* cases the vision grew slowly worse, and in *one* case the vision was somewhat improved.

In *five* cases the vision remained as it was at the time of operation or improved, while the fields grew narrower.

Age, in itself, did not seem to exercise any definitely bad effect, for some of the most satisfactory results occurred in patients over seventy years of age.

The best results as to ultimate vision occurred in the cases in which the central vision was the best and the fields were the least encroached upon at the time of operating, or in other words as soon as the existence of the disease was definitely established.

A careful study of these cases has led me to the conclusion that where the disease undoubtedly exists in both eyes of a patient better results as to visual acuity and the field of vision are obtained by a simultaneous operation on the two eyes.

Finally, quoting from a recent statement of my own made before the New York Academy of Medicine: "The operative effect of iridectomy is more certain and undeniable the earlier it is done. The slightest narrowing of the field, whether for form or color, demands operation, once our diagnosis is made. The curative action of iridectomy stands in direct proportion to the increase of tension. Early iridectomy, while the iris is still mobile, the field but little contracted, and the cupping of the disc slight, very often arrests the disease, at least for a long period, and preserves what sight remains. *Done early* it offers the best prospects for the arrest of the process, and its effects are either permanent or very prolonged.

CASE I. F., aged 33. Prodromata for 8 years, with paracentral scotomata. Concentric limitation of field. V.=15/16—.

Iridectomy on both eyes, one month interval. Under observation 13 years. V. reduced to 15/200. Loss of entire nasal half of both fields. Hyp. astig.

CASE II. M., aged 80. Concentric limitation of both fields. V.=15/200+. Iridectomy simultaneously on both eyes. V. and F. uninfluenced by operation. Under observation two years. R. E. l. p. L. E. 2/200: field reduced to supero-temporal quadrant. Death. Hyp.

CASE III. F., aged 46. Gouty. Hyp. astig. Prodromata with paracentral scotomata for 4 years. Concentric narrowing of both fields. R. E. 15/70+. L. E. 15/20+. Iridectomy on both eyes, with interval of 4 years. Under observation for 20 years. Gradual failure to absolute glaucoma.

CASE IV. M., aged 27. Myopia. Iridectomy on R. E., with interval of 2 years. Fields concentrically narrowed. Paracentral scotoma. R. E. 15/30—. L. E. 15/200. Under observation 7 years. R. E. 15/40—. L. E. 12/200. Fields steadily narrowed.

CASE V. M., aged 60. Hyp. Prodroma for 2 years. R. E. 8/200. L. E. 15/20—. Iridectomy on both eyes at interval of one month. Under observation for 4 years. R. E. movements of hand. L. E. 15/100. Loss of entire nasal half of field.

CASE VI. M., aged 69. Myopia. Prodromata in one eye for 4 years, and in the other eye for one year. R. E. 15/70. L. E. 15/100. Fields very narrow on nasal side. Simultaneous iridectomy on both eyes. Under observation for 3 years. R. E. 15/100. L. E. 15/200. Progressive narrowing of fields. Death in 4th year.

CASE VII. M., aged 54. Hyp. Prodromata for 4 years in one eye, and for one year in the other. R. E. 15/70. L. E. 15/200. Iridectomy on both eyes, with interval of one week. Irregular concentric narrowing of fields. Under observation 3 years. Final result: R. E. 15/100—. L. E. absolute glaucoma.

CASE VIII. F., aged 79. Hyp. One year's duration R. E. 15/20—. Field limited on nasal side. L. E. 15/15 normal.

Iridectomy on R. E. Under observation 11 years. R. E. movements of hand. L. E. 15/50, field narrowed on nasal side. Death in 1896.

CASE IX. F., aged 48. Hyp. Duration of disease about 3 years. R. E. 15/70. L. E. 10/200. Fields narrowed concentrically. Iridectomy on both eyes simultaneously. Under observation 3 years. Final result: R. E. 4/200; L. E. l. p.

CASE X. M., aged 62. Prodromata with paracentral scotomata for a year. Myopic astigmatism. R. E. 15/20—; L. E. 15/30—. Simultaneous iridectomy in both eyes. Nasal halves of fields very narrow. Under observation for 18 years. Final result: V.=15/40+ in both eyes, with steadily contracting fields till his death in 1900.

CASE XI. M., aged 73. Hyp. Symptoms for four months. Irregular concentric narrowing of both fields. R. E. 15/100+. Simultaneous iridectomy in both eyes. Profuse hemorrhage. Under observation for 3 years. Final result in R. E. l. p.

CASE XII. F., aged 50. Co. hyp. astig. Irregular concentric narrowing of both fields. R. E. 15/20—; L. E. 15/30+. Simultaneous iridectomy in both eyes. Under observation for 8 years. Field and vision remained unchanged for 8 years. R. E. 15/30— till her death.

CASE XIII. F., aged 40. Co. hyp. astig. Field concentrically narrowed in both eyes. R. E. 15/20—; L. E. 15/40. Iridectomy on both eyes with interval of 5 years. Under observation for 8 years. Ultimate result: R. E. 15/30 —; L. E. 15/50, with steadily contracting fields.

CASE XIV. M., aged 65. Hyp. Symptoms for 2 years. R. E. 5/200, nasal and lower quadrants of field gone. L. E. 15/30—, field contracted on nasal side. Simultaneous iridectomy on both eyes. Under observation for 5 years. Ultimate result in R. E. absolute glaucoma, L. E. 20/40—, but field very narrow.

CASE XV. F., aged 50. Hyp. astig. Both fields contracted on nasal side, with paracentral scotomata. Simultaneous iri-

dectomy on both eyes. Under observation for 11 years. Before operation V. B. E. 15/15—. Final result 15/20— till her death.

CASE XVI. F., aged 48. Co. hyp. astig. Fields narrowed on nasal side. Iridectomy on both eyes, with interval of two weeks. Before operation V. B. E. 15/20—. Final result, 15/50. Under observation 4 years. Fields steadily grew more contracted.

CASE XVII. F., aged 64. Hyp. Duration of disease one year. R. E. 15/200; L. E. 15/20. Fields concentrically narrowed. Iridectomy on both eyes, with interval of one week. Under observation for 4 years. Final result: R. E. l. p.; L. E. 15/30—; with steadily contracting field to death.

CASE XVIII. F., aged 37. Myopic astig. Faint corneal macula in R. E. Both fields concentrically narrowed. R. E. 15/40; L. E. 15/20—. Iridectomy on both eyes, with interval of 3 weeks. Under observation for 5 years. Final result: R. E. 15/50; L. E. 15/40. Loss of entire nasal half of field in both eyes.

CASE XIX. M., aged 63. Hyp. astig. Both fields concentrically narrowed. R. E. 15/20—; L. E. 15/40. Simultaneous iridectomy in both eyes. Under observation 3 years. Final result: R. E. 15/30—; L. E. 15/50. Field in L. E. reduced to a quadrant.

CASE XX. M., aged 66. Hyp. R. E. absolute glaucoma. L. E. 20/40—. Field concentrically narrowed. Iridectomy on L. E. V. of L. E. and field remained the same (15/40) for 5 years, and was then suddenly lost by retinal hemorrhages.

CASE XXI. F., aged 54. Hyp. Both fields concentrically contracted. R. E. 15/30+; L. E. 15/20. Iridectomy on both eyes, with interval of one month. Under observation for 10 years. Final result: R. E. 15/50; L. E. 15/20; but with steadily contracting fields.

CASE XXII. M., aged 62. Myopia. Both fields concentrically narrowed. R. E. 15/20—; L. E. 15/20. Simultaneous

iridectomy in both eyes. Vision made immediately worse, but it recovered. Under observation for 8 years. Final result: R. E. 15/30; L. E. 15/40; with unchanged fields.

CASE XXIII. M., aged 32. Hyp. astig. Both fields irregularly narrowed downwards and inwards. R. E. 15/20—. Iridectomy in both eyes at intervals of 3 weeks. Under observation for 5 years. Final result: R. E. 15/30—; L. E. 15/20—; with contracting fields.

CASE XXIV. F., aged 65. Hyp. astig. Both fields concentrically narrowed. Iridectomy in both eyes, with interval of 3½ years. Under observation 12 years. Final result: R. E. 15/70+; L. E. 15/50; but with steadily contracting fields.

CASE XXV. M., aged 72. Hyp. Concentric narrowing of both fields. R. E. 15/15—; L. E. 15/200. Iridectomy in both eyes, with interval of five weeks. Under observation for 2½ years. Final result: R. E. 15/40; L. E. 5/200; but with very little change in fields. Death.

CASE XXVI. F., aged 65. Myopia. Concentric narrowing of both fields. R. E. 15/70+; L. E. 15/40+. Simultaneous iridectomy in both eyes. Under observation for 3 years. Final result: R. E. 15/200, field very narrow; L. E. 15/70—.

CASE XXVII. F., aged 60. Hyp. Both fields very narrow in all directions. R. E. 15/50—; L. E. 15/50+. Iridectomy on R. E., and owing to irritation of fellow eye iridectomy on L. E. the next day. Under observation for 2 years. Final result: R. E. 15/200, with steady narrowing of fields. Death from cerebral hemorrhage.

CASE XXVIII. F., aged 58. Hyp. Both fields contracted on nasal side and downward. R. E. 15/70; L. E. 10/200. Iridectomy on both sides, with interval of 2 weeks. Under observation for 4 years. Final result: R. E. 10/200; L. E. 3/200; with very narrow fields.

CASE XXIX. F., aged 61. Hyp. Both fields concentrically narrowed. R. E. 15/30; L. E. 15/100. Iridectomy in

both eyes, with interval of one month. Under observation for 3 years. Final result: R. E. 15/50+; L. E. 15/50—; with continuous contraction of fields.

CASE XXX. M., aged 37. Co. hyp. astig. Marked narrowing of both fields. R. E. 15/200+; L. E. 15/20—. Iridectomy on both eyes, with interval of one week. Under observation for 8 years. Final result: R. E. 10/200; L. E. 15/30—; but with steadily narrowing fields.

CASE XXXI. F., aged 51. Hyp. astig. Field of R. E. contracted on nasal side and downwards. R. E. 15/40+; L. E. 15/15+. Iridectomy on R. E. Under observation for 3½ years. Final result: R. E. 15/100+; L. E. 15/15+. Field of R. E. steadily narrowing.

CASE XXXII. F., aged 75. Myopia. L. E. glaucoma absolutum. R. E. 15/30—. Field contracted on nasal side. Iridectomy on R. E. Under observation for 9 months. At time of death R. E. 15/70—, with loss of entire nasal half of field.

CASE XXXIII. F., aged 42. Hyp. R. E. glaucoma absolutum. L. E. 15/30—. Typical concentric narrowing of field. Iridectomy in L. E. Under observation for 6 years. Final result: L. E. 15/70—, with slow but steady narrowing of field.

CASE XXXIV. F., aged 67. Hyp. Concentric narrowing of both fields. R. E. 15/100; L. E. 15/40. Temporal scotoma in both eyes. Iridectomy in both eyes, with interval of one week. Under observation for 3½ years. Final result: R. E. 15/200; L. E. 15/70+. Steady narrowing of fields.

CASE XXXV. F., aged 66. Hyp. astig. Both fields concentrically contracted, and central scotoma in R. E. Vision R. E. 15/70+; L. E. 15/20—. Iridectomy in both eyes, with interval of 6 months. Under observation for 2½ years. Final result: R. E. 15/100; L. E. 15/40+. Fields unchanged.

CASE XXXVI. M., aged 68. Co. hyp. astig. Fields contracted concentrically, especially in L. E. Iridectomy in both eyes, with interval of 6 years. Under observation 11 years. Be-

fore operation: R. E. 15/30; L. E. 5/200. Final result: R. E. 15/70; L. E. absolute glaucoma.

CASE XXXVII. F., aged 75. Hyp. Fields narrowed inwards and downwards. R. E. 10/200; L. E. 15/50. Iridectomy in both eyes, with interval of a week. Under observation 15 months. Final result: R. E. 15/200; L. E. 15/40. Fields unchanged.

CASE XXXVIII. M., aged 76. Hyp. R. E. glaucoma absolutum. L. E. 15/20—. Nasal side of field nearly gone. Iridectomy in L. E. Under observation for one year. Final result: L. E. 15/70+. Field reduced to a quadrant.

CASE XXXIX. F., aged 75. Hyp. Fields contracted inwards and downwards. R. E. 15/30—; L. E. 15/20—. Iridectomy in both eyes, with interval of one month. Under observation for 6 years. Final result: R. E. l. p.; L. E. 15/70 —; with very narrow field.

CASE XL. F., aged 63. Hyp. Typical contraction of field of L. E. Right eye normal. L. E. 15/70+. Iridectomy in L. E. Under observation 26 months. Final result: R. E. normal; L. E. 5/200 in infero-nasal quadrant.

CASE XLI. F., aged 70. Hyp. R. E. absolute glaucoma. L. E. 15/30—. Typical glaucomatous field, with marked narrowing on nasal side. Iridectomy in L. E. Under observation for 2 years. Final result: L. E. 15/30+, with very narrow field.

CASE XLII. M., aged 70. Hyp. Both fields concentrically narrowed. R. E. 15/40+; L. E. 15/100+. Iridectomy in both eyes, with interval of ten days. Under observation for 3 years. Final result: R. E. 15/50—; L. E. 15/100—; with slowly narrowing fields.

CASE XLIII. M., aged 45. Co. hyp. astig. Field concentrically narrowed in R. E., and reduced to quadrant in L. E. R. E. V.=15/30—; L. E. 10/200. Iridectomy in both eyes, with interval of 3 weeks. Under observation for 3 years. Final result: R. E. 15/40—; L. E. movements of hand.

CASE XLIV. F., aged 26. Co. myopic astig. Fields contracted inwards and downwards in both eyes. R. E. 15/30+; L. E. 15/20—. Iridectomy in both eyes, with interval of 2 weeks. Under observation for 5½ years. Final result: R. E. 15/30—; L. E. l. p.

CASE XLV. M., aged 70. Myopic astig. Both fields concentrically narrowed. R. E. 15/20—; L. E. 15/40—. Iridectomy in both eyes, with interval of 3 months. Under observation for 20 months. Final result: R. E. 15/40; L. E. 15/50—. Fields unchanged.

CASE XLVI. M., aged 84. Hyp. Both fields very narrow. R. E. 10/200; L. E. 15/100. Patient unusually healthy and rugged. Iridectomy simultaneously in both eyes. Under observation for 2½ years. Final result: R. E. fingers eccentrically; L. E. 5/100. Field very narrow.

CASE XLVII. M., aged 60. Hyp. L. E. absolute glaucoma. R. E. 15/30. Field concentrically narrowed. Iridectomy in R. E. Under observation 4½ years. Final result: R. E. fingers eccentrically in extreme temporal field.

CASE XLVIII. M., aged 71. Co. hyp. astig. Both fields concentrically narrowed. R. E. 15/40; L. E. 15/100. Iridectomy simultaneously in both eyes. Under observation for 9 years. Final result: R. E. 15/100; L. E. absolute glaucoma.

CASE XLIX. F., aged 75. Hyp. Both fields concentrically narrowed. R. E. 15/30+; L. E. 15/30+. Patient unusually young and well for her age. Iridectomy in both eyes, with interval of 3 years. Under observation for 4 years. Final result: R. E. 15/50; L. E. 15/70. Slowly narrowing fields.

CASE L. M., aged 76. Co. hyp. astig. Both fields narrowed concentrically, most in R. E. R. E. 4/200; L. E. 15/100. Iridectomy simultaneously in both eyes. Under observation for 3 years. Final result: R. E. absolute glaucoma; L. E. 5/200.

NOTES OF CASES OF SIMPLE CHRONIC GLAUCOMA TREATED BY RESECTION OF THE SUPERIOR GANGLION OF THE CERVICAL SYMPATHETIC; WITH A REPORT OF THE MICROSCOPICAL EXAMINATION OF THE EXCISED GANGLIA.

BY JOHN E. WEEKS, M.D.,

NEW YORK CITY.

The object of this communication is not to review the literature on resection of the upper portion of the cervical sympathetic for the relief of glaucoma, or to mention at any length the experience of others, but to report a number of cases that have occurred in the writer's practice, to mention the results of the examination of the ganglia removed, and to make a few comments on the findings. The ganglia were examined by Dr. Ira Van Gieson, former Director of the Pathological Institute of the New York State Hospitals, to whom I am indebted for the work, and to whom I wish to express my sincere thanks.

HISTORY OF MRS. M. V.

CASE I. Mrs. M. V., aet. 56 years, came to the New York Eye and Ear Infirmary March 8, 1902, and gave the following history: Two years ago she noticed dimness of vision of the right eye, which has increased gradually up to the present time. There has been but little pain in the eye, although the patient has experienced much dull pain in the head and neck. A halo about a light has been frequently observed when looking with the right eye, and occasionally when using the left eye. Status praesens — Right eye: Pupil slightly dilated, circular. Iris reacts slightly to stimulus of light. Anterior ciliary vessels dilated and tortuous. Anterior chamber very shallow; iris in contact with cornea to the nasal side at its periphery. Media clear. Disc shows glaucomatous cupping of 2/3 mm.; arteries at disc reduced in size, pulsation of infratemporal branch. Veins full. Tension + T2. Field of vision for white very small;

color field abolished. Vision, with correction, equals finger at one foot. Cornea slightly anaesthetic.

Left Eye: Indications of involvement only to a slight degree. Halo observed from time to time. Vision, with correction, 20/20—. + T1.

Diagnosis: Simple chronic glaucoma.

March 11th. Operation: Dr. John F. Erdemann and Dr. Weeks. Ether. Incision on right side along anterior border of sterno-mastoid, 4 inches long. Dissection down to deep vessels. Internal jugular carotid and pneumogastric drawn in towards median line. Sympathetic exposed and tissues around

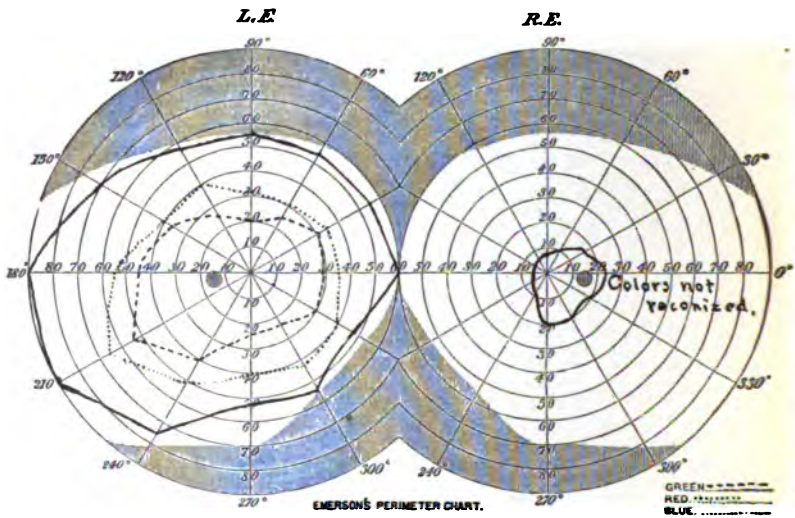

FIG. I. M. V. Field Charts, March 9, 1902.

it dissected away. Ganglion (superior) drawn down and excised. Buried sutures of No. 1 catgut, skin sutures of silk, sterile dressing.

March 12th. Right pupil slightly smaller than left. Iris reacts quite readily to stimulus of light. Vision, by candle light, fingers at two feet. Tension slightly below normal. Slight ptosis. Difficult to open eye wide enough to expose pupillary area.

March 14th. Vision by daylight fingers at 22 feet. Tension normal. Recognizes all colors.

March 17th. Vision by dull daylight=9/200. Tension slightly plus. Pupil small. Ptosis not as marked. Halo has disappeared from around light.

March 18th. Tension +. Vision=fingers at 20 feet.

March 23d. Discharged improved. Temperature but little above the normal at any time.

March 25th. V.=12/200 and fingers at 18 feet.

April 6th. O. D. Tension + 1. V.=fingers at 16 feet. Pilocarpine 1% solution instilled once every second day.

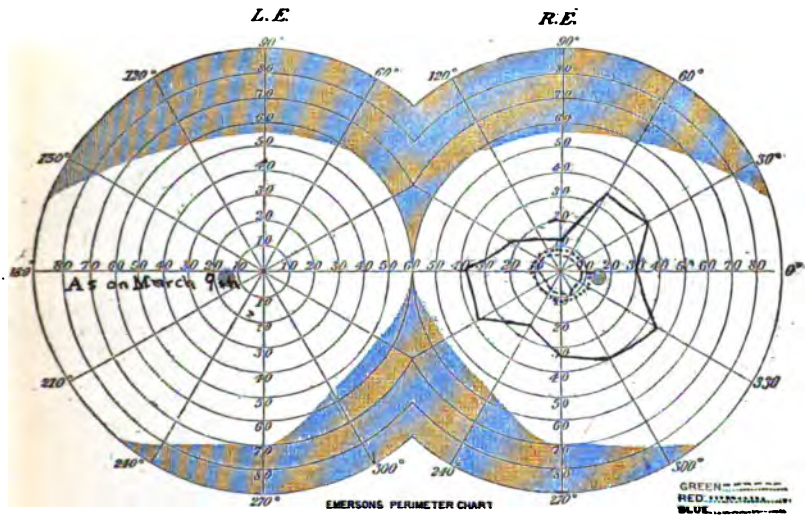

FIG. II. M. V. Field Charts, April 20, 1902.

April 20th. Right eye: Tension + T. Vision, with correction, equals 20/70. Patient complains of some fullness of the head, which does not appear to be associated with the eye. The field of vision is much increased for white, and color fields are now present.

The left eye appears to be slightly better in vision and in extent of field of vision.

June 8th. Attack of acute glaucoma in the right eye. Much pain in the head, particularly on the right side. Patient did not present herself until one week later.

June 16th. Right eye much congested. Anterior chamber very shallow; pupil much dilated. V.=perception of light. Left eye apparently unaffected. Immediate iridectomy advised.

June 20th. Iridectomy right eye under ether narcosis.

July 18th. V.=R. E.=fingers at seven feet.

HISTORY OF WALTER BRUMMER.

Walter Brummer, age 70 years, first came to the New York Eye and Ear Infirmary March 15, 1902. Diagnosis: Simple glaucoma, — subacute in the left eye, almost absolute in the right eye.

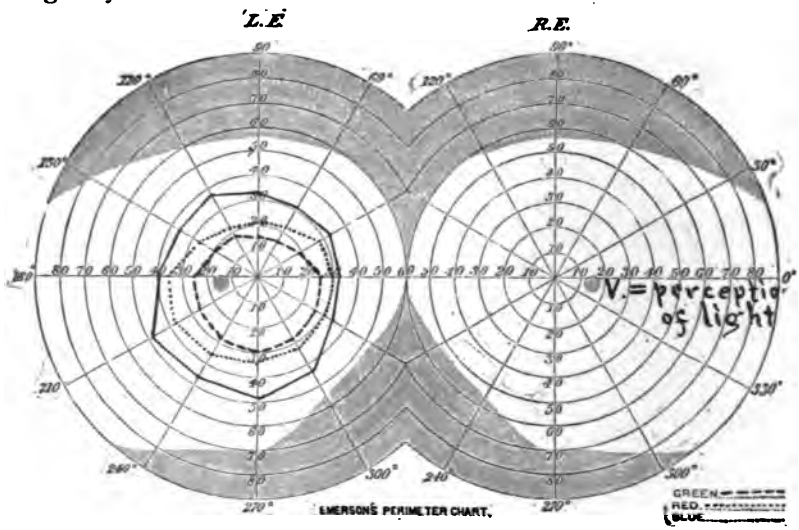

FIG. III. WALTER BRUMMER. Visual Fields, March 21, 1902.

April 1, 1902. Admitted. General health good. Specific history denied. Had no trouble with his eyes until last February. Had not consulted a physician until he came here. Right eye: V.=light perception; disc markedly cupped; nerve white; lens sclerosed; T + 2. Left eye: V.=20/40; field very much contracted; + T.

Operation: Ether. Incision 2½" long over anterior border of sterno-mastoid muscle on left side. Tissues dissected down to vessels of neck. Sheath drawn forward, exposing sympathetic, the upper ganglion of which was excised. Deep fascia

sutured with catgut. Wound closed externally with black silk sutures. Rubber tissue drain at lower angle of wound. Pupil of pin-point size immediately after the ganglion was excised.

April 2d. Pupil contracted and responds to light promptly. —T.

April 9th. Sutures removed. Healing by first intention.

April 15th. Operation by Dr. John F. Erdmann. Ether. Incision over right sterno-mastoid muscle 1 7/16" long. Dissection down to deeper structures. Sheath of vessels drawn forward, exposing sympathetic, and upper ganglion removed. Wound closed by deep catgut sutures and superficial silk sutures. No drainage. Pupil contracted.

April 16th. Pupil smaller and reacts slightly to light. +T 1.

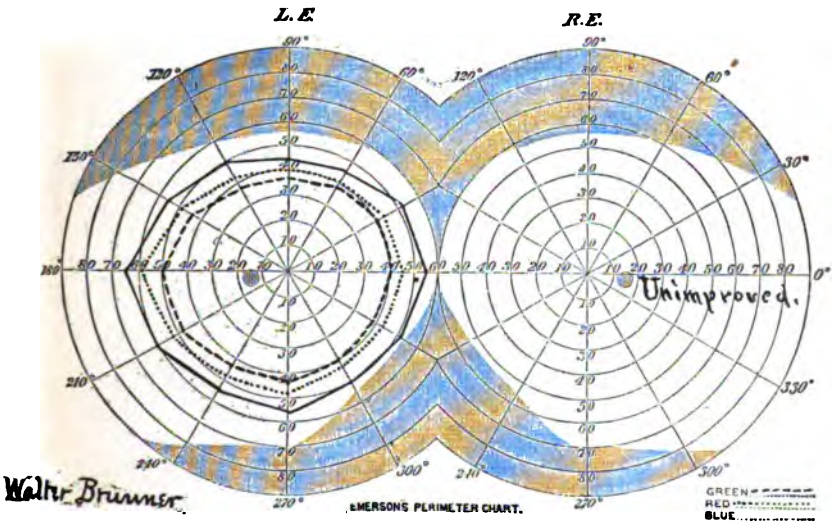

FIG. IV. WALTER BRUMMER. Visual Fields, June 5, 1902. V.= 20/20.

April 18th. Pupil smaller. +T 1. Healing progressed rapidly and satisfactorily. The temperature reached 100° F. on the afternoon of April 3d, after which it did not go above 99° F., averaging very nearly normal.

June 5th. The patient has complained of some fullness in the head since the operations, but on the whole has had little discomfort. Fields and V. good.

July 12th. Patient examined by House Surgeon. Reported to be in good condition.

HISTORY OF A. GOLDBERG.

A. Goldberg, age 63 years, was admitted to the New York Eye and Ear Infirmary April 15, 1902. Diagnosis: Simple chronic glaucoma, left eye; absolute glaucoma right eye. General health good. Patient states that his right eye began to trouble him twelve years ago, and that one year later he came to the clinic, and was told that he had waited too long. Vision=0. Iridectomy by Dr. Gruening three years ago. Vision of left

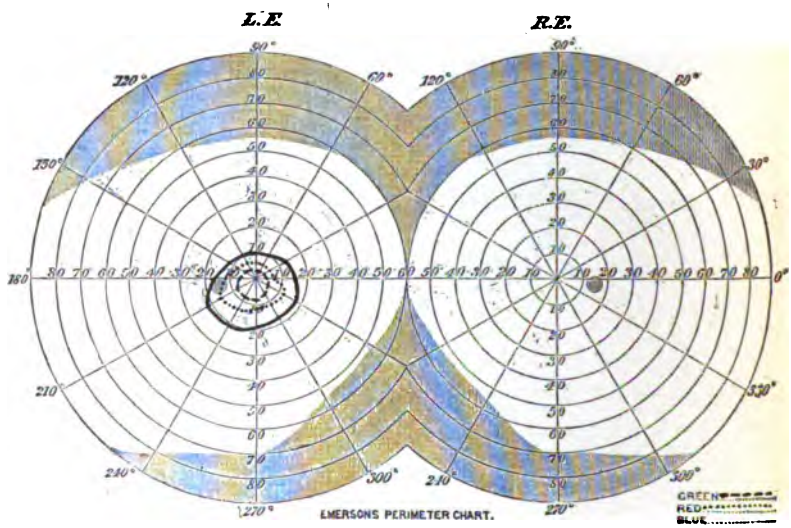

FIG. V. A. GOLDBERG. Field of Vision, April 10, 1902. R. E. V.= 20/70.

eye began to fail some years ago and to pain him. He was able to see very well after the operation, but everything looked smoky.

The patient has been under observation at the Infirmary for seven years at least. There has been a gradual contraction of the field of vision of the left eye. A solution of eserine and cocaine once or twice daily gave relief and maintained good central vision. The vision of the left eye today is 20/70; right eye nil.

April 15th. Operation. Ether. Removal of superior ganglion. Incision 1 11/16" long along anterior border of sternomastoid muscle. Wound closed with deep catgut and superficial silk sutures. No drainage. Immediately after the operation the pupil was much reduced in size. Slight suffusion of the eye. Lachrymation increased. Tension still slightly plus. The patient made an uneventful recovery, the temperature not going above 99° F.

April 17th. Tension normal. Pupil pin-point in size.

April 21st. Tension again plus. Pupil dilated slightly, but still smaller than normal.

April 25th. Tension normal. Vision=20/30+.

May 28th. Left eye T. Pupil pin-point in size. V.= 20/30+.

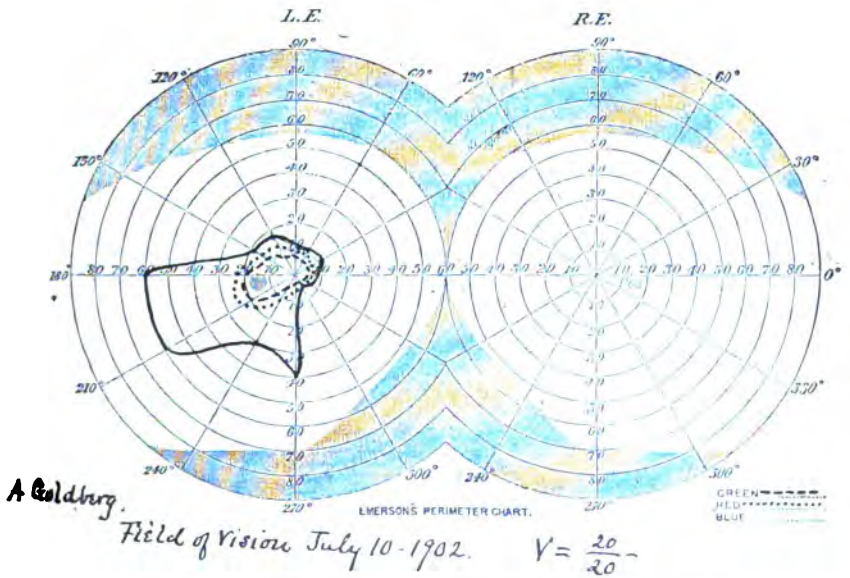

FIG. VI. A. GOLDBERG. Field of Vision, July 10, 1902. V.= 20/20.

July 10th. Severe pulsating pain over left side of head. L. E. + T. Vision with 1.5=20/20—. (Gave for left eye 1.5 D s).

HISTORY OF ROBT. B. HURST.

Robt. B. Hurst, age 28 years, came to New York Eye and Ear Infirmary March 12, 1900, in Dr. C. S. Bull's service. By the kindness of Dr. Bull I am permitted to present a history of Mr. Hurst's condition at that time.

March 12, 1900. Right eye: V.=20/70 with cyl. —0.75 D. ax. 180°=20/30. Left eye: V.=20/200 with cyl. —2 D. ax. 180°=20/40. R., Jaeger 1 at 7 inches; left, Jaeger 2 at 8 inches. Tension +1 in both eyes. Failing vision in left eye for eighteen months, and recently in right eye. No pain, but eyes tire easily. Irides react normally to light and convergence. This morning lost sight in right eye entirely for a few minutes, and has had three other attacks of same nature since this morning. Patient is neither rheumatic or gouty. Slight pressure on eyeball causes arterial pulsation.

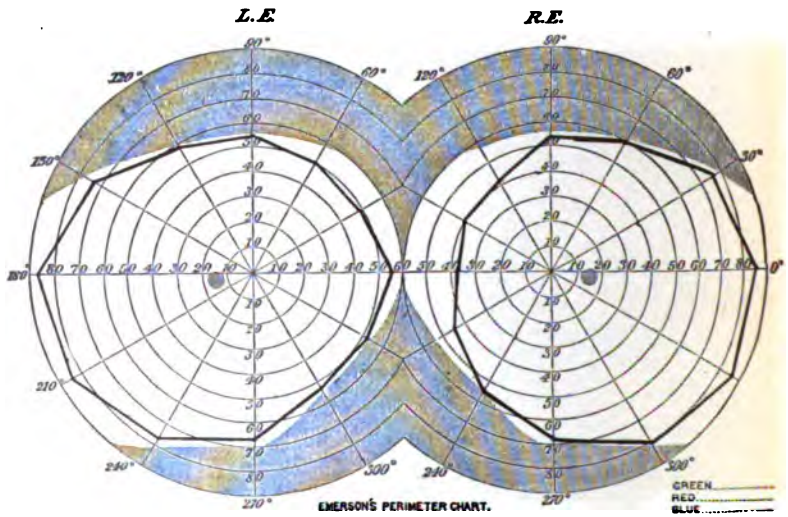

FIG. VII. ROBT. B. HURST. Fields of Vision, March 12, 1900.

March 16th. Tension same. Irides react to light and convergence. No arterial pulsation except on decided digital pressure.

Right eye: V.=15/15 W — D. 1.75 ax. 180°.

Left eye: V.=15/30 W — D. 2 ax. 180°.

March 23d. Right eye: V.=20/20—. L. E. V.=20/70 W — D. 2.25 ax. 180°=20/20.

April 19, 1902. Mr. Hurst consulted me at my office. Rheumatic, alcoholic, and specific histories negative. Age, 30 years. Married. Clerk.

April 22d. Tension in both eyes + T. 1.5. Both anterior chambers are of normal depth. Pupil in *left eye* moderately dilated and slightly elongated in the vertical diameter. Pupil in *right eye* of normal size; anterior ciliary vessels are dilated and tortuous in both eyes, but more markedly so in the left. Depth of cupping in *left eye* is 1.2 mm. Depth of cupping in *right eye* is .3 mm.

R. V.=20/50+. With —1.25 sph. ⌒—75 cyl. x 165 V.= 20/40+.

L. V.=2/200. Unimproved.

Urine: Negative.

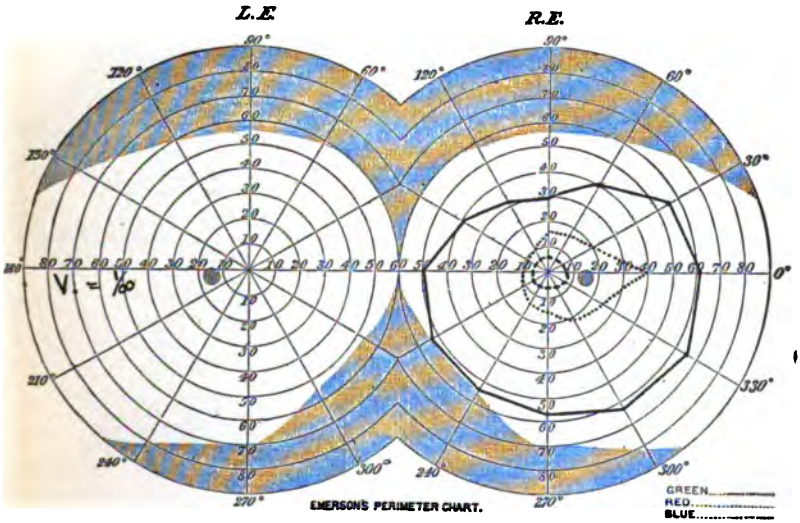

FIG. VIII. ROBT. B. HURST. Fields of Vision, April 22, 1902.

Patient could not distinguish the 1 cm. disc of the perimeter with the left eye, so the field was taken with a 2.5 cmm. disc. Green appeared white; green was seen as white and blue as green.

April 29th. Operation. Removal of the right sup. ganglion of the cervical sympathetic. Right pupil contracted almost to

pin-head size as soon as the ganglion was removed. Tension but little affected.

April 30th. Tension normal. Iris reacts readily to stimulus of light. L. E. tension + 2. Slight injection of ocular conjunctiva. Some pain. Acute attack of glaucoma apparently excited. Pilocarpine 1 per cent. t. i. d. Patient has vomited frequently. Was much disturbed by the ether.

May 1st. Pain on left side of head. Cornea slightly steamy. Ant. chamber left eye cloudy. + T 1½. Eserine (gr. i to oz. i) twice daily.

May 6th. Removed sup. ganglion of cervical sympathetic left side. Immediate effect, marked contraction of left pupil.

May 7th. + T 1½. Vision in left eye markedly improved.

May 8th. Slight pain in right eye. Patient does not think the vision is affected. Left eye quiet.

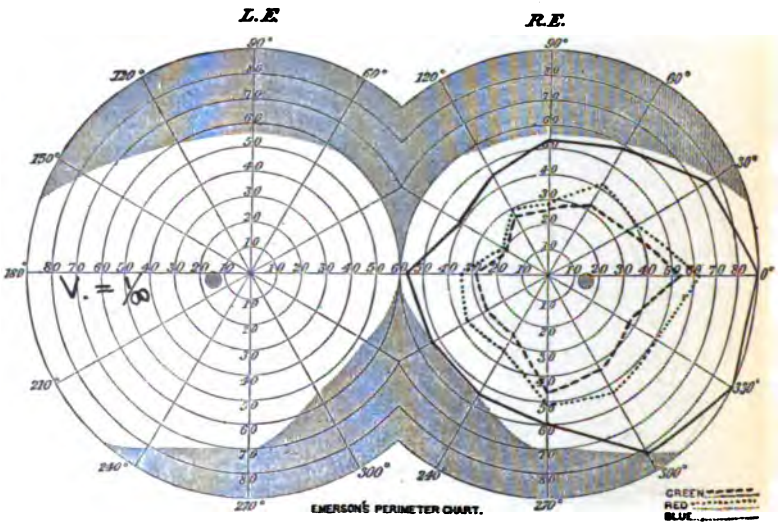

FIG. IX. ROBT. B. HURST. Fields of Vision, June 6, 1902.

May 10th. R. E. tension normal. Iris reacts to stimulus of light. Has had a very little pain. L. E. + T ½.

May 12th. L. E. + T 2. Cornea a trifle hazy. Vision diminished. No headache.

May 15th. Discharged improved. Eyes quiet. No pain. L. E. cornea clear. Tension slightly above normal.

May 17, 1902. Operation. Performed iridectomy on the left eye. Cocaine and holoccaine anaesthesia. Operation perfectly satisfactory, healing uneventful. Discharged from the Infirmary May 29, 1902.

June 16th. Vision, with correction, R.=20/20—. Had some pain in the right eye yesterday morning, which disappeared when a drop of eserine (gr. i to oz. i) was instilled.

June 23d. R. + T. L. Tn. Advised one drop of a solution of eserine (gr. i to oz. i) every third night.

June 28th. Has had two or three attacks of pain in the right eye and one in the left eye since June 23d. Had some nausea this morning.

July 12th. Has occasional headache. Took a long trolley ride yesterday afternoon and experienced intense pulsating pain in the occipital region which lasted a few hours. R. V.=20/20; +T. L. V.=9/200; Tn.

August 3d. Condition unchanged.

The patient experienced intense headaches, similar to that of July 12th, beginning in the occipital region and becoming general, for some months before he was operated upon. The headaches occurred at least once in two weeks. They were aggravated by assuming the recumbent position, and were accompanied by nausea and blurring of vision. The family history regarding glaucoma is interesting. The grandmother, on the mother's side, became blind from some unknown cause. It is thought by a grandson (who is a physician) to be chronic glaucoma. An uncle, 55 years old, has been suffering from simple chronic glaucoma for three years, and is gradually growing worse. The mother has some impairment of vision, from what cause I have not been able to determine. The only brother, aged 26 years, has simple chronic glaucoma, and has recently had an iridectomy performed on each eye by Dr. Ring of New Haven.

It will be seen that six sympathectomies have been performed on four individuals. All of the cases were those of simple chronic glaucoma. In one case a severe attack of glaucoma was

experienced about two months after sypathectomy, the attack occurring on the side of the sympathectomy and in an eye that was almost blind. In one case the more affected eye presented symptoms of more or less acute disturbance rendering iridectomy advisable. There has not been absolute freedom from symptoms in the eyes in which iridectomy has been done, but no subsequent glaucomatous attack of moment and no diminution of vision has occurred.

In the light of what has gone before and of the published experience of others, we may put some queries and answer them with some assurance of being right.

Regarding the effect upon the patient, there has been in all of the cases that I have observed, in addition to the symptoms of paralysis of the sympathetic (as ptosis, myosis, slight flushing of the ocular conjunctiva), a sensation of fullness in the head, intermittent and usually pulsating in character. This symptom is accentuated on over-exertion and, when present, is aggravated when the individual assumes the recumbent position. The symptom persists for many months. Some individuals suffer much from this symptom of vasomotor disturbance, other relatively little. Mohr (Monatsbl. f. Augenheik, xxxviii, p. 159), reports paræsthesia as a distressing symptom in one case.

Regarding the danger to life from the operation? If the operation is confined to resection of the superior ganglion, the danger to life is very little. Of some ninety cases known to the writer, there was a fatal issue in but one. This is referred to by Axenfeld, and doubt is expressed that death was due to the operation.

What disability does the patient suffer as a result of the operation? The patient is usually confined to bed thirty-six to forty-eight hours. Union is ordinarily by first intention. The superficial stitches are removed on the seventh or eighth day, and the patient can resume his ordinary life at about the same time. The inconvenience occasioned is not greater than, if as much as, that occasioned by iridectomy for glaucoma.

What is the condition of the eye regarding subsequent iri-

dectomy, and what is the influence on eyes with hemorrhagic glaucoma? In the two cases in which iridectomy was done by the writer after sympathectomy, there did not appear to be any more hemorrhage than occurs ordinarily. Recovery in these cases progressed satisfactorily. The cases of hemorrhagic glaucoma known to the writer were not aggravated by the operation. Mohr (loc. cit.) reports one case in which an iridectomy was followed by retro-choroidal hemorrhage with loss of sight.

Regarding the influence on the fellow eye? A number of reports of cases occur in literature in which the effect on the fellow eye was apparently beneficial. In the case of Mrs. V. of those reported, there appeared to be some enlargement of the field of the opposite eye, and the vision improved. In the case of Mr. Hurst an exacerbation in the glaucoma of the fellow eye occurred the day after the operation. There was much systemic disturbance from the other, and, as the exacerbations in the condition of the left eye were frequent before operation, it cannot be said that the operation itself was the cause of the attack. On the whole, the evidence is against any marked influence one way or the other.

Regarding the operation? Two routes are open to the operator, one behind and one in front of the sterno-mastoid muscle. The anterior route is the simpler and more direct. The ganglion can be reached and removed without wounding any important structure. The incision should begin or end just anterior to the tip of the mastoid process, along the anterior margin of the sterno-mastoid muscle, and need not be more than 5 cm. long. The external jugular can be avoided in the greater number of cases. It may be necessary to secure some cutaneous vessels. It is best to stop all bleeding, so far as possible, before passing the deep cervical fascia. The deep cervical fascia is now divided (a grooved director may be employed), dissecting with the handle of a scalpel or other dull instrument. By means of a retractor the sterno-mastoid is now drawn outward and backward; the spinal accessory nerve may now come into view as it passes into the sterno-mastoid muscle. The belly of the digas-

tric muscle forms the base of a triangle that is now entered, which contains loose connective tissue and some adipose tissue. The bundle of large vessels and the pneumogastric nerve lies along the anterior border of this triangle, and by continuing the "blunt" dissection it is soon found. These structures are drawn gently forward and toward the median line. If the dissection is carried deeper the smooth surface of the rectus capitis major muscle is encountered and the nerve trunks of the cervical plexus are seen. These nerve trunks may be mistaken for the cervical sympathetic; they are, however, whiter, and the plexus can be easily traced. In the writer's experience the sympathetic is always raised with the sheath of the large vessels. It is well to determine the location of the pneumogastric in order to avoid unnecessary complications, and to this end it is expedient to open the sheath of the vessels posteriorly. The white trunk of the pneumogastric nerve will then come into view. Search in the tissue of the sheath backward and a little inward will result in finding the sympathetic nerve. This should be carefully dissected free from the tissues in which it lies, and followed upward by "blunt" dissection, when the superior ganglion will be exposed. The lateral branches going to and from the ganglion should be divided and the ganglion followed well up to the base of the skull; it may then be seized with forceps at its upper extremity and torn out, or it may be cut out; the trunk of the nerve just below the ganglion may then be cut across. If the dissection is carefully made, there may be little or no bleeding after the deep fascia is reached. The deep fascia is now united by catgut sutures and the wound in the integument closed by means of a continuous silk suture, and the bandage applied. The operation itself need not consume more than fifteen or twenty minutes. Union by first intention usually follows. There is frequently slight swelling of the tissues in the vicinity of the wound, because of the trauma produced by the traction on the tissues.

In regard to the value of the operation in glaucoma? The literature on the subject seems to show that it is of no value in acute glaucoma and may be harmful. In hemorrhagic glau-

coma it appears to be of some value, at least temporarily. This is the result in a case operated on for Dr. Price at the New York Eye and Ear Infirmary recently. In three cases, referred to by Axenfeld, the results were negative. In simple chronic glaucoma good results *are reported* in about sixty per cent. of the cases.

In what forms of glaucoma should resection of the superior ganglion of the cervical sympathetic be performed? In all forms of glaucoma except the hemorrhagic variety, iridectomy should be tried first. This, in suitable cases, may be supplemented by anterior sclerotomy in seeing eyes, posterior sclerotomy in blind eyes. If the iridectomy and sclerotomy fail to arrest the disease, sympathectomy may be resorted to. In cases of chronic subacute inflammatory glaucoma and in cases of simple chronic glaucoma, if iridectomy is not successful, sympathectomy may be done as a supplementary measure. In hemorrhagic galucoma it should be tried.

The conclusions of Jonnesco and of Ball, in his early articles on the subject, are entirely too sanguine.

MICROSCOPICAL EXAMINATION OF EXCISED GANGLIA.

IRA VAN GIESEN, M.D.

Seven ganglia have been examined microscopically, including two bilateral operations, comprising thus five different cases. The work has been paralleled by the examination of control ganglia taken from subjects as near as possible the same age as the operation cases. As the control studies are very important in an examination of this kind, the normal ganglia were subjected to precisely the same steps as in the operation cases, and carried along with them side by side. Four ganglia of normal subjects were studied as controls and secured in autopsies averaging about twenty-four hours after death. (Thus far, however, but two of the control ganglia have been complete for study.)

We have endeavored to bring to bear on the question as comprehensive an examination as possible, and the technique

has been directed toward all of the structures of the ganglion in the following order: (1) The detection of any cytological changes in the neuron cell bodies. (2) A special study of the so-called pigment granules in the neuron cell bodies. (3) An examination of the connective tissue framework of the ganglion. (4) A study of the blood vessels; and (5) the examination of the medullated and non-medullated fibers.

Special methods, both of fixation and staining, have been used for each of these points in both sets of ganglia, — the operation cases and the controls, — and in all, some three hundred sections have been examined. Ten different fixations have been employed, as well as the several varieties of staining methods best adapted for the demonstration of each of the objects of examination.

(1) *The neuron cell bodies.* Throughout the series of operated cases, the neuron cell bodies show the normal arrangement and distribution of the chromophilic granules. There are no evidences of degeneration, nor is there any atrophy or signs of disappearance of the neuron cell bodies. In a very few places, in fact of quite exceptional occurrence, there are appearances which might be considered as similar to the form of chromatolysis in the centers of the neuron cell bodies seen in the central nervous system. This, however, is also seen in the control cases and it seems to be of no significance in relation to the production of the glaucoma. Here and there, also, are larger and smaller vacuoles in the periphery of the cell bodies, but this is obviously an artefact, and is due to the shrinkage of the cell in certain of the fixatives, leaving strands of protoplasm adherent to the capsule which thus enclose spaces.

(2) *The pigment granules.* The capsules of the ganglion cells are also without alterations. The pigment grains are certainly increased in the glaucoma cases as compared with the control cases. Both a larger number of cells contain pigment grains in the glaucoma cases, and the aggregate volume of the pigment grains is greater. While the control cases contain a considerable amount of pigment particles, this can be reckoned

as being only fifty to sixty per cent. of the quantity in the operation cases.

(3) *The connective tissue.* Studied in specimens prepared in Fleming's weak and strong solutions and stained by the picric acid fuschin method, the connective tissue framework shows no signs of proliferation or degeneration in the glaucoma cases. One would not be able to distinguish between the operation cases and the controls, judging by the connective tissue.

(4) *The blood vessels.* These were examined with especial attention, both in the substance of the ganglion and in the loose connective tissue surrounding it. The vessels are normal, the endothelial lining is intact, and the tunics of the vessels, both large and small, are without histological alterations.

(5) *The fibers.* The medullated fibers in the ganglion are so relatively few as compared with the non-medullated fibers that Weigert's method of staining the medullated sheath leaves the section quite decolorized. There are not enough medullated fibers to take the stain. Under the microscope, however, the bundles of fibers in the ganglion show here and there the darkly stained medullated fibers among the naked axones. Changes in the non-medullated fibers are exceedingly difficult to demonstrate. Unless there are changes of a coarse and gross character they are quite sure to escape attention. Compared with the controls, however, there seems to be no differences in the non-medullated fibers.

Summary. We find, then, that as far as our methods of examination of hardened material go the ganglia seem to be normal with the exception of an excess of pigment in the neuron cell bodies, and, as to the significance of this, if it has any, we are entirely, as yet, in the dark. With the exception of the increase of pigment it is doubtful whether any one could distinguish the glaucoma sections from the normal ones. The operation seems to depend upon the carrying out of a well-known physiological experiment in its effects on glaucoma rather than upon the removal of a morbid condition. At the same time,

however, the result of the examination does not positively preclude the existence of a lesion in the ganglia.

The examination merely shows that there are no coarse or gross lesions present. Even with the extent of the examination and of the methods employed, they are nevertheless crude and inefficient. And, further, the negative character of the examination does not at all undermine the theoretical conclusion that there is an excess of expenditure of neuron energy along the course of the vaso-constrictor fibers to the eye, that these fibers work unduly and too persistently. (The ganglia were examined at the new Pathological Laboratory of the Woman's Infirmary of New York.)

DISCUSSION.

DR. C. S. BULL. — I would like to say a few words upon the subject of this paper, based upon my experience in three cases. The first case, that of a patient fifty-two years of age, occurred eighteen months ago. There was absolute glaucoma and iridectomy had been done four years before. In the left eye vision was 10/200, with tension plus 2, and dilated pupil. The superior ganglion was removed and the immediate effect was reduction of tension and extreme myosis. There was no effect upon the field of vision, but the vision improved from 10/200 to 10/100, and remained unchanged for two months, when it slowly failed, and is now below what it was before the operation.

The second case, that of a man fifty-nine years of age, was operated upon eleven months ago. He had had an iridectomy on the left eye five years before, and in that eye had light perception. In the right eye vision was 20/200, the field gone on the nasal side and narrowed in the other quadrants. The right upper ganglion was removed, he having refused iridectomy. The tension was immediately lowered and myosis pronounced. Vision improved from 20/200 to 20/70, and still remains at that point. The tension is increased above normal, the field is still narrowed and the pupil is in a condition of dilatation.

The third case was a woman of fifty who was operated upon five months ago. The right eye was entirely blind from iridocyclitis, the original cause being traumatism. In the left eye vision was 5/200, with plus tension, narrowed field, and dilated

iris. After removal of the superior ganglion there was immediately myosis and lowered tension, but after two months there was widely dilated pupil and tension of plus 2, with no field at all, and the final result was absolute glaucoma.

It seems to me from my reading of the records of cases published and consideration of the remarks made upon the cases by the various operators that sympathectomy should not be considered at all for acute inflammatory glaucoma, and that in the cases of simple chronic glaucoma, whether iridectomy has been done or not, I am inclined to think that the one symptom that is liable to remain is the myosis. We all recognize, of course, that sympathectomy for chronic glaucoma is still sub judice and I thought the recording of these three cases might assist the paper of Dr. Weeks.

DR. E. GRUENING. — With regard to the paper of Dr. Bull's I would say we certainly all agree with him that when we see the eye in the first stage of glaucoma and recognize that we have to deal with chronic glaucoma that operation is indicated. In reference to the color field in this series of operations we have not been told by Dr. Bull exactly what the color field was before the operation, nor what the color perception was, and that is a very important point. When the patient comes to us in the later stage, and we are apt to be consulted by colleagues in such cases, where our colleague is in doubt as to whether the operation should be performed or not, I think it is very important to know whether there is any impairment of the central color perception or not. It is not so important to know what the color field is, for if the field for white light is encroached upon the color field is correspondingly impaired; the question is whether color perception is impaired, for if so there is atrophy, and if iridectomy is performed the benefit we expect is not obtained, and so I am guided in my advice as to whether an operation should be performed or not by the condition of the central color perception.

With regard to the operation Dr. Weeks speaks of I have also had some experience and have had it done in two cases. In the first case I proposed the operation and when I described it to the patient he said he preferred that a general surgeon should perform it. In my cases something occurred that is not mentioned in the cases of Dr. Weeks or Dr. Bull, namely, paralysis of the recurrent laryngeal nerve. The patient became

aphonic and remained so for nine months. The same thing occurred in the second case. In the first case operation was on the right side and in the second case on the left side, and the anatomical course of the recurrent nerve would not seem to have any influence on the occurrence of the condition. The first operation was performed by Dr. Willy Meyer, and I was present. It was the ordinary operation and apparently no nerve other than the sympathetic was cut. The case was one of chronic glaucoma. One eye was entirely blind, and in the other only one quadrant of the field was left. The patient complained of constant headache and there was a slight increase of tension in both eyes. After the operation they became soft and the headache disappeared. The patient has not had increased tension nor been troubled with the headache since. His improvement has lasted since the operation, which is now fifteen months, but he was aphonic, due to paralysis of the recurrent nerve for nine months, after which the symptom disappeared.

The second case was one of atrophy of the optic nerve. Some of the cases were not really cases of glaucoma, but of atrophy of the optic nerve, and some improvement was noted in these cases. I told the patient that such cases had been reported and he was willing to have the operation done. He had lost sight in the right eye completely, and in the left eye had telescopic vision only. There was good central vision. The operation was performed by a surgeon at the Mt. Sinai Hospital, and nothing but the sympathetic was attacked and the superior ganglion removed. The aphonia occurred exactly as in the other case and it is now four months since the operation, yet he is still suffering from paralysis of the recurrent laryngeal nerve of the left side. Vision was completely lost after the operation. In regard to the conclusion of Dr. Bull that the myosis is the only permanent symptom, we all know that; it is to be expected.

Dr. Samuel Theobald. — There is one point about which I would like to ask Dr. Bull. I understood him that the best results were where iridectomy was done at the same time on both eyes. My own inclination would be, in performing iridectomy for glaucoma simplex, not to operate on both eyes at once, because I think we all recognize that the outcome is very uncertain. We may get good results, but sometimes we get just the opposite, and so for myself I would not be disposed to operate on both eyes at the same time. I would not like to put

all my eggs in one basket in that way. I would operate on one eye and be guided as to a second operation by my first experience.

DR. THOMAS R. POOLEY. — I should like to inquire in how late a stage of glaucoma this operation is recommended? I have had within the last few months a consultation almost every day for cases of glaucoma, and patients have visited me for the express purpose of asking if I would advise this operation. One such case I would like to mention: A patient from Boston, who having exhausted the resources of that city came to New York for further advice, and one of our celebrated New York men unhesitatingly advised the removal of the superior sympathetic ganglion. In the left eye there was doubtful perception in a very limited quadrant — that kind of vision where a patient can count his own fingers. The patient was very anxious to have the operation done and I took a diplomatic position, declining the operation myself and trying to have her see someone else, but she was persistent and asked me: "If you had the same condition, what would you do?" I said: "I would not be operated on"; that was easy. That is only one of many such cases, and never a week goes by without my being consulted by hopeless cases. I like to hear these reports, but I have an abiding faith that they will go the same way as so many other things: that they will have their little day and cease to be; and, while I hope for something that shall be permanent and hold out some hope to these patients, just at present I am conservative in my views.

DR. H. B. CHANDLER. — I consider this one of the most important subjects. From my own experience of twenty years in the treatment of cases of simple chronic glaucoma I have found very little advantage in performing iridectomy. It is true should an attack of acute or subacute glaucoma supervene, which, however, I believe secondary to the pre-existing chronic state, and due to an entirely different cause, one being excessive secretion and the other closure of the canal of Schlem, iridectomy would be justifiable.

If we had the statistics side by side of operated and non-operated cases, I think it would be found that the ultimate results are about the same.

I have followed several cases where one eye has been operated upon and the other not, where there has been a gradual loss of

vision nearly equal in both eyes. There is a certain number of cases where simple chronic glaucoma is separated from simple subacute with difficulty, there is no sharp line of demarcation by which we can separate the two.

I would like to speak of an operation I have been doing for the last two years in those cases of a doubtful nature, where we feel some operation is necessary, but fear to operate on account of past experiences. It is a question in these cases where tension is increased, vision diminished, but no acute symptoms of glaucoma present, whether the symptoms present are due to closure of canal of Schlem or to an increased secretion from excessive blood supply to the ciliary region; this increased secretion may be due to dilated arteries, change in their structure, or some interference in the returning venous blood, in other words, either an active or passive congestion.

In this class of cases I have divided the anterior ciliary arteries before they perforate the sclera.

In every instance satisfactory results have followed this operation, lower tension, improved vision, and relief from pain, when that symptom has been present.

In cases of acute glaucoma I believe there is only one operation, iridectomy.

From my experience of the past two years I think the division of the anterior ciliary arteries, in cases where there was doubt about operating, has been most satisfactory.

Dr. Myles Standish. — Just a word about Dr. Chandler's operation. I have been present at several of the operations, and such cases as I have seen were those in which there was not so marked dilatation of the pupil as there was increase in tension. After the cutting of these arteries as they go into the sclera there is in fifteen minutes diminution of tension. There was no doubt of it at all and the stopping of pain was immediate. As to the ultimate outcome of the cases I do not know, but at the time the results spoken of were certainly produced, and to stop an attack of glaucoma in an eye that is hopelessly involved, with great pain, and where we might be inclined to advise enucleation, this is a comfort to any man and I shall always resort to it before enucleating an eye.

Dr. H. W. Ring. — You have noted the sad history of the young man Hurst, who is only twenty-five. I had his brother

for a patient recently, and did an iridectomy which was clean, and I think I got the root of the iris, but the outlook for the boy is bad in spite of all that has been done. There was no reaction after the iridectomy, but he was anxious to do some studying to get through his college term, and could only work one hour a day. On one day he tried some physical exercise and immediately had pain in the head and eyes. Considering the condition the eyes are in it did seem to me that were it an ordinary case he should have been able to get more use out of them. The outlook, however, is very uncertain, particularly considering the bad family history, and there is going to be the question of what more can be done for him in the future; whether or not a sympathectomy will prove any more effective. I should have been much disappointed in the case except for his distressing family history. His field was very little narrowed, as it was taken early. I operated on the second eye last month, not because of any marked glaucomatous symptoms, but for safety.

Dr. J. E. Weeks. — In regard to the continuation of any particular symptom after removal of the superior ganglion, I think the myosis does not remain. Dr. Bull thought it did, but I do not think so. In regard to having the general surgeon perform the operation, I think Dr. Bull has answered that question very well.

In the cases that I have had charge of there has been no aphonia at all, no disturbance in the voice. The incision made has exceeded 2 inches in only one case. I measured the incision made by a general surgeon in one case and it was $5\frac{1}{2}$ inches. It is not necessary to make an incision of such length, as the ganglion can be removed just as well through an incision 1 or 2 inches in length. There is no necessity at all to interfere with the recurrent laryngeal nerve. Furthermore, if the incision is made along the anterior border of the sterno-cleiodmastoid muscle there need be no disturbance of any important structure except the ganglion.

Dr. Gruening has spoken of the operation for optic nerve atrophy. Dr. Ball of St. Louis has tried it in five cases with no result except in one case, in which some improvement in vision was noted. It has been done at the New York Hospital in two cases and the results have been negative. It has also been done in hydrophthalmos with negative results.

Dr. Pooley spoke of the roseate report I have made today. I have approached the subject in an entirely unbiased manner

and have endeavored to report the facts as they are, and have drawn a few conclusions.

In reference to the patient spoken of by Dr. Ring it seems to me that, if iridectomy has proven a failure, from the reports we have had of the effect of removal of the superior ganglion in cases of simple chronic glaucoma we might consider the removal of the ganglion in his case providing the vision tends to fail. In the case of the brother we seem to have the condition fairly well under control. Iridectomy has been done on one eye, and I shall probably advise it on the other. Sympathectomy is not contraindicated after iridectomy.

DR. RING. — I did not say his vision had fallen away at all, but simply that there is inability to use the eyes. His vision is normal.

A CASE OF ENDOTHELIOMA OF THE ORBIT.

BY C. A. VEASEY, M.D.,
PHILADELPHIA, PENN.

The following case of orbital growth presented himself at the Jefferson Medical College Hospital on July 8, 1901, for examination and treatment.

History. H. R. P., married, a male, aged 35 years, is a chemist by occupation. According to the patient's statement his mother died from "cancer of the tongue." His father had an enlargement on the cheek bone, but as it caused him no annoyance nothing was ever done for it. One brother died of pulmonary tuberculosis. The patient himself was tall and slender, his general health being good. Twelve years before the examination a small growth about the size of a green pea was observed beneath the left upper eyelid at the external portion of the orbit, and in front of the location of the lachrymal gland. The size of this growth slowly increased until it became as large as a walnut. At this time he consulted some oculist at a hospital dispensary, where the condition was diagnosed as a prolapsed lachrymal gland.

Examination. Examination showed a kidney-shaped growth, situated beneath the upper third of the left orbital ridge, which was mobile from side to side, but apparently having deep attachments in the orbital cavity. The eyeball was pushed slightly toward the nose and downward, and there was some impairment of the upward movement. No ophthalmoscopic change was found, and the vision of each eye was normal. During the year preceding this examination the growth of the tumor had been much more rapid than before.

Operation. Extirpation was advised, and, as the patient refused to have employed any general or local anæsthetic, the tumor was dissected out without their aid through an incision along the orbital ridge in the outer third of the lid. Very little difficulty was experienced in its removal, except that the point of attachment was deep in the orbital cavity, from which it had to be divided with scissors. There has been no recurrence of the growth.

The specimen was sent to the pathological laboratory of the Jefferson Medical College, and under the direction of Professor W. M. L. Coplin sections were made and a report submitted.

Macroscopical Examination. Macroscopically the growth was kidney-shaped, measuring 2½ cm. in length, and from 1 to 1½ cm. in width. It was hardened in a 3 per cent. solution of formalin and was firm in consistency, cutting with little resistance. The outer surface was smooth and of a slate color, with grayish mottling. The inside surfaces present a granular appearance, one-half of these surfaces being dark gray with blackish, yellowish and brownish mottling, while the remainder is light gray in color. If pressure is brought to bear upon the latter half a grayish gelatinous material exudes, giving to the surface a honeycomb appearance. In the dark gray half of the inside surfaces are three black areas containing gelatinous material, each measuring approximately 2 mm. in diameter, two of these areas being partially surrounded with a narrow rim of grayish translucent jelly-like substance. The mass is completely encapsulated. After dehydrating in alcohol and embedding in paraffin the sec-

tions were stained with hematoxylin and eosin, picric acid, toluidin blue, by Van Giesen's method and for hyalin material.

Microscopical Examination. Sections made from the light gray half of the mass are covered on three sides by a layer of fibrous and muscle tissue; the width of the layer varying from 1 to 2 mm. in thickness. It contains areas of rhexis, and scattered through it is a small amount of blood pigment. It also contains a few small round connective tissue cells and a number of large cells that take eosin intensely, but do not take any basic stain. At one end of the growth there is an area of gland structure in the fibrous layer, but between this and the tumor proper the capsule is found unbroken. The gland structure presents the ordinary appearance of normal lachrymal gland.

Within the capsule the structure is composed of fibrous and muscle tissue and finely reticulated network that stains faintly with the basic dyes. In this structure are what appear to be giant cells, with a low magnification, but with a high magnification it is found that they consist of a number of cells lying very close together. Their nuclei stain intensely with the basic dyes, while the protoplasm stains with the acid dyes. In a number of the cell clusters there is a faintly basophilic, intercellular substance; here the nuclei do not stain so intensely and the protoplasm is granular and basophilic in character. Throughout the reticulated structure there is also found another type of cell, varying in size from 7 to 20 micro-mm. in diameter, some being oval and others polyhedral in shape. Some of these cells do not take any basic stain, while others take it only faintly. Many anastomosing spindle and stellate cells are also found.

In the dark gray portions of the growth the cellular elements are more conspicuous. In many of the cells the nuclei are oblong, resembling the nuclei of muscle fibers, and varying from 8 to 15 micro-mm. in size, and staining intensely with the basic dyes. Some of them are surrounded by a rim of protoplasm, but the greater number appear to lie free in a basophilic granular material. In other situations the nuclei are either oval or spindle-shaped, but are all surrounded by a rim of protoplasm.

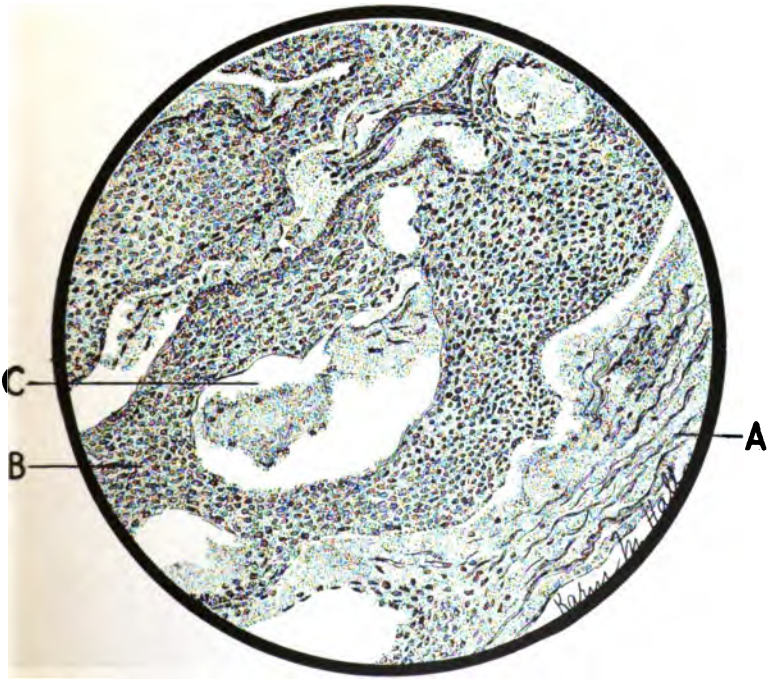
C
B
A

Many of these nuclei contain vacuoles. Beside these, or near by, are many spaces that are found to be occupied by a finely granular basophilic material, and are surrounded by a rim of basophilic material somewhat denser than that just referred to. There are also a few scattered areas of hyaline cartilage undergoing myxomatous degeneration.

Throughout the entire sections, but more marked in the periphery, are large areas that are composed of homogeneous acidophilic substance, and within these areas are grouped the cellular masses and mantle-like accumulations of endothelial cells. The microscopical examination, therefore, shows the growth to be a mixed tumor of endothelial origin similar to the mixed tumors of the parotid to which the term endothelioma has been given; and the general grouping and arrangement of the cells is such as to justify the term used by Borrmann of lymphangio-endothelioma.

Warthin[1] has reported a somewhat similar case having its origin in the lachrymal gland. The patient was a farmer, aged 45 years, whose family and personal history were negative. Five years before the growth was removed by Dr. Fleming Carrow there had been observed a bulging of the right eye, which increased gradually until there was marked exophthalmus. For two years preceding the removal of the growth the increase in size had been very slow. Vision in the right eye was 14/120; in the left 14/20. The eye of the affected side showed neuroretinitis and interstitial choroiditis. The tumor was about the size of a walnut, and was found well back in the orbit in the lachrymal gland region, but its exact relations to the gland could not be definitely determined. The tumor was shelled out of its bed, having no attachments, after which the exophthalmus disappeared, and the vision improved.

The growth was found to possess a thick capsule of dense hyaline connective tissue, from which trabeculae of a similar tissue passed into the growth, giving it somewhat of a lobulated appearance. Between these trabeculae the appearance of the cut surface varied greatly, in areas being firm and quite like

cartilage, in other portions translucent and jelly-like; other areas were yellowish, granular, and of a crumbling consistency. There were a few small reddish spots scattered over the surface. Immediately beneath the capsule the peripheral portion was pinkish, more homogeneous, and of softer consistence.

The microscopical examination showed the growth to be a mixed tumor, containing myxomatous tissue, cartilage, cylindromatous and sarcomatous areas, similar to the mixed tumors of the parotid. Just beneath the peripheral cellular zone there were scattered gland spaces lined with short columnar or cubical epithelium similar to that of the lachrymal gland. Many of these glands were very irregularly branched, some were cystic, and nearly all contained a colloid substance. A few of these glands were found also in the peripheral zone, but they were most numerous toward the center, where some areas presented the appearance of normal lachrymal gland structure. It is believed, therefore, that this growth had its origin from the lachrymal gland.

The author in his most excellent monograph reviews the literature of lachrymal gland tumors, and states his belief that the great majority of lachrymal neoplasms are mixed growths of endothelial origin similar to his own case, and should therefore be classed as endotheliomata, to accord with the similar tumors of the parotid. It is also stated there can be but little doubt that in all of those reported cases of lachrymal gland tumors in which cartilage, hyaline, and myxomatous tissue were present in the growth the neoplasm was similar or identical with the mixed tumors of the parotid.

In my own case the connection with the lachrymal gland is not so apparent, for while the growth seemed to be so adherent to the gland that a small portion of the latter was excised in its removal, serial sections show that the capsule between the gland and the growth was unbroken. In addition, no gland spaces with epithelial lining are present.

As pointed out by Warthin, the serous gland endotheliomata occur most frequently in early adult life, giving rise to slow-

growing painless tumors which are usually found encapsulated. There seems to be very little tendency to become malignant, and when they have been entirely removed their recurrence is seldom observed.

(1) Aldred Scott Warthin, "A Case of Endothelioma of the Lachrymal Gland (Myxo-Chondro-Endothelioma Cylindromatodes), with an Analysis of Previously Reported Cases of Lachrymal Gland Tumors." Archives of Ophthalmology, Vol. 30, 1901, p. 601.

DISCUSSION.

DR. LUCIEN HOWE. — As I read the title of this paper it occurred to me that it might be interesting to refer to another case of very similar character. This showed the ordinary symptoms of what I considered to be a sarcomatous growth of the orbit, with a gradual increase of exophthalmos. The condition is shown in this photograph taken just before the operation. That diagnosis was not based on my examination alone, but on sections of the tumor made at the state pathological laboratory. The degree of exophthalmos is the only particular point of interest.

While the subject of these tumors is before us I would like to call attention to a pair of hemostatic forceps which I have found useful when operating on these cases. The tumor can be grasped from each side so that we have it under control, and the bleeding can be arrested in a manner that to me was very satisfactory and infinitely better than with the ordinary straight forceps. (Exhibiting photographs and forceps.)

MELANO-SARCOMA CHOROID AND ORBIT.

S. B. ST. JOHN, M.D.,
HARTFORD, CONN.

Mrs. R., 70, a rather slender but fairly well-preserved lady, came to me Feb. 24, '99, with following history: Four years before she ran against a door in the dark, striking head violently, but soon recovered from effects. Soon after she found the vision of right eye was poor, she saw a local physician who

could use the ophthalmoscope, who said the retina was detached. Since then vision has steadily failed and on her visit to me V=0. The eye had a glaucomatous look, T+1, pupil moderately dilated, lens partly opaque, fundus not visible. There is a salmon colored patch in the sclera about 3 mm. from upper edge of cornea and about 3 mm. in diameter. For three weeks there has been discomfort like that from a smooth foreign body but no decided pain. Using bi-focal lens for other eye $\frac{+2.75}{+5.50}$ and VL=+2.75 was 20/40. She lived at a distance and I advised no interference then but to see me again in 3 months. I next heard of her from her son, who reported that something black was growing on the eye, and the discomfort was somewhat greater. She was brought to me April 12, 1902, and said she had had much pain at times since I saw her. Had been to a charlatan institution for six weeks where they assured her they had been able to save the *other* eye. For a year there had been a black protuberance above the cornea (where the salmon patch was). The eyeball was immovable and protruded considerably, but she could close the lids over it. The cornea was eroded, conjunctival veins distended, T+3 and at the outer side a hard mass could be felt attached to the eyeball. The black protuberance was larger than the salmon patch had been and was roundish, elevated some 4 mm. above the surrounding tissue and hard to the touch. Under ether enucleation was done with much difficulty, no muscles being found and much dissection with scissors being required. After removal of the eyeball and attached mass, the orbital cavity presented a fairly smooth and pinkish appearance except at the site of the ethmoidal plate, where it was rough and black, as was that portion of the tumor that had lain in contact with it. There was not much hemorrhage and recovery was uneventful. I saw her last on June 16; there was no sign of return and the cavity looked well and she was given an artificial eye, which she prefers to wear, though it is, of course, motionless. Dr. A. J. Wolff has kindly made for me a very cleverly mounted macroscopic preparation of one-half of the specimen divided longitudinally, which permits inspection

of both sides, and also several slides of the entire mass, and has also furnished the following report of the microscopic findings:

HARTFORD, CONN., July 14, 1902.

MY DEAR DR. ST. JOHN: —

The tumor you have submitted for examination is one of the common intraocular growths of adult life; but it presents certain uncommon peculiarities, in fact, rare peculiarities. The intraocular mass seems to have its origin directly from the choroid, occupying more than one-half of the vitreous space. This has to a certain extent displaced the lens, and certain parts of the retina are detached. On the surface and to the sides of the neoplasm, the structure of the retina is wholly destroyed, and the symmetry of the eyeball markedly altered. On the exterior of the eyeball are to be observed black masses, which upon close examination are found to be composed of extended portions of the choroid and the intraocular growth.

Exteriorly is to be seen a large dense mass, almost semilunar in shape, closely blended with the base of the eyeball, which presents a shape not unlike the kidney, the optic nerve springing from a well-marked hilus, and near the latter, a large mass of melanotic material can be seen. The outer growth seems to have infiltrated the surrounding structures.

Microscopically, the intraocular tumor consists of moderately sized spindle-cells, with a very small amount of connective tissue, and quite a large amount of melanotic material, which, as seen in the sections, is of a golden yellow color. The intervening grades of pigmentation are due to the deposit of this material (melanin). The structure shows it to be a sarcoma of the melanotic spindle-celled variety. This, of course, is one of the commonest varieties of the melano-sarcomata.

It is the outer tumor that presents the peculiarities of which I spoke. In this mass quite a quantity of melanin is to be seen, but when examined microscopically it is seen to consist of a reticulum of connective-tissue fibres, in the spaces of which are to be found groups of large sarcoma-cells, but these are not

aranged in compact concentric masses as in ordinary carcinoma. Large quantities of melanin are to be seen in the fields. The structure of this part of the growth corresponds to that of the melano-alveolar-sarcomata, which is comparatively rare.

In this case are presented two varieties of sarcoma distinctly separated from each other by the dense tissues of the eyeball, the intraocular mass springing from the deeper pigmented layers of the choroid, and the extraocular mass of an entirely different histological structure infiltrating the external structures, following the sheaths of the blood vessels, which are seen to be altered and thickened by deposits of large round cells, similar to those of the tumor. In this respect the case is one of extreme interest and rarity.

Yours sincerely,

ARTHUR J. WOLFF.

DISCUSSION.

DR. J. A. ANDREWS. — I have learned since my return to New York of the death of a patient whose eye I removed for sarcoma of the choroid twenty years ago. There had been no return of the disease up to the time of his death, two years ago, which, so far as I was able to learn, was in no way related to malignant disease.

One year ago I removed an eyeball that was the seat of choroidal sarcoma which had penetrated the globe and invaded the tissues of the orbit, and the disease returned locally within three months after the operation. It has been my experience, and, I believe, that of others who have operated upon such cases, that when the disease has extended to the optic nerve, or penetrated the globe and invaded the tissues of the orbit, the affection invariably returns locally within a short time after the operation, no matter how thoroughly the contents of the orbit have been removed.

I am aware that there are a number of cases on record where an eye has been removed for choroidal sarcoma—without implication of the optic nerve or invasion of the tissues of the orbit—and the patient lived for a number of years without return of the disease; but never, so far as I am aware, is the patient free from the danger of local return where the tissues of the orbit are involved.

Spindle-cell Sarcoma of Choroid.
Retro-ocular growth is Alveolar Sarcoma.

DR. W. F. MITTENDORF. — I would like to ask Dr. St. John if he has treated the wound in any special manner after removal of the tumor? I generally use Vienna paste, or carbolic acid, and think that method has been very satisfactory.

DR. SAMUEL THEOBALD. — One point I think we all agree upon is that, when we have to do with an intraocular growth, we should divide the optic nerve as far back as possible. Many years ago, when I was a student in London, Mr. Bader was using a pair of fixation forceps that had only one tooth on each side, very sharp-pointed, and with a shoulder that prevented complete crossing of the teeth. They actually took hold of the sclerotic. I have found them extremely useful in performing the operation of enucleation. After having divided all the muscles, it is very difficult, as everyone knows, to grasp the eyeball with the ordinary fixation forceps. With these forceps one can grasp the sclerotic and make any desired amount of traction, and with their aid I have been able to cut the optic nerve very much further back than it is possible to do without help of this sort. I do not know how many of you are familiar with these forceps, but throw out the suggestion for what it is worth.

DR. H. W. RING. — I recently saw at Saratoga an instrument devised by Dr. Suker, of Chicago, which grasps the entire eyeball after the manner of a pair of obstetric forceps and locks. With these you can draw the eyeball out easily.

DR. S. B. ST. JOHN. — In answer to Dr. Mittendorf's question, I used no special treatment after operation in this case. I curetted as well as I could. The surface of the bone had a carious appearance and I did not think I was justified in scraping away the entire thickness of bone, which is so little at that point. The healing was as complete and satisfactory as after an ordinary enucleation.

In regard to Dr. Theobald's remarks about the division of the nerve, you can see by my specimen that something over an inch of the nerve was removed and it is not implicated at all, but lies free from the mass that surrounds it.

I have employed forceps like those referred to by Dr. Theobald and I like those spoken of by Dr. Howe for controlling the hemorrhage. I have succeeded in removing an eyeball without more loss of blood than a teaspoonful. In some cases where I feared hemorrhage I found it a great relief to be able to enucleate the eye with so little of that annoying difficulty.

CONGENITAL ORBITAL CYST WITH MICROPHTHALMOS.

BY GEORGE C. HARLAN, M.D.,
PHILADELPHIA, PENN.

The curious anomaly usually described as "congenital orbital cyst with microphthalmos or anophthalmos" seems to be a rather rare one. A few cases have been reported in England and France and quite a number in Germany since Arlt first called attention to the subject in 1858, but, so far as I have been able to learn, none in this country except the one that I recorded in a paper read before this Society in 1893. In this case, that of a child five months old, the cyst filled the whole orbit and pushed forward both lids with great tension and stretching. Dr. McFarland, demonstrator of pathological histology in the University of Pennsylvania, found a "peculiar tissue resembling an atypical cerebral tissue, collections of nuclei corresponding to those of neuroglia, and muscle fibres loosely bound together, which may represent some of the muscles of the eyeball." The patient died thirty hours after the operation, apparently from exhaustion following shock, and careful inspection of the orbit revealed no trace of an eyeball or optic nerve.

The case I now report is a typical example of the large proportion of those recorded, which are usually described as "congenital lower lid cysts with microphthalmos." The patient was a rather delicate-looking but apparently healthy girl, seven years of age, a Polish waif from the coal regions without other obtainable history than that the tumor was supposed to be congenital and thought to be increasing in size. The left lower lid was pressed forward by a large, incompressible but tensely fluctuating cyst, the blue color of which was evident through the thin and distended skin and gave, at first sight, the im-

HARLAN.— Congenital Orbital Cyst.

pression of an aneurism. The external dimensions of the tumor were 40 mm. by 25 mm. The lower margin of the orbit was 5 mm. below the level of that of the other eye. The interpalpebral commissure was pushed upward and arched by the pressure of the tumor and opened into a deep conjunctival sac above the cyst. At the bottom of this sac could be felt a rudimentary eyeball, apparently scarcely larger than a pea, which moved in unison with the other eye. The right eye was perfect, and no abnormalities could be found elsewhere.

The cyst was removed without serious difficulty. It was found to extend back to the bottom of the orbit, but no connection with the rudimentary eye could be established. It was filled with a clear, yellowish fluid. It was submitted for examination to Dr. Flexner, the pathologist of the Pennsylvania Hospital, who has furnished the following report of his examination:

"The outer layers of the section show muscle and adipose tissue. The inner layer of tissue consists of sclerotic fibrous tissue in which sparse blood vessels, of small calibre but thin walls, occur. The innermost layer is somewhat polypoid in appearance, as there are irregular elongations projecting into what was doubtless the cavity of the cyst. In these there is much pigment of dark brownish-black color, sometimes clearly within cells. Lighter yellow pigment also occurs, these being extravasated blood and hæmatoidin. Extending into the sclerotic tissue along rifts in the section are similar pigmented cells and hæmatoidin, and these masses are included in a highly cellular tissue in which the cells are oval and round, but larger than the cells of the granular layer of the retina. In some sections the pigment forms an almost continuous layer within the cavity of the cyst, and, under a high power, it is resolved into fine yellowish-brown or yellowish-black granules. It also appears in branching cells in the sclerotic layer. No true retinal elements persist." This evidently suggests the structures of an eye, including muscular, sclerotic, choroidal and possibly retinal elements.

The pathology of these cysts is very obscure. Panas considers this the most obscure chapter in ocular pathology. Most authorities agree that they are formed of embryonic elements intended for the development of the eye, and are the result of an imperfect closure of the fœtal fissure, though a few insist that they have no necessary connection with the globe, whose development is prevented by their presence. Talko and Hoyer supposed that they have their origin in an entanglement of the upper part of the lachrymal sac, and Panas believed that the case described by him was one of fœtal involution of the mucous membrane of the nose and accessory cavities. Cases occurring in connection with complete anophthalmos, which are very rare, have been thought to be analogous to hydrophthalmos. A review of the literature, with a complete bibliography, is given in my former report.

DISCUSSION.

DR. E. E. HOLT. — I had about ten years ago a case with a history like this: A woman in the early part of gestation, living in the country, where they were digging a cellar under the house, had a child get in the way of the dirt being thrown out, so that a shovel full of dirt was thrown directly into the child's face. The mother saw the accident, and screamed that the child's eyes were put out. In due time the woman gave birth to a child without eyes, and it was brought to me at twelve years of age with both eyes gone, just a rudimentary condition, looking very much like the picture after destructive inflammation and atrophy of the globes.

A CASE OF METASTATIC CARCINOMA OF ONE OPTIC NERVE, WITH PECULIAR DEGENERATIONS OF BOTH NERVES.

CLINICAL AND PATHOLOGICAL REPORT.

BY WARD A. HOLDEN, M.D.,

NEW YORK CITY.

(*With four figures.*)

In the past three years valuable contributions to the pathology of the optic nerve have been made, particularly by Druault, Birch-Hirschfeld, and Nuel. We still have much to learn, however, and I wish here to describe a case which seems of importance both clinically and pathologically. Important, first, because it shows that an optic nerve may be destroyed for some distance by a new growth, with complete blindness of four months' duration, yet without the development of pallor of the disc; and, second, because the second nerve in this case shows that an affection of vessels in the pial sheath may cause a limited sclerosis of the nerve, producing a defect in the field of vision.

The *clinical history*, in so far as it bears upon the eye symptoms, was as follows:

S. B., a negress, aged forty-one, married, and without evidences of syphilis, alcoholism, or arterial sclerosis, had the right breast amputated for carcinoma early in 1900. Nov. 7, 1901, she was admitted to the Roosevelt Hospital complaining of persistent vomiting, weakness, and headache. December 6th she was discharged, improved, after treatment of the stomach. Jan. 15, 1902, she was admitted again, on Dr. James' service, with emaciation and weakness, vomiting, continuous severe pain above the left eye, and partial paralysis of the left third nerve.

On examining the eyes at that time, I found the following condition: Left, nearly complete paralysis of all muscles sup-

plied by the third nerve. Left pupil large and reacting to light neither directly nor consensually. No perception of light. Fundus normal.

With the right eye the patient readily counted fingers obliquely across the ward, perhaps forty feet away, and she had noticed no disturbance of vision in this eye. The field was complete for movements of the hand, but for a three-mm. black dot, and for pale grays and colors there was a defect, including the infero-nasal quadrant, and encroaching upon the supero-nasal quadrant (Fig. 1). The fundus was normal. The pupil reacted directly to light, but not consensually.

The patient stated that the left eye had been totally blind for over a month, and that its vision had been failing slowly for some months before that.

My *diagnosis*, recorded at that time, was: multiple metastatic carcinoma at the base, involving the chiasm or the optic nerves anterior to it. However, realizing that this condition was hopeless, and that the same complexus of ocular symptoms might be produced by gummata of the meninges, I suggested that antisyphilitic treatment be employed, and this was done. But the patient gradually became more emaciated, and died April 11, 1902. Frequent examinations over this period of three months revealed no change in the condition of the eyes. Both discs remained normal and alike, and the expected pallor of the left disc did not appear.

The *autopsy* was made by Dr. Hodenpyl eight hours after death. The pyloric end of the stomach, the lungs, and the liver were found to be studded with small nodules, apparently carcinomatous. I was permitted to remove the brain, optic nerves, and posterior segments of the eyeballs. After taking out the brain there appeared an area of discolored nodular dura, irregularly two cm. in diameter, about the left optic foramen and sphenoidal fissure (Fig. 2). One nodule involved the left third nerve directly, and another was adherent to the left optic nerve which, at a point one cm. anterior to the chiasm, was increased to twice its normal thickness. Passing backward

from this point, the nerve thinned down to its normal size before entering the chiasm, but, passing forward, a thickening of its sheath could be followed into the orbit 1 cm. beyond the optic foramen.

The right nerve was of normal size, shape, and appearance, and had not been involved by the new growth.

MICROSCOPIC EXAMINATION OF THE LEFT OPTIC NERVE.

The flattened nodules which were scattered over the area of affected dura were found to be carcinomatous foci, which rather rested upon the dura than deeply invaded it. The left optic nerve in its most thickened part was occupied by a carcinomatous growth extending directly from the dura and leaving only a crescentic marginal area upward and inward, in which any semblance of optic-nerve structure could be found. The invaded interseptal spaces contained only carcinoma cells, with here and there a compact ball of neuroglia (Fig. 3). Passing backward the carcinomatous infiltration gradually became less, and ended in a small group of cells lying just beneath the pial sheath, 2 mm. in front of the chiasm. Passing forward, the carcinomatous infiltration rapidly decreased, but as the nerve passed through the optic foramen and there became invested with its dural sheath, the dural carcinomatous infiltration followed, filling the space between the dural and the pial sheaths for a distance of 1 cm., and sending a few tracts of carcinoma cells into the nerve along its septa. In the thickest portion of the nerve, the Weigert stain revealed only a few normal medullated fibres which lay in the uninvaded crescentic nasal portion of the nerve; but farther toward the eyeball, in the chiasm, and in the optic tracts Weigert's method revealed no atrophy. One cm. behind the eyeball Marchi's stain, the most subtle test for recent degeneration of the nerve fibres, revealed only a few degenerated fibres in each bundle, according thus with the clinical observation of the absence of pallor of the disc. The ganglion cells of the retina seemed to exhibit no evidences of the degeneration that follows destruction of their axones. In many of the cells the nucleus had migrated to the periphery, but this condition is found in

every wasting disease. Sections stained by van Giesen's method showed that in the infiltrated portion of the nerve, in the posterior orbital portion, and back through the chiasm and tracts, the neuroglia tissue, which binds the fibres together into bundles, was greatly increased without any very marked increase in the connective-tissue septa, except in the tumor mass itself.

In comment, we may recall the fact that after blocking of the central artery of the retina, with degeneration of the ganglion cells and later of the nerve fibres, and in cases of permanent blindness after lesions of the nerve in the orbit, in the optic foramen, or within the cranium, the fibres of the optic nerve degenerate sufficiently to cause pallor of the disc, as a rule, not later than from three to six weeks. The present case proves, however, that with the nerve almost totally destroyed over a considerable longitudinal area total blindness may exist for four months without the disc becoming pale, or any but the slightest microscopic changes being found in the nerve near the ball.

The cause of the blindness in the left eye was apparent at the autopsy, but the cause of the defect in the infero-nasal portion of the field of the right eye was puzzling; hence the right nerve was examined with care and serial sections were made of several segments of it. Happily some of these sections were found to contain what was evidently the primary lesion, permitting a rational explanation of the clinical symptoms.

MICROSCOPIC EXAMINATION OF THE RIGHT OPTIC NERVE.

The ganglion cells in both lateral halves of the retina were alike, and the optic nerve near the ball exhibited no signs of degeneration either with the Weigert or the Marchi stain. But about 6mm. anterior to the chiasm a large vessel passed from the pial sheath into the upper portion of the nerve. This vessel, like other smaller ones in this portion of the sheath and nerve, had thickened walls and an increase of nuclei in and about the outer tunic, while the lumen was slightly narrowed. In this region much new connective tissue in delicate strands had developed within the bundles of the upper portion of the nerve, as was

shown by van Giesen's stain, and there was an excessive amount of neuroglia—in fine, a sclerosis of the upper portion of the nerve (Fig. 4). Weigert's method revealed the degeneration of a few fibres at this point. This sclerosis extended some distance forward and also back through the chiasm, but in the latter localities it was more diffuse and the increase in connective tissue was rather in the original septa than within the fibre bundles. The neuroglia was increased in both nerves, but the hyperplasia of connective tissue was more marked in this right nerve.

In advanced sclerosis of the optic nerve the medullated fibres are wanting, the neuroglia is increased, at least at first, the connective-tissue septa are hypertrophied, and the vessels have thickened walls and a narrow lumen. Formerly it was believed that the process consisted in a primary hyperplasia of the interstitial or supporting connective-tissue elements, which then secondarily by pressure destroyed the parenchymatous or nervous elements. Uhthoff sought in this way to explain the degeneration in tobacco-alcohol amblyopia.

Our ideas of sclerosis of the organs in general have changed.

The present view in regard to the optic nerve is that sclerosis usually means a primary breaking down of the nerve fibres from any cause, followed by a compensatory hyperplasia of neuroglia. Later the nutrient vessels, after the loss of the tissues which it was their chief function to nourish, become degenerated. Thus the blood supply of the connective-tissue septa becomes diminished and in consequence the septa first grow thicker and later shrink. This process has been studied by Nuel in experimental amblyopia from male fern and his observations have been confirmed by Birch-Hirschfeld.

On the other hand, we know that, as in other organs, changes in nutrient vessels here also may bring about both the parenchymatous degeneration and the interstitial sclerosis. In this way the condition of this right optic nerve is to be explained. With the general carcinomatous metastases, some vessels running to the pial sheath of the nerve had doubtless been interfered with, and the disturbance of circulation caused a

slight degeneration of the nerve fibres and a marked increase in connective tissue and neuroglia. No other explanation seems plausible.

As regards the effect of vascular disease on vision, we know that hardened vessels of the circle of Willis about the chiasm and hardened ophthalmic arteries which run beneath the optic nerves, may by pressure cause atrophy; but it would seem that we must now go further and recognize that disturbances in the pial vessels may by affecting the nutrition of the optic nerve lead to sclerosis of the nerve and defects in the field of vision. And in this way some of the obscure atrophies of the optic nerve may find an explanation.*

In conclusion I wish to express my obligations to Dr. James and to Dr. Hodenpyl, and particularly to Dr. van Giesen for his frequent and valuable suggestions while the pathological work was being carried out in the laboratory under his direction at the New York Infirmary for Women and Children.

EXPLANATION OF FIGURES ON PLATE.

Fig. 1.— The relative defect in the infero-nasal portion of the right field.

Fig. 2.— A reconstructed diagram of the chiasm and of the nerves as seen from above. The shaded area represents the infiltrated dura mater with many carcinomatous nodules, one involving the third nerve.

Fig. 3.— The left optic nerve in its thickest portion. The dural carcinoma has invaded the greater portion of the nerve. In this portion only the septa remain, with carcinoma cells and

*The paper by Siegrist (*Arch. f. Augenheilk*, xliv, Ergänzungsheft), in which he describes a great number of limited degenerations of the fibres of the optic nerve, will not be discussed here, because the writer is not convinced that many of the conditions which Siegrist describes and pictures are not artefacts. They have to the writer the appearance of changes brought about by too much manipulation of the optic nerves before hardening. To obtain reliable results in preparations of medullated fibres, it is advised, in the case of the Marchi stain at least, that the nerves be left untouched in the body for a number of hours after death and then removed with great care. Siegrist, replying to previous criticisms that his conditions were probably post-mortem ones, says that they cannot be post-mortem because most of the nerves were removed in life. This fact, however, the more favors the probability of the changes being artificial, due to traction, torsion, and compression of the fresh nerves.

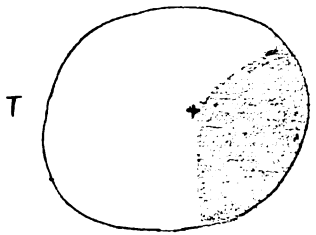

FIG. I.

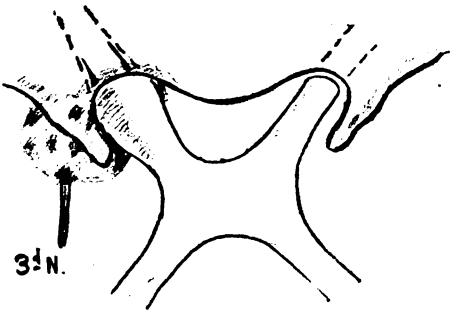

FIG. 2

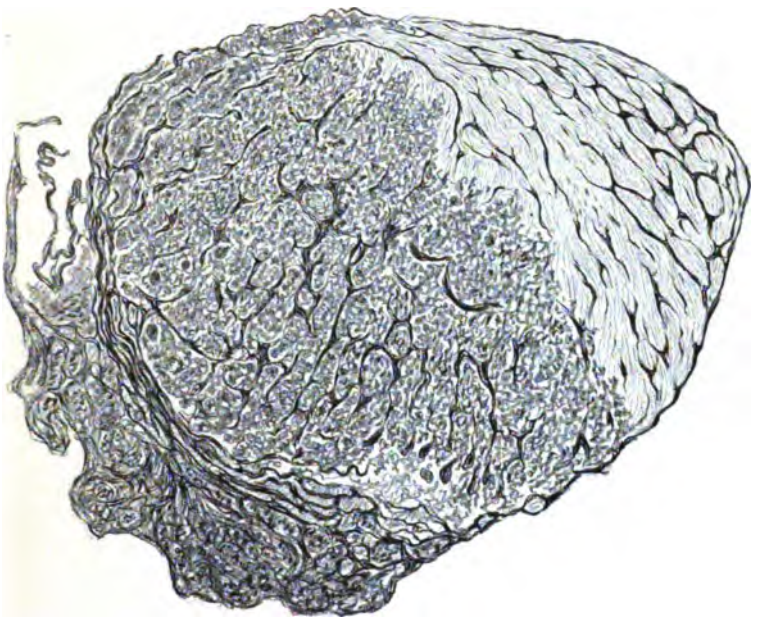

FIG. 3.

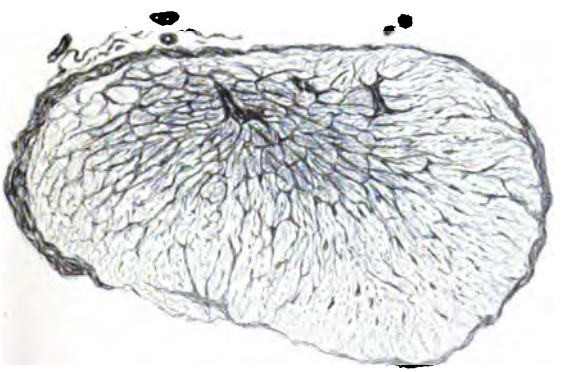

FIG. 4.

occasional balls of neuroglia tissue between them. In the remaining portion of the nerve many nerve fibres are degenerated. Van Giesen stain.

Fig. 4.— The right optic nerve 6 mm. anterior to the chiasm. Large vessels with infiltrated outer tunics are seen in the upper portion of the nerve, and about them new tracts of connective tissue have developed within the nerve fibre bundles, and the neuroglia is increased. Van Giesen stain.

A CASE OF DOUBLE METASTATIC CARCINOMA.

BY EDWIN E. JACK, M.D.,
BOSTON, MASS.

This patient was first seen by me in June, 1901, in a hurried consultation, and the diagnosis of probable metastatic carcinoma of the left eye was then made. In August she entered the Massachusetts Charitable Eye and Ear Infirmary, and in my absence Dr. H. H. Haskell took charge of her.

Family History. Father died ten years ago, aged 67, from cancer of the lip (pipe smoker), mother living and perfectly well, aged 67. One sister died at 35 with tumor of the breast. Three other sisters and two brothers are living and well. Patient has had ten children, six are living and four are dead,— three from summer complaint and one at birth (" came wrong "). The woman has always been well, with the exception of rheumatism four years ago. Nine years ago a hard lump the size of a walnut began to develop in the upper part of the left breast, growing slowly downward and inward with no pain and little impairment of health till recently. Two months before entrance there was a feeling of a foreign body in O. S., soon followed by impairment of vision, objects appearing yellow. This continued till two weeks before entrance, when she found she could not tell light from darkness in that eye. Soon after, the conjunctiva became injected and swollen, followed by a similar condition of the lids.

Examination. A fairly well developed and nourished woman. Heart, lungs, and urine negative. Left mammary gland shows

an infiltrating mass larger than a hen's egg situated in the upper third with depression at the center, small area of overlying skin red, nipple retracted. Typical picture of scirrhus. Left axillary glands enlarged. Eyes —V. O. D.—0.7—, apparently normal. V. O. S.—no light perception, lids bluish red and moderately swollen. Conjunctiva injected and slightly chemosed. Cornea slightly hazy. Anterior chamber shallow. Iris a little muddy. Pupil moderately dilated, a little irregular and deposits of exudation on border. Closely applied to the back of the lens and occupying almost all of the pupillary area is separated retina. T+. August 6th, left eye was enucleated by Dr. Haskell. Orbital tissue apparently not involved. Healing normal. (See pathological report).

On September 18th she again entered the hospital in my service, this time for trouble with her right eye. The vision in that eye had begun to fail. There was some dull pain and there were dazzling circles in the upper part of the field. V. O. D. 20—70. Eye normal to inspection. Pupil moderately dilated and reacts normally. Tn. Marked separation of the retina outer part. Separation starts near the macular region, its edge running nearly vertically up and down except at the upper and lower parts, where it encroaches more to the nasal side and is more prominent. Elsewhere the separation is more gradual. Surface of separation is smooth and without folds and pinkish in color, not transparent or movable. Patient was discharged from the hospital on September 28th.

I have followed this case since she left the hospital and can give the later history in a few words. During the winter she grew gradually weaker, taking to her bed in the fall and remaining there, becoming more and more emaciated and developing bed sores. She became unable to retain any solid food and very little liquid food, even vomiting the capsules given her for the pain in the right eye and head, which at times was very severe. Her mind began to wander and for two months or more she was in a half comatose state and at times could not be aroused at all. There also came on a hemiplegia of the right

side. About two months ago she began to revive, her mind became clearer, she gradually retained liquid and even some solid food, the bed sores began to heal, and she began to talk of getting well and expressed hopes of seeing again. The hemiplegia, too, began to improve. During all this time there was no apparent change in other organs; an examination by my friend Dr. A. K. Stone showed nothing abnormal. The eye became practically blind, retaining only perception of light; the anterior chamber became a little shallow, pupil a little enlarged, reacting to light. TR.

A brief résumé of this subject is all that is necessary at the present time, since the literature has been so recently and exhaustively presented by C. Devereux Marshall and Felix La Grange. Including our own case there have been twenty-nine cases of ocular metastatic carcinoma reported, twenty-three females and five males, one clinical history unrecorded. Of these, nine have been double and all but one in females. In the twenty-three females the primary tumor was in the breast in twenty-one, in the lung and pleura in one, and in the thyroid in one. In the five males, stomach in three, breast one, lung one. Of the double ones eight were in females, and one in a male; the primary tumor was in the breast in eight, including the male, and in the lung once.

PATHOLOGICAL REPORT ON DR. JACK'S CASE OF METASTATIC CARCINOMA OF THE CHOROID.

BY FREDERICK HERMAN VERHOEFF, A.M., M.D.,

BOSTON, MASS.

(*With three illustrations.*)

The globe was fixed in formalin, frozen, and sectioned in a horizontal plane passing just below the optic nerve. The diameters of the globe are as follows: Antero-posterior, 23 mm.; horizontal, 24 mm.; vertical, 22.5 mm.

Macroscopic Examination. Except for a slight amount of ciliary injection the globe externally appears normal. The cornea is fairly clear. The lens is shrunken, somewhat opaque, and is pushed forward, pressing the iris against the cornea. On its anterior capsule there are a number of fine pigment dots. The retina is separated, remaining attached at the ora serrata and disc only, and forming a plaited funnel behind the lens. The subretinal fluid, clear at first, is now, after 48 hours in formalin, represented by an opaque whitish coagulum, and a similar material occupies the space internal to the retina which normally should contain vitreous humor.

Attached to the ocular wall and covered over apparently with normal choroid, there are two flattened tumor nodules. One of these starts on the nasal side at the equator, 15 mm. from the disc, extends backward over the latter and then becomes continuous with the other. At one place it projects as far as 4 mm. into the vitreous chamber, but over the disc it is only 1.25 mm. thick, and just before it joins the other nodule it is scarcely thicker than normal choroid. The other nodule starts on the temporal side at an equal distance from the disc and at the level of the section attains a thickness of no more than 3 mm., but lower down it is 5 mm. thick. This nodule does not reach a higher level than the middle of the disc, but the nodule on the nasal side extends upward as far as the equator. Both nodules reach the equator below, where they become more firmly united. There is, however, apparently no unaffected choroid lying between the two nodules anywhere. Together they thus involve the greater part of the fundus.

The cut surface of the new growth is light gray in color, soft, and somewhat resembles a section of emphysematous lung tissue, having a highly cancellous appearance. Near the sclera there are a few small areas that appear more solid. Scattered over the surface there are a number of dark areas, evidently blood extravasations. At no point has the growth broken through the ocular wall nor apparently has it invaded the optic nerve.

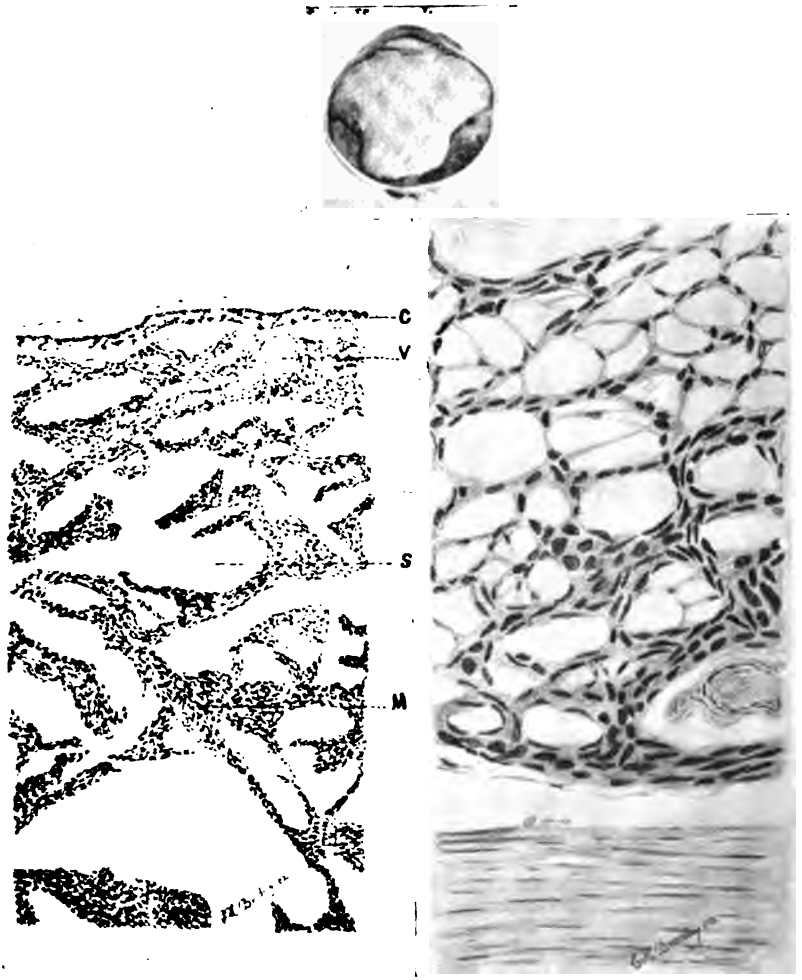

Metastatic Carcinoma of Choroid.

1. Photograph of sectioned eye showing extensive involvement of choroid.

2. Low power drawing of a section through a median portion of growth. *C*, capsule formed by the choroid; *V*, vessel; *M*, mass of tumor cells; *S*, large empty space.

3. High power drawing of a section made through the advancing margin of the growth.

Microscopic Examination. The cornea shows marked œdema, the lamellæ being widely separated, but otherwise it is normal. The subconjunctival tissue of the limbus and sclera also are œdematous. The iris is œdematous and shows beginning atrophy, as is evidenced by an increase in the density of its connective tissue. The ciliary body and ciliary processes are greatly atrophied and the former is highly œdematous. The filtration angle was evidently closed by the iris, but now appears free, owing to the traction exerted by the coagulum in the vitreous chamber during its shrinkage while in alcohol. The canal of Schlemm is widely open and contains blood.

The retina shows some proliferation of the connective cells around its blood vessels and other changes commonly seen in separated retinæ. The choroid in general is considerably thinned, and as the tumor is approached it becomes more and more congested and œdematous and shows infiltration with tumor cells. The optic nerve is highly œdematous and shows a distinct though slight cupping of the disc. If it were not for the œdema the cupping would evidently be much greater. The neuroglia fibres stain well and there are no evident signs of atrophy. The nerve structure is not infiltrated with tumor cells.

The tumor is composed for the most part of irregularly elongated cells, each containing a single oval nucleus. When lightly stained the nucleus appears vesicular and shows many fine granules, so many, in fact, that when deeply stained it appears almost solid. In sections stained in hematoxylin and eosin no nucleoli can be made out, but sections stained in Mallory's phosphotungstic acid hematoxylin show one or more nucleoli in every nucleus. The cells vary greatly in size, the smallest being seen at the advancing margins, while the largest cells, about 30 microns in length, are in the older portions of the growth. Where the cells are massed together to any extent they are distinctly spindle-shaped. Karyokinetic figures are numerous. But the most striking feature of the tumor is the arrangement of the cells. In the older portions the latter are

arranged in the form of large irregular masses connected together by narrow isthmuses, which form the walls of equally large communicating spaces. This accounts for the cancellous appearance of the tumor as seen by the naked eye. Some of the spaces contain masses of degenerated cells, others are filled with extravasated blood, but most of them are apparently empty. The manner in which the cancellous structure was brought about is rendered plain by the appearances seen at the advancing margin of the growth. Where the tumor is just beginning to invade the choroid, many of the tissue spaces, including the perichoroidal lymph space, are solidly packed with tumor cells, many others are widely dilated, often ruptured, and their walls lined by tumor cells, and most of the remaining spaces in the neighborhood are greatly dilated, even though they contain no cells. In many cases the appearance produced suggests that the dilatation occurred after the spaces had been filled with cells. In others it is evident that the tumor cells are growing along the walls of spaces already dilated, thus producing a glandular appearance. In these situations, however, the cells have no tendency to become columnar, but on the contrary are very much flattened. In places the tumor takes on a structure closely resembling that of adipose tissue, but specimens treated with Marchi's osmic acid fluid show that the spaces here contain no fat. It is evident that had the tumor cells in these situations continued to grow, and the spaces continued to dilate, the stroma of the choroid gradually disappearing, just the appearance present in the older parts of the tumor would have finally resulted. As a matter of fact, all the gradations of this process up to the complete disappearance of the stroma can be traced. It is interesting that Weigert's elastic tissue stain shows that the elastic fibres of the stroma are the last to disappear.

The tumor thus consists of choroidal tissue infiltrated with tumor cells. On one side the infiltration extends almost as far forward as the ciliary body. The inner layers of the choroid, including the membrane of Bruch, form a capsule for the tumor.

To the capsule are attached numbers of pigmented epithelial cells left by the retina, many of which show marked colloid degeneration, although colloid excrescences are not present on the choroid elsewhere. The blood vessels of the tumor are not numerous and most of them are seen just beneath and within the capsule. All of them have definite walls. Sections stained by van Gieson's method fail to show connective tissue between the individual tumor cells. The growth shows a marked tendency to degenerate and there are many comparatively large areas which are completely necrotic and infiltrated with pus cells and fibrin. There is very little pigment within the tumor, and that present evidently belonged formerly to the choroid. None of the pigment gives the reaction for iron. No so called cancer bodies can be found.

Opposite the thickest portion of the tumor the sclera is highly œdematous and densely infiltrated with pus cells, the episcleral tissue being more affected in this way than the inner layers of the sclera. Only the latter, however, have been invaded by the tumor cells.

Diagnosis. The marked infiltrating character of the intraocular growth, and the tendency of the latter to spread over the fundus and form flattened nodules rather than to grow as a single circumscribed tumor, indicate clearly enough that it is metastatic in origin. Morphologically the cells more closely resemble those of a spindle-cell sarcoma than they do those of a carcinoma, but the decision as to whether the intraocular growth is sarcomatous or carcinomatous in nature must rest entirely upon the character of the primary growth itself.

A HISTOLOGIC STUDY OF THE CRYSTALLINE LENSES OF A HANGED CRIMINAL.

BY CHARLES A. OLIVER, A.M., M.D.,

OF PHILADELPHIA, U. S. A.

Through the kindness of Dr. Jay C. Knipe of this city, one of my assistants and friends, I was put in possession of the two eyeballs of a recently hanged forty-year old Negro. A systematic study of the lenses was made, notes of the most minute change found in each section being taken.

The portions of the studies considered in this communication may be summarized as follows:*

The eyeballs failed to show the slightest anomaly. The lenses were normal for their age, and their weights were those that are given for the noncataractous types at the subject's period of life: They were not tumescent; they did not evidence any radially arranged thickenings or opacities; and none of the normal dark interspaces were filled with tissue-fluid. There were not any capsular folds.

In the capsules and subjacent lens-elements of the equatorial regions between the anterior and the posterior insertions of the zonule of Zinn — situated somewhat more posteriorly and to the right sides respectively, there were a number of linearly arranged zigzag-like breaks with extruding margins. These breaks were accompanied by a series of short, irregular, and feathery-like offshoots. The more central portions of both of the anterior and the posterior capsules, with the underlying lens-matter, exhibited shorter and more minute cracks and splits similar to those seen on freshly broken surfaces of newly formed ice: mere solutions in continuity.

* The writer is under deep obligations to Dr. Harold G. Goldberg, Pathologist and Curator to Wills' Hospital, Philadelphia, for his painstaking preparation of the specimens which have rendered these studies possible.



Fresh tears in the anterior fibres of the zonules, corresponding in position with the main equatorial breaks, and without any signs of inflammatory bands or other products, were manifest. The suspensory ligaments were torn in several situations, but not to sufficient degree to give rise to coarse dislocation of the lenses, as has been seen macroscopically in some previous instances.*

(Coarse appearance of one of the capsulo-lenticular breaks.)†

A few striated and plaque-like areas of deposit on the lenticular surface of the anterior capsule of the left lens, were, after most careful staining processes, shown to be in slight evidence, though there were not any coarse hyperplasias of the capsular epithelium: These hyaline excrescences, exhibiting the very beginning of localized capsular opacities, were, however, no more pronounced than the writer has seen in other clear lenses of the same age of life. There was not a single daughter cell of vesicular type parentage.

Abnormally placed epithelial cells in other situations were unsuccessfully searched for. Particularly those hyperplasias which would prove the existence of new cellular formations among the extremely delicate and most readily irritated so-called formative cells in the equatorial regions. Dislocated and fissioned nuclei, for which particular search was made along the borders of both the anterior and the posterior capsules, were not found. The connections between the whorls, the capsules, and the delicate and newly formed fibres did not exhibit the slightest trace of undue separation. The capsules were not thickened, and did not evidence any hyperplasias in the regions of the wounds. The breaks did not show the usual free spindle-cell infiltration; and there were not any pigment granules. In other words, with the exception of the fresh capsular and underlying lenticular breaks, there were not any changes that could be considered abnormal for the age of the subject.

* See records of such cases by Dyer and Green, in the Transactions of this Society.

† One of a series of sketches made for the writer by Miss E. C. Potter, one of the students at the Woman's Medical College of Pennsylvania.

There were some hemorrhages from a few minute traumatisms in the contiguous tissues of the ciliary body. No other extravasation of sanguineous fluid could be detected.

Aside from these changes the globular contents were intact.

It was not deemed necessary to study the chemistry of the nuclei of the lenses, as the lenses had not undergone shrinkage, and hence it was doubtful whether there could be any chemical change indicative of future senile sclerosis. As far as could be ascertained, there did not seem to be any hereditary predisposition to the formation of cataract.

Remarks. As to the lenses themselves; lenticular retrogression may be said to begin as early as the third period of fœtal life, when the youngest fibres crowd the older ones toward the lens centre, and expose them to changes which result in the formation of nucleus and cortex. Moreover, the superficial layers of lenses microscopically assume a faint, gloss-like appearance as early as the twentieth year, which proportionately increases as age advances, causing the nuclear areas, one or two decades later, to become apparent as deeply seated yellowish bodies. In the meanwhile, the stellate arrangements of the lens fibres become more pronounced, and the equatorial borders appear as pale golden-like rings, from which fine and superficially situated radii—possibly thickenings along the insertions of the zonule of Zinn—may be noticed.

The thin fibrinous plugs of regeneration situated at the sites of recent injuries to lenses could not be recognized. Degenerated lens fibres and epithelial nuclei with surrounding leucocytoses, forming the first signs of regenerative processes, could not be found. No signs of cicatricial tissue, although systematically searched for at the original points of the breakage areas, could be determined.*

In this case there was a traumatic solution of the continuity of the capsules, of so rapid a type, and one that was practically provoked at the time of general dissolution, that there was not

*This in spite of the fact that it was well understood that any hyperplasia of the capsular epithelium may remain primarily transparent for at least seventy-two hours

time to disturb the nutrition of the lens. There was no opportunity offered for chemical changes to take place in any stagnated intercellular fluids,—let alone the appearance of secondary cloudings of the lens fibres; there was not any chance given for the surrounding intraocular lymph streams to act upon the exposed lenticular fibres.

It was probable that the incomplete dislocation of the lenses was due to partial breakages—true tears—of circumscribed areas of the zonule of Zinn. The capsular cracks and the subjacent lenticular ruptures were dependent upon breaks in the weakest portions of the capsule and lens.*

The probable mechanism was that the greater specific gravity of the lenses and the capsules held in their liquid chambers by networks of delicate fibrillæ, which probably exercised relatively equal amounts of pressure upon the contained capsules and lenticular bodies, allowed a partial tearing away of these structures from their zonular attachments, the moment that the impact of the body against the rope took place—the tense elastic lens and capsular fibres suddenly spreading, and breaking at their most vulnerable and most greatly disturbed parts.

The causative factors for the production of the ciliary hemorrhages can be understood from the same standpoints.

The few indifferent hyperplasias of the epithelial cells were the probable results of age and use; true consecutive conditions that are so often seen in the so-called normal lenses of such periods of life.

The splits, the zonular ruptures, and the hemorrhages, most certainly took place during life; the other lens-changes were undoubtedly not of post-mortem type.

* This can be understood when it is considered that in a subject of the age of the individual the zonular tissues are somewhat stiffened and brittle, and the capsular and subcapsular tissues are relatively hardened and unyielding; such structures subjected to the sudden action of a gross direct force or an indirect violence as in this case, in which there was a quick concussion of the entire body, must necessarily give rise to the above noted conditions.

A PRELIMINARY STUDY OF THE OCULAR CHANGES PRODUCED BY THE INJECTION OF PURE CULTURES OF THE BACILLUS TYPHOSUS INTO THE VITREOUS CHAMBERS OF RABBITS AND GUINEA PIGS. (1, 2, 3, 4, 5, 6.)

BY CHARLES A. OLIVER, A.M., M.D.,

PHILADELPHIA, U. S. A.

The results herein noted constitute but a portion of those that have been obtained by the writer during a series of experiments which have continued through a period of nearly three years' time (7). In order to render the reading of the paper brief, logical, and intelligible, many details that are of value not only to the ophthalmologist, but also to the physiologist, the neurologist, and the general practitioner, have been

(1) Experimental work upon injections of chloride of sodium into the anterior chamber and into Tenon's space, is now being tried, in order to study the histological findings of any abortive effects that they may have upon the minor forms of bacteria invasion and inflammatory reaction.

(2) General studies, both clinical and histological, to show the effects of vitreal colonization cultures upon other animals of similar kind and equal bulk, are being prepared.

(3) A series of experiments in an endeavor to show the routes of intraocular lymph circulation are being made in a number of novel but strictly scientific ways: As early as is compatible for certainty of results the findings will be reported.

(4) Culture studies from the mesenteric glands, the spleen, the liver, the bile, the bone marrow, and particularly the lymph channels of the cerebro-spinal system and its peripheral sense organs, will be made upon the visual structures.

(5) Attempts at vitreous inoculation will be made upon animals which have been immunized as fully as possible, in order to study the earliest and most minute evidences of local effects, and thus to compare mere aseptic traumatic leucocytoses with pyogenic infections.

(6) Instillations and injections of weak solutions of definite strengths of formalin — which drug is said to be a most excellent agent for killing the bacilli without disturbing the diagnostic qualities of the agglutinating signs — will be made upon induced mild cases of typhoid fever in the rabbit, to determine whether the drug can be made of therapeutic value.

(7) Some of the primary work in these researches was done in the Pathological Laboratory of the Philadelphia Hospital; some in the Pathological Laboratories of the Department of Medicine of the University of Pennsylvania; and some at Wills' Hospital. Many of the later experiments were performed in the private laboratory of the writer and at the home of one of his former assistants and friends, Dr. Van Schoick, of Hightstown, New Jersey.

In all, fifty-four healthy animals were studied: some twenty privately, twenty-four at the University of Pennsylvania, and the remaining number at the Philadelphia Hospital: of these, forty-six were rabbits.

omitted from the text of the report, and relegated to foot notes.

The type (8) of the bacillus employed was proved by the noncoagulation of milk with the ordinary tests; the inability to give rise to sugar fermentation with lactose agar; the absence of indol with and without the use of the nitrites; and the production of alkaline reaction, or at least minimal degrees of acidity, when associated with litmus milk before the microorganism was used for injection purposes. To be doubly certain, the reactions to the blood serum of an immune animal, and the agglutination tests, were obtained (9).

Pure cultures of the bacillus were injected aseptically into the upper outer anterior portion of the vitreous chamber of the animals, through a puncture made in the scleral coat, back of the ciliary region, midway between the insertions of the external and the superior rectus muscles.

The germ was inserted directly into the eyeball—ectogenously, as it were — a true primary bacillar infection, without any intermediate steps; the microörganism was placed in a lymph organ, which is in direct, close, and independent communication with the intracranial fluids.

The clinical expressions were rapid in their appearance. As a part of the general symptoms, there were varying degrees of hyperpyrexia lasting twelve to sixteen days. The animals soon refused food and lost weight, although carefully cared for; a number of them—particularly the rabbits—developed the characteristic signs of a true myelitis; some succumbed to toxin asthenia.

The writer is under obligation to Dr. Simon Flexner, Napoleon B. Boston, Richard M. Pearce, and William F. Hendrickson for many suggestions throughout the studies. To Dr. I. L. Van Schoick and Clarence Van Epps he is grateful for assistance during the experiments. He is indebted to Dr. John T. Krall for most conscientious research work. He also desires to express his gratitude to Miss Mary C. Koonce, Miss Paula B. Himmelsbach, and Miss E. C. Potter for the execution of the many water-color sketches that have been rendered necessary in the proper pursuance of the work.

(8) For all of the primary experiments the human bacillus carefully obtained in pure cultures, and in some instances grown through several generations and proven to be still virile and able to reproduce the general disease, was used: rabbit cultures were employed in some of the later experiments.

(9) The cultures of these injection materials were kept *pari passu* with the series made from the intraocular fluids that had been aspirated at varying periods of time.

Locally, the iris became involved in from twenty to forty hours' time. The primary manifestations consisted in a thickening of the stroma, the appearance of numerous radially arranged vessels, and the development of a number of clump-like hemorrhages at the major and minor circles. Scattered throughout the posterior chamber, and in the pupillary area, free erythrocytes, mingled with fibrin and polymorphonuclear leucocytes, could be seen. The retinal pigment layer of the iris was but little disturbed. The blood vessels of the choiroid evidenced considerable injection, and in some situations, the tissues of the membrane were edematous. At this period, a few deeply seated choiroidal and probable retinal hemorrhages, with fibrillary bands and dust-like opacities in the vitreous humor, could be recognized (10). The cornea was infiltrated in its deeper layers, and new blood channels sprang from the limbal series, penetrating the membrane in all manner of fantastic ways, but more often ranging in straight radial lines. In this stage, Descemet's membrane was found to be intact.

In a more pronounced stage, or as a separate condition, the conjunctival membrane and the subconjunctival tissues, especially around the corneoscleral junction, became edematous and swollen, until, in many instances, the cornea was set in a deep and sharply circumscribed pit. The palpebral conjunctiva was but slightly affected, and the eyelids apparently did not participate actively in the process. The tissues around the point of inoculation were never more involved than were the other areas of inflammatory reaction. In many instances, the vitreous chamber was in great part occupied by broad yellowish masses which reached almost as far forward as the posterior capsule of the lens. A number of these cases showed a beginning decrease in intraocular tension. Early in this stage, the retina evidenced such extensive infiltration with leucocytes of polymorphonuclear type, that all appearance of retinal structures often was obliterated. Considerable extravasation of red blood cells into the tissues could be determined in some situations

(10) No qualitative blood studies have been established as yet.

(11). There were many accumulations of inflammatory exudates, serum, leucocytes, and erythrocytes.

Grosser forms exhibited an increase of all of the previous conditions with a number of superadded signs of coarse degenerative type. Portions of the corneal epithelium were denuded, the underlying lamellæ exhibiting minute areas of necrosis. The iris showed numerous thickenings, discolorations, and, rather infrequently, a few fine plastic adhesions. The lens (12) and the capsules were opaque and tumescent in places. The external structures were much swollen and catarrhal. There was a true lessening of intraocular tension.

The last stages exhibited numerous atrophic signs. In many of the first cases studied, the eyeball had shrunk into a small, irregular, and hardened stump, fixed in a mass of coarse fibrinous tissue. Over this crossed the remnants of a cicatrized and band-like conjunctiva, dragging the thinned and irregularly shaped lids against itself.

At varying periods during the many stages of these reactions, minute quantities of the infected vitreous humor were carefully aspirated and placed in varied culture media. Most of these withdrawals were made through the corresponding inner sides of the anterior segments of the eyeballs (13).

Cover-slip preparations of the withdrawn vitreous fluids showed motile typhoid bacilli with peritrichially arranged flagella; these bacteria exhibiting their peculiar properties of not being able to retain aniline dyes when treated by the Gram or Weigert methods (14).

---

(11) In some places the amount of exudate of serum and corpuscular elements was so marked that the retina was found to be separated from the choiroid, giving an appearance resembling ordinary blisters.

(12) The crystalline lenses have been set aside for special study, though the presence of the bacillus in these structures has been proved by pure growths obtained in culture colonization.

(13) The rule that was made was, that although different amounts of the material were injected, yet the most minute quantity possible was withdrawn.

(14) Attempts for agglutination processes within the ocular bulb (which is particularly rich in lymph glands), showing the effects of development, growth, and colonization modifications upon the already inflamed contiguous structures, will be tried — not for diagnostic purposes, but for actual therapeutic gain. For this purpose variable strengths of dilute serum will be employed. Widal's reaction studies will be applied to this particular phase of the work.

In many, if not in all, of the cases, the infected portions of the withdrawn vitreous humor were found to be translucent where filled with bacilli. Nearly all of the specimens of removed aqueous humor were more or less albuminous in character.

After preparation of the tissues in different ways, several hundred sections showing the combined effects of the germ and the traumatism upon all of the ocular tissues were obtained. These specimens were studied in every detail (15). The main characteristics were as follows: In sections of the early stage, portions of the ciliary bodies and adjacent uveal structures—probably the glandular tissues—were swollen, and in some instances were found to contain aggregations of typhoid bacilli. Penetrating and surrounding these tumescent parts were numerous dilated capillaries and newly formed blood vessels, from which the typhoid bacillus could be isolated in a number of instances. In direct connection with the lymph organs there were numbers of large free masses of the bacilli. Further back, the superficial layers of the retina were found to be richly infiltrated with polymorphonuclear cells and leucocytes. As early as the fourth day free hemorrhages were found irregularly distributed throughout the fibre layer and deeper portions of the retina; particularly in the circummacular regions just below the outer extension of the normally retained nerve sheaths of the animal (16). Rather deeply placed and more forwardly situated hemorrhagic extravasations from the two inner vascular layers of the choiroid were found in two or three of these cases.

There were not any coarse indications of pyogenic infection in this grade of sections.

In the grosser stages, many of the sections showed an acute endarteritis in association with the bacilli (17). Some of the specimens exhibited changes that indicated toxin action; others

(15) These studies have nothing whatever to do with the many postfebrile conditions which are so constantly quoted as being associated with and following typhoid fever, and which at best are merely concomitants and sequelæ of any form of continued hyperpyrexia. Such conditions cannot be considered as pathognomonic of the disease.

(16) Rabbits.

(17) This finding substantiates Keen's belief in microbic invasion as the cause of retinal hemorrhage.

(18) evidenced signs of well marked secondary infection. In the majority of the nonlethal cases, sanguineous extravasations with some erythrocytic aggregations and leucocytic masses were seen. At times, hyperplasia and even degenerative changes in the adjacent tissues were manifest. In some of the cases, both arteritis and periarteritis and phlebitis and periphlebitis could be seen near the larger lymph cavities and main lymph channels.

In the coarser groupings, there were all the marks of erosion of the walls of the larger vessels, with gross signs of pyogenic invasion throughout the now greatly disorganized tissues. In the equatorial sections especially, secondary phlebites with streptococcal and staphylococcal invasion of the clots and venous coats—true sepsis—could be determined. Many thrombi composed of fibrin-laden leucocytes, situated mostly in the lymphatic channels and main venous stems, could be seen, the containing walls in places being excessively attenuated. In the more marked cases there were localized abscesses. Pyogenic microörganisms were obtainable in excessive amounts in nearly all of the ocular tissues.

The last stages showed all manner of connective tissue growth. Well pronounced foci of cell death—leucocytic in part, —surrounded areas of necrotic tissue, which at times were almost indeterminable. The bacillus typhosus was now most difficult to find, only an occasional stray one being seen (19).

---

(18) Not many signs in this stage of the condition.

(19) True optic neuritis was often present in cases in which the eyeball was destroyed, but in most instances it was not of pronounced type, and it never involved the fellow organ. Several times a very low grade of the condition as secondary to uveitis was seen ophthalmoscopically. In this connection it must be remembered that the primary invasion of the germ was through the eye.

The presence of the germ in the meninges and the linings of the lymph channels of the brain was more than once noted during the cursory examinations vouchsafed these structures by the writer.

In the vast majority of cases, oculomotor changes in typhoid fever are dependent upon intracranial disturbance, but it is conceivable, nay probable, that a true peripheral neuritis from the actual presence of the bacillus typhosus and its frequent associates (particularly in the vascular and lymph channels of the muscular and other tissues of the orbit) can give rise to localized peripheral palsies and trophic changes: Of course, true extension of pyogenic inflammation along the nerve, vessel, and lymph channel tracts, may take place from contiguous areas of primary bacillar inflammation, and, as a result, no bacilli be found in the extraocular structures.

Bacteriological examination of the inflamed conjunctiva showed true secondary infection; pneumococci, staphylococci, and streptococci being present in the tissues, fluids, and secretions. Orbital involvement was not infrequent.

In one of the cases, which had progressed from a slow form of suppurative panophthalmitis to a phthisical globe, the bacillus typhosus was found nested in the extraocular orbital contents in several situations, substantiating Swanzy's belief concerning the same, and proving Panas' findings (20).

In a word, every portion of the organ is affected: the ocular expressions of the presence of the germ are protean and panophthalmic; the low grade, uveites, keratites, and retinites being principally primary (21); and the ophthalmites, gross conjunctivites, and orbital cellulites mainly secondary (22).

Remarks. Presupposing that the tissues or "soils", as they are called, were as near alike as possible, the symptoms varied with the dosage (23). The majority of the eyes perished with the amounts of injections at first used. Later, with the employment of lesser amounts, and the same technique, most of the eyeballs, though ofttimes functionless, were saved. In a

(20) Since the time that the main experiments were made, several cases studied by the writer showed that the other eye could be made to participate in the characteristic manner of typhoid inflammation by an injection of a slight amount of streptococcal matter into it, true typhoid germ colonization areas being found in the interior of the organ; thus proving in a measure, the earlier finding, that a few stray bacilli from endogenous infection may produce fine retinal and choiroidal hemorrhages in the constitutionally affected organ.

(21) Traumatic infection during the experimental procedures, in the minor cases at least, can be set aside to some extent by the presence of the germinating bacillar colonies in the vitreous humor, the absence of pyogenic germs, and the distinct localization of the leucocytoses around the typhoid organism aggregations.

(22) In these two varieties there is merely an induced ocular type of the general disease; the fever may be induced by the primary entrance of the bacillus typhosus into the structure of the eyeball, not only giving rise to local effects, but also to general disturbances This is particularly true in cases in which there is an already existent streptococcal invasion of the ocular bulb or surrounding lymph channels. It will thus be seen that it is possible to have a localized typhoid bacillus disease of the eye, without general involvement. Introduced directly into an eyeball either accidentally or intentionally, the microörganism may germinate locally only and excite leucocytosis and bactericidal action of the serum and the blood to a sufficient degree to produce a primary infectious condition before being destroyed or rendered innocuous. Particularly is this so in cases in which lymph and sanguineous circulations are impeded, as for example in glycosuria and glaucoma.

(23) The bacillus typhosus belongs to what is known as the facultative anerobic type: That is, it is a form of life which while growing the best with a plentiful supply of oxygen, is able to exist with but a very small amount and even none at all.

few, the symptoms subsided early, and the eyes were able to functionate (24).

Experimentation showed that the bulk of the early intra-ocular conditions arose from the processes set into action by the actual presence of the typhoid bacilli themselves, and that they were not dependent upon a minor aseptic traumatism (25). Vessel wall erosion with hemorrhagic extravasation, lymph gland infiltration, with lymph and blood stream blockage, and increased leucocytosis — with an abundance of the germ element — were soon followed by the formation of bacillar colonization areas, giving rise to a punctate haze with fibrillar opacities in the vitreous humor (26), succeeded in turn by inflammation of the bacilli-laden coats of the ocular vessels. Thrombi appeared and leucocytosis became profound (27).

The second stage, one of localized septicemia in which suppurative processes, not only from the typhoid germs themselves, but also, most probably, from ectogenous inoculation through rupture channels, ensued. Pyogenic microörganisms became prevalent and most virulent. At this period the bacillus typhosus began to disappear.

Later, the tissues degenerated: perforation through the ocular coverings, both from within and without, took place, the eyeball atrophied, and cicatrization bands of connective tissue, tying the organ into a motionless nodule, formed (28).

---

(24) The well known fact that typhoid fever bacilli can be carried within the human body for many years, makes it entirely within the province of certainty, that the germs may remain dormant or even isolatedly colonizing very slowly and indefinitely in successive generations within the eyeball for long periods of time. In such situations they may remain harmless until discharged into seral circulation by some traumatism or secondary degeneration of the surrounding tissue. For aught the writer knows, the bacillus may yet be present (seven months at present writing) in the shrunken eyeballs of two rabbits which are being kept alive for other purposes.

(25) Coarse pathological examination cannot explain the etiology of the condition: Careful histological and bacteriological research, as in these studies, must always be instituted. The best results are obtained in cases in which there has been but a moderate degree of reaction.

(26) Both Bull and Hansell describe this condition clinically.

(27) About this time general leucocytosis is most marked.

(28) In cases in which the animal had recovered from the gross local and general clinical signs of the primary vitreous infection, the second eye, when experimented upon, did not behave so badly as its fellow — this probably being due to the presence of germicidal serum in the vascular channels or possibly even in the serum of the tissues of the animal.

Should the ocular conditions be less pronounced, and the lymph channels to the brain remain pervious and active, intracranial and spinal infections from the passage of the germ and its associates will early ensue, giving rise to all manner of coarse clinical signs of central disease (29).

The minor degrees of endogenous type, in which there are slight and, at times, undisturbed and unsuspected retinal and uveal symptoms, as so frequently seen in the primary intestinal forms of the disease, are interesting, and prove what has been claimed ophthalmoscopically by a few competent clinicians (26), (30).

The external ocular signs, which have been not infrequently described as associated with the general disease, can all be placed under the same categories of cause and effect, and are mere expressions of the main conditions.

The position in regard to the pathology that may be taken is, that when the bacilli-laden serum gets into the interior of the eyeball, agglutinative processes followed by bacteriolytic changes, which remove the bacilli, take place. This destruction frees the toxins, which are either carried away or neutralized by the antitoxins. During these changes the invaded structures of the eyeball lose a few or many of their component parts, with the final result of either a useful organ, a functionless one, or a mere mass of degenerate tissue (31).

(29) This may be not an infrequent cause for lethal result. The effects of the bacillus upon the intracranial prolongations of the visual apparatus will be considered in another communication. Nissl's method will be employed in a part of this work.

(30) It is possible that some of the cases of suppurative ophthalmitis occurring during attacks of typhoid fever or even when individuals are exposed to infection from others, have arisen from the actual entrance of the bacterium into the eyeball itself through a break in the ocular tissues—a true ectogenous infection. It is probable, as hinted in another place in this communication, that the auto-infectious cases suffer the less; that is if the general condition is relatively good.

(31) It is highly probable that the soluble toxins of the streptococcus diminish the protective leucocytosis of the organ. If not early destroyed by the bactericidal power of the serum and blood, they will permit a rapid growth with increased virulence of the typhoid germs, producing not only suppurative death of the organ, but also pronounced involvement of the cerebro-spinal cavities. Fortunately, in most cases of general typhoid invasion, the streptococcal elements, unless locally introduced, are so infrequent in the ocular bulbs, that gross localized affections of the eyeball from the actual offensive presence of the typhoid germ are seldom seen.

It is probable that most of the reported instances of destructive eye changes in cases of typhoid fever have had previous or coetaneous breakages of the ocular walls, with

THE CONJUNCTIVAL FLAP AND THE CATARACT WOUND.

DR. F. M. WILSON AND DR. H. S. MILES, BRIDGEPORT, CONN.

For more than a hundred years cataract extraction has been a justifiable operation. For more than fifty years it has been a reasonably successful operation. For more than a quarter of a century it has been so very successful, in such a variety of ways, that small tables of statistics have, in great measure, lost their value. Where results are uniformly bad, small tables of successes have great meaning. Where results are uniformly good, and by different methods, it is very difficult to prove anything by small tables.

With this preliminary apology, I ask the indulgence of the Society, *first*, to the history of the conjunctival flap in cataract surgery, the facts for which were furnished me by my colleague, Dr. H. S. Miles; and, *second*, to the more or less uncertain conclusions from a small number of cases.

The making of some sort of a conjunctival flap is probably as old as the operation of cataract extraction. No doubt every surgeon who has made his incision at or near the sclero-corneal junction, has, at times, included more or less conjunctiva. Daviel's incision in the middle of the eighteenth century was wholly in the cornea, and from his time to the middle of the nineteenth century most incisions were corneal. Travers writes in his treatise, 1821, that in making the incision: "The sclerotic conjunctiva, the sclerotica, and especially the iris, should be untouched," believing, as did many other early writers, that the wound healed better if both surfaces were com-

the entrance of streptococcal material, the toxins of which have aided the bacilli to act much more decidedly, and thus give rise to expressions which could be recognized by coarse clinical study: conditions which perhaps have been simply superadded to existing signs of the disease, such as retinal and uveal hemorrhages.

In the intestinal type of the disease, the microörganism probably germinates in the lymphatic glands, and then enters the lymph and blood circulation. In these researches the serum was thrown directly into one of the nearest, one of the most direct, and one of the largest lymph streams passing into those within the intracranial structures, thus probably giving rise to a more rapid and a more pronounced symptomatology of the nervous system than could be found in any other variety of ectogenous infection.

posed of clear cornea. The modifications from 1750 to 1850 consisted chiefly in changing the size or situation of the corneal flap, and the discussions were upon these points and the instruments used.

In using Beer's knife, and other triangular knives, it was customary to make a complete corneal incision, although, of course, if the incision is peripheral, a small amount of conjunctiva will be included. Schweigger writes that a conjunctival flap may be formed with his large triangular knife if desired. Since the narrow Græfe knife was introduced more conjunctival flaps have been made. Jacobson, in 1863, had approached the border and made his incision "in the conjunctival limb."

Louis Stricker thinks one of the chief reasons why Græfe's knife has received greater recognition than Beer's is because with it it is easier to make a conjunctival flap.

In the published reports of series of extractions during the last fifty years, and the descriptions of the incisions, we find that some operators always avoid a conjunctival flap, the majority aim their incisions at the margin and at times, more by accident than intent, secure a small conjunctival flap; a few dip their knives back and finish through conjunctiva.

In a report of 1,420 cataract extractions by Prof. v. Rothmund, done between April, 1868, and April, 1883, it was stated that "only in the last six or seven years have efforts been made to form a conjunctival flap, this having been totally neglected before."

Most American operators make their sections just within the clear cornea. Dr. H. Knapp, in describing the incision in Norris and Oliver's System, says: "The section thus comprises . . . almost half the corneal circumference, lies from one end to the other in the same plane, the limbus, and comprehends at its tip a small piece of the conjunctiva. In 1887 he wrote, "If the eye is completely free from irritation I avoid a conjunctival flap as a useless complication, but when there is chronic conjunctivitis or dacryocystitis, I consider a conjunctival flap of advantage;" in 1889, "A conjunctival flap is somewhat

in the way during the operation, but I think it acts favorably on the closure of the wound; that it is a protection from secondary infection, I am fully convinced." In 1890 he had "shifted occasionally toward the old peripheric section with a conjunctival flap, and whenever I did so prolapses were more frequent;" he said in 1892, "A small conjunctival flap is neither necessary nor disadvantageous;" at Moscow in 1898, "a small conjunctival flap is made."

The surgeons at the New York Eye and Ear Infirmary mostly make no conjunctival flaps, or very small ones. Dr. Noyes did not like them because of the bleeding. Weeks and Gruening do not make them, although the latter in 1898 at the American Ophthalmological Society meeting admitted that sections with a conjunctival flap close more readily than sections in the clear cornea. Dr. Webster endeavors to get a small flap of conjunctiva, Drs. Emerson, Hepburn, and Lewis make their incisions at the limbus.

De Schweinitz directs that in making the incision the knife should be kept well upon the border of the cornea until the summit is reached, when it is turned a little forward and the flap completed, unless it is desired to make a conjunctival flap, when the direction remains a little upward.

Randolph never makes a conjunctival flap.

Casey Wood objects to bleeding, but makes a small flap when he wishes quick healing.

After the return to extraction without iridectomy, about 1885, and with it a larger number of prolapses and incarcerations, more attention was paid to the conjunctiva, and some European operators, especially Snellen, turned the knife under the conjunctiva and made a *large* flap.

Schweigger conceived the idea of leaving a conjunctival bridge and extracting the lens sidewise, but says, after describing the maneuver, "who can think of anything smart or stupid that nobody has thought of before! On consulting my books, I found that Desmarres had done the same thing in 1851." (Vacher reports some cases operated upon by this method in

1900.) Schweigger then tried to make a broad conjunctival flap, and suture it after the extraction, but was not satisfied with either procedure.

A few other men have sutured the cornea or cornea and conjunctiva, among them H. W. Williams, H. Snellen, Sr., Kalt, de Mendoza, Chisolm, C. H. Williams, and Vacher.

H. W. Williams, in 1869, wrote in the Archives of Ophthalmology, "at present I am disposed to extend the corneal flap at the apex a little way into the conjunctiva, so as to allow the placing of the suture in this membrane, where it is more easily inserted than through the tougher corneal tissue."

Most operators in their reports either simply mention "a conjunctival flap," or say, "a small conjunctival flap."

S. D. Risley dips his knife slightly backward to secure a conjunctival flap, and in a table of extractions sometimes notes a small flap and sometimes a large one.

Schweigger does not think there is any advantage in a conjunctival flap. But Snellen, Sr., has for a long time made it a rule in simple extractions to have a large conjunctival flap; his incision includes half the cornea, and turning the knife slightly backward cuts just into the sclera and up under the conjunctiva, securing a triangular flap six or seven mm. high.

In 1895-96, Dr. Miles made the following notes from personal observation:

Mr. Nettleship did "no more *so-called* simple extractions"; his section was aimed at the margin, but he preferred to err on the conjunctival side.

Mr. Tweedy had never done a simple extraction, his section was at the sclero-corneal junction.

Mr. M. Gunn did a preliminary iridectomy with a small conjunctival flap.

Mr. Lawford's section was entirely in the sclera.

McHardy almost always did a preliminary iridectomy.

Mr. Juler's section was small, and in the cornea. Mr. Tay also made a small section, sometimes with a conjunctival flap.

Mr. T. Collins tried to have "a good conjunctival section." He made a large iridectomy. "As soon as the knife has pene-

trated the fibrous tissue of the globe it should be made to cut a short conjunctival flap."

C. Higgens was the only surgeon seen in London who did simple extractions. He did not make a conjunctival flap.

Galezowski ended his incision in clear cornea; did simple extraction in 90% of cases.

Abadie usually did simple extraction, so also did Landolt.

Panas did simple extraction with small conjunctival flap.

Valude made a small section in the cornea.

A. Trousseau made his entire operation with Græfe knife only. Section one-half the cornea at the margin.

E. Meyers did not like conjunctival flaps because of the hemorrhage.

Hirschberg did simple extractions mostly, and preferred incision in cornea to conjunctiva.

Fuchs made his section two-fifths of cornea, near margin, with a very small conjunctival flap.

Schnabel also made a small flap. Snellen at Utrecht was the only operator observed at that time who made what could be called a *large conjunctival flap.*

De Wecker stated in 1882 that he did not have a single case of suppuration in 366 extractions, and he ascribed this good result largely to the exact closure of the wound by a well adapted conjunctival flap.

Schweigger later declared that "in peripheral sections the unavoidable conjunctival flap offers nothing but disadvantages. The assertion so often made, that it prevents an invasion of bacteria, is an illusion. So far as my experience goes there is no advantage in a conjunctival flap."

Prof. Haab does not insist on the formation of a conjunctival flap, but thinks that its presence ensures rapid closure of the incision.

Chas. Higgens says, "If the conjunctiva stretches over the knife, as is often the case, and is cut at a distance from the incision in the sclero-corneal junction, I have no objection to it."

In the discussion on cataract extraction in the ophthalmological section of the British Medical Association, 1896, Berry said he had come round to the view that simple extraction, if performed according to Prof. Snellen, possesses more important advantages than the cosmetic one. Cross agreed with Berry's view, and approved of Snellen's operation.

At the meeting of the ophthalmological section of the New York Academy of Music, held January 20, 1902, which was given up to the discussion of cataract operations, the incision was described as being at the junction of the opaque and transparent margins. The small conjunctival flap and the large flap, such as Snellen makes, were mentioned but not advocated.

The cases are seventy-four in number, occurring in a series of one hundred consecutive extractions. All cases, no matter what the complication, are included. The ages range from 20 to 92. The visual results are:

1 Total failure from chronic iridochoroiditis.
1 Pulled up pupil, w. good field.
4 5/200 — 10/200.
3 10/200 — 20/200.
18 20/200 — 20/70.
41 20/70 — 20/30.
32 20/30 or better.

There were twenty-four discissions. Four patients had one eye done with conjunctival flap, and the other without. In three of these cases the eyes with conjunctival flap did better, and in the fourth the results were about equal.

Fortunately the lips of most cataract wounds stay in place and heal kindly. Unfortunately, a few of them do not, producing unsatisfactory results, with which we are all familiar, and this is true, to a greater or less degree, of every form of incision which has yet been devised. I was led to try the larger conjunctival flap, chiefly through the influence of Snellen, and though he is inclined to disclaim originality, he has perhaps used it as extensively as anyone.

The conjunctival flap which I have each time tried to cut has approximately the shape of an equilateral triangle with sides measuring about 7 mm. At its base, where it joins the cornea, it should be as thin as possible, in order to keep away from the ciliary body. But it happened to me once, that in trying to come as near the surface as possible, before turning the knife to make the conjunctival flap, that the knife slipped through the tissue, where the base of the flap would have been, and left me without any conjunctival flap at all, and by a coincidence the wound was reopened by a large knuckle of iris in this case.

The most conclusive experiment as to the power of the larger conjunctival flap to hold the wound together is as follows:

If, during an operation, just before the expulsion of the lens, the speculum is taken out, the larger conjunctival flap is very apt to be manipulated into place by the upper lid, and if this does occur, it may almost be classed as an accident, for no ordinary pressure on the globe will dislodge it, and it is uniformly necessary to reopen this wound with the spatula before the lens can be delivered.

This is of course an annoyance at the time, but does clearly show the adhesive power of the large conjunctival flap, and if this is true when the eye is open, it must be still more difficult to dislodge it when the eye is closed, and the upper lid in contact with it and held in place by the dressing.

This helps to explain the following clinical fact, viz.: That in no one of the 74 cases did the conjunctival flap let go. Some of these flaps were too thick, some of them were too thin, some were too small, and some were too large, and some were ragged and irregular. But once smoothed into place none of them were dislodged, and all delayed healing was confined to the ends of the wound.

I tried to measure the adhesive power of the flap by experiments upon the cadaver within an hour or two after death, but the *dead* flap had so much less adhesive power than the *live* flap that the experiments were nearly valueless.

Incidentally, however, I did measure my own muscular sense of the maximum pressure which should be applied for the delivery of the lens, and found that I had unconsciously adopted a standard of about half an ounce.

We should naturally expect that anything which helped hold the wound together would help keep the iris inside the globe, and this is true to a certain extent.

So far as my own cases go the iris gets into the wound a little oftener with the conjunctival flap than without it, but does not get outside the wound. There were nine cases in which iris was caught in the wound. In one the cicatrix remained staphylomatous at its outer end, with the iris in the staphyloma, in one a small bit of iris showed at the angle of the wound, in three the iris was engaged enough to slightly displace the pupil, and in four oblique illumination was necessary to see that the iris was in the wound at all. There was no large knuckle of iris, either under the flap or outside, at the end of the wound.

There is, of course, more hemorrhage with a conjunctival flap than without one, and it is always wise to wait until the hemorrhage stops before introducing the cystitome. If an iridectomy is necessary the conjunctival flap is in the way, and great care is necessary to avoid cutting it with the scissors.

If soft cortex has to be manipulated out, its removal is more difficult with a piece of flabby conjunctiva hanging across the wound.

Whether a large conjunctival flap will ever be more than the justifiable experiment of a few operators is hard to say. It does lengthen and sometimes complicates the operation, but on the other hand it does exert a positive influence to prevent the reopening of the wound.

BIBLIOGRAPHY.

1. Travers, Benj., Synopsis of the Diseases of the Eye (1821), p. 350.
2. Risley, S. D., Jour. Amer. Med. Assn., Dec. 7, 1891.
3. Williams, H. W., Archives of Ophth., Vol. I, p. 98.
4. Williams, H. W., Diseases of the Eye, p. 282.

5. Williams, C. H., Boston Med. and Surg. Jour., April 16, 1896.
6. Meyer, E., Diseases of the Eye, p. 344.
7. Noyes, H., Text-book, p. 457.
8. Nettleship, Diseases of the Eye, p. 434.
9. Fuchs, Text-book of Ophth., p. 762.
10. De Schweinitz, Diseases of the Eye, p. 607.
11. Stricker, Louis, The Crystalline Lens System, p. 300.
12. May, Chas. H., Diseases of the Eye, p. 208.
13. Knapp, H., Archives of Ophth., Vol. 2, p. 169.
14. Knapp, H., Norris & Oliver's System, Vol. III, p. 798.
15. Knapp, H., Archives of Ophthalmology, 1887, p. 54.
16. Knapp, H., Ibid, 1889, p. 61.
17. Knapp, H., Ibid, 1890, p. 286.
18. Knapp, H., Jour. Amer. Med. Assn., Sept. 3, 1892.
19. Knapp, H., at Moscow, Archives Ophth., Vol. XXVII, p. 565.
20. V. Rothmund, Ibid, Vol. XIII, p. 324.
21. Schweigger, C., Ibid, Vol. XVI, p. 281.
22. Schweigger, C., Ibid, Vol. XVI, p. 452.
23. Schweigger, C., Ibid, Vol. XXVII, p. 265.
24. Schweigger, C., Ibid, Vol. XXVII, p. 565.
25. Haab, O., Ibid, Vol. XXII, p. 465.
26. Collins, E. Treacher, Internatl. Text-book of Surgery, p. 836.
27. Wecker, Annal d'ocul., Nov., 1882.
28. Hjort, Norsk Mag. f. Largerid, Christiana, 1891, p. 643.
29. Randolph, R. L., Trans. Amer. Ophth. Soc., Vol. 8, p. 133.
30. Gruening, E., Ibid, p. 401.
31. Jackson, Edw., Ibid, 1888, p. 62.
32. Jackson, Edw., Ibid, 1900, p. 145.
33. Webster, D., Ibid, 1891, p. 75.
34. Higgens, Chas., Trans. Ophth. Soc. of United Kingdom, Vol. IV, p. 117.
35. Swanzy, Ibid, Vol. XIII, p. 169.
36. Vacher, La Clin. Ophth., Nov., 1900.
37. Franke, E., Archives of Ophth., Vol. X, p. 122.
38. Kalt, E., Ibid, Vol. XXIII, p. 421.
39. Berry, Cross, Brit. Med. Jour., Sept., '96, p. 822.
40. Snellen, Sr. H., Trans. Eighth Internatl. Ophth. Congress, page 11.
41. Grut, H., Ibid, p. 30.

A SIMPLE USE OF THE CIRCLE OF DIFFUSION IN THE CORRECTION OF AMETROPIA.

BY DR. WILLIAM AND DR. ARCHIBALD G. THOMSON.

Dr. Wm. Thomson, in 1870, described in our Transactions a method for measuring the refraction by the circle of diffusion, aided by the use of an instrument consisting of four discs with small openings. It may, perhaps, not yet be forgotten that with one disc containing two openings which were three (3) mm. apart, one could be covered with a piece of ruby glass. The test was a small point of light, which in ametropia appeared double; further, that the one made red appeared in myopia on the same side with the hole covered with red glass, and in hypermetropia it was crossed. The circle of diffusion being converted into sharp definition by the effect of the small diaphragms or holes, the two lights were clearly seen; and with myopia, the red light was homonomous, and with hypermetropia, crossed. The reason being evidently that in hypermetropia the red image would fall on one side of the fovea, in myopia on the other, and being projected were seen on one or the other side of the white image.

The desire to complete this experience and to save others from the severe effort of its rediscovery induces us to submit to you this instrument which simplifies the coloring of a small portion of the light passing through the cornea by acting upon the entire half of it. It consists of a piece of ruby glass, flashed on one side, ground down to make its edge thin, cut into a hemicircle and mounted in an opaque disc, the size of a test glass, in a spherical opening of half a centimeter. Placed in a trial frame over one eye, the other being closed, the patient regards a test light half a centimeter in diameter at six meters distant, a plus six or four sphere being placed before the eye; a brief glance

enables the patient to hold the head so as to observe the image of diffusion and to see it either white or red or half red and half white. This would cause acquired myopia, and the red side of the light would be on the red side of the glass. The gradual or rapid correction of the plus glass by minus glasses reduces the acquired defect, removes the circle of diffusion, and makes it impossible for the light to be split as in emmetropia. Half of the cornea can be covered with the ruby glass, say the right half, and if then the light appears double or split the red part will in hypermetropia be crossed, or on the side opposite the red glass, while in myopia it will be on the same side.

ILLUSTRATION.

Having De Zeng's refractometer, it requires but a moment to gain a fair idea of the refraction; and for those who use this instrument it requires only that one of the extra eye pieces should have its high minus sphere removed and a hemicircle of red glass inserted. Of course the accommodation may conceal a part of the defect in hyperopia, but experience shows that by blurring the vision by over correction by a plus sphere and gradually reducing it, that a fair opinion of the refraction may be formed with ease and rapidity. Myopia is detected at once and its degree fairly determined. For those who do not have De Zeng's instrument the test glasses answer the purpose.

The circle of diffusion is a misnomer, and should be rather called image of diffusion, since the perfect circle depends upon a circular pupil and an absence of astigmatism. Iritic adhesions, irregular openings from iridectomies or iridotomies, and irregular astigmatism, must be considered in this method of diagnosis, as they alter the shape of the image and should not be confounded with corneal or lenticular astigmatism, which is recognized by the fact that the light cannot be made into a perfect disc, white or red, as the head is slightly moved, but that the

two lights remain in such position as to indicate the axis of the defect.

The manifest degree of a defect of astigmatism and its axis may be very quickly determined by finding the plus or minus sphere that fuses the red and white images in one direction, and the plus or minus spheres that make the light point single in the other meridians. Of course the test disc is to be moved by rotation in the trial frame when needed.

The only test object used is a single point of light, the acuity of vision not being in question until the refraction has been ascertained. This can often be done when from lesions of transparency the acuity is much diminished, as in corneal opacities or partial cataracts. Cases of mixed astigmatism reveal themselves unexpectedly and immediately.

The accommodation seems to be more relaxed in regarding only a light point as the test object; and when we consider the invariable opposition to mydriatics in private work, it is an advantage to feel that we may give often a provisional correction that may answer all purposes until increased later. For those who do not have the expensive apparatus of De Zeng, we propose to combine this last idea with the optometer of Græfe, a modified opera glass. The first effort to effect this is crude and imperfect, as you will see, but it has served to prove to us that celerity and comfort may be gained over the tiresome findings of the test case. The instrument consists of an ordinary Galilean telescope ranging in focus from plus 5 to minus 7 D, and magnifying about two or three times. For the higher defects test glasses from the trial case can be employed with it.

As it is often difficult for the patient at first to be able to split the light into red and white, we suggest the use of the double maddox prism of two degrees each, bases together over the clear portion of the hemicircle. This produces two white lights connected with a fine white line and a red light between them. The patient is then able to tell readily on which side of the line the red light appears. In using the single red and white glass it is often very difficult as you near the proper correction with sphere glasses to tell exactly when they are fused.

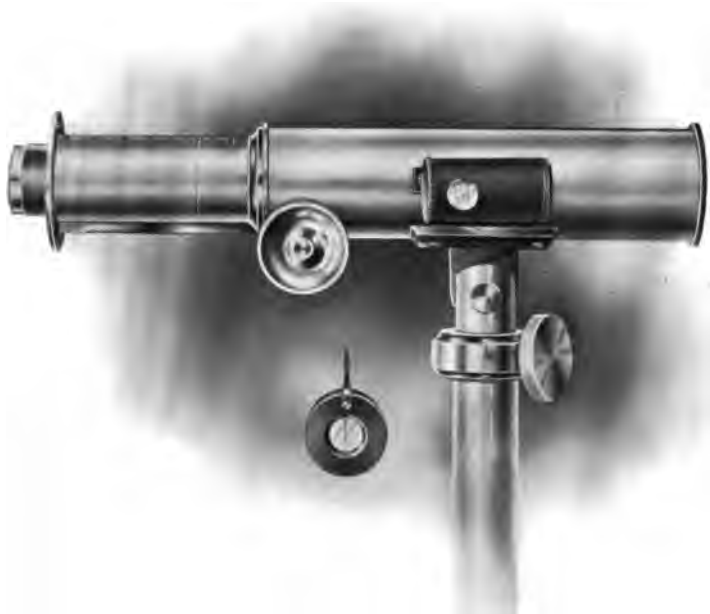

By the means of the use of the maddox prism the patient can easily place the red spot in the line and know when the correction is completed. This is merely added as a help to a diagnosis of the refraction, but not in any way to change the principle which is laid down in the previous part of the paper.

This mode of testing the refraction is very important, in fact is almost the only way to correct the refraction in the following classes of cases, such as opacities of the cornea due to injuries or interstitial keratitis, irregular astigmatism or opacities in the lens, in fact anything that interferes with the transparency of the media, and when other tests are impossible, as retinoscopy, ophthalmometer, direct method with the ophthalmoscope, and where the vision is so poor that the patient is unable to distinguish differences in test lines or letters.

Several cases we may briefly mention in which this method has been exceedingly satisfactory: Mrs. P., age 33, asthenopia, frequent nervous headaches on near use since age of 10, has been often examined and corrected, but never relieved. Right eye V.=1/4; round letters almost interlace laterally, monocular diplopia nearly, light point or image of diffusion long axis towards 165°, limit of reading ten minutes. Left eye V.= 6/5 emmetropic; orthophoria far and near. In reading or sewing closes right eye; apparently myopic astigmatism, but no good results by correcting glasses. By Javal no corneal astigmatism. With ophthalmoscope erect details seen better through upper half of the cornea than the lower with same glass. She was given mydriatic to use for some days, which was followed by intense and constant involuntary contractions of orbicularis. With accommodation paralyzed was able to get nearly full acuity of vision with: R—25s:—150 cyl. ax. 165°. The mydriatic was continued several days, when the contractions extended to her face and she lost her voice. Finding an hysterical element, further search revealed complete analgesia with muscular weakness on the entire right side, with occasional contractions of the muscles of that side. Her correction was determined by this

method and given about three months since, and she has not had a single headache, nor has she been limited in the near use of her eyes. She is gradually regaining the sensation and strength of the affected muscles under proper general treatment. Her diagnosis from all sources was astigmatism against the rule, and from the absence of corneal astigmatism this condition seemed caused by twisting of her lens.

Her case acquires a classical interest, as we find on looking up the subject that Thomas Young in 1801, our first great refractionist, found from observing the forms of the circle of diffusion, from a luminous point, in his own eye, that he was astigmatic, that the degree was 1.75 D against the rule, that it was not corneal, as he proved by his celebrated experiment of putting his eye under water and testing his refraction in this way. He ascribed his astigmatism to the obliquity of the crystalline lens, and remarked that the defect could be corrected with glasses placed obliquely in front of the eye.

Another case: J. P., a young woman of 33 years of age has been under our care for nearly ten years, having suffered almost all her life from interstitial keratitis. When we first saw her both corneæ were entirely opaque and presented the appearance of an acute attack of interstitial keratitis. Since then she has had several attacks, occurring first in one eye and then in the other. Since the past two years she has had no attack in the left eye. Under constant treatment her eye is now quiet and has cleared up considerably, although at present the cornea is covered with nebulæ, and one would apparently think there would be no useful vision obtained by the use of any correction.

We, however, by the use of astigmatic lines increased her vision considerably. Her vision at present is $\frac{8}{100}$ for far. The ophthalmometer, retinoscope, and the direct method with the ophthalmoscope proved useless, and only a fair estimate of the refraction could be gained by testing with astigmatic lines with an artificial far point. By this method of the circle of diffusion we were able in a very short time to get the proper correction, which consists of a plus 6 cylinder axis 105°. This gives for

far 6/30 partly vision, and she was able to read one meter type at 10″.

Case No. 3. We have in our records a lady 60 years of age who has had recurring attacks of rheumatic irititis since the age of 22, for which 20 years ago iridectomies were done on each eye. Her vision when consulted in '96 was 1/64 in the right eye and light perception in the left. There was the usual appearance of old irititic deposits of lymph on lens capsule, and several small opacities very faint in character in the cornea, the lens becoming cataractous, for which an extraction was performed first in the left eye, followed in about a year afterwards with the right eye. The cataract was not perfectly ripe, although the lens was hard enough to extract.

Following these operations discissions and iridotomies were done on each eye. She was subsequently refracted principally by the use of astigmatic lines. After a great deal of hard work and tedious examination she received 1/10 vision in each eye.

By this method of correction by the circle of diffusion her refraction was gotten very much clearer and more perfectly. It gave her 1/6 vision in one eye and 1/10 vision in the other. Right eye plus 14 sphere, left eye plus 14 sphere with 4 cylinder, axis 75°.

This case is simply cited to show the advantage of this method of correction where the vision is so bad that the placing of plus and minus glasses of quite high power did not apparently improve or hurt the vision seriously.

This small addition that we propose to so great a discovery we feel sure will in friendly hands give comfort and satisfaction to surgeon and patient by saving much time and effort.

TWO UNUSUAL COMPLICATIONS FOLLOWING CATARACT EXTRACTION. (1) DEATH AFTER CATARACT EXTRACTION FROM DIABETES; (2) DELIRIUM TREMENS FOLLOWING EXTRACTION OF CATARACT.

BY THOMAS R. POOLEY, M.D.,
NEW YORK CITY.

The occurrence of complications other than those which are directly due to the surgical procedure after cataract extraction has received very little consideration, although all the possible phases of reaction dependent upon the latter cause have been described *ad infinitum* and almost *ad nauseam*. It is this consideration which determined me to report the following two cases:

CASE I. The patient, a woman sixty years old, was operated upon for cataract of the right eye on December 4, 1901, in the New Amsterdam Eye and Ear Hospital, by my colleague, Dr. George A. Taylor. The following brief history is entered upon the hospital records:

Eight months ago she first noticed failing sight in her right eye, which gradually became worse, until she was only able to discern light from darkness. She has had diabetes for years, and previous to the operation was for a considerable time under the treatment of Dr. Warner, and at the time of her coming to the hospital her urine showed an abundance of sugar. Before the operation was undertaken she was put upon a strictly antidiabetic regimen and treatment under the care of her physician, Dr. Warner. At the time of her admission for operation there was a mature cataract of the right eye, mostly cortical in structure, with very little nuclear opacity. Perception of light and visual field excellent. The left eye showed an immature cataract of the same character, with vision reduced to counting fingers at

a few feet. She was exceedingly anxious to be operated upon, and gladly accepted any additional risk which might ensue from her diseased condition.

The operation, which was made under cocaine with the most thorough regard to asepsis, was completed without the slightest mishap; iridectomy being made, the latter procedure was determined upon beforehand as giving the best chances of success. After the operation the lips of the wound were in apposition; there was still some cortical matter left in the anterior chamber which was not interfered with. The eye was thoroughly flushed with sterilized solution of boracic acid and the patient put to bed.

December 5th. Slight injection of conjunctiva, no pain, no infection, no prolapse of the iris, shallow anterior chamber, and wound not closed.

December 6th. Conjunctiva less injected, the cornea clear, no pain, counts fingers readily, a little incoherent and drowsy. She was given ten grains of trional and fifteen grains of citrate of potassium.

December 7th. Drowsiness more marked. Diagnosis, diabetic coma, not profound. Carbonate of lithium and codeine were administered.

December 8th. Eye clear, still counts fingers; wound not yet closed, no injection, appetite poor, nausea, and remains in a comatose condition until aroused. She is now taking milk, two ounces every four hours, codeine and arsenate of sodium combined with carbonate of lithium; this she takes with her milk.

December 9th. No appetite; restless. Passes enormous quantities of urine. Sat up during the night and bumped her eye against the bed-post; hemorrhage into the anterior chamber took place; the wound is partly closed.

December 10th. Hemorrhage in the anterior chamber is absorbing; the diabetic condition is worse; the wound is entirely closed, but there is slight conjunctival injection. Continued treatment as above. Coma more pronounced. Patient apparently dying.

December 11th. Died at 1.30 A. M.

CASE II. J. L., aged sixty-five, admitted to the hospital March 4, 1902, with mature cataracts in both eyes. Cataracts were of the usual senile type with large nuclei; perception of light and the visual field good. The patient, however, was evidently a chronic drunkard. His wife, who accompanied him, gave the following history: For a number of years he drank to excess; suffers from alcoholic gastritis, but that he had had delirium tremens several times was carefully concealed and did not come to light until after the operation. Before his admission to the hospital, the patient had been seen by me at my office and was as thoroughly well prepared for the operation as was possible under the circumstances.

The operation was made under cocaine and to my surprise uninterrupted by any excessive show of nervousness on the part of the patient. Simple extraction was accomplished without the slightest accident and with the least possible trauma. After the extraction of the cataract the lips of the wound came into perfect apposition; there was no prolapse of the iris, the anterior chamber rapidly refilled, and the iris was restored to its normal position. Both eyes were bandaged and the patient was put to bed. Just before the operation the patient took one pint of whisky.

March 5th, 3 P. M. Bandage was removed; there was little injection of the eye. No prolapse of the iris. Perfectly round black pupil, but the patient had now become excessively nervous, although he had been allowed whisky at short intervals ever since the operation. At 10 P. M. he began to talk incoherently and later became slightly delirious. He was given liquid diet and whisky.

March 6th, 3.30 P. M. Bandage removed, counts fingers; no prolapse of iris; lips of wound in apposition. At 5 P. M. the patient was rapidly developing delirium tremens. He was given 30 grains of bromide of sodium, 10 grains of hydrate of chloral every three hours, which quieted him during the night.

March 7th. The patient is now excessively violent and it is almost impossible to keep his bandage on. It became necessary

to have a nurse by his bedside constantly. He was given 20 grains of bromide every two hours and a hypodermic injection of 1/50 of a grain of hyoscine at 8 P. M. At 10 P. M. 1/50 of a grain of hyoscine and one-half grain of morphine were given hypodermically and the bromides were stopped. He then slept from one o'clock to 8 A. M.

March 7th. Very delirious. Tympanites, suppression of urine, bowels have not moved since the operation, and he has now prolapse of the iris and the wound is open. He still, however, counts fingers readily during the moments of abatement of his delirium. At 10 P. M. he received one-fourth grain of morphine, 1/50 grain of hyoscine. Four ounces of milk with two ounces of whisky were given every hour and a half.

March 8th. Delirium still worse. Pulse weak. Patient is only restrained now by a man nurse who sits at his bedside day and night. The bowels move freely; there is prolapse of the iris, with infiltration of the wound; the temperature is normal, pulse 92, respiration 24. Strychnine 1/60 of a grain every four hours, two ounces of milk and whisky every two hours, hyoscine 1/100 of a grain every four hours. Infiltration of the wound is worse.

March 9th and 10th. Delirium continued with hardly any intervals of relief, and on the 10th there was more infiltration of the wound and the anterior chamber was filled with pus. At this time he was given apomorphine with better effect in relieving the delirium.

March 11th. The wound was gaping, there was prolapse of the iris, and anterior chamber was filled with pus. The condition now, so far as the eye was concerned, seeming hopeless, the patient was sent to his home for treatment by his family physician.

These two cases are extremely suggestive and interesting from several points of view. In the first place, the occurrences which immediately followed the operations illustrate what I think, no doubt, has occurred in the experience of all, that any pre-existing disease or abnormal condition, although it may

have been improved or held in abeyance by treatment, is very likely to be aggravated by any surgical procedure.

In the first case, although the patient undoubtedly suffered from diabetes at the time of the operation, still her condition was not such as to warrant us in the belief that the operation was unjustifiable, or would have resulted, as it did, in a fatal issue.

As has been remarked in the history of the case, the patient was very carefully prepared by the treatment of an excellent physician before the ordeal of the operation, and notwithstanding the occurrence of diabetic coma made its appearance within less than forty-eight hours after the operation, and rapidly progressed to a fatal termination.

This is the first occurrence of the kind which has ever come under my notice, although I have not hesitated to operate upon diabetic cataracts, always observing, however, the precaution to have the patient placed under proper treatment preliminary to operation, and frequent examinations of the urine made.

One case in particular, which I operated upon at intervals of about two years, was that of a man of seventy-two years, who had been suffering for a number of years with diabetes, and I obtained a very satisfactory result in both eyes, healing occurring without any complication whatever, and visual acuity also being satisfactory. In this case the patient was immediately put upon the usual anti-diabetic regimen for a number of weeks before the operation and during the healing process, so that, as the outcome of my own experience, I shall still continue to operate upon these subjects.

In the second case it seems to me that the occurrence of a severe attack of delirium tremens, such as supervened after the operation, is even more dangerous to the integrity of the eye than in the preceding one, because of the almost impossible solution of the problem how to keep the patient quiet and prevent injury to the eye, which is almost sure to ensue. Although the patient and his wife freely admitted that he drank to excess for many years, and the nervous tremor which he showed at the time of his consultation with me were sufficient evidences of

chronic alcoholism, still, with that fatuity so often shown by patients in their dealings with us, it was carefully concealed from me that he had had delirium tremens, which, had I known, might have led me to reject the operation, or, at all events, to have made more careful preparation beforehand to secure the patient from injuring himself. As it was, I had only the usual resources of the hospital to depend upon. If I were to operate again upon such a case I should feel inclined to restrain the patient by the use of straps, a straight-jacket, or even a plaster-of-paris jacket, until the wound had healed.

It is somewhat remarkable that there should have been so little reaction and such favorable closure of the wound at first, and that it was not until the violent efforts of the patient had resulted in a traumatic opening of it that subsequent infection gave rise to the loss of the eye. It seems to me, too, in this connection, that had I taken the precaution to make an iridectomy this might possibly have been averted.

Some recent German writer, whose name I do not now recall, remarks that the only way to treat such a case after operation is to let him take his whisky bottle to bed with him. This in effect I really did, for it will be observed that virtually he was given all the whisky he desired. That this, however, and the heroic treatment to which he was subjected after consultation with my colleagues had very little effect upon the course of the delirium, is obvious enough, and there is only one drug, viz., apomorphine, which seemed to have a decided effect in relieving the delirium.

DISCUSSION.

Dr. Herman Knapp. — I recall one case, that of a young woman twenty years of age, where the extraction was without accident, and in two weeks she was announced to be ready to be taken home, and her husband, who lived in a neighboring place, prepared to take her home the next day. She died that night without any premonition. Diabetic coma developed without any previous symptoms having existed. She was a well nourished young woman without any bad habits.

Last winter I had another case where a woman died after cataract extraction without any apparent cause. She was a woman of about sixty, of the better class of society, with no bad habits, well nourished and with healthy eyes. The first extraction healed without any difficulty whatever, and at the end of the second week she wanted the other eye operated upon and I had no objection to make. Her daughter came to me and said she thought it might be dangerous to do it, but the old lady asked me and I said I did not think it would be dangerous at all. I saw no reason why I should not operate. I did a simple extraction; there was no trace of inflammation. About the sixth or seventh day she had an attack of weakness in the evening, between four and five o'clock, and I was in the hospital myself and saw her. She was soon all right again, but her daughter asked that their family physician be called to see her. I told her that I hardly thought it necessary, as there seemed to be no reason whatever for it. The next morning I was informed that the woman had died that night and from apparently no cause whatever. She simply complained of feeling weak and died without a struggle. On inquiry I was told that her mother and also a sister had died in the same way. Whether the operation could have had anything to do with her death I do not know, but it is certainly a strange coincidence. I have also seen another old lady die after cataract extraction. She was disappointed that she could not see better and died of old age.

Dr. S. D. Risley. — It occurs to me that it is surprising we do not oftener have serious and quite accidental complications during the convalescence of our aged cataract patients. Except a few cases of surgical delirium I can recall but three instances of serious intercurrent complications in my own experience: one of hemiplegia on eighth day after extraction of cataract; one of intercurrent pneumonia which proved fatal, and one of acute articular rheumatism which came on within twenty-four hours after extraction.

Dr. G. C. Harlan. — I had a case very similar to that of Dr. Knapp's. Several weeks after the extraction the patient died without any definite cause at all; just gradually failed.

Dr. O. F. Wadsworth. — I had one case of this kind, an old lady, where the operation went on smoothly, but within twenty-four hours she developed a low muttering delirium, fol-

lowed by coma, and she died within five days. The wound had closed properly and the eye looked perfectly well.

I have had also a case of a man operated upon for cataract in a hospital where he had been for some time for other surgical work, and of whom I took charge at the request of the other surgeon, and the night after the operation he suffered an epileptic attack, from which it was feared he would die. The operation had been perfectly smooth.

TWO CASES OF DETACHMENT OF THE RETINA, TRAUMATIC IN ORIGIN, TREATED BY DRAINAGE INCISION.

BY W. K. ROGERS, M.D.,

COLUMBUS, OHIO.

CASE I, L. G., an Italian laborer, age 48, came under observation at my dispensary clinic Oct. 15, 1900, complaining of serious impairment of V., O. D., of about a month's duration. The history obtained through an interpreter familiar with the patient's patois was not very satisfactory, but it was learned that a short time before the defect was noticed a contusion had occurred to the eye from a chip of stone. V.= fingers at .20m.; ophthalmoscope showed a gray elevation in the lower outer quadrant of the fundus which, however, did not present the wavy folds usually found in detachment of the retina. There was some uncertainty as to the diagnosis until the case had been watched for several weeks, and the prominence had gravitated somewhat to the bottom with the appearance of characteristic wavy folds. Absolute rest in bed was not possible for various reasons, but it was approximated as nearly as practicable, and iodides, mercury, pilocarpine, and laxatives were administered for ten or twelve weeks without appreciable effect. The case was lost sight of for several months but came under observation again last February — about sixteen months after it was first seen. The detachment had increased and was now more charac-

teristic than before; V.= l.p.; no fibrillation could be made out in the vitreous. At this time the patient consented to be placed under hospital care for operative interference. He proved so intractable when operation was undertaken that aspiration was not attempted, and an incision only was made beneath the tendon of the inferior rectus, evacuating considerable serum into the subconjunctival space. Eserine and a bandage were used, but during the night the patient got out of bed, and subsequently continued very unmanageable. There was considerable reaction and convalescence occupied about six weeks, at the end of which time the vitreous was filled with an organized opacity and V.= defect. l.p.

CASE II, W. H. C., a car builder, age 47, was sent to me Sept. 30, 1901, by the Relief Department of the Pennsylvania Railroad Company, giving a history of a contusion three months before. Vision did not become impaired for two or three weeks, but the impairment gradually increased until at the time of my examination it was limited to counting fingers at .50m. in the upper field. Ophthalmoscopic examination showed a general elevation of the retina with dull purplish reflex, and a few prominent bands leading from the region of the macula. In the superior temporal region of the fundus there was quite a little area of complete detachment. It was not until two weeks later that the patient entered St. Francis Hospital and treatment could be rigorously enforced. Absolute rest on the back with iodides, salines, and pilocarpine were kept up for six weeks, during the early part of which period atropine and a light bandage were employed. At the end of this time vision had improved to the extent of counting fingers at 4m., but extensive detachment still existed which had gradually shifted to the lower temporal portion of the fundus. Six weeks later, however, the man meanwhile keeping up internal treatment and maintaining a state of comparative quiet at home, though not continuously in bed, vision had again diminished to fingers at .50m., and four weeks later he was sent back to the hospital to resume absolute rest in bed. At this time the detachment had formed a pouch at the

lower nasal as well as temporal sections of the fundus, with a sulcus between. Three weeks later no improvement had taken place, and after stating to the patient my doubts as to the outcome of the proceeding, the area beneath the detachment was aspirated at the same time the former case underwent operation, something over a c.c. of serum being removed under ophthalmoscopic observation in which I had the assistance of my associate, Dr. Clark. As there was still considerable elevation of the retina and no further fluid could be obtained, a section was made beneath the inferior rectus which evacuated more serum under the conjunctiva. A pressure bandage was applied and eserine used for a week. Two weeks after the operation — March 3d last — V.=6/40. There were one or two small vitreous opacities, and in the lower nasal quadrant of the fundus (the side opposite most of the operative procedures) there was a considerable area having all the appearance of extensive rupture of the choroid, with adjacent wavy folds suggesting the condition described by Dr. de Schweinitz in a case reported June, 1900. The lower temporal portion of the retina was considerably elevated but nowhere could actual detachment be made out. About six weeks later, the condition still being maintained, with V.= 6/15 under correction, the case was shown at the Columbus Academy of Medicine. I wish very much that my report might stop here. Unfortunately there is more. On May 26th last, V.=6/100, although the man had not resumed work; June 2d, V.=l.p., and the detachment was as marked as ever. Since then several saline injections have been made with, thus far, negative results.

These two cases are presented to the Society not only to add them to the literature at present available on the subject, which is still meagre in the number of surgical cases reported, but because they seemed to present some features of interest, and also, and especially, in the hope that they may draw from some of the members present an expression of their larger experience with this condition, upon which a good deal of diversity of opinion seems to exist, which may develop a clearer idea as to when

conservative treatment, and under what circumstances more radical measures should be adopted. The most satisfactory summary of this kind that I have been able to find is contained in the paper of Dr. Bull, presented to this Society in 1894.

DeWecker makes a general claim of very gratifying results from saline (or normal salt and 3 per cent. gelatine) injections into Tenon's capsule, but gives no statistics that I have seen. In Gabler's report of 120 cases, most of which were due to high myopia, scleral puncture and iridectomy were accredited with the best results. I have not had the temerity to essay the method of Deutschmann, but his claim of 25 per cent. of cures in all classes of cases, and upwards of 30 per cent. of betterment, in addition, is an enviable record. Whether this would occur in other hands may be doubted; the technique would seem likely to result in the frequent production of intraocular hemorrhage, and at all events I find no reports of other experiences with this method, which may be taken to have been founded on that of Von Graefe, which I think is largely followed by Dr. Knapp and others.

In spite of much that is said by eminent surgeons in condemnation of operative interference in this class of cases one may note a tendency to resort to it, and it would seem that something more like a consensus of opinion than we now have on the subject might be attainable. Good results have been obtained by it, and by other plans. It is hardly reasonable to suppose that all classes of cases will lend themselves equally well to all methods of treatment, and if we could formulate more clearly than has been done what cases are best treated surgically and what medically it would be a considerable step in the direction of judging what surgical treatment and what medical treatment to adopt in a given case. It would be natural to infer that traumatic cases would be best adapted to surgical measures, a the cause may be supposed to have ceased after the immediat results of the injury have subsided, while in cases of pathologica origin the cause may continue after interference has been under taken. It was, to some extent, this inference that led to th

adoption of these measures in the two cases reported. The primary success in one of the cases justifies the inference that the delay in resorting to them may have been responsible for the ultimate failure, as time had been allowed for permanent changes to occur which would prevent readhesion of the retina. But without some general indications for guidance one is naturally tempted to postpone surgical precedures until rest, alteratives, etc., have been tried; meanwhile the day of grace is sinned away. The reports of most observers do not indicate any discrimination on account of etiology, nor do the results appear to be affected thereby to so great an extent as one might expect. This, however, may be partly due to neglect to classify cases definitely and adequately. The complete failure in the first case may as readily be attributed to the behavior of the patient as to anything else, although I am inclined to think it was due to extensive hemorrhage at the time of the operation — a contingency which I cannot well see how to be assured of always avoiding.

A METHYL ALCOHOL DEBAUCH AND ITS RESULTS.

H. W. RING, M.D.,
NEW HAVEN, CONN.

In relating the history of the following cases of methyl alcohol poisoning only one of the patients has been under my personal observation, and my sources of information have been varied and would have been more laborious but for the courtesy of Dr. C. J. Bartlett, pathologist of the New Haven Hospital and Yale Medical School, who, as medical examiner of the city of New Haven, was brought into close relationship with the victims and the events.

A certain amount of information leading up to the main event is valuable, though somewhat indefinite and nonscientific, and this has been obtained from my patient and his attending physician.

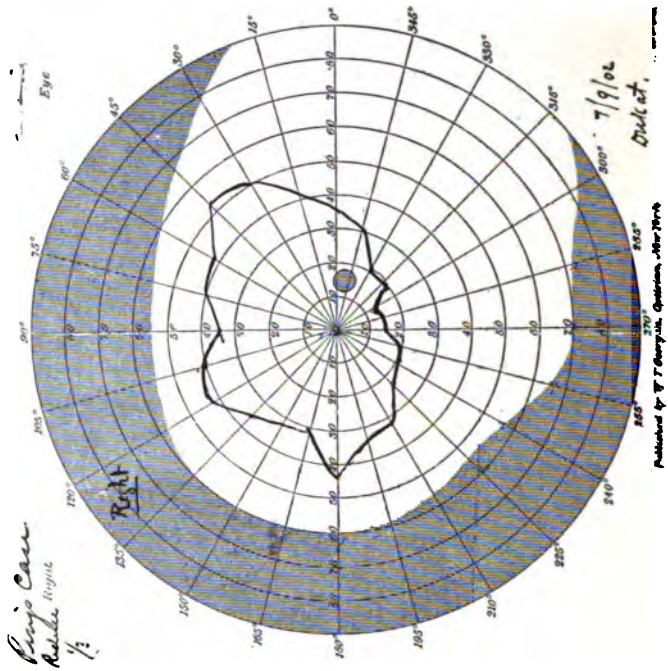
Right
7/9/02
Duke at

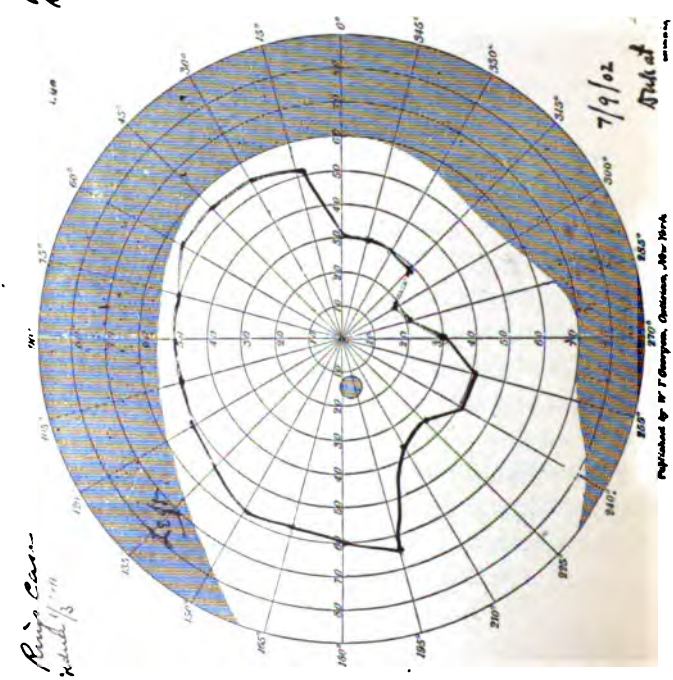
Left
7/9/02
Duke at

Anton Dukat is a native of Poland, aged 41; dairyman, employed on a large farm four miles outside New Haven. He is fairly intelligent and talks English well enough to be easily understood. Dr. Henry H. Smith has attended him at intervals during the past five or six years, when he or his wife and children have needed treatment, and from Dr. Smith I learn that it had been the habit of Dukat and his wife to visit a cousin in New Haven occasionally on Sundays; and it became rather common observation among his fellow workmen that whenever such visits occurred he was not likely to be seen at work the following day, and Dukat admits that there was usually a drink made up of sweetened water and alcohol and he was likely to have headache, nausea, dizziness, etc., the following day.

In December, 1900, the wife of this same cousin, Mrs. J. S. Pole, aged 43, made a mixture containing about one-half pint of black coffee water and sugar and same quantity of wood alcohol. She drank perhaps one-fourth of this before going to bed and during the night had nausea and vomiting. She took more the following forenoon, having consumed probably half the whole quantity.

Becoming worse Dr. N. R. Hotchkiss was called and found her comatose, fairly good pulse, sighing respiration, widely dilated pupils, and was informed that before his arrival she complained of loss of vision.

He suspected uræmia and returned to his office for a catheter, being gone about fifteen minutes. Upon his return she was dead. He drew off some urine and, according to his recollection, albumen was found. The medical examiner, Dr. Bartlett, was called; alcohol poisoning was not suspected, and no autopsy made, but the cause of death was considered to be uræmia.

About a month later, another Polish woman, Mrs. Z., was employed for a day by this same J. S. whose wife died as just related by me. She made a mixture of sweetened water and wood alcohol in equal quantities. During the forenoon she drank about four two-ounce whisky glasses full. In the afternoon there was dizziness, nausea, and vomiting, and at 6 P. M.

vision was so bad that she could not see a lighted lamp in the room. At 9 A. M. the next day sight began to return, and in an hour or two was thought to be as good as usual, and she went about her work.

For the history of this case I have depended entirely on my patient, Dukat, as the physician who was summoned could not recall details of case, but she was given vigorous and successful treatment according to my informant. (Dr. Smith saw her.)

On Sunday, February 3, 1901, there were assembled at the house of this same J. S., whose wife had died and whose employee for the day was so ill, five adults and several children, all Poles. The adults were Vincent S. and wife, Anton Dukat and wife, and the host, Jos. S.

The children ate the usual food provided for the day and were not ill. They drank water or whatever liquid was usually supplied for them. They did not share in the liquid provided for the older people.

J. S. was employed at Sargent's large general hardware factory and from this place he took away, the preceding day, a pint bottle full of alcohol which he supposed was "good alcohol." None of the alcohol so carried home could be found when search was made Feb. 5th, but the bottle was found and it was empty. From the description given by him and the location described the alcohol was traced to a package of wood alcohol. He made a three-pint mixture of water, wood alcohol, coffee, and homemade wild cherry wine. From Dr. Bartlett's investigations he concludes that in each pint there was about three-fourths of a cupful of coffee and one-half a cupful of cherry wine, and that the concoction contained about one-third wood alcohol. It was well sweetened.

Mrs. Vincent S., who was four months pregnant, drank at two different times about one-half a glass of this mixture and ate very little food. She was nauseated and vomited, but had no visual disturbances and the following day was able to be about as usual.

Vincent S. drank three to four glasses and ate a little food.

He had no nausea or vomiting, went home and overslept the next morning till seven o'clock and was dizzy but went to work.

Mrs. Anton Dukat ate a small quantity of food at noon, and between that time and 7 P. M. probably drank about four glasses nearly filled with the mixture. She and her husband went to their home during the evening. She slept all night but the following forenoon was dizzy, nauseated and vomited. She was moving about the house as late as 1.30 P. M., as her husband was awakened by her then, but she became worse from that time and was first seen by a physician at 5 P. M., Dr. G. H. Joslin of Hamden. His observations are as follows, viz.: Patient comatose, pupils widely dilated and no reaction, eyes fixed and staring, no tremor, could not find second sound of heart, pulse 110, rapid and wiry, capillary circulation sluggish, body cold, clammy, and perspiring freely, respiration deep, sighing, and slow, 8 or 10 to the minute, coarse bronchial râles, reflexes abolished. No effect from two ounces of spirits frumenti and nitro glycerine, no muscular contraction, jaws set, muscles upper extremity rigid. Urine had been passed several times according to her husband. One slight convulsion previous to death, which occurred at 6.30 P. M.

Dr. Bartlett made an autopsy which showed nothing unusual except widely dilated pupils and marked congestion of all the organs with dark, liquid blood, as in narcotic poisoning.

Jos. S., who made the mixture, ate some food and drank six to eight glasses full while his friends were at his house and another small glass the next morning. He was able to go to work till 3 P. M., when he returned home because of dizziness. He went to bed at 4.30 and slept till 4.30 next morning. Was still very dizzy and was troubled by nausea and vomiting. Vertigo prevented him from moving about the room and he kept in bed. Vision became dim about 12 M., and when first seen by a physician the evening of next day he was blind or nearly so. Pupils were fixed and widely dilated, respiration slow and sighing, pulse weak and rapid. Uranalysis showed albumen and many hyaline casts.

He recovered all the functions except vision and was under the care of Dr. H. L. Swain for his eyes, who has kindly given me the information that when he first saw him the pupils were dilated and fixed, there was no perception of light, the rather hazy papillæ soon changed to a white atrophy with sunken vessels. He has made a long, faithful trial of medication for improvement of sight, including iodide of potassium, mercury, and strychnia injections, with no result.

The fifth and last victim who partook of the beverage was Anton Dukat whose wife died. He drank six to eight times, filling a glass nearly full each time, and ate sparingly.

He went home with his wife, slept heavily, and awoke or was awakened about 5 A. M. following morning. Tried to dress and go to work, but was unable to get about because of weakness, vertigo, and headache, and returned to bed and slept till 1.30 P. M., when he was awakened by his wife. These symptoms continued till 9 P. M., when he was seen by Dr. Joslin, who found capillary circulation sluggish, pulse 80 and weak, respiration 10 to the minute (raised to 14 by stimulation), deep, regular, and sighing, pupils widely dilated and vision blurred, no pain in stomach or bowels, vertigo and tendency to fall to the right, partly delirious, temperature and reflexes normal. At 11 P. M. was taken to the New Haven Hospital.

There an attempt was made to use the stomach pump, but nothing was brought forth.

February 5th.— Pulse full and bounding, 120; respiration 22, temperature 98°; slight headache, tight feeling across chest, knee jerks exaggerated, pupils very widely dilated, very poor vision, but react to light and accommodation.

February 6th.— Vision = 12in. fingers, pupils widely dilated, but still react sluggishly. Respiration 24, deep and labored· pulse 96, strong and good volume. Patient lies in a dazed con dition. Knee jerks slightly exaggerated, plantar reflexes markedly so. No nausea or vomiting. Has been given hot baths strychnia, dilute HCl and cathartics.

February 8th.— Cannot count fingers; eyeballs and lids feel sore.

February 11th. — V.=objects at one foot distant. All other untoward symptoms have disappeared.

February 12th.— V.= 12in. fingers. Can walk about without help.

February 13th.— Vision very poor and much constricted. Pain right side head, shooting pains running down the legs, feeling of tightness across chest. V.= 3in. fingers. Temperature, 103.8°.

February 14th.— General improvement. V.= 12in. fingers. Temperature, 100.4°.

February 16th.— I see the patient today for the first time. V.= 24in. fingers. Pupils dilated about two-thirds maximum. No changes in media. Papillæ pale. Outlines supero-temporal periphery right nerve moderately blurred. Calibre arteries decidedly diminished, capillaries shrunken. No exudation or hemorrhages.

The patient was not under my care, and at this time I do not think it was known what caused his condition. I suggested that he should be given K. I. in rapidly increasing doses and 1/20 strychnia every six hours by injection. On the 22d inst. K. I. was stopped and biniodide mercury given. The 23d inst. he left the hospital with a vision o.u. 2/120.

Uranalyses were made the 5th, 8th, and 11th insts. A trace of albumen and a few epithelial casts found.

I did not see Dukat again till June 19. He had been given mercury K. I. and tonics. On this date his ocular condition was as follows: viz., O. D. 2/200, O. S. 4/200; no Jaeger type can be read. Pupils dilated, right fixed, left very sluggish. White atrophy of each optic nerve, arteries diminished in calibre and capillaries looking thready.

He came to my office for daily injections of strychnia for a period of three months, the only other medication being syrup of the hydriodic acid. I gave him full doses of strychnia, getting

the physiological effect, very often, so that he would be so weak in the knees that locomotion was impossible without a rest of an hour or two. His sight gradually improved to O. D. 4/200, O. S. 9/200. October 4th right pupil sluggish, but responds mildly to strong light, dilated but little; left pupil about normal. During October I gave him injections three times a week, and then stopped all treatment, as I became convinced that I had reached the limit of visual improvement, frequent tests showing no material change.

The field was constricted, but there was no central scotoma in either eye. I have seen him occasionally since, and he has held his own, the last record, July 10th, 1902, being as follows: viz., O. D. 5/200, pupil slightly dilated and responds sluggishly to strong light. Greenish white atrophy of nerve and a few spots of choroid in crescent shape showing at temporal side. Diminished calibre of all the vessels, capillaries being mere threads. T — ½. Field as shown in charts and no central scotoma. Color perception fairly good. Slow in selecting shades from the mass of worsteds and a tendency to mix green and blues. O. S. 10/200, T — ½, pupil dilated little if any and fairly active. Condition of nerve and vessels similar to left eye. Color perception a trifle more accurate.

Lenses afford no material improvement to sight and he can read J. 16.

He has had from the beginning more or less photopsia, seeing green and red sparks and flashes of light. No pain or photophobia now and goes about in comfort and milks cows.

He thinks there is a tendency to gradual, slight improvement in vision.

His history previous to his affliction has been good, having been only an occasional and moderate smoker and not indulging in alcoholic drinks regularly or excessively.

Regarding the concoction that was mixed by J. S., it was thought that perhaps cherry pits might have been crushed into the wine which was used and some alkaloid have caused the poi-

soning, but nothing deleterious was found by the Connecticut State chemist and Dean of the Yale Medical School, Dr. H. E. Smith.

The wood alcohol was examined and found to be the ordinary commercial article.

The five people drank from the same glass, a regular two-ounce whisky glass, and this was filled nearly full each time a drink was taken. It has been quite conclusively shown that the mixture was one-third wood alcohol, hence the approximate amount of this alcohol drunk by each person was as follows: viz.,

Mrs. V. S.,	5½ drachms		
Mr. V. S.,	16 drachms		
Mrs. D.,	21 drachms	(died)	
J. S.,	40 drachms		
A. D.,	37 drachms[1]		

It will be observed that the seven people who showed the marked symptoms of wood alcohol poisoning obtained their drink from J. S. directly or from materials found in his house, and there is every reason to believe that he was accustomed to pilfer a pint of wood alcohol from the factory where he was employed, supposing he was getting "good alcohol."

The subject of methyl alcohol amblyopia has been so thoroughly treated in its pathological aspects during the past few years that I have only attempted to consider these cases in their clinical features, and the two points of chief interest in the single case I have had an opportunity to keep under personal observation, are the absence of central scotomata and the improvement in vision by the faithful and long continued use of strychnia in large doses.

There had been no material improvement in vision from the time he left the hospital, February 23d, to the day I began strychnia injections, June 20th, and he had used K. I. mercury, and it seems to me fair to assume that the subsequent change from O. D. 2/200 to 6/200 and O. S. 4/200 to 10/200 was due to the drug used.

So far as I have been able to ascertain only two of these seven people were accustomed to use some form of alcoholic drinks as a regular habit. V. S. had a daily habit and "could hold a lot."

J. S. may have been used to two or three drinks of whisky daily and six or eight on an occasional Sunday or holiday.

In the cases of the two women who died neither was addicted to the regular use of any form of alcohol.

DISCUSSION.

DR. WARD HOLDEN.— There are certain districts in New York where wood alcohol is regularly sold to the Italian laborers.

DR. HIRAM WOODS.— I want to express my deep appreciation of Dr. Ring's paper. I have been thrown a good deal into contact with this matter in connection with the wood alcohol contained in Jamaica ginger sold by a certain drug firm in Baltimore, and in the cases brought to my notice the symptoms were very much the same as those referred to in Dr. Ring's paper.

Subsequently my friend and colleague Dr. Harlan got hold of some of the products made by this firm and it was found that the alcohol used in their manufacture was wood alcohol, and there are now pending in Baltimore a number of suits against the firm.

The drug trade, physicians, and other people should know more about the poisonous effects of this drug. As Dr. Holden has just said, it is being sold to laborers in a number of places and there are some chemists who are willing to go on the stand and testify that it is not dangerous. I think the ignorance that prevails about it is much to be deprecated. The use of wood alcohol is rapidly increasing in the arts and manufactures, and it will be, I think, largely through the observation of ophthalmologists that its evil effects upon the organism will be demonstrated.

DR. A. G. THOMSON.— I reported several years ago a case of blindness caused by use of Jamaica ginger, which I had examined and found to contain methyl alcohol. I have had many cases since and it has seemed to me that perhaps the methyl alcohol in itself is not so much the cause of the blindness, but

when it is compounded with other ingredients, as with the Jamaica ginger. I understand that where they make the wood alcohol they take the crude oil and distill it and skimming off the top use it with apparently little harm, but when compounded with other drugs, as with Jamaica ginger and perhaps Cayenne pepper, it produces these poisonous symptoms.

DR. J. M. RAY.— Several years ago I had a case, which unfortunately was not published but which was reported to a local medical society. I wrote out the history of the case and forwarded it to Dr. de Schweinitz. That was a case where pure methyl alcohol was drunk. The patient had been out with friends and drank some wine and then went home and retired, but being nervous and restless during the night got up and looked through the medicine chest for something to relieve her condition and finding a bottle marked "alcohol," diluted a quantity with water and drank it. Exactly how much was drunk could not be determined, as she absolutely denied that she had taken anything that could have produced the blindness, but the bottle was found and we could assume that she drank at least a half ounce of the wood alcohol. The symptoms were those with which we are all now so familiar, as resulting from wood alcohol, the intense nausea and vomiting, gastric irritation, burning sensation over the region of the stomach, followed by blindness with dilatation and inaction of the pupil. I saw the patient on the third day and made an ophthalmoscopic examination; except a hazy fundus there was no evidence of disease. The case went on for ten days with no pupillary reaction and no perception of light, then gradually light perception returned. She improved for nearly three weeks; vision in one eye became 20/70 and in the other 20/40. Then atrophic nerve changes occurred with shrinking of the retinal vessels and rapid lessening of vision.

Since that time I have seen another case with exactly the same history following the taking of medicine from an herb doctor. A colored woman drank some of the medicine for some purpose or other and developed changes similar to those that occurred in the first case. The first case proves conclusively that the methyl alcohol is certainly a factor in the blindness that occurs. In these two cases, and in the other cases that have been reported, the clinical course is so similar that I cannot understand why some are still skeptical as to the influence of wood alcohol on vision.

DR. J. W. INGALLS.— In conversation, a short time ago, with Dr. E. H. Squibb on this subject he told me that there was quite a difference in the methods of manufacture of wood alcohol; that if the distillation went on slowly then the poisonous properties of the product are slight, but if the distillation is carried on rapidly then you get the pronounced poisonous effects. Perhaps that accounts for the fact that some of the samples may be taken with but little injury, while others get hold of a product that produces very serious results. Quite likely the trouble lies chiefly in the manner of distillation.

DR. LUCIEN HOWE.— About seventy or eighty per cent. of the wood alcohol is manufactured in the town from which I come, and this question of its poisonous action has been considered very carefully there. One of the companies has a very careful and intelligent secretary, who watches the literature on this subject and carefully culls all the cases that are reported. I am quite sure there are very few as conversant with the facts as this secretary. I heard him cite the case of a hat manufacturing company which used such large quantities of this product that they instituted a condensing process, by which the alcohol taken in at one end passes through the room and is collected at the other end, and the alcohol laden air seems to have no deleterious effect upon the employees. We should be very careful in drawing our conclusions upon this subject.

A CASE OF COLOR BLINDNESS IN A RAILROAD EMPLOYEE DUE TO TOBACCO AMBLYOPIA, FAILING TO BE RECOGNIZED BY ANY OF THE WOOL TESTS, BUT IMMEDIATELY DETECTED BY LAMP.

BY ARCHIBALD G. THOMSON, M.D.

The case which I present to the society today unfortunately came to my notice after the time the titles of the papers should be sent in to the Secretary to be published in the announcement, but, as it is rather an interesting case of color blindness, I beg to present it now.

W. R., an engineer on the West Jersey Railroad, was sent to me a few days ago by the examiner of that division for test of his vision in color perception. A man of 45 years of age, been in the railroad service 36 years, and recently passenger engineer. A man whose family history has been particularly good, well preserved, has drank and smoked moderately during his life; never used tobacco until after 21 years of age. Since that time he has smoked about 5 cigars a day and about half an ounce of tobacco in his pipe. The history of the case is as follows:

Last July he noticed that his vision became hazy for distance at times. This, however, was only at times. A month or so after noticing this he found some difficulty in reading his orders. He went to an optician, procured a pair of high plus glasses; these enabled him to see his work somewhat better, but did not clear up the haziness. Four months after first noticing the haziness in his eye, which had gradually increased, he was about to take his engine out one morning, which happened to be slightly foggy. He then found that he was unable to recognize any of the signals, and his vision was so decreased by the fog that he was unable to read the number of the engine quite close to him, which could be seen by others. However, on a clear day he was able to recognize clearly.

He then came before the examiner of that division, who found that his vision was very much decreased, being only 1/5 in each eye, but he was able to pass perfectly and promptly all the wool tests for color blindness. He then consulted a doctor, who, after examination, found that he was suffering from tobacco amblyopia, and had the typical negative scotoma for red and green occupying the area between the blind spot and fovea. He was put under treatment, but his vision, although somewhat improved, was not up to the standard to enable him to go on with his work, and is still under treatment. My examination shows the following conditions:

That the anterior aspect of the eyeball was apparently normal. Ophth. examination showed the media clear, but the disc

was slightly pale to the temporal side, otherwise negative; fundus was normal; the vision was only 1/10 in each eye. With the color stick he was able to pick out rapidly all colors without a mistake or hesitating. This was also proved by all the other wool tests. His field of vision showed with the perimeter that the form field was normal; no contraction in color fields; yellow and blue were recognized in all parts of the field, even in the area between the fovea and blind spot, but his perception for red and green was lost in that area.

However, being tested with a lamp, with one eye closed at a distance of 20 feet, and put through general examination with lower disc containing red, green, blue, and ground glass, he was unable at first examination to recognize the red light, but in subsequent examination he was able to recognize the red light almost always. However, he mistook it occasionally, calling it white. The green light, if very bright, was frequently recognized, but just as many times called white. The white light was almost invariably called green.

By placing the smoked glass of rather deep hue over these colors he was only occasionally able to tell red, but never to distinguish between green and white, which were readily recognized by the normal eye. In the upper disc of Thomson's lamp, which represents the cross-examination of a case, is a light pink, which is composed entirely of blue and red, a light green, and a white light, which represents the neutral colors to a red and green blind man. He was unable to distinguish them apart, all resembled a shade of gray, which clearly proved the neutral band of a color blind man. This test was the same with one or both eyes open. By placing a red or green glass, size from test set, over one eye and allowing him to look at a luminous point 6 meters away, he was able to recognize the color almost always. By placing a dark smoked glass in front of the eye the color was entirely lost, giving only a yellowish gray color; however, could be easily recognized by one with full color perception. By this test was shown that the color perception although present in the periphery of the field of vision was greatly reduced.

With the red glass 6 centimeters in diameter, and the patient fixed on a spot 5 meters away, close to the eye the color was clearly seen. As glass was gradually withdrawn from his eye he lost the red perception at 20″ exactly.

This case is interesting in two particulars:

First. This is the first case that has come under the notice of the examiner where a man's eye was deficient in color perception, due to the use of tobacco, which has prevented him from continuing his occupation as a railroad engineer.

Second. In showing the insufficiency of wool tests in detecting defects in color blindness of this character.

Third. The advantage of the use of deep London smoke glass in reducing the intensity of the color, resembling certain conditions that engineers are subjected to, and shows clearly if a man's color perception is lowered.

DISCUSSION.

Dr. Charles H. Williams. — This is very interesting as an additional case showing how a person may pass the wool test without difficulty and yet fail in recognizing the distant signals used by railway men. As the test with the lantern is more used these cases are more frequently discovered, which formerly were passed as all right because they could get through with the wool test. I remember one case which I examined before the superintendents of the Boston and Providence Railroad. He passed the wool test without a single mistake, but when tried with the lantern he called green red and red green so often that it was apparent that he could not distinguish the difference with any certainty, and he made the same mistakes with switch lights. The central portion of his retina had a small scotoma for red and green, in which those colors were confused, and which covered the area in which distant signals would be focused.

Dr. W. K. Rogers. — I can add one case of this kind from recent experience, in fact two occurring quite closely together. One had passed four division examinations on the Pennsylvania road system and was referred to me not on account of that, but for presbyopia, and the matter came up in the course of the

examination made by my assistant. I had instructed him to put these cases through a routine examination just to make a record of them. He called my attention to the fact that the man was color blind, although with the worsteds he had no difficulty whatever. The more experience we have with the lantern the more satisfaction we get in this way. And there is satisfaction in another way too, from the point of view of the men we examine. It is quite common to hear them say: "Doctor, this is the first fair test I have had." It appeals to the men as being a fair test.

DR. CHARLES A. OLIVER. — I am glad that this discussion has taken the course it has. As early as 1854 this matter was discussed by Dr. George Wilson of Edinburgh, who, while making careful examination of some subjects with subnormal color perception, found that quite a number who could differentiate the colored wools very well when close at hand could not distinguish certain colors when they were situated at a distance; to this condition he gave the name "chronic myopia"; such cases as now shown not infrequently having central relative scotomata.

Ten years or more ago I brought before this society the proof that the ordinary methods of wool examination then (and even as now) employed were valueless for use among employees of railways, marine, army, and navy service. I showed that it was not the recognition of colors at two or three feet distance, but at "safe distances", a hundred feet or more, as I termed it, was that which was necessary. For this purpose I devised a series of methods which I considered were the best applicable for the detection of subnormal color perception among such employees. A description of these tests can be found in the Transactions of our Society.

I further found that the signals generally employed were not only improperly gauged as to the tint of the colors used, but also as to their degrees of saturation and size. The dangers from these faults were discussed, as for example with the lights on vessels, especially in foggy and well filled harbors. So, too, with railway lights and the signals which are used for "danger" and "caution"; they should be arranged not only as to color, but as to the grade, the size, and the condition of the color, thus bringing up questions which can be decided only by an international commission, as I have elsewhere pointed out. At present I have another paper prepared for that purpose.

The lanterns now employed by Thomson and Williams are better than the wool tests, but as at present made and used are most imperfect.

The candidates to be properly examined must be placed in their actual positions during work, and their color vision must be studied by properly adapted methods in some way like that which I have previously shown to the Society.

Recently, I had an instance of the condition in a well known railway official, who being both conscientious and solicitous by a discovered inefficiency of central color perception in himself, requested that a series of tests be made upon him. These, which were made by competent surgeons with both wool and lanterns, he successfully passed. At this juncture I was called in. After pursuing the ordinary plans I tried him with a number of tests made during the very conditions under which he worked. As a result I found negative scotomata for red, green, blue, yellow, and even white, which proved his incapacity. He gave up his post on that account, and was given a safe and more lucrative position on the road.

It is certain that such cases are not rare, remaining unexposed by reason of the still general employment of inadequate apparatus and inefficient methods.

A CASE OF CAVERNOUS SINUS THROMBOSIS FOLLOWING GRIPPE — AUTOPSY.

DR. EDWIN E. JACK.

C. F. B., male, aet. 43, a shipper. Family history negative. He had always enjoyed the best of health, was a hard worker and temperate in habits. His illness began Jan. 26th, and the history of it as given by his physician, Dr. J. M. C. Murphy, is substantially as follows: The patient complained of severe pain in the right side of the face, starting at the angle of the jaw and radiating over the whole side of the face; there was also some pain in the chest, intercostal in character, and he complained of feeling very tired. Temp. 101, pulse 80, bowels constipated, urine dark colored, slight cough. Diagnosis: grippe, with facial neuralgia. He was ordered a cough mixture and a

coal tar product for pain and heat to the face. After a few days the patient was relieved, got up, shaved, and read the morning paper. The temperature was reduced, but not the pulse. A cathartic was ordered. Feb. 1st, face was feeling better, but whole side of head felt sore. Cough much relieved and pain over chest gone. Pulse as before, bowels hard to move; magnesium sulphate ordered. On Feb. 3d the pain started up again with renewed vigor over right side of face and back of head. Considerable swelling at angle of right jaw, which went away in a few days. Temp. 100, pulse 80. The pain continued day and night, severe at times, till Feb. 8th, when it disappeared, leaving considerable soreness on that side of the head. He was ordered a sedative. On the 9th the right eye became a little more prominent than the left. Cough was diminished, tongue swollen and cracked, saliva very tenacious. Temp. 100, pulse 80. On the 10th the left eye also became prominent. Patient desired to sleep all the time, but could always be aroused when spoken to. Given phenacetine salol and caffeine. Next day there was no change in the condition of the eyes, and Dr. J. A. Tenney was called in consultation. In his opinion no other symptoms were presented than those of cellulitis or tenonitis, and those not marked. The patient was in a drowsy state, but could easily be awakened and answered questions intelligently. Leeches and hot fomentations were ordered. Patient took nourishment every two hours, egg-nog, malted milk, and beef tea. No change in condition of eyes next day except that o. s. was more prominent than o. d. Pressure on eyes was not especially painful. Pupils reacted to light. He was more drowsy than before, but if roused could answer questions intelligently and then relapse into a stupor. The following day brain disturbance was quite marked, he could be aroused with difficulty and talked very thickly. Temp. 102, pulse 100. Later the same day I saw him; the temperature then was 101, the pulse 120. The man lay in a stupor from which he could only with considerable difficulty be aroused. There was a decided exophthalmos of both eyes, the conjunctiva was chemotic, pupils some-

what dilated, responding to light; there was no œdema over the mastoid. The fundi were imperfectly seen, but there seemed to be no marked change except some dilatation of the veins. I was a little uncertain of the diagnosis, though it was difficult to explain the general condition by anything except thrombosis of the sinuses. I advised his removal to the Eye and Ear Infirmary, and he arrived there on the afternoon of the next day moribund. He was unconscious and could not be aroused. Pressure back of the angle of the jaw on the right side caused patient to flinch and raise head; pressure on the back of the neck did the same, but to a less extent. There was considerable cyanosis especially of face and lips, which were dry and cracked. Some swelling back of right jaw, mouth wide open, stertorous breathing, tongue dry and covered with a thick brown-black coating. Free perspiration, especially about the head and neck. No œdema over mastoids. Superior wall of right external auditory canal bluish in color. Both membrana tympani normal. Nothing definite in lungs except breathing sounds were harsh and coarse rales could be heard in places. Heart sounds feeble and often intermittent. Abdomen negative. Temp. 106.5, pulse 155, resp. 32. 4 P. M.: cyanosis increasing, temp. 103.5, pulse 170, very weak and intermittent, resp. 40. A consultation was held with Drs. Mixter and Dwight. Operation was not advised. At 8 P. M. temp. was 106, pulse could not be counted, resp. 50. Died at 9.15 P. M.

AUTOPSY. (Dr. Verhoeff.) Body that of a fairly well nourished man. Length, 166 cm. Marked rigor mortis and considerable lividity of dependent parts. Eyelids and conjunctivæ on both sides highly œdematous.

Head. Pia-arachnoid congested, œdematous, and shows numerous foci of suppuration in the sulci on the sides and at the base of the brain. Cerebro-spinal fluid very turbid. Both cavernous sinuses distended with pus and their walls lined with thrombi. Circular sinus filled with purulent thrombus. Left superior and inferior petrosal and left sigmoid sinuses similarly affected. Right inferior petrosal sinus filled with pus, which

continues into a thrombus blocking the right jugular vein. The other venous sinuses are free. Frontal and ethmoidal cells are normal. Sphenoidal cells filled with pus and surface of sphenoid bone covered with purulent exudate. Orbital tissue on right side œdematous, but shows no suppuration. Orbital tissue of left eye contains a considerable quantity of pus, which is in direct continuity with that in the left cavernous sinus. The tympanum and mastoid cells on each side normal. Brain on section shows the right lateral ventricle filled with blood and pus. The brain substance is apparently normal.

Body. Peritoneal and pleural cavities free from adhesions and fluid. Pericardial cavity does not contain an excess of fluid. Surfaces of lungs not generally congested, but show numerous elevated nodules, some of which on section are found to contain pus. Both lungs are for the most part crepitant, slightly œdematous and show hypostatic congestion. On section they show a few purulent foci. Heart normal. Liver shows no abscesses on section and is apparently normal. Spleen shows a number of punctiform hemorrhages scattered over the capsule. On section, pulp is very soft and grayish red in color, trabeculæ and malpygian bodies not well seen. Kidneys show one or two small cysts beneath the capsule, but are otherwise apparently normal. The stomach is normal. Intestines not opened.

Bacteriology. Smears from the pus in cavernous sinus, left post-orbital tissue, and meninges, show a variety of bacilli and only a few cocci. Cultures from same, and from blood in left ventricle of heart, show only the staphylococcus pyogenes albus.

Diagnosis. Empyema of sphenoidal cells. Thrombosis and suppuration of cavernous, circular, right inferior petrosal, left superior and inferior petrosal, and left sigmoid sinuses. Thrombosis of right jugular vein. Suppuration of left post-orbital tissue. Purulent meningitis. Embolic abscesses of the lungs.

The subject of sinus thrombosis has been treated at length within a few weeks by Drs. E. W. Dwight and H. H. Germain in a paper reporting four cases and one cranial operation. For a full account of the subject and the bibliography I would refer

members to this. There are, however, one or two things which my slight experience with these cases has suggested to me. First, as to the diagnosis of the condition. I recall seeing but two undoubted cases of this disease, one the present one, the other one of those reported by Dr. Dwight and operated on by him. In neither of these cases was there a marked neuritis, decided swelling of the disc, or especially enlarged retinal veins, conditions which are supposed to be distinguishing features between thrombosis and orbital cellulitis. Oedema of the mastoid also has been wanting in both cases; apparently the lateral sinus must be directly involved to cause this. In the absence of these two symptoms, at least before the second eye becomes involved, the diagnosis is not sure. In the present case the absence of œdema over the mastoid and the fundus appearance led me to think at first that possibly there was a double orbital cellulitis — a complication of grippe which I believe has been reported; the mental state, however, seemed incompatible with this diagnosis.

Dr. Dwight in his paper states that early operation is important and that the cavernous sinus is readily accessible. The operation done by him on the first case I saw, practically the same as done by Hartley on a case of Knapp's — trephining the temporal bone low down, lifting up the temporal lobe, and incising the sinus with a guarded bistoury — occupied only eight minutes, and its efficacy was shown by the rapid recession of the exophthalmus and the improvement in the general condition of the patient. It was too late, however. Here it seems to me is where the great difficulty comes in: the symptoms, certainly in most cases, do not allow a sufficiently early diagnosis, for although toxæmia is not a bar to the operation the reasons for early interference are evident.

In our own case the autopsy showed an apparent direct connection between the sphenoidal suppuration and the sinus, a direct infection such as occurs in the lateral sinus from middle ear disease. Considering this immediate cause and the extent and virulence of the process it seems impossible that any operation, except possibly an early drainage of the sphenoidal sinuses, could have saved the patient.

DISCUSSION.

DR. B. A. RANDALL. — I think at a previous meeting I referred to the employment of probing the sphenoidal sinus, and at the risk of being tedious I should like to repeat my remarks as to the facility with which the sinus can be reached by a probe in the large proportion of adult cases. A cotton-carrier with a slight terminal curve, wrapped with a little cotton and moistened with cocaine, is carried up past the junction of the middle and posterior thirds of the middle turbinal, and will usually enter the sphenoidal cell, and thus the presence of pus can be determined and operative treatment at once resorted to if necessary. I have with a child passed forceps up into the sinus and opening them there, withdrew them, making a free exit for the secretion. The early use of such simple means may throw a great deal of light upon the case and enable you to avoid serious and perhaps fatal complications.

THE TREATMENT OF EPITHELIOMA OF THE EYELIDS BY THE X-RAYS.

BY WILLIAM M. SWEET, M.D.,

PHILADELPHIA, PA.

The X-rays as a method of treatment in certain forms of malignant growths may be considered to have passed the experimental stage, and to have apparently established their superiority to operation in the relief of superficial affections like epithelioma. Apart from their use in the primary treatment of the new growths, they have a distinct value when employed after operation to prevent recurrence of the diseased tissue. What may be done by the X-ray treatment of epithelioma of the tissues surrounding the eyeball is evidenced by the cases here recorded.

CASE I. Mrs. G., aged 84, was referred to me on February 14, 1902, by Dr. W. P. Goff, of Clarksburg, W. Va. About 12 years ago a slight roughness of the skin appeared on the side of the nose close to the inner canthus of the left eye. Four weeks later a crust formed, which, upon becoming detached while bathing the face, left a small ulcerated spot, from which

FIG. 1. Epithelioma.

FIG. 2. Result of Treatment by the X-Rays.—36 exposures.

a few drops of blood flowed. For several years afterwards the process of temporary scabbing over continued without causing much pain or inconvenience, although there was a gradual increase in the ulcerated area. About four years ago the growth commenced to spread more rapidly, passing upwards on the nose and also implicating the eyelids and the tissues of the orbit, the sight of the eye being lost in about a year. With the spread of the ulceration there was itching and considerable pain, the paroxysms of the latter often lasting for many hours. Numerous ointments and lotions were employed, without relief, but she refused all operative treatment.

The condition of the growth when I first saw it is shown in Fig. 1. At that time there was an almost complete obliteration of the conjunctival sac from inflammatory adhesions, the eyeball was atrophic, and there was an extension of the growth into the structures of the orbit, but to what depth could not be determined. The itching was intense, and the pain would often continue throughout a whole day. Examination of a section of the growth showed it to be a squamous-cell epithelioma.

After a lead mask had been prepared to protect the face and the sound eye from the action of the rays, treatment was commenced on February 15th, and continued daily for periods ranging from 5 to 10 minutes for two weeks, when it was given every second day for one month, and then every third or fourth day for two weeks more.

Within a week after the beginning of the treatment there was a decided diminution in the severity of the pain, the discharge was lessened, and the area had a healthier appearance. At the end of the third week the size of the growth had diminished slightly, healthy granulations appearing at the edges. The improvement continued, and on April 5th the nasal portion had entirely skinned over, and the palpebral and orbital disease showed decided diminution in size. The picture Fig. 2 was taken at this time, after a total of thirty-six exposures.

On April 14th she returned to her home, and the treatment has been since continued by Dr. Goff on an average of three

times a week, directed to the diseased tissue of the orbit, with still further improvement.

CASE 2. Thomas M., aged 71, was sent to me February 28th, by Dr. C. A. Oliver, with the history of a growth of the lower lid of the right side, close to the external canthus, which started 11 years before as a small ulcer. Under the use of ointments the ulcer healed, and gave no trouble for several years. In August, 1900, the disease recurred, and continued to spread, notwithstanding all forms of local treatment. The growth was found to be an epithelioma. Its appearance at the first examination is shown in Fig. 3.

As the man lived some distance from the city the X-ray exposures could only be given every fifth or sixth day, and extended over a period of four months, twenty-two treatments in all being given, with the result as shown in Fig. 4.

CASE 3. James M., aged 64, came to me from Dr. C. A. Oliver with a narrow ulceration on the edge of the lower lid of the left eye near the internal canthus, which had existed for a number of years. No section of the growth was secured, but it had the appearance of epithelioma. After ten treatments, extending over a period of five weeks, there was complete healing of the ulcerated area.

The action of the X-rays in relieving malignant growths has not as yet been satisfactorily explained. All operators recognize a destructive action of the rays upon embryonic cells, without, however, affecting normal healthy tissue, except under prolonged exposures, but the reason for this selective action remains to be determined. The sections made from a piece of the diseased tissue taken from Case 1, after a number of applications of the rays, and examined in the laboratories of the Jefferson Medical College, showed intense infiltration of leukocytes, although there was at that time subsidence of the early inflammatory symptoms. Over 90 per cent. of the cells were polymorphonuclear leukocytes, which were conspicuous in the cancer areas, around the blood vessels, in the blood vessel walls, and as intravascular marginal collections. The epithelial cells

FIG. 3. Epithelioma of Lower Lid.

FIG. 4. Result of Treatment by the X-Rays. — 22 Treatments.

showed evident degeneration; the chromatin being fragmentated at the periphery of the nucleus, and appearing as fine irregular granules, with reduced intensity of stain reaction.

While leukocytosis may be a causative factor in the cure, the prompt relief of the pain and the fact that the ulcerated area loses its sensitiveness to touch indicates that some trophic change takes place under the influence of the rays. This may be secondary to changes of degeneration in the finer nerve filaments, resulting in decreased vitality and ultimate destruction of the cells of the diseased tissue. That the X-rays have a pronounced action upon the nerve structures is seen in the loss of sensation of healthy skin, following too long or too frequent exposures, while as regards the cancerous tissue, large portions may be excised without pain after the part has been subject to the action of the rays for several days.

In employing this method of treatment the healthy tissues are protected from the action of the rays by heavy sheets of tin foil, or by a sheet of lead, about 0.3 mm. in thickness, having an opening corresponding to the size of the diseased area. A tube of low vacuum gives more prompt results than one of high penetration, and is to be placed from 6 to 10 inches distant from the part. The exposures vary from 5 to 10 minutes. The closer the tube is to the disease, the more powerful is the effect. Care must be taken not to seriously burn the tissues, a result that may readily follow exposures that are prolonged, too frequent, or with the tube too close. This burning does not usually appear until a week or ten days after any given exposure to the rays.

There is probably no portion of the body where the value of the rays will be greater than in the surgery of the face, particularly of the eyelids. Their employment will render unnecessary the extensive plastic operations, with disfigurements of the face, which are now required to cover the area after the disease is removed. Even the new tissue that replaces the disease after the X-ray treatment differs from ordinary scar tissue, having more nearly the appearance of normal skin, being more pliable and not so liable to contract.

The most uniform results have been secured in the treatment of epithelioma and lupus, although the rays are of value in other neoplasms. Sufficient time, however, has not elapsed since the discovery of the method of treatment to indicate the permanency of the results. I believe that when the treatment is properly carried out, and continued for a short time after healing has occurred, the disease will not return. Even if there is recurrence, exposure to the rays may be renewed, with results equal if not superior to what may be secured by secondary operations.

DISCUSSION.

DR. SAMUEL THEOBALD. — Dr. Gilchrist, of the Johns Hopkins, has been working along this same line, and his experience has been such that he is extremely enthusiastic on the subject. He has not watched the cases long enough yet to be sure of the final outcome, but the good so far accomplished has made him very sanguine.

DR. CHARLES A. OLIVER. — I would like to ask Dr. Sweet if he thinks the method would be of any value in the treatment of fresh scars?

DR. SWEET. — I have not tried it in that way and I doubt if it would make any change in such tissue.

DR. OLIVER. — The reason that I have asked this is that I believe that the action of the rays is catabolic in such cases, without any selective action upon the character of the cells themselves, thus probably making the method of value for the production of better cicatrization areas in recent wounds.

DR. S. B. ST. JOHN. — Have you noticed any effect upon the eye in the use of the rays in this procedure; does the screen keep the rays from injuring the eyeball?

DR. SWEET. — The opening in the lead screen permits the rays to strike only the diseased tissue. As a precautionary measure the cornea is rotated away from the area treated, as the rays have a burning action, and might affect the cornea. In carrying out the treatment, the length of exposure is lessened or the period between the treatments increased as healing takes place.

DR. PETER A. CALLAN. — I have seen some little work of this kind by Dr. Horton, who is very enthusiastic on the subject. I saw a case that had been under treatment for two months, a woman of forty years. He did not cover the eye as the doctor suggests. I saw the eyes immediately after treatment and they were a little reddened, but nothing more. The rest of the face had been covered with tinfoil.

DR. O. F. WADSWORTH. — Dr. F. H. Williams, of Boston, has been using the X-ray for epitheliomata, and I have seen two or three cases that have been benefited by the treatment. No one of them was nearly as bad as the one shown by Dr. Sweet. In one, however (a patient that I sent him), the tissues were so much involved that it did not seem possible to stop the disease without removal of the eye, and very likely some of the bone at the edge of the orbit. This man was very much improved, but withdrew from treatment before he was entirely cured. So in one or two other cases, while there seemed to be improvement, when I saw them last the tissues were not entirely healed.

DR. J. M. RAY. — I have been very much interested in this work and have seen some results of it. A case of epithelioma of the external canthus was treated in this manner by Dr. Butler, a friend of mine; a piece of sheet lead was used, cutting an opening the size of the epithelioma, thus exposing the growth without any danger to the eye.

A second case I would refer to was an epithelioma of the anterior pillar of the palate. He commenced the treatment by exposing the glands first to the influence of the light and they softened rapidly. Then the growth itself was directly exposed to the light and there was very decided diminution in its size.

THE IDEAL RESULT TO BE KEPT IN VIEW IN THE OPERATIVE TREATMENT OF CONVERGENT STRABISMUS IN CHILDREN.

BY SAMUEL THEOBALD, M.D.,
BALTIMORE, MD.

From the oculist's point of view to prescribe glasses for a small child, to be worn constantly and perhaps permanently, is a matter of little moment; but, especially among the well-to-do classes, the child's parents regard the matter in a very different light. To them, not infrequently, it is a serious misfortune, a matter taken much to heart, a source of real distress. And, after all, it must be admitted that this feeling is not wholly without warrant. Unquestionably it *is* a misfortune for a child, whether boy or girl, to be doomed to the perpetual wearing of glasses; for it cannot be denied that the good looks of the girl and the manly appearance of the boy are seriously marred thereby. Such being the case, it seems to me it is the oculist's duty not to lose sight wholly of this aspect of the matter, but in the prescribing or withholding of glasses to give it a measure of consideration, and to permit it, within certain limits, to influence his decision.

It is in the management of cases of squint occurring in children that this deep-rooted prejudice against glasses is especially apt to manifest itself. Every oculist, doubtless, has observed the feeling of disappointment which parents commonly exhibit when told that the successful outcome of a proposed operation for squint will depend largely upon the subsequent use of glasses. To the parent the choice between the squint and the glasses seems little else than a choice between evils of nearly equal magnitude.

In several cases of squint the success which has attended my efforts to regard this parental prejudice has been such as to

encourage me to further experimentation in the same direction, and, on the whole, to lead me to believe that, oftener than is commonly supposed, it is possible after operating for convergent strabismus to avoid the constant and continued use of glasses. The practicability of doing this will depend, of course, largely upon the degree of optical error back of the squint; but as there are many cases of concomitant convergent strabismus in which the ametropia is not excessive, the field for such experimentation is not so restricted as might appear at first sight.

Briefly outlined the method which I have employed is as follows:

A minimum amount of muscle cutting, usually a free tenotomy of the internal rectus of the squinting eye, which commonly leaves a residual squint.

The correction of this residual squint and the establishment of binocular vision by the careful adjustment of glasses, prisms being not infrequently combined with the spherical or spherocylindrical correction in order to encourage binocular fixation.

And, finally, after binocular vision has been firmly established through a period of several months, the *gradual* withdrawal of the assistance afforded by the glasses, until ultimately the glasses are put aside altogether or, at most, are worn only in near vision.

In modifying the glasses the prisms are first reduced in strength, then withdrawn; then a gradual reduction in the spherical correction is made until finally nothing is left. The rapidity with which these changes can be effected necessarily varies in different cases, and after each change one should assure himself that binocular fixation is still maintained. The recurrence of the squint or the development of asthenopic symptoms would be an indication that the help afforded by the glasses was being too rapidly withdrawn.

The conditions which make against the success of the method are the existence of a high grade of hypermetropia, a very considerable amount of astigmatism, decided anisometropia, marked amblyopia in the squinting eye, and, above all, that pronounced

indisposition to binocular vision which exists in some strabismic individuals, and in the presence of which one may congratulate himself if a satisfactory result is secured even with the aid of carefully selected and constantly worn glasses.

The history of a single illustrative case, which can be given in a few words, will suffice to show, when the conditions are favorable, what may be accomplished by the method I have outlined.

An extremely pretty little girl, four years of age, the daughter of one of the teaching staff of the Johns Hopkins University, was brought to me in November, 1897, for advice regarding a pronounced convergent squint of the right eye. She had been seen some months previously by Javal in Paris, who, it seems, was not disposed to operate, but advised only that the vision of the squinting eye should be strengthened by closing the good eye and using the defective one during a part of each day. Whether due to the carrying out of this advice or not, the sight of the squinting eye, at the time she came under my observation, was less defective than is usually the case. A two-grain solution of atropia which I prescribed revealed in each eye a hypermetropia of 3.50 D.; but, though used for a week, produced no appreciable effect upon the squint. A free tenotomy of the right internal rectus was then made. The cosmetic effect was good, but the cover test showed a residual squint, and, as this persisted, on the fifth day after the tenotomy glasses for constant use were prescribed as follows:

L. Eye + 2.75s ⊃ Prism 2° base out.

R. Eye + 2.75s ⊃ Prism 3° base out.

The effect of these glasses was to establish in a short time binocular fixation in both far and near vision. As this was satisfactorily maintained, two months after the glasses were prescribed the prism of the left lens was turned with its base inward, thus reducing the combined prismatic effect from 5° to 1°. This change gave rise to no inconvenience, and, binocular fixation continuing as before, the lenses were changed nine days later to + 2.s for each eye. Twelve days after this they were

further reduced in strength to + 1.s, and when these had been worn for about three weeks they were put aside, and the little patient was allowed to go without any glasses. Some transient asthenopia followed the withdrawal of the glasses, but there was no disturbance of binocular vision. Eleven months later, after an attack of influenza, the child being then in attendance upon school, there was some complaint of discomfort in the eyes; but carefully made tests showed not only that binocular fixation was still maintained, but that there was orthophoria in distant vision.

It is not improbable that in this, as in other similar cases, glasses for near vision may, sooner or later, be required, but even should this prove to be necessary, from the parents' point of view, it will be a mitigated evil as compared with their constant use.

NOTE. — Since this paper was presented to the Society I have received a letter from the father of the little patient, dated Paris, July 7, 1902, in which he says: "Her eyes have been perfectly '*straight*' at all times, nor has she ever complained of her eyes in any way since the operation."

DISCUSSION.

DR. W. B. JOHNSON. — I think it would be interesting to know in how many cases the doctor has made observations of a like character. I hardly think binocular vision would result in many such cases where the glasses are removed, even though they are removed temporarily. When the eyes have been corrected the mere removal of the glasses for a moment or two causes them to converge. Now how the gradual removal by reduction of the strength of the spherical glasses or prisms would result I cannot tell. It would seem to me rather questionable if anything could be accomplished in that way or not.

DR. PETER A. CALLAN. — Thirty years ago Dr. Donders advocated the nonoperative treatment of girls with squint and the nonuse of glasses. He said the cosmetic effect was bad, and he preferred to let them squint until they reached a certain age and then operate. It seems to me, however, that is a mis-

take. During the growing period if they need correction they should have it, and when they become old enough to decide for themselves they can take them off if they wish. Of course the wishes of parents should be acceded to. We all know what they do when they get old enough to have a voice in the matter.

DR. E. GRUENING. — I had a little girl under my observation, nine years of age, who squinted with one eye. I prescribed glasses for her and she still squinted with the glasses occasionally, and when the glasses were removed she squinted badly. She came home every day crying because of the remarks of the children, and the father came home from his work in the evening, and when he looked at his child he was very sorry that he had a squinting child, and he spoke to his wife about it every day. Then his wife came to me and told me how unhappy it made them all. She said it had a bad influence upon their family life and upon the character of the child, and asked me why I did not operate. I told her the eye would probably in the course of time become straight. I told her that if I operated on the eye then it would turn to the other side later. Then she said but could it not be operated on again in that case, and I said yes, it could. The result was that I operated and the eye has been straight ever since. And since that time I operate on every squinting child and am glad I can do it.

DR. W. F. MITTENDORF. — I can substantiate what Dr. Gruening has just said. The deformity is as painful to the parents as it is annoying to the child itself. I used to follow the same teaching and give glasses and tell the parents it would come out all right after a while. A family I thought a great deal of had such a child and I persuaded them to wait in this manner. Later I learned that the child had been taken to another doctor who operated and the child's eyes were perfect in every way. I think that if after the use of glasses we find that when they are taken off the child squints badly we are justified in operating, and this is so in the majority of cases. My most successful cases have been where I operated on both eyes at the same time. I have never had occasion to regret it.

DR. S. D. RISLEY. — Taking it for granted that our present views regarding the nature and cause of strabismus are correct it seems to me that in the long run it will be better to accept these views as a scientific basis for our advice to patients rather

than the minor and less important considerations which have been mentioned.

DR. SAMUEL THEOBALD. Just a few words in reply. As to Dr. Johnson's question about the number of cases, I mentioned that I had tried the plan in only a few instances, in fact only in three, but there was failure in no one of these cases. I have not tried it in dispensary practice, as there the parents would not be willing to buy a new pair of glasses every few weeks. The three cases were all good looking little girls, and the parents were much distressed about their having to wear glasses. Of course the whole thing hinges on the *gradual* withdrawal of the glasses. If you withdraw the glasses suddenly the squint returns at once; the point is to withdraw them very gradually and so teach the eye to depend upon itself, and in a considerable number of cases this, I believe, can be done.

Dr. Callan says he thinks it is well to let them have glasses when children, and when they grow older they can be withdrawn. I think it is very much more difficult to do this — after patients have worn glasses for from six to ten years, to say now we will take them off. Even the gradual withdrawal of the glasses is then not so likely to succeed. It must be done early.

Dr. Gruening tells us that he is now strongly disposed to operate upon all cases as they come to him, and I quite agree with him. The earlier I can get hold of them the better, not only because we can get good results then, but because I am a believer in the theory that the amblyopia is due to the squint, and I feel that the sooner I can get binocular vision established the better. I have made it a practice for years to operate on cases of convergent squint as early as possible. This little patient I spoke of was four years old. I do not know on what ground Javal decided not to operate.

Dr. Risley says he thinks we should treat these cases scientifically, without regard to prejudices on the part of patients. If it is practicable to do what I have described and leave the patient with orthophoria, with perfectly comfortable eyes, it seems to me it is scientific treatment. All we want is to restore binocular vision and enable the patient to go on using the eyes comfortably. This is rational and scientific too, and it is unquestionably practicable in a certain number of cases. The idea that hypermetropia is the sole cause of the squint makes some think that the only scientific course is to correct the hypermetropia;

yet out of thousands of cases of hypermetropia we have only tens of cases of squint. I believe hypermetropia is the most potent factor in the production of convergent squint, but there are certainly other factors, and the next most important is insufficiency of the external recti muscles. We have weakness of the external recti, and in doing a tenotomy of the internal rectus we do something which is rational and scientific. In many cases of hypermetropia I try the effect of glasses, to see what full correction will do without tenotomy, but as a rule I do not delay tenotomy.

THE EXTRACTION OF METALLIC FRAGMENTS FROM THE VITREOUS CHAMBER.

BY S. D. RISLEY, M.D.,

PHILADELPHIA, PENN.

The recent visit of Professor O. Haab of Zürich to the United States has awakened a renewed interest in the giant Electro-Magnet devised by him for the extraction of iron and steel particles from the interior of the eye. Those members of the profession who enjoyed the opportunity of hearing his own eloquent presentation of his methods and the analysis of his results in 165 cases must have been impressed by his skill as shown in the large percentage of successes, and incidentally by the great value and importance of extended experience in the employment of his powerful instrument. The time, therefore seems opportune for a discussion of the relative merits of extraction by the giant magnet, and the methods heretofore more generally in use in this country by aid of weaker instruments as represented by the Hirschberg magnet.

That a more powerful apparatus is often desirable had found expression in the more efficient instruments devised by Dr. Lippincott, Dr. Johnson, and Dr. Sweet, all members of this society. It remains to be seen whether a more extended experience will not demonstrate that these instruments when employed in conjunction with our modern means of determining

both the size and exact location of the metallic body, are to be preferred to the giant magnet, in the routine of practice, because of their portability, practical efficiency, and greater safety. The claim of the giant magnet to superiority must rest alone upon its greater power, while its size and weight, and the powerful electric current required to energize it, will always present the disadvantage of a fixed position, which requires that the eye of the patient must be approached to the magnet. It loses, therefore, the advantage of portability which permits a more ready control of the force employed and of the line of direction of the traction exerted upon the foreign body.

The principles which should guide us in the discussion of the modes of extracting metallic particles from the vitreous chamber may be set forth more briefly with a few illustrative cases as a basis for study. For this purpose I have selected four typical examples, all occurring at my Wills' Hospital clinic in Philadelphia. A much larger number could be brought forward were it necessary for my present purpose.

CASE I. David Fox, aet. 26, blacksmith. Foreign body in vitreous of left eye. While at work at his anvil on the morning of Aug. 2, 1901, he received a fragment from his hammer head in the left eye. I saw him at the Wills' Hospital three hours later and found a small penetrating wound exactly at the temporal corneal limbus on the horizontal meridian. The media were transparent, the pupil was slightly distorted or flattened at the temporal side, and the corresponding portion of the iris did not react to light and shade, possibly from injury to its periphery in the region of the penetrating wound, but no break in its continuity could be demonstrated. There was a faint irregular line at a corresponding point in the pupillary space, apparently a crack in the anterior capsule, but the lens was transparent. The pupil dilated widely under cocaine and atropia. The ophthalmoscope, with +6 D., the eye being turned strongly downward, revealed a glistening metallic body lying deeply in the eye ground, apparently oblong in form, with a quadrate end projecting backward along the vertical meridian, the forward end

being lost to view in the lower ciliary region. Vision, O. D.= 6/VI. O. S.=6/XXIV. Immediate operation was advised. Ether was administered, the ball seized with fixation forceps, turned strongly upward, and a meridional incision 6 mm. in length made with a cataract knife, parallel with and along the estimated temporal border of the inferior rectus muscle, beginning near the equator of the ball and carried forward. The point of the knife was fine and sharp and was made to enter the ball vertically to its tangent at the point of entrance in order to avoid as far as possible any danger of pushing the choiroid and retina before it. A small bead of vitreous immediately presented, but there was no visible hemorrhage, as both cocaine and a solution of adrenal chloride, 1-5000, had been instilled before the section was made. The short tip of the Hirschberg magnet was then introduced just within the lips of the wound and the current turned on. It was allowed to remain a moment and then withdrawn with the particle of metal clinging to it. There was no reaction following, and the patient was discharged from the hospital on the tenth day, the eye at no time having suffered any pain or shown any considerable injection. V.= 6/VII. The media were transparent, the rent in the capsule having closed immediately, and there was no notable external scar at the site of the operation for extraction. There was a small white cruciform scar at the site of the foreign body in the fundus, surrounded by a few pigment masses. The hemorrhage, if any, from the incision in the choiroid and retina was at no time demonstrable. The patient has returned from time to time as an out patient, but vision was unimpaired and the eye remained well. There was at no time any evidence of retinal separation or vitreous opacities which might produce it.

CASE II. Fred Neidhart, aet. 31, came to Wills' Hospital Aug. 14, 1901, with a note from his physician, Dr. Seiple of Allentown, Pa., stating that on Aug. 3, 1901, eleven days previously, he had received a piece of steel in his right eye. He had been treated with atropine and cold compresses. V.=6/LX. The wound of entrance was 3½ mm. in length, vertical in direc-

tion, 5 mm. from the inner and upper quadrant of the corneal limbus. The lens was transparent, but there were vitreous opacities and the location of the foreign body could be made out as an opaque splotch, anterior to the equator in the upper and inner quadrant of the globe. The man was admitted to the house, ether administered, the wound of entrance reopened and enlarged upward and backward, and the tip of the Hirschberg magnet introduced and projected slightly in the direction of the known locality of the foreign body. When withdrawn the foreign body was found lying in the lips of the wound and was removed. There was some reaction following, which slowly subsided under cold and atropia, and the man was discharged from the hospital on Sept. 6th with V.=6/XXI. He returned as an out patient from time to time, but had no further trouble. There was a stellate white scar visible with the ophthalmoscope in the vicinity of the scleral puncture.

CASE III. J. C., aet. 29, carpenter, Wills' Hospital, Nov. 29, 1901. On Nov. 27th a fragment from his steel chisel struck the right eye, entering through the cornea on the horizontal meridian just to the nasal side of the corneal pole. The wound of entrance was linear and about 2½ mm. in length. The lens was swollen and opalescent; a portion of the upper nasal quadrant of the pupillary rim of the iris had been torn away, leaving a ragged, incomplete coloboma. There was no reflex from the fundus, the vitreous probably being discolored by blood. The approach of the magnet to the ball caused pain. The man was sent to Dr. Wm. M. Sweet for a skiagraph, who reported the presence of a foreign body 1 x 2 mm. in size, situated 7 mm. above the horizontal plane of the ball, 8 mm. back of the pole of the cornea, and 8 mm. to the nasal side of the vertical plane. Fig. I. The patient refused operation until Dec. 2d. He was then admitted to the hospital, etherized, and a meridional section made over the indicated site of the foreign body, which was withdrawn upon the tip of a Hirschberg magnet. Ice compresses were applied at once, but there was no reaction, and two days later the eye was nearly white. Two months later there

had been no pain or trouble of any kind. The lens was partially absorbed and V.=1/25. There was no evidence of retinal separation.

CASE IV. Wm. K., aet. 28, laborer. Sent by Dr. Work of Bethlehem, Pa. Came to Wills' Hospital Dec. 27, 1901, and stated that he had been struck in the right eye by a piece of steel on Dec. 23d. The pupil was 4 mm. in diameter, but the eye had been treated with atropia and cold compresses.

There was a vertical linear scar on the vertical meridian of the cornea 3 mm. long, extending to the limbus. The lens was transparent except a gray, snow-flake, posterior polar opacity which did not appear to be traumatic in origin and may have been present before the entrance of the foreign body. No satisfactory study of the fundus could be made, due apparently quite as much to vitreous haziness as to the polar cataract. There was marked ciliary injection, and chemosis of the conjunctiva at the temporal aspect of the globe. V.=6/48. He was sent to Dr. Sweet for a skiagraph, who reported a foreign body 19 mm. back of the pole of the cornea, 9 mm. below the horizontal plane, and 2 mm. to nasal side of the vertical plane, and sent the accompanying diagram. On Dec. 30, 1901, under general anaesthesia, the ball was rotated strongly upward and a Graefe knife inserted behind the equator of the globe at the nasal border of the inferior rectus and a meridional section made 5 mm. in length. The short tip of the Hirschberg magnet was introduced, just within the lips of the wound, allowed to remain a moment and was then withdrawn, leaving the foreign body in the wound, which was then picked out by a second application. There was no reaction until 36 hours later, when pain, due to a smart irido-cyclitis, developed, which rapidly subsided under local blood-letting, cold compresses, and atropia. Six days after the extraction the polar opacity remained unchanged, but the patient said his vision was clearer. The man was discharged from the hospital on Jan. 24, 1902, with the eye free from infection. A dull view of the fundus could be had with the indirect image showing a linear scar at the site from which the foreign

FIG. 1.

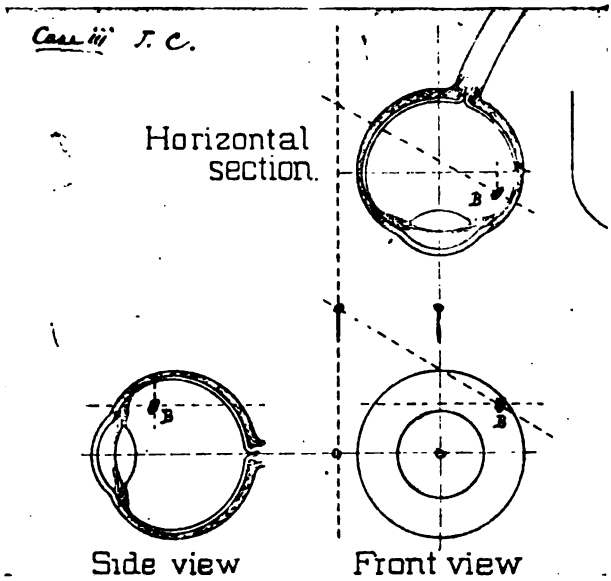

B. Foreign body, size 2x1 mm.
Situation 8 mm. back of center of cornea.
7 " above horizontal plane.
8 " to nasal side of vertical plane.

FIG. 2.

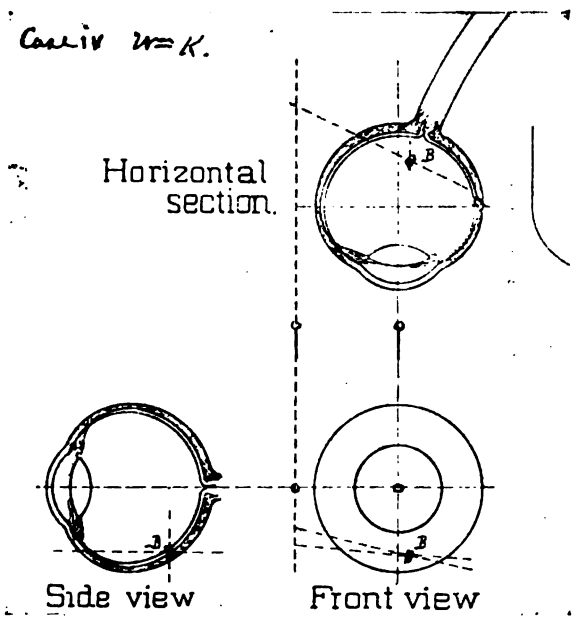

B. Foreign body, size 2x1 mm.
Situation 19 mm. back of center of cornea
9 " below horizontal plane.
2 " to nasal side of vertical plane.

body had been removed, surrounded by a maroon colored band, evidently the remains of a choroidal hemorrhage.

It will be observed that in all of these selected cases the exact location and in two of them an approximation of the mass of the fragment of metal was known, in two of the cases by ophthalmoscopic examination, while in the others it was located with great precision by my friend, Dr. Sweet, as set forth in his skiagraphic diagrams. Without this knowledge of the location of the foreign body the methods pursued for their removal would not have been practicable.

Before the discovery of the skiagraph the method pursued would have been feasible only for the comparatively rare cases where the foreign body can be located with the aid of the ophthalmoscope or possibly by the sensation of pain produced when the tip of the magnet was made to approach that part of the globe contiguous to the metal fragment. Since modern science has made it possible to localize these bodies with such exactitude any discussion of the subject is not complete which fails to recognize this as an important factor.

A number of questions present themselves for consideration. In each of the cases reported above it is probable that the giant magnet would have drawn the foreign body forward through the vitreous body, the suspensory ligament or zone of Zinn, and so onward through the posterior into the anterior chamber. Once in front of the iris a corneal section could have been made for its final extraction. There can be no question, I think, but that this method would have been better than to have made a scleral wound at random, through which the tip of a feeble magnet could be inserted more or less deeply in the vitreous to blindly search for a piece of metal supposed to be present somewhere in the vitreous chamber. The problem before the surgeon is, however, quite a different one, when not only the presence of the foreign body is known, but its exact locality and approximate size. The questions, therefore, which remain to be solved by the surgeon are of a different import and cluster about the relative amount of injury likely to be done to the eye by the dif-

ferent procedures which may be adopted for the removal of a foreign body, the presence and exact location and size of which are known.

The procedure employed in each of the four cases presented was practically identical, viz.: a scleral puncture at the known site of the foreign body, the shallow insertion of the tip of a relatively weak magnet, and the successful withdrawal of the fragment. Fortunately the result was all that could have been expected in each case. Now it cannot be denied that certain definite dangers cluster about any surgical procedure which involves an incision through the sclera, lamina fusca, choiroid, and retina. In the first place it opens the eyeball, which is always to be deprecated as a possible source of infection. A bead of vitreous usually presents, and this together with the hemorrhage which must follow the cutting of the choiroidal vessels may interrupt the subsequent processes of repair in the retinal wound by flowing between the retina and choiroid, and so cause a retinal detachment. In any event, however favorable the healing may be, there will be a scar and therefore a circumscribed blind spot at the site of the wound. It is true that these dangers may be reduced to a minimum by aseptic precautions and by a small, always meridional, incision, that is to say, an incision parallel with the direction of the choiroidal and retinal vessels, which will reduce the hemorrhage to a minimum as compared to an equatorial section which would cut across these vessels. Then, too, a meridional scleral wound gaps less than when made equatorially. In no case, notwithstanding the theoretical dangers mentioned, have I seen any considerable hemorrhage or any detachment of the retina. It is worthy of inquiry whether these probabilities of permanent injury to the eye which have been enumerated are greater than those presented by extraction through the anterior chamber with the aid of a sufficiently powerful magnet. In Case I, for example, the most favorable of the group for this procedure, since the injury was recent and the foreign body could not therefore have been fastened in situ by inflammatory products, there can be no question but that the giant magnet, placed

near the pole of the cornea, would have drawn the fragment into the anterior chamber if manipulated with skill, on a tractable patient. The fragment of steel was lying in the bottom of the eye and resting on the retina just back of the ciliary processes. The magnet, therefore, must have dragged it with its sharp and ragged edges forward through a hitherto uninjured portion of the vitreous over the ciliary region and through the suspensory ligament or zone of Zinn, thence through the posterior chamber between the iris and lens, necessitating its gliding over a portion of the delicate anterior capsule of the lens before emerging into the aqueous chamber. On the way there would be danger of entanglement in the ciliary processes or the posterior surface of the iris or of injury to the lens capsule. But once safely through these possibilities it would remain to make an opening in the cornea for its final delivery. This would involve the opening of the ball, the emptying of the anterior chamber and the dragging of the foreign body away from a close imprisonment between the iris and cornea and the consequent traumatism to these tissues, not to mention the possibility of hernia of the iris or anterior synechia during the process of repair. Added to these considerations is the additional possibility of the foreign body having been impure so that the dangers of infection would have been greatly enhanced by its progress through a new and hitherto uninjured pathway through the tissues. In cases two, three, and four an additional factor was introduced. The foreign body had been present long enough to become fastened to the retina by inflammatory products. It is probable that to have dragged these away from their attachments would have endangered a retinal separation and hemorrhage quite as much as a meridional section through the sclera at the site of the foreign body.

These are questions which it is probable can be decided definitely only in the light of extended experience, but which have seemed to the writer of sufficient importance to be presented to the Society for consideration.

This much, however, may be said by way of conclusion, that,

in the present state of our experience, in absence of definite knowledge as to the presence or exact location of the metallic fragment, the powerful giant magnet is an invaluable aid, but that, given the knowledge afforded by the skiagraph, in exactly localizing the foreign body, the less powerful instruments are efficient, less costly, and more convenient in the daily routine of office and hospital practice. It remains to be shown by extended statistics which procedure will best conserve the integrity of the eye.

DISCUSSION.

DR. HERMAN KNAPP. — Dr. Risley has presented a number of cases which show the utility of the small magnet distinctly. The small magnet is useful in those cases where the foreign body can be located definitely with the ophthalmoscope, the siderоscope, or the X-ray. For several years I have used the Haab magnet preferably, and have resorted to the small magnet only exceptionally, as the primary success was repeatedly seen to be followed by detachment of the retina. It is known that after perforating injury to the sclerotic it is two years at least before we can say that there will be no detachment of the retina. The cases may not show reaction at first, but will do so later, as the detachment of the retina forms slowly. The method of getting foreign bodies out of the vitreous into the anterior chamber is successful in many cases, and where it is so the results are ideal. I have had a number of them and my son has had several of the same kind. I have followed the method Haab described three years ago. The method is especially adapted to foreign bodies in the vitreous that are not very large. The magnet should be applied to the center of the cornea when you do not know the location of the foreign body, and then carried gradually downward. As soon as you see a bulging you know the foreign body is there. Then placing the magnet higher up, the foreign body moves up and comes through the pupil. If the foreign body does not move I make the incision into the cornea and iris where the latter is bulging. In the cases where the foreign body does not injure the iris and ciliary body, you cannot notice, in a few weeks, that anything has been done. Injury to the sclerotic is always dangerous, and I can recommend the above method, based on a good deal of experience. If you do not know the location of the foreign body use the X-ray, but when

the patient comes to you fresh put him before the magnet and very frequently it will be found that nothing else is necessary. When you put the magnet to the apex of the cornea you cannot do any harm. You only have to try this method to be fascinated with it.

DR. C. J. KIPP. — I would like to call attention to a method of extracting a foreign body that has become entangled, as it often will, in the iris. It is based upon the idea of changing the polarity. If the body has been drawn from the posterior chamber and becomes entangled you can change the polarity of your magnet and thus swing the foreign body around. With small particles you can do this without any difficulty at all. I have succeeded in that way in several cases in which no other method would do. I did it with one of the largest pieces I have had, a piece of iron three-fourths of an inch long. It became entangled and I could not move it, but on resorting to the change of polarity I found that as soon as I changed the pole the piece swung around and the other end came into the wound of entrance. I believe with the Haab magnet I can extract any piece of iron where the case is seen fresh. I have given up the use of the Hirshberg magnet, as in nearly all cases it has produced detachment of the retina. I do not know whether detachment will follow the use of the Haab magnet or not, as we have not been observing its effect long enough to say.

DR. PETER A. CALLAN. — The skiograph sometimes fails us, and so does the Haab magnet. I would like to speak of two such cases, one reported by Dr. Hepburn and one by myself, where the foreign body occupied this particular location (illustrating on the board). In both these cases the foreign body was behind the zonula, between the ciliary processes and periphery of the lens. When each eye was examined after enucleation the foreign body was found embedded in a mass of exudate. This in all probability accounted for the negative action of the magnet, especially as the foreign bodies were very small. My case gave no reaction whatever to the Haab magnet. At first I used Johnson's magnet, twenty-four hours after the injury. Then I brought him to the infirmary and tried the Haab magnet, but got no reaction. In another case there was no result with the Haab magnet, no pain, no drawing sensation, and no bulging. It was only when the eye was carefully depressed and the magnet placed back here where the foreign body was that the eyeball,

you might say, almost jumped out of the orbit. The lens was clear, but the vitreous filled with opacities.

Dr. B. L. Millikin. — I have been using the Haab magnet for three years and have had an experience with a considerable number of cases of foreign bodies, but I have not been able to get with the Haab magnet anything like the ideal results mentioned. I have come to look upon the reported effect of the magnetic current as somewhat mythical. I have in mind one case operated on by me more than a year ago, where the foreign body could be seen in the sclera, just outside the macula. The use of the magnet externally gave no result, though the foreign body could be seen distinctly with the ophthalmoscope. The sclera was then opened in front of the equatorial region externally, and the end of the magnet introduced between the lips of the wound and with no effect upon the foreign body at all. It gave no evidence of pain, drawing, or bulging. The wound was closed, the eye recovered from the operation, and in ten days we could see with the ophthalmoscope the foreign body distinctly in situ. The magnet was again applied in front of the eye and the body was seen to float up into the central portion of the vitreous, not rapidly, but with a very slow, oscillatory movement. A small section was then made at the site of the former wound with a Graefe knife, fixation forceps were introduced, and the foreign body attached itself to the forceps and was withdrawn. The wound healed up, the man left the hospital in two weeks, and had vision of 6/12. The ophthalmoscope shows changes in the eye ground where the foreign body had rested. This case gave me a new idea of the effect of the magnetic current, and I have come to look upon the possibility of a foreign body being drawn through strong structures as somewhat mythical. I do not believe the magnet has yet been invented that will draw small foreign bodies through tough fibrous tissue.

I had another case of similar character where a piece of metal passed behind the ciliary region, in which the magnet was used in the same way and the foreign body was immediately removed, without difficulty, and the man made a good recovery, with normal vision. No scotoma can be made out. Of course, the method that Dr. Risley has indicated is an ideal one, but, as Dr. Callan has said, our X-ray apparatus is not always in good working order. I think the Hirshberg magnet is indicated in the class of cases Dr. Risley has spoken of, but can see

no contraindication to the use of the larger magnet in the same cases.

DR. C. H. WILLIAMS. — One point that should be borne in mind in the use of the large magnet is the position of the foreign body. If you have applied your strong magnet here (illustrating), then when the current is turned on the body immediately takes a position in line with the traction, and will be drawn in that line towards the magnet. It does not come side on, but end on, and I doubt much if the changed polarity that Dr. Kipp speaks of would affect it, for though you change the polarity of the magnet you do not reverse the foreign body.

DR. KIPP. — I have tried the experiment sufficiently often, and you can see the foreign body turn.

DR. KNAPP. — When I said apply the magnet to the center of the cornea I meant on general principles. Of course, if the foreign body is back here you would not do so.

DR. E. E. HOLT. — I have tried to keep run of the series of cases I reported some years ago, and if there has been any trouble from the incision through the sclerotic I have failed to observe it. It has always healed with a linear scar. In the first series I reported, in nine out of twelve I was not able to locate the foreign body, but I opened the eye in the outer inferior quadrant and was able to extract the foreign body quite as easily in cases in which I did not know its location as in those in which I did.

We should give Dr. Bradford of Boston credit for devising this magnet, as he published his paper before Hirshberg.

DR. KNAPP. — I do not think that is correct. Hirshberg had made modifications of his magnet many times before.

DR. O. F. WADSWORTH. — When Dr. Haab was here he visited the Infirmary in Boston. It so happened that there were two cases there on which he was able to use his magnet, and it was very interesting to see his manipulation. One foreign body was drawn out, as Dr. Knapp has described, through the pupil. In the other case the search for the detection of the steel was not successful. It could not be positively determined that there was any steel in the eye. He applied the magnet closely in a great variety of positions. One thing he did that was new to me:

He placed the magnet in position and then had the full current turned suddenly on, so that the power was applied with a jerk, as it were. He seemed to think that was very effective in certain cases.

DR. CALLAN. — That is the way I did, and with no response whatever.

DR. S. D. RISLEY. — I call attention to the fact that my paper claims only to be discussion as to the relative merits of the different procedures mentioned. There is no expression of opinion even as to which is best. This must be left to a more extended experience in the newer methods. The results secured under the older methods which have been mentioned by Dr. Knapp are not comparable to the experiences gained since the discovery of the modern localization of metallic particles by the skiograph. That detachment of the retina would follow any procedure which involved a more or less blind fishing in the vitreous body with a pair of forceps was to be expected. But it is quite different when the vitreous body is not penetrated by the magnet. In the group of cases reported the only one which exhibited any reaction was when the tip of the magnet had been made to enter the vitreous chamber.

THE VALUE OF PARTIAL RESECTION OF THE TARSAL CARTILAGE IN THE OPERATIVE TREATMENT OF CONGENITAL PTOSIS.

E. C. GRUENING, M.D.,
NEW YORK CITY.

I have performed seven operations according to this method, and have been successful in every case. The operation is simple and practical. If we wish to shorten a leg we have to cut out a piece of the bone, and if we want to shorten the lid we shall have to remove a part of the cartilage. The removal of so much of tarsal cartilage as may be necessary for the freeing of the pupil is the principle followed.

A young man, 23 years of age, came to me two years ago. I had performed an operation on him for ptosis when he was ten

years of age. The operation, though a combined one — the Graefe and what is now called the Eversbach operation — was not successful. He was now desirous of marrying a girl who objected to his ptosis, and he was consequently miserable. I had exhausted my resources, and then thought of this method and told him I would make the experiment with his assent. I found that the difference in the length of the two upper lids was 6 mm., the cornea of the ptosic eye being covered by 6 mm. of lid. I proceeded in the following manner: I made an incision through the skin and muscle of the upper lid, parallel with the free border of the lid, and at the distance of 3 mm., and exposing the whole of the tarsal cartilage cut out a piece of it, measuring 2 mm. at each end and 6 mm. in the center. Both needles of a doubly armed silk thread were then passed through the orbito-tarsal fascia and through the edge of the upper lid behind the lashes. Three such sutures were employed. They were knotted at the free edge of the lids, and the lips of the wound in the cartilage were thus brought in opposition. I also united the skin wound by silk sutures. I think, however, that the suturing of the cartilage and the lids is not important. The operation is practically completed when the cartilage has been removed. The result in this case was immediate. The cornea was free. In four days I removed the sutures and the patient remained well.

On looking over the article on operations on the lids that Dr. Harlan wrote for the System of Ophthalmology, edited by Norris and Oliver, I found that Gillet de Grandmont had written a paper in the Recueil d'Ophthalmologie for 1891 on the same subject. He does the operation somewhat differently, but the principle is the same, and to Grandmont belongs the priority in the use of this method. He measures the difference in the length of the upper lids from the upper edge of the eyebrow to the free edge of the upper lid, and removes as much tissue from the cartilage and the orbito-tarsal fascia as may be necessary to equalize the lids. He does not confine his operation to the cartilage, as I did in my cases, but removes the upper edge of the tarsus together with as much of the tarso-orbital fascia and the levator

muscle as he may find requisite. He sutures the fascia and the cartilage with catgut. His results have been satisfactory. Here is a photograph of a boy fifteen years of age who had double congenital ptosis and epicanthus. He could not raise his lids by the action of the levator. When he used his frontal muscle and threw his head back he could free the pupils sufficiently to see a little. On this boy I performed the operation. His ptosis is cured. His appearance is changed. He opens his eyes without wrinkling his forehead, and there is a decided improvement in the epicanthus.

DISCUSSION.

DR. T. R. POOLEY. — I feel under great obligation to the doctor for bringing forth this operation. All my attempts with the Graefe and Pannas operations have been disappointing, and it is my desire to take the first opportunity of trying this operation.

DR. G. C. HARLAN. — I called the attention of the Society to this operation several years ago, and stated that I had performed it a number of times and found it very satisfactory. Dr. Oliver had also performed it several times with equally good results. It is not even necessary to dissect out the cartilage. It is sufficient to put a spatula under the lid and cut through all the tissues.

DR. W. F. MITTENDORF.— Could these patients close the eyes?

DR. GRUENING. — Yes, perfectly.

DR. S. B. ST. JOHN. — I have had some experience with a method suggested by Dr. Ferguson, which has the advantage that no disfigurement of the patient follows. The incision is made over the orbital ridge about 1½ inches in length; then by dissecting up under the scalp you get a piece of the frontalis and cut it off and run the end of that down between the skin and the tarsal cartilage and fasten it by sutures close to the margin of the lid. I have done it in one case with perfectly satisfactory result.

ACUTE CIRCUMSCRIBED EXUDATIVE CHORIO-RETINITIS.

BY HARRY FRIEDENWALD, A.B., M.D.

(*With one drawing.*)

It is with some hesitancy that I bring before you an account of the clinical history of a not uncommon form of choroiditis, — of the most common form of acute choroiditis. I am led to do so by the very meager descriptions which I have been able to find in our literature. Indeed most of the text-books and hand-books do not give the disease even a passing notice, and I have looked in vain in all the important atlases of ophthalmoscopy and have only found a single illustration of the disease, and this in a complicated form.

The best description of the disease that has been given is to be found in A. Hill Griffith's chapter in Norris & Oliver's "System of Diseases of the Eye," under the heading "Choroiditis with Descemetitis." He writes: "The disease is ushered in by sudden dimness of vision in one eye, which shows, on close examination, a greater or less number of very fine, gray, dust-like opacities on Descemet's membrane. There is complete absence of all external signs of inflammation, the iris is healthy, and the pupil is normal and quite active.

"In the neighborhood of the disk is found a single, recent, opaque white or bluish-gray patch of choroido-retinitis, shading off gradually at its circumference into the healthy fundus.

"Very rarely there may be two patches close together and evidently of similar duration, or a recent patch may be continuous with an old pigmented spot, in which case we may elicit a clear history of an apparently similar attack years before. Fine vitreous opacities are sometimes seen near the choroidal disease, or a long string of lymph may extend into the vitreous from the edge of the patch. If the choroidal patch is continuous with

the disk, the real condition may for a time be masked by a papillo-retinitis. The dots on the back of the cornea fade away rather quickly, the choroidal patch becomes converted into an atrophic area, with exposure of the choroidal vessels and pigmentation, and normal vision is frequently regained.

"I hold that the dots on Descemet's membrane are in these cases formed in the choroid, set free in the vitreous, and carried by the nutrient currents of the eye to be deposited on the back of the cornea, which view necessitates the permeability of the suspensory ligament by solid particles.

"The patients have all been young adults, the female sex largely preponderating. I have seen between forty and fifty cases; syphilis has never been present, so far as I could make out, although ozena has not infrequently been noted; tuberculosis or a tubercular family history is very common, and my treatment has been based accordingly."

Frost, in his "Fundus Oculi," speaks of the disease in the following manner: "A variety of choroiditis in which retinal œdema is a prominent feature occurs in association with isolated patches of old choroidal atrophy. The subjects of this affection are usually young adults of sedentary habits and anæmic aspect. The condition has no connection whatever with syphilis, but a family history of tubercle can often be elicited. In the course of a few weeks the œdema clears up, and there is exposed to view a patch of partial or complete atrophy of the choroid."

At the recent meeting of the Ophthalmic Section of the American Medical Association, Drs. G. E. de Schweinitz and Hiram Woods reported cases of this disease, and the writer discussed the affection in its relation to keratitis punctata interna or descemetitis. As the papers of the two gentlemen just mentioned have not yet been published I shall not be able to refer to them.

The cases upon which the following paper is based were seen during the past twelve years, and comprise 38 active cases, more or less fresh, and of quite a number in the atrophic form. But,

as doubt may be expressed by some as to the proper interpretation of the latter, I have based my description entirely upon the fresh cases.

The age of the patients varied from 17 to 50, the average being $27\frac{1}{4}$; only 4 were over 35 years of age and 8 over 30 and less than 35. The great majority (26) were 30 or under. But I am of the opinion that the age limit is much lower than 17, for in many of the younger patients there was evidence of previous attacks which had passed unnoticed by the patient: I am inclined to place them in early childhood or in infancy.

Of the 38 cases 20 were female and 18 males. These numbers are small, but they indicate that there is no marked preponderance of the female sex.

In 20 cases the left eye was alone affected, and in 12 the right, and in 5 both eyes.* In one the side is not mentioned.

More than half the patients were seen in private practice. Etiology: Syphilis has certainly no etiological bearings; it was admitted in but a single case, though inquired into in almost all. A history of rheumatism was found in one case; slight albuminuria was found in one. One patient attributed the affection to malaria, subsequent anæmia and slight amenorrhœa. Two of the patients observed the affection arise after parturition, in one case ten months afterward. The grippe may have been an etiological factor in two cases, but in one of these the attack was found to be a recurrence. One patient claimed that the disease followed a severe cold, and in another the affection began two months after an attack of typhoid.

There was aortic insufficiency (with marked retinal arterial pulsation) noted in one, "valvular cardiac lesion" in two cases.

One patient ascribed the condition to exposure to electric light, and trauma bore a definite relation in two cases; in one the affection was noticed two weeks after the eye had been struck with a nail, and in the second there was a recurrence a week after a severe blow in the eye.

---

* In one of the last-mentioned the left eye became affected while the right was under treatment.

Inquiry was made in most cases as to constipation, but this was rarely found. Chronic nasal affections were likewise not found, and not a single patient had ozena. One patient who had had muscæ volitantes since childhood showed a recurrence after having lived in Cuba and suffered from fever, followed by constipation and slight transient albuminuria. A number of the patients were sent to a clinical laboratory for examination of the blood, but in each case the result was negative.

In more than half nothing bearing on the etiology was suggested by the patient or could be elicited by careful inquiry. Indeed on the whole these patients appeared quite healthy, and tuberculosis was not found in a single case.

Appearance. The disease manifested itself as a whitish, bluish white or grayish white circumscribed effusion, most resembling a cloud,* rapidly fading into the normal fundus.

Its situation is varied. In ten cases it was close to or directly connected with the optic disk; in thirteen within or very near the macula lutea. In sixteen of the cases the lesion was in the periphery (this includes three cases which were within four P D of the optic disk); in most of these cases the location was in the outermost periphery, frequently near the limit of the ophthalmoscopic field. Griffith describes his cases as all occurring "in the neighborhood of the disk." In our cases this location was found in only one-quarter of the number.

The size of the lesion was in some cases less than that of the disk, but in the great majority it was three, four, or five times this size. In most cases the effusion completely obscured the retinal vessels. In five cases there were a few small pigmented or atrophic choroidal spots near by or in the periphery of the fundus affected, and in one case in the fundus of the other eye.

In fourteen cases the attack was a recurrence of inflammation at the site of a large atrophic choroidal spot; in a few of these the inflammation was within the area, but in most it was at the margin of the old lesion. In twenty-two cases the affection was a fresh inflammation without any evidence of previous disease at or about the region involved. In two cases the opacity

* Frost describes this as retinal œdema.

of the media was so great that the choroidal inflammation could not be observed until a very late stage, and it was impossible to determine this question. This does not accord with Frost's view that this disease always "occurs in association with isolated patches of old choroidal atrophy."

Opacities of the vitreous are always to be found in these cases during the entire course; they are slow to disappear after the choroidal effusion has been entirely absorbed. These opacities are for the most part fine and dust-like, but larger opacities and threads also form. The larger opacities and threads are often found directly connected with the choroidal lesion.

The corneal opacities are of the form of keratitis punctata interna or descemetitis. They are seen a few days after the onset of the affection, at first as the finer variety. Later, larger deposits appear, usually arranged in triangular form. These in rare instances may become so great as to cover the entire cornea and for a long time prevent any inspection of the fundus. The fine deposits are the first to disappear, frequently after a few weeks. The cornea usually clears up entirely, long before the choroidal lesion passes into the atrophic stage. These opacities are found almost constantly. In this series they were noted in 31 cases; in four the patient was seen too late, and they had probably disappeared; in one the pupil was too small to make a careful examination.

It was Hill Griffith, as we have seen, who first called attention to the almost constant association of this sign with this form of choroiditis.

Course. The course is usually typical. The inflammation makes its appearance very suddenly, rapidly reaches its greatest intensity (usually within a few days), remains at this point for a variable time, and then slowly declines and leaves behind it an area of choroidal and retinal atrophy and irregular pigmentation. Brilliant crystals sometimes appear on this surface. This area is smaller than the area previously occupied by the cloud-like effusion, a fact that indicates that this is in part œdema.

The duration of the process varies greatly. The shortest

period was one month, but most cases required two to six months and many a still longer time.

The affection shows a great tendency to recurrence; in the 38 cases here reported 14 were seen as recurrences and in another seen during the first attack a recurrence at the same location was witnessed six months later. In several cases there was a history of repeated recurrences.

COMPLICATIONS.

Optic Neuritis. One of the most serious complications is optic neuritis. This sometimes occurs when the lesion is adjacent to the optic disk. It is this condition which is pictured in Haab's illustration No. 55 A.* It was observed in two of our cases; in both of these the intensity of the inflammation was very great.

Vascular Changes. In three cases, in all of which the seat of the inflammation was below the macular region along the course of the inferior temporal vessels, a rare form of perivasculitis was observed. This involved chiefly that portion of the artery between the disk and the seat of the choroidal lesion; but in one case the superior temporal artery was likewise affected. (See drawing.) The vascular affection consisted in numerous white spots arranged along either side or upon the surface of the vessel. I do not remember having observed this peculiar small form of vasculitis under other circumstances.

In another case (that mentioned under the heading glaucoma) there was great congestion and tortuosity of the retinal veins. These showed contractions of their caliber at numerous points, many of the smaller veins disappearing entirely for short distances and then reappearing. This condition was found in all the veins throughout the fundus. The patient was examined a long time after the inflammation had disappeared, and not a single such contraction could be found.

In one case marked narrowing of the artery was observed

* See Atlas of Ophthalmoscopy, first edition.

RIGHT

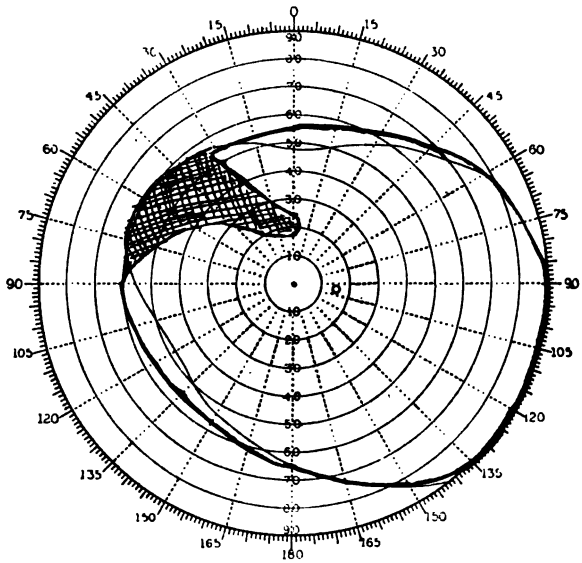

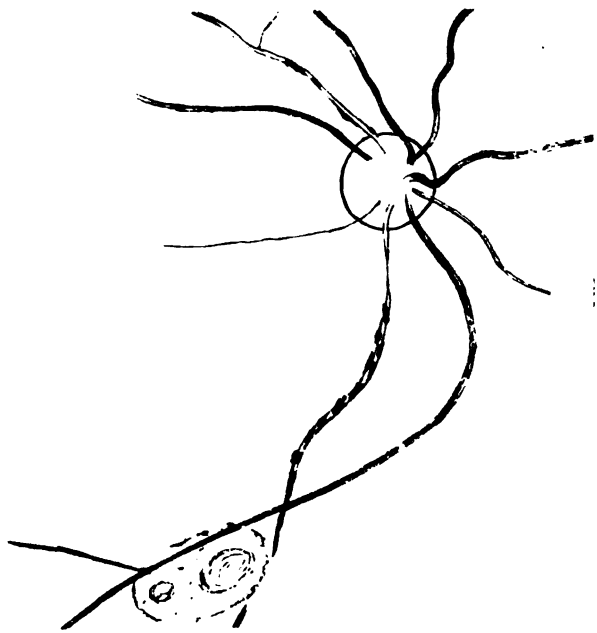

as it entered the affected portion; but this was after the atrophic stage had come on and was probably secondary.

Hemorrhages of the Retina. In one case a few very small hemorrhages were found near the choroidal lesion. In a second (mentioned under the heading optic neuritis) there were extensive hemorrhages throughout the retina. But it must be remembered that in this case the intensity of the accompanying neuritis was the most marked that I have seen, and great pressure was probably exerted on the retinal veins.

Decreased Intraocular Pressure. This was observed to a slight extent in one case, in which it soon disappeared. In a second case the decrease in tension was most marked. It accompanied an intense irido-cyclitis and led to the production of the well-known corneal lines which are now believed to be folds of Descemet's membrane.

Iritis. This was seen in but two cases: in the one just referred to, which represented a very malignant form, and in a second in which it was slight.

Increase of Intraocular Tension was observed in one case, the one mentioned above as having presented the numerous contractions in the retinal veins. The increase of tension occurred during the first week of treatment. Atropine, which had at first been ordered, was immediately discontinued; eserine was substituted, and the condition disappeared.

Cataract. Slight lenticular opacities were found in one eye, in a patient who had suffered from recurring choroiditis in both. This patient was but twenty-two years of age when examined, and there is no doubt that the cataract depended upon the choroiditis.

SYMPTOMS.

The earliest symptoms are a "blurring of vision," or the appearance of a "veil," or of "specks before the sight," or of a "quivering of vision." In a number of cases these symptoms were preceded or accompanied by severe headache and sometimes by eyeache. There is rarely any pain or sensitiveness of

the eye during the further course of the disease. In a few cases there was slight congestion of the eyeball during the early stage, and in a large number there was marked congestion of the fundus.

The fundus in most cases appears hazy, the optic disk blurred; this may lead to the diagnosis of "slight neuritis"; but these appearances (excepting in the cases of optic neuritis described above) are due entirely to the vitreous and corneal opacities.

Central Vision. A. In a number of cases, especially in those in which the lesion was peripheral, central vision was but slightly disturbed, the patients complaining only of a blurring of vision. In seventeen eyes vision at the first examination ranged between 6/18 and 18/18, the last mentioned amount being noted in six cases. But it must be mentioned that many of these cases were not seen until some time after the disease had made its appearance. All of these cases improved greatly and finally obtained perfect, or almost perfect vision.

B. In ten cases vision varied between 10/200 and 25/200. In four of these which were under observation for some time, vision improved greatly. In one it rose from 20/200 to 50/200 in six weeks; in the second it rose from 20/100 to 20/30 in three months. In the third, from 10/200 to 20/24 in six weeks, and in the fourth it rose from 6/100 to 6/12 in five months, and when examined several years afterward had still further improved to 6/8.

In one of these cases with vision 20/200 there was no improvement during a long course of observation (optic neuritis), and in another with vision of 25/200 vision was finally lost entirely. (Case complicated by irido-cyclitis.) In four cases the period of observation was very short and vision did not change.

C. In eight cases vision ranged between perception of light and counting fingers at ten, twelve, or fifteen feet. In one vision equaled 8/30 at the first examination, but in a few days central vision was entirely lost; in six months the vision was as good as that of the other healthy eye, although there had in the mean time been a second slight attack at the same location.

Similar favorable results occurred in three other cases: in the first vision improved from counting fingers at fifteen feet to 20/30 in three and a half weeks; in the second, from counting fingers at three feet to 20/30 in two months; and in the third, from counting fingers at one and a half feet to 20/24 in six and a half months.

In one case vision improved from counting fingers at four feet to twenty feet in four weeks. In one case vision declined from counting fingers at twelve feet to seven feet in one week, when the patient was lost from further observation, and in one vision improved from perception of light to almost 6/60 during several months of observation; this patient is still under treatment.

Complete loss of central vision did not occur as the final result in any of the fresh cases observed. It was found in one case as the result of a previous attack in the left eye of a patient who consulted me because of a fresh attack in his right. I have seen a number of typical pigmented and atrophic patches occupying the macular region, with loss of vision, which I have no hesitation in attributing to the disease under consideration.

Micropsia was observed in several cases in which the lesion was close to the fovea; it was complained of by the patients after the process of repair was well under way.

The Field of Vision. This was examined carefully in almost every case and always showed a defect corresponding accurately with the lesion. Wherever situated the defect is outlined sharply and is absolute. When the lesion is peripheral the defect is peripheral and extends to the limits of the field; when the lesion is near the disk or macula it may produce a scotoma corresponding in form and position, or the defect produced may involve not only the corresponding part of the field, but extend with increasing breadth to the limit of the field and thus involve an entire sector. Such a sector corresponds with the course of the blood vessels. The defects produced by lesions within or very close to the macula lutea are central or paracentral scotomata.

The size of the defect in the field usually diminishes as repair sets in. This is of great importance and it accounts for the restoration of the central vision in cases with central scotoma, which subsequently become paracentral. But though diminished in size the defect in the field is permanent.

Diagnosis. The diagnosis is not difficult. The presence of keratitis punctata interna or descemetitis without iritis should lead to a thorough examination of the fundus, both in the direct and the indirect method. Much can be accomplished with saving of time if we watch the ophthalmoscopic reflex from the position of the indirect method, but without the use of the convex lens, allowing the patient to move the eye in all directions, and examining with the indirect method whenever a whitish reflex appears. The careful examination of the field of vision will often lead to finding the lesion. The lesion is so characteristic in appearance that when found a question as to its nature will rarely arise. Even with care it will often be overlooked and repeated examinations with a dilated pupil are necessary. The writer feels that in earlier years a number of cases passed through his hands as " serous iritis " or " cyclitis." In one of his own cases the diagnosis was not made until four years later, when a second attack occurred.

It is proper to state here that many of the large white or pigmented spots which are frequently seen and entered in our case books as isolated patches of choroidal atrophy are the vestiges of the disease we are considering. This statement is based upon the identity of appearance, the frequency of recurrences at the site of these patches and upon the fact that the writer had never observed the development of similar atrophic areas from hemorrhages. This statement excludes colobomata of the choroid, but it does not exclude many of the cases looked upon as coloboma of the macula. As a single illustration of many that might be given, we may take Fig. 7 of Haab's Atlas, described as " Coloboma of the Choroid on the nasal side of the disk."

Prognosis. The prognosis of the disease is good, unless the lesion produces neuritis (which occurs in about one-fifth of

those cases in which the lesion is close to the disk) or destroys the fovea (which did not happen in any of our cases in which the lesion was situated in the macula). Useful vision, and in most cases normal central vision, is restored. The malignant form, which is exceedingly rare and which includes one or at most but two of our cases, leads to loss of vision. In considering the prognosis we must not lose sight of the great tendency to recurrence of the disease.

Treatment. In ignorance of the cause of this affection the treatment adopted in our cases has been that approved by most of our authorities in various nonspecific choroidal inflammations. Eye-rest was ordered in all cases. Atropine was used locally in most. Pilocarpine and mercury were tried in a number; but the remedy administered in the great majority of cases was iodide of potassium. The writer regrets that he has been unable to find any difference between these remedies or any advantages of one over the other.

REMARKS.

The pathology and etiology of this disease are not known. The former will be difficult to establish by direct examination, for such eyes are not readily obtained for pathological examination. The study of the ophthalmoscopic image and its changes suffice to give an approximate idea of the condition.

What is most needed now is the study of the etiology, for the determination of this will aid us not only in the treatment but also perhaps in the prevention of recurrences. This appears to me the most important field for inquiry, and one purpose in bringing this subject before you is to secure more general interest and study of this question.

DISCUSSION.

Dr. C. J. Kipp. — I do not know why the doctor assumes that this subject has not interested others, as I am sure we have all followed up this disease for many years and arrived at pretty much the same conclusion. I object to two of the terms which the doctor uses: one "descemetitis" — there is no such thing,

that would mean an inflammation of Mr. Descemet — and to the term "keratitis punctata." It is simply a deposit on Descemet's membrane.

DR. GRUENING. — Since the subject has been brought up, I would say that I think we have all been acquainted with this condition for some time. We have all known exudative choroiditis clinically.

DR. S. D. RISLEY. — I am glad that Dr. Friedenwald has brought this interesting and important subject before the Society. It is quite true, as has been said, that it is not new, but it is a form of disease always interesting, and in its early stages often overlooked.

DR. HARRY FRIEDENWALD. — I am glad that Dr. Kipp has expressed himself in the way he has, because I would not like the impression to go abroad that I considered this a new disease. I said that it is most common, and yet I would like to ask Dr. Kipp for any reference to an adequate description of it, except the ones I mentioned. I think, therefore, that it is proper to call attention to a disease that has been neglected to such an extent. Furthermore, the etiology is very obscure and deserves to be studied.

As to the term "keratitis punctata" we had a discussion at Saratoga. I would prefer to have some term that would cover "deposits on the posterior surface of the cornea" and not be quite so long, but I prefer to use the old term of "descemetitis" or "keratitis punctata interna" to distinguish it from keratitis punctata superficialis. In using the term keratitis or descemetitis we are not expressing simply the idea of inflammation. I had some correspondence with Dr. A. Rose on that subject, and he informs me that the suffix "itis" doesn't express the idea of inflammatory changes alone, but that any affection whatever of a part entitles it to that suffix. By using the term "keratitis punctata interna" we do not necessarily imply an inflammation, or by "descemetitis" an inflammation of Descemet's membrane. I will be obliged if Dr. Kipp will give me any reference to this disease, as I have searched the literature extensively and found none, except those I have mentioned, and these are not satisfactory.

A CONTRIBUTION TO THE KNOWLEDGE OF OSSIFICATION OCCURRING IN THE EYE, WITH CLINICAL REPORT OF CASES OCCURRING IN THE SERVICE AT LAKESIDE HOSPITAL.

BY B. L. MILLIKIN, A.M., M.D.,
AND
JOHN C. DARBY, A.B., M.D.,
CLEVELAND, OHIO.

HISTORICAL.

Ossification of the various structures of the eye have been reported from time to time for over a century. Little consideration can be given to some of the earlier writings on this subject for two reasons:

First: In numerous cases reported as ossification the diagnosis rested upon the presence of hard masses in the eye, unsupported by histological examinations.

Second: Reports of ossific processes developing in structures of the eye which today we are confident do not occur, such as the lens, vitreous humor, ciliary body, and iris. It is to be regretted that in over one-fourth of the cases we have been able to collect from the literature there is no reference to histological examination, and that in over one-half of the cases reported nothing is said regarding the mode of development of the bone.

Pagenstecker in 1860 was probably the first to write fully upon this subject. Since then Knapp in 1871, Alt in 1877, and Goldzieher in 1880, have discussed the subject very thoroughly. Berthold (1871), Schiess-Gemuseus (1873), Hoene (1882), Fontan (1883), Ried (1892), and Webster (1901), have also touched upon the mode of bone formation in the cases they reported.

The reports of forty-nine cases have been collected from the literature, and of these in only thirty-eight is there more or less satisfactory description of the histological appearances. To

these we wish to add four more cases, making forty-two cases in all in which the diagnosis was substantiated by microscopical examination.

It can scarcely be credited, however, that this condition is not of more frequent occurrence than the literature of the subject would seem to indicate, for the four cases here reported all occurred in Lakeside Hospital service in less than one year.

CASE I. SUMMARY.

I. Clinical. Phthisis bulbi, result of injury; sympathetic irritation, tenderness of blind eye.

II. Pathological. Chronic panophthalmitis, with ossification of the organized inflammatory exudate posterior to the lens. Detached and degenerated retina. Atrophied and calcareous lens. Detachment of the choroid and of the posterior portion of the ciliary body from the sclera.

CLINICAL HISTORY.

J. K., male, aet. 25 years. Was admitted to Lakeside Hospital August 28, 1901, giving the following history: Eighteen years previously the patient accidentally stuck the point of a pair of scissors into the right eye, producing a serious wound, leading to contraction of the eyeball, a phthisical bulb. There had been no trouble with the eye until in the spring of 1901, when it became somewhat painful and teared considerably. The left eye had shown a tendency to tear with some discomfort in the cold weather during two or three winters previously. For a month before entering the hospital there had been more than usual tearing of his sound eye, with considerable pain at times. For this he went to the Eye Dispensary at Lakeside Hospital, where, under treatment, the discomfort had largely disappeared. The injured eye had been somewhat painful for several months, the pain being of a sharp, shooting character, and as the irritation of the eye did not subside under treatment he was referred to the house for enucleation. Examination showed the right eye much smaller than the left, the tension diminished, the cornea

entirely opaque, with a transverse scar across its center, the result of the old injury, considerable conjunctival reddening, tenderness on pressure, etc. The eye continued to increase in irritability until on August 31st, when, under general anæsthesia, the eyeball was enucleated. The patient made an uninterrupted recovery and was discharged from the hospital on September 7th.

The eyeball was referred to the pathological department for examination.

DESCRIPTION OF EYE.

The eye is about half its natural size, irregular in shape, and has its greatest diameter transversely. The cornea is greatly shrunken and opaque, and yellowish white in color. On palpation a hard tumor mass is felt in the interior of the eye. A median antero-posterior section reveals the sclera considerably thickened, especially posteriorly, where it is 2 mm. thick, about twice that in the normal eye. The inner surface of the sclera is yellowish white in color, and in no place does any pigment layer appear to be present. An irregularly oval mass of bone-like consistency occupies about one-half of the interior of the eye. It is attached anteriorly in a position corresponding to the posterior surface of the cornea, the free portion being of a brownish black color. This mass measures 19 x 12 x 10 mm., its greatest diameter being transversely, and least antero-posteriorly. The cut surface of the mass shows a lamellated structure closely resembling that of bone, and at its posterior portion there is a small irregularly round cavity about 4 mm. in diameter. The iris is apparently present between the mass and the posterior corneal surface, these three structures being intimately adherent, obliterating the anterior chamber. The pigment layer is very evidently attached to the outside of the mass for a space of about 3 mm. beyond its attachment to the eyeball, and then rather abruptly becomes thinned and merges into the brownish black covering of the free portion of the mass. The lens cannot be made out. The remaining portion of the eye, which formerly had been filled with vitreous humor, contained a dirty looking sero-purulent material when the eye was removed. A delicate

slightly funnel-shaped mass of tissue its base anteriorly, extends from the region of the optic nerve to the posterior portion of the tumor mass, evidently the remains of the detached retina. Microscopically the whole eye shows evidences of an old inflammation. The sclera is greatly thickened, especially posteriorly. The cornea shows marked change. The corneal epithelium is thinned in some places and in others is entirely absent. There are no evidences of recent inflammation, however. The substantia propria is almost entirely replaced by ordinary fibrous tissue like that of the sclera. The lamellated structure and the nuclei of the cells are either lost or very indistinct. One small area alone shows a dense homogeneous structure, with lacunæ containing stellate corpuscles, resembling normal corneal tissue. The inner surface of the cornea stains more deeply than the rest, but the cell structure of the endothelial lining is entirely lost. The iris is adherent to the posterior surface of the cornea throughout almost its entire length, obliterating the anterior chamber. The iris and ciliary bodies are somewhat atrophied and congested. The choroid and the lower portion of the ciliary body is detached from the inner surface of the sclera and forms a covering to the surface of the tumor mass. Here and there portions of choroidal tissue are included in the tumor mass. It is very unevenly distributed over the tumor and in some places greatly thinned. The retinal tissue seems to have entirely disappeared. Just posterior to the iris is a zone, apparently the result of a fibrinous exudate. This zone is composed of delicate fibrinous strands and contains no cellular elements or blood vessels, and is of moderately loose structure. In the center of this tissue is an irregular mass of dense calcareous tissue staining very dark blue. It is lens-shaped and evidently the remains of an atrophied calcareous lens. Posterior to this loose fibrinous layer is another or denser structure extending almost directly across the eye from the region just back of the ciliary body. This layer consists of interlacing fibrillæ supporting connective tissue cells. The nuclei of these cells are rather irregular in size, and a number of round cells are scattered diffusely through-

out this tissue. A few plasma cells are seen. This tissue is quite vascular. Many of the arteries show a well marked obliterating endarteritis and their coats show marked hyaline degeneration involving especially the media. The posterior portion of this layer is in contact with the bone and is denser than the rest of the layer and contains fewer cellular elements. There is a considerable amount of choroidal pigment here and there through this area. The osseous portion of the tumor is made up of normal spongy bone. The Haversian canals are of good size and contain blood vessels and fat tissue. The lacunæ contain typical stellate bone corpuscles. A few osteoclasts are to be seen. In a few places metaplasia of fibrous tissue into bone can be readily traced, the fibrous tissue becoming denser and less cellular as it approaches the fully developed bone. This dense tissue is largely composed of a homogeneous finely fibrillated matrix, hyaline in character, which here and there encloses spindle and stellate cells. No cartilage is seen.

CASE II. SUMMARY.

I. Clinical. Phthisis bulbi. Result of old injury.

II. Pathological. Chronic panophthalmitis, with ossification of the organized inflammatory exudate from the chorio capillaris and partial ossification of the septum. Detached retina. Partly calcareous lens.

CLINICAL HISTORY.

L. B., female, aet. 17 years. Was admitted to Lakeside Hospital May 1, 1902, giving the following history: When she was one year old the left eye was injured by being struck with a gun-cap, after which the eye was greatly inflamed and very painful. The eye was left in a phthisical condition with a large scar involving the central portion of the cornea. The eye has never given her any trouble since healing after the injury, nor has there been any evidence of sympathetic irritation. The patient desired the removal of the eye on account of its appearance, so that she might use an artificial eye. Under general anæsthesia

on May 2d the eyeball was removed. Recovery was uninterrupted and the patient was discharged on May 15th.

DESCRIPTION OF EYE.

The eye is about half the normal size, irregular and somewhat cubical in shape. The cornea is opaque. On palpation the whole posterior half of the eye is of bone-like hardness. An equatorial section of the eye reveals the sclera considerably thickened, the retina detached, except at the optic nerve and ora serrata, giving it a funnel-shaped appearance. The anterior chamber is obliterated and the iris and remains of the lens lie in close contact with the cornea. The choroid lies in its normal position in apposition with the sclera, and just internal to the former there is a shell of bone-like hardness. This shell is unequally distributed over the interior of the choroid, extending about to the equator of the eye on one side, and on the other it extends forward to the region just posterior to the lens and seems to extend for a short distance into the septum formed by an organized exudate just posterior to the lens. This hard plate is not of uniform thickness, but has a very nodular appearance, in a few places being over 3 mm. thick, though most of it is 1 to 2 mm. thick. A small hole in the bony shell is seen where the retina passes through, and is attached about the optic nerve. About one-half of the remaining interior of the eye is filled with a soft cream-colored tissue. Microscopically the corneal epithelium is somewhat irregular in width, and in a few places is absent or the cell structure lost. The substantia propria shows a slight round cell infiltration in places, and here and there a few blood vessels are seen. The cell structure of the endothelial lining is entirely lost. The sclera is greatly thickened, especially posteriorly, and there is some round celled infiltration in places. The iris and ciliary bodies show a diffuse round cell infiltration with some increase of the cellular elements. The lens is fibrous with a zone of calcareous material about it. The choroid is greatly thickened and congested, and shows a slight diffuse round cell infiltration, with an increase of the normal

cellular elements. Just internal to the choroid and apparently involving its inner layers is a tissue having a delicate fibrillated structure, supporting spindle and stellate cells, apparently a delicate fibrous tissue. In this tissue there is a shell of true bone with typical bone corpuscles in lacunæ connected by canaliculi. Here and there are small canals apparently rudimentary Haversian systems containing blood vessels and fat tissue. Internal to this layer is a portion of the retina in situ, though it is detached in most of the section and occupies the center of the vitreous chamber. The layer of rods and cones and ganglion cells seems to have entirely disappeared. The nuclear and reticular layers are more or less intact and can be traced in a large part of the section. The nuclear and reticular layers are greatly thickened, and there is a marked proliferation of the cellular elements of the nuclear layer throughout the section. Just posterior to the lens a mass of tissue extends across the eye from the region just posterior to the ciliary body. It is a direct continuation of the tissue just internal to the choroid in which the ossification has taken place and is identical structurally. Here and there throughout the section are areas of tissue situated between the bone and the loose fibrous tissue which demonstrate the metaplasia clearly. The loose connective tissue gradually becomes denser as it approaches the bone. The cellular elements become scattered and few in number, due to an increase in the interstitial tissue. This tissue becomes very dense and hyaline in character, with a delicate fibrillated structure enclosing here and there the stellate connective tissue cells. In places the branches of the cells may be seen invading the homogeneous matrix, and the whole picture resembles that of true bone with its bone corpuscles and canaliculi except for the deposition of lime salts.

CASE III. SUMMARY.

I. Clinical. Phthisis bulbi. Result of old injury. Sympathetic irritation.

II. Pathological. Chronic panophthalmitis, with ossification of the organized choroidal exudate forming a partial shell

of bone. Septum not ossified. Detached retina. Calcareous lens surrounded by organized inflammatory exudate.

CLINICAL HISTORY.

S. D., female, aet. 39 years. Was admitted to Lakeside Hospital May 22, 1902. She gave the history that at three years of age she was struck in the left eye with a stick, since which time she had been unable to see with it. From the history it would seem that the right eye must have had some sympathetic irritation afterward, as she states that for several weeks succeeding the injury she was unable to see anything clearly with it. The vision in the right eye improved slightly, so that at eight years of age she thought she was as well as ever. Until six or seven weeks before entering the hospital she had had no trouble since eight years of age. At this time she was attacked with a sharp pain in the right eye, with dimness of vision, which was continuous up to the time of admission to the hospital. Examination at the time of admission gave the following result: O. D. V.= 6/18-2. There was some redness of the conjunctiva of O. D., but no tenderness on pressure. T.=n. Ophthalmoscope showed the pupil of O. D. good size, responding promptly to light, fundus somewhat hazy, so that the details were made out with great difficulty, but apparently no marked pathological changes. The left eye showed a phthisical bulb, sensitive on pressure, with a hard feeling as though a calcareous deposit existed. The patient was sent to the hospital for enucleation. This was done on the afternoon of May 22d. The patient made an uninterrupted recovery and was dismissed from the hospital on June 2d.

On June 12th an examination of the right eye was made, the vision being slightly subnormal. With a —1.50 Ds. it was 6/12.

DESCRIPTION OF EYE.

The eye is about half the normal size, and somewhat irregular in shape. The cornea is opaque. On palpation the posterior third of the eye is of bone-like hardness. A median antero-pos-

terior section reveals the sclera somewhat thickened posteriorly. The anterior chamber is obliterated, the iris lying in close contact with the cornea. The lens is hard and apparently calcareous, lying just behind the iris. Just inside the choroid, which was in normal position, is a hard shell lining about a third of the posterior portion of the eye about the optic nerve. This shell is of fairly uniform thickness, being about 1 mm. thick throughout. A small aperture exists about the middle of this bony plate, where the retina passes through and is attached posteriorly about the optic nerve. The retina is detached except in the region of the optic nerve and the ora serrata. A portion of the vitreous chamber is filled with an organized exudate which is most marked anteriorly just posterior to the lens, where it extends across the eye like a septum, being attached laterally to the choroid just posterior to the ciliary body. Microscopically the corneal epithelium is lost in places. The substantia propria is almost entirely replaced by ordinary fibrous tissue. The endothelial lining is lost. The iris is adherent to the posterior surface of the cornea. Here and there is a well marked fibrous tissue, thickening, though the greater part of the iris is atrophied. The remains of the lens consists of an atrophied and calcareous shell which lies just posterior to the iris in a delicate tissue of fibrillated structure containing a few connective tissue cells. The ciliary body is negative. The outer layer of the choroid is very vascular and thickened in places. On the inner surface of the choroid is a layer of tissue similar to that described about the lens. This tissue covers the whole surface of the choroid in a moderately thin layer, and extends across the eye posterior to the lens as noted above. Posteriorly about the optic nerve and extending over about half the eye is a shell of bone lying in this tissue. This shell occupies nearly all of the delicate tissue previously spoken of. This bone is intersected by numerous Haversian canals containing blood vessels and fat tissue. The lacunæ and canaliculi have a somewhat definite concentric arrangement. Near the extremity of this bony shell the process of ossification is readily traced. The denser tissue with its delicately fibrillated structure is in places somewhat granular looking, always inter-

vening between the completely formed bone and the loose fibrous tissue.

CASE IV. SUMMARY.

I. Clinical. Phthisis bulbi. Result of injury. Recurring attacks of inflammation.

II. Pathological. Chronic panophthalmitis, with osseous masses in the organized choroidal exudate. Retina and lens have disappeared. Osteoid looking tissue at the base of several ciliary processes.

CLINICAL HISTORY.

Male, aet. 47. Injured O. S. three years ago. Eye sightless and he has had recurring attacks of inflammation in it at times since the injury. No symptoms of sympathetic irritation.

DESCRIPTION OF EYE.

The eye is not half the normal size. Very irregular in shape and flattened antero-posteriorly. The cornea is opaque. On palpation the posterior portion of the eye is of bone-like hardness. A median antero-posterior section reveals a greatly thickened sclera, especially posteriorly. The anterior chamber is obliterated. The iris is in close contact with the cornea, and just posterior is the shrunken lens, which appears calcareous. The choroid is in the normal position, and just internal to it is a layer of soft tissue in which is a small shell of extremely dense substance almost 1 cm. in diameter. The eye is so shrunken that the vitreous chamber is very small and almost entirely filled by this soft tissue. A mass of this tissue projects through the vitreous chamber, forming a septum just posterior to the lens from the region just behind the ciliary body. This septum becomes rapidly thinned toward the center of the eye, being broadest at its attachment in the ciliary region. No retina made out. Microscopically the corneal epithelium is lost in places. The substantia propria is entirely replaced by ordinary fibrous tissue with well marked round cell infiltration in places. The endothelial lining is lost in places, the cells proliferated in others.

The sclera is vascular and greatly thickened posteriorly. The iris is thickened and shows a diffuse round cell infiltration. The connective tissue cells are large and abundant. The vessels are markedly congested. The iris is not in close contact with the cornea, but separated from it by a layer of structureless hyaline material which is also seen on the posterior surface of the iris. The ciliary bodies show congestion and round cell infiltration. Just at the base of the several ciliary processes are small areas which are of dense finely fibrillated structure, containing no cells. The tissue stains deeply in eosin and gradually fades off into a less dense tissue containing a few cellular elements, apparently stellate fibrous tissue cells, and finally into the ordinary tissue of the ciliary body. The appearance is strikingly that of osteoid tissue, though no osteoblasts were found. No lens seen. The ciliary body has evidently been the seat of an exudate which has organized and which extends across the eye as a fibrous septum and is a direct continuation of an organized exudate evidently taking place from the choroid. The outer layer of the choroid is slightly detached from the sclera in places. It shows well marked congestion and a diffuse round celled infiltration, and is atrophied in places. In apposition with the choroid and apparently involving the chorio capillaris is an organized exudate which was spoken of before. This tissue consists of a mesh-work of fibrillæ supporting fairly numerous spindle and stellate connective tissue cells. Round cells are also scattered diffusely throughout this tissue. Here and there are areas, denser in character, of delicately fibrillated structure supporting only a few cells of the stellate connective tissue variety, which in favorable places are seen to grow gradually denser and fade into well formed bone. The stellate connective tissue cells with their branches very evidently become bone corpuscles in lacunæ with their canilicula. Still other portions of this section show areas of completely formed bone surrounding portions of loose connective tissue containing large blood vessels. In others the blood vessels are surrounded by fat tissue, as in Haversian canals. In very few places do we see blood vessels coming in close contact with the new bone formation, but they are always surrounded by a loose connective or fat tissue. No traces of the retina are seen.

ANALYSIS OF 42 CASES OF

TABULATION OF CASES OF

Case.	By Whom Reported	Year.	Patient's Age.	Sex.	Reason for Removal of Eye.	Etiology.	Time Elapsing since Primary Lesion.	Sympathetic Irritation.
1	H. Berthold	1870	45	Male	O. S. Phthisis bulbi with pain. Diagnosis — Intraocular tumor	.....	.....	.....
2	E. Berthold	1871	30	Male	O. D. Severe pain. Blindness	Injury	20 years	Yes
3	H. Knapp	1871	17	Female	Blind for three years. Phthisis bulbi. O. S. Repeated attacks of inflammation	Inflammation	Since childhood	Yes
4	H. Knapp	1871	60	Male	Phthisis bulbi. O. S. Repeated attacks of inflammation. Eye tender. Cornea opaque	Injury	45 years	Yes
5	H. Knapp	1871	45	Male	Detached retina. Irido-cyclitis	Injury	5 years	Yes
6	H. Knapp	1871	38	Male	Detached retina. Irido-cyclitis	Injury	.....	Yes
7	H. Knapp	1871	....	Female	O. S. Keratitis. Irido-cyclitis	Inflammation	19 years	.....
8	H. Schiess-Gemuseus	1873	26	Male	O. D. Inflammation. Severe pain. Clinical diagnosis — Tumor; secondary glaucoma; detached retina	.....	.....	.....
9	H. Schiess-Gemuseus	1873	35	Male	O. D. Inflammation. Iridectomy five years before. Tumor. Phthisis bulbi	Inflammation	6 years	.....
10	H. Schiess-Gemuseus	1873	....	Male	O. S. Blindness. With chronic iritis and chronic retinitis	Inflammation	Since childhood	.....
11	H. Schiess-Gemuseus	1873	....	.....	Phthisis bulbi	Injury	20 years	.....
12	H. Schiess-Gemuseus	1873	....	.....	Phthisis bulbi. Irido-cyclitis. Plastic choroido-retinitis	.....	.....	.....
13	H. Schiess-Gemuseus	1873	....	.....	Irido-cyclitis. Detached retina	.....	.....	.....
14	H. Schiess-Gemuseus	1873	16	Female	O. S. Phthisis bulbi. Irido-cyclitis. Choroido-retinitis	Inflammation	10 years	.....
15	H. Schiess-Gemuseus	1873	....	.....	Phthisis bulbi. Detached retina	.....	.....	.....
16	H. Wagner	1873	48	Male	O. S. Phthisis bulbi. Complete amaurosis	Injury	35 years	Yes
17	M. Boncheron	1875	26	Male	Phthisis bulbi. Sympathetic inflammation twenty years later	Injury	23 years	Yes
18	Dianoux	1880	50	Male	Phthisis bulbi. Detached retina	Inflammation	.....	Yes
19	W. R. Amick	1880	50	Male	O. S. Malignant tumor of iris and choroid. Iridectomy done. Subsequent enucleation	Injury	27 years	Yes
20	Wadsworth	1880	....	Male	O. D. Recurring attacks of inflammation and tenderness	Injury	14 years	Yes
21	W. Goldzieher	1880	45	Male	Blind. Choroiditis. Severe pain	Injury	.....	.....
22	W. Goldzieher	1880	....	Female	O. D. Phthisis bulbi. Eye painful. Irido-cyclitis	.....	.....	.....

OSSIFICATION OF THE CHOROID.

OSSIFIC GROWTHS IN THE EYE.

Character of New Growth — Macroscopically.	Character of New Growth — Histologically.	Development of Bone.	Other Pathological Conditions.	Case.
Tumor, 1 c. m. in diameter. Hard masses on outside	Spindle-celled sarcoma and small masses of true bone with characteristic bone corpuscles and lamellar systems	.....	.....	1
Complete shell	Normal bone tissue which contained marrow spaces filled with large fat cells	In connective tissue consisting of meshwork containing necrotic cells and leucocytes	Posterior synechia	2
Complete shell. Septum not ossified	True bone with concentric arrangement of bone corpuscles about nutrient canals	No cartilage or membrane. Soft layer of delicate connective tissue fibres and round cells — abundant — lying within the bony shell and contined across the eye posterior to the lens	Posterior synechia. Calcareous and fibroid lens. Slight fibrous change of outer layer of choroid. Retina degenerated	3
Septum ossified. Ring felt, 1½ m. m. broad	True bone in different stages of ossification readily made out	Different stages of ossification seen in tissues of the septum, composed of a fibrillous matrix filled with round, spindle, and stellate cells	Degenerated lens. Retina shows fibrous change. Cornea opaque	4
Partial shell; also small tumor in septum	True bone in both places	Osseous tumor lying in the soft granular-looking tissue enclosed by the coarcted retina	Degenerated and shrunken lens. Detached retina. Atrophied choroid. Fibroid degeneration of iris	5
Partial shell. Largely on one side	Thin shell of bone	Bone developed from the material exuded from the choroid	Detached retina with F. B. in fibrous tissue posterior to lens. Old choroiditis	6
Complete shell; also ossification of septum	True bone formation	Ossification of the inner layers of the choroid and of the fibrous septum, following an old irido-choroiditis	Detached retina. Ciliary bodies and iris thickened. Lens shrunken	7
Islands of bony tissue	Islands of bony tissue with bone corpuscles	Layer of new-formed tissue on choroid. Inflammatory hyperplasia. New-formed blood vessels. Round cell infiltration	Retina thin and atrophied	8
Tumor. Partial shell	Melanotic sarcoma. Partial bony shell	Small masses of bone lying in connective tissue	Degenerated lens	9
Partial shell	Plates of bone with bone corpuscles	.....	Fibrous lens	10
Partial shell	Bony tissue	Bone lying in connective tissue	Retina absent	11
Partial shell	Layer of new formed bone	.....	.....	12
Partial shell	Atrophied choroid covered with thin layer of bone	Bone lying in connective tissue	.....	13
Islands of bone	True bone formation with bone corpuscles	.....	.....	14
Partial shell	Masses of bone	Bone contained in connective tissue layer	.....	15
Small hard tumor projecting from choroid	True bone tissue	.....	.....	16
Plaque of bone	True bone formation	Bone lying in fibrous tissue	Detached retina. Vitreous body transformed into fibrous tissue	17
Complete shell	Perfectly formed bone with osteoplasts and bony canals and vascular channels	.....	Detached retina. Old inflammatory exudate	18
Partial shell	True bone	.....	Tumor, probably malignant. Detached retina	19
Partial shell	True bone formation	.....	Calcareous lens	20
Islands of bone	True bone involving the chorio-capillaris and retina. Both thickened and changed	Metaplasia of the organized exudates of the chorio-capillaries and retina with three stages of ossification	Vitreous liquefied. Retina fibrous in places, proliferating in others	21
Ossification of septum	Ossified septum with stellate bone corpuscles. Osteoid tissue extends into lens	Metaplasia of cyclitic membrane, with three stages of ossification	Detached retina and corpus ciliare. Obliterated anterior chamber. Iris adherent to cornea and lens	22

TABULATION OF CASES OF OSSIFIC

Case.	By Whom Reported.	Year.	Patient's Age.	Sex.	Reason for Removal of Eye.	Etiology.	Time Elapsing since Primary Lesion.	Sympathetic Irritation.
23	W. Goldzieher	1880	....	.....	Atrophied bulb	....	.....	.....
24	Dianoux	1881	....	Female	Phthisis bulbi	.....	.....	Yes
25	Dianoux	1881	....	.....	Phthisis bulbi	....	.....	Yes
26	Hoene	1882	....	.....	O. D. Iridectomy. Subsequent enucleation	Injury	... .	.....
27	Hoene	1882	....	.....	Eye enucleated — for sympathetic inflammation. Lens removed at previous operation	.....	.....	Yes
28	J. Fontan	1883	....	.....	Eye removed after death	.....	.....	Yes
29	J. Fontan	1883	....	.....	.....	.....	.....	.....
30	J. Fontan	1883	....	.....	.....	.....	.....	.....
31	C. J. Kipp	1883	22	Male	Irido-cyclitis. Had cataract since birth	No cause	.....	.....
32	T. H. Wood	1890	25	Female	O. S. Phthisis bulbi. Neuralgic pain. Blind. Following ophthalmia neonatorum	Inflammation	25 years	Yes
33	T. H. Wood	1891	27	Female	O. S. Inflammation	Inflammation	5 years	Yes
34	T. Reid	1892	26	Male	O. S. Gradual loss of sight. No pain	No apparent cause	12 years	.....
35	D. De Beck	1897	59	Male	O. S. Irido-cyclo-choroiditis. Phthisis bulbi	Injury	21 years	Yes
36	Robert L. Randolph	1900	....	Male	Eye removed after death	Injury	Since childhood	.. ..
37	David Webster	1901	18	Male	O. D. Phthisis bulbi. Recurring attacks of inflammation	Injury	15 years	Yes
38	David Webster	1901	22	Female	Enucleation for sympathetic inflammation. O. D. Blind, following original inflammation	Inflammation	20 years	Yes
39	Millikin and Darby	1902	25	Male	Phthisis bulbi. Blind	Injury	18 years	Yes
40	Millikin and Darby	1902	17	Female	Phthisis bulbi. Blind	Injury	16 years	No
41	Millikin and Darby	1902	39	Female	Phthisis bulbi. Blind	Injury	36 years	Yes
42	Millikin and Darby	1902	47	Male	O. S. Phthisis bulbi. Blind. Recurring attacks of inflammation	Injury	3 years	No

GROWTHS IN THE EYE.—CONTINUED.

Character of New Growth — Macroscopically.	Character of New Growth — Histologically.	Development of Bone.	Other Pathological Conditions.	Case.
Bony shell occupying position of lens	True bone	Ossification of organized exudate, extending about lens from the cyclitic membrane or septum	....	23
Hard mass occupying about one-third interior of eye	True bone having osteoplasts in bony canals	.....	.....	24
Hard shell occupying region of choroid and ciliary processes	True bone	.....	.....	25
Complete shell and ossification of septum	Bony lamellæ, forming Haversian canals	Bone lies in connective tissue	Posterior synechia. Cellular infiltration of the sclera. Choroid shows fibroid thickening	26
Partial shell	True bone formation	Attached to the thickened and fibrous choroid	Choroid and iris atrophied. Optic nerve atrophied. Choroid shows fibrous thickening near and bony shell. Also thickening and round-celled infiltration of sclera	27
Partial shell	Compact plates of bone separated here and there by medullary spaces	.....	.....	28
Islands of bone	Islands of compact bone	Contained in the thick fibrous choroid, which had been the seat of a fibrinous exudation	....	29
Small masses of bone	True bone	Masses of bone contained in the thickened and fibrous choroid	.....	30
Complete shell. No ossification of septum	Normal bone	....	Posterior synechia Calcareous lens. Detached retina. Choroid thickened. Aperture for optic nerve. Atrophic iris	31
Complete shell	True bone	.....	Atrophied optic nerve. Fibrous cornea. Outer layer of choroid degenerated. Retina and vitreous degenerated. Aperture for optic nerve. Lens absent	32
Partial shell	True bone	.....	Detached retina. Calcareous lens	33
Partial shell	True bone. Numerous lacunæ and canaliculi, in some parts concentrically arranged about rudimentary Haversian systems	Place of chorio-capillaris taken by an exudate containing spindle cells, in the midst of which the osseous capsule has developed	Detached retina. Calcareous lens	34
Complete shell	True bone	.....	Optic nerve atrophied. Detached retina. Lens atrophic. Aperture for optic nerve	35
Partial shell	True bone	.....	.....	36
Complete shell	True bone	....	....	37
Partial shell	Resembles cancellous tissue of true bone with its concentric lamellæ and irregularly formed Haversian canals	Tissue about bone contains numerous leucocytes. No choroidal vessels, except in deeper parts, where there is choroidal pigment	Cornea thickened. Deep anterior chamber. Atrophic ciliary body. Calcareous lens. Detached retina	38
Hard mass in septum	True bone with bone corpuscles in lacunæ and Haversian canals	Metaplasia of fibrous tissue into bone	Detached retina. Calcareous lens	39
Complete shell with partial ossification of septum	Same	Same	Detached retina. Calcareous lens	40
Septum not ossified. Partial shell	Same	Same. Tissue similar to that of the septum surrounds lens	Detached retina. Calcareous lens	41
Bony masses	Same	Same. Osteoid-looking tissue at the base of several ciliary processes	Retina and lens absent	42

ETIOLOGY.

Age. After childhood, age seems to have little or no influence in the development of bone in the eye. In 25 instances in which the age was given the ages ranged from 16 to 59 years.

Sex. Although twice as many males have been reported as females it seems highly probable that this factor is of little etiological importance.

Previous Inflammation. In 29 cases in which there were definite statements regarding this factor there was no inflammation in two eyes, but both had been blind for over ten years. In the other 27 cases 16 gave a history of injury a number of years previous to the enucleation. The other nine cases gave history of inflammation coming on insidiously in the eye several years before enucleation.

The Time Elapsing since the Primary Lesion. Data were given in 24 cases. No cases of ossification reported are in less than three years after primary inflammation of the eye. Four out of 24 cases reported under ten years. The eye affected was designated in 21 cases showing 8 right and 13 left eyes.

Phthisis bulbi was noted as being a prominent characteristic in 22 cases. Blindness noted in 11 cases. Pain in enucleated eye, 10. No pain reported in 2. Sympathetic irritation was recorded in 22 cases, and was usually one of the most potent reasons for enucleation. The absence of sympathetic irritation was recorded in 2 cases.

Other Pathological Conditions. The frequency with which certain other pathological conditions were found in these eyes containing bone deserves to be noted. In 21 out of the 42 cases the retina was reported as degenerated and usually detached. Atrophy and degeneration of the lens recorded in seventeen cases.

Reasons for Enucleation. As was stated above, 22 cases were reported as having had sympathetic irritation, and this was by far the most important indication for removal. In 8 other cases enucleation was practiced on account of recurring attacks of inflammation and pain. Two eyes were removed on account of

melanotic sarcoma of the choroid, and bone masses were found on the periphery of the sarcoma. One eye was removed after death. The cause for removal of 9 other eyes is not recorded.

Position of Bone Mass. Recorded in 42 cases. By far the greater number of cases (27) report specimens containing a partial shell of bone or masses or islands of bone just internal to the choroid. In 11 cases the shells of bone were said to completely cover the internal surface of the choroid.

The septum or ciliary membrane alone was reported as ossified in 3 cases. In 4 other instances the septum showed ossification in connection with choroidal ossification. Ossification was found in the exact region of the lens in one instance.

Besides these cases Pagenstecher has described bone at the base of the retinal funnel. Berthold described bone at the posterior surface of the iris. Shiess describes ossification in the retina. Schiess-Gemuseus speaks of ossification in the connective tissue common to both the retina and choroid. Goldzieher reports a case of ossification of the septum with the osteoid tissue invading the posterior surface of the fibrous lens.

Formation of Bone. Twenty-five of the 42 cases reported described the bone as lying in and developing from a loose fibrous tissue which is evidently the result of an organized exudate in the interior of the eye. No author as far as we can learn has ever recorded the presence of cartilage in the eye.

Knapp in 1871, in discussing the formation of bone in the eye, said that true ossification has never been demonstrated in the crystalline lens, retina, cornea, iris, or vitreous body, but has only been found in exudations from the choroid. The abrupt termination of the osseous capsule at the ora serrata makes it probable, in his opinion, that the chorio-capillaris are essential in the production of osseous deposits, on account of its rich blood supply. Subsequent inquiry strengthened his views. Knapp further stated that the formation of bone in the eye is a consequence and a final stage of a plastic inflammation of the capillary layer of the choroid. He described the exudate as investing the inner surface of the choroid and continuing in the

form of a transverse septum through the anterior part of the vitreous humor behind the ciliary body and crystalline lens. Knapp's descriptions are clear cut and accurate, and much of his interpretation of the process might have been written at the present time. During the next few years several cases were reported by such able men as Pagenstecher, Berthold, Schiess, Schiess-Gemuseus, Alt, and Goldzieher on bone developing in exudations other than those derived from the choroid. These cases prove conclusively that ossification may occur in the fibrous tissue of organized exudates in the retina and uveal tracts, or that such an exudate originating in the choroid and invading other tissues such as the retina may ossify. Now the essential factor necessary for ossification is a new formed vascular connective tissue. These conditions are best met in organized exudate from the uveal tract, the vascular tunic of the eye. The few cases reported as involving the retina can be explained by the involvement of that organ in the original inflammation from the neighboring choroid. Or we might call it an ossification of an organized choroidal exudate which had invaded the other tissues. The ossification about a lens may be explained in a similar way. The inflammatory exudate which forms a septum by extending across the eye posterior to the lens, may in some instances extend about the lens or even penetrate the lens substance and finally may become organized and then ossify. Knapp considered this septum as a portion of the choroidal exudate, but Goldzieher speaks of it as a "cyclitic membrane." The fact remains that ossification occurs in organized exudates from the internal structures of the eye and not in the stroma of an inflamed structure. No particles of bone have ever been demonstrated in the stroma of the choroid, ciliary body, or iris. Ossification has never been observed in the cornea, as the conditions there are entirely unfavorable to bone formation. That the inflammatory exudate from the choroid is not the only tissue in the eye capable of undergoing ossification was demonstrated by Alt in 1871, when he discovered ossific processes as having taken place in the colloid excrescences of the lamina vitrea

choroidiæ. Goldzieher in 1880 in discussing this subject stated that according to Sattler the lamina vitrea is a kind of connective tissue made up of wonderfully delicate fibrillæ having a lattice work structure on its external surface toward the capillaries. He believes that following an old inflammation a hyaline material is usually deposited in this irregular, thickened, and organized lamina vitrea, the so-called "colloid excrescences" of Alt. At times, however, after the organization has taken place calcareous salts may be deposited here instead of the hyaline material. Alt reports that he found "colloid excrescences" in seven out of one hundred and fifty eyes examined, and that only one or two of these seven showed definite bone formation and three showed calcareous degeneration. Alt also reports having examined fourteen cases of ossification of the choroid and found that every one took place in the organized exudate from the chorio-capillaris, as had been described by Knapp and Pagenstecher. The mode of development of bone in the eye has been ably discussed by Goldzieher in 1880, whose views have been upheld by Ware, 1886, Drake Brochman, 1889, and De Beck, 1897. The process of ossification is one similar to that of early periosteal bone formation. Cartilage has never been demonstrated in this variety of bone formation. The meta-plasia of fibrous tissue into bone has also been discussed extensively by Paul Rohmer and Kurt Pollack in their articles on ossification occurring in atheromatous heart valves, arteries, and in calcareous nodules in the lung. The results obtained by these men were very similar and coincide with the method of bone development in the eye. They, however, always found their bony plaques in fibrous tissue about some calcareous nodule. This organized inflammatory exudate in an eye from which bone may be developed is made up of loose fibrillæ with a reticulated structure supporting a moderate number of spindle and stellate connective tissue cells and some small round cells. This tissue is well supplied with blood vessels and usually contains small scattered areas of choroidal pigment. In a suitable specimen where the process of development is easily seen this tissue as it approaches the fully developed bone becomes denser. The loose

intercellular substance becomes replaced by numerous delicate interlacing fibrillæ, making a dense homogeneous matrix containing few cellular elements. The intercellular substance becomes more homogeneous and the cellular elements become fewer and more evenly distributed as the bone is approached. As yet no lacunæ or canaliculi are seen, but the processes of the stellate connective tissue cells can occasionally be recognized. Finally the deposition of lime salts take place, forming lacunæ, in which the connective tissue cells lie, which now represent the bone corpuscles. The lime salts are first deposited at a point farthest away from the larger blood vessels where the current in the capillaries is sluggish. Hence we sometimes see in these specimens areas of new formed bone in the vicinity of a small blood vessel, but there always exists a considerable space about this vessel in which ossification has not taken place. In the more recent specimens the vessels are seen surrounded by the ordinary loose connective tissue from which bone is primarily formed. In ossifications of long standing the ossified tissue approaches close to a vessel and ends abruptly. The vessel itself is surrounded by a loose reticulated structure containing numerous fat cells and a few epitheloid cells.

CONCLUSIONS.

Ossification of the choroid is of moderately rare occurrence, though probably more common than is generally supposed. Careful search of the literature has revealed thirty-eight undoubted cases reported in the last thirty years. Age has little to do with ossification, as it occurs in all ages, though very rarely under fifteen years.

Sex. Ossification has been reported in the enucleated eye of about twice as many males as females, though this probably only indicates that traumatism destroying the eye is more common in males than females. Previous inflammation is probably the chief etiological factor in producing this condition. Between 60 and 75 per cent. of these cases are reported as due to inflammation, the result of injury.

Time elapsing since primary lesions has usually been from ten to thirty years. It has sometimes been found in eyes

enucleated less than ten years after primary lesions, but very rarely in less than five years. The relative frequency as to which eye was the more often injured shows nothing, as each eye had been enucleated about the same number of times.

Sympathetic irritation was the cause for removal of more than one-half of the cases reported.

Phthisis bulbi was noted as a prominent characteristic in about one-half the cases.

Blindness, though only recorded in one-third of the cases, was probably present in almost all, if not all, cases. Faint light perception was mentioned in one case. Pain in the enucleated eye was a prominent symptom in one-fourth of the cases reported. Detached or degenerated retina has been noted in over one-half the reported cases. An atrophic and degenerated lens was noted in about one-half of the cases.

Position of the bony mass. Two-thirds of the cases were those of partial shells or masses of bone springing from the choroid in the posterior part of the eyeball. A complete shell over the inner surface of the choroid was reported in about one-fourth of the cases, but some of these reports were very short and abbreviated, so probably the number is a little high. A few cases of ossification have been reported occurring in the fibrous septum posterior to the lens. Finally, a very few cases report an involvement of the retina and lens. Regarding the formation of bone we may say that ossification only takes place in an eye in which a long standing inflammation has occurred. Ossification almost always takes place in the organized exudate of the chorio-capillaris. This exudate at times involves other structures in the eye where ossification may subsequently occur. The essential for ossification is a vascular new-formed connective tissue, the result of an organized inflammatory exudate. Rarely ossification takes place in the lamina vitrea choroidæ, thickened and showing slight organization, the result of an old inflammation. The deposit of lime salts in osteoid tissue always occurs first at a point farthest away from the larger blood vessels.

Our thanks are due to Dr. W. T. Howard, Jr., for advice and supervision in this work.

BIBLIOGRAPHY.

Berthold, H. Ein phthisischer Augapfel mit theils erweichtem, theils verknöchertem Chorioidealsarkom. Klin. Monatabl, f. Augenh. Erlang., 1870, VIII, 19-24.

Berthold, E. Verknöcherung der Chorioidea: Neubildung von Glashäuten: eigenthümliches Verhatten des Seheerven. Arch. f. Ophth., Berl., 1871, XVII, 1 Abth., 196-202.

Knapp, H. Formation of bone in the eye. Arch. of Ophth., N. Y., 1871, Vol. II, 1-35.

Schiess-Gemuseus, H. Beitrag zur Sehn. von der Knochen neubildung in der Chorioridea. Arch. of Ophth., Berl., 1873, XIX, 1 Abth., 202-220, 1 pt.

Wagner, H. Eine Hyperostose der Chorioidea ueben diffuser Verknöcherung derselber. 8° Halle, 1873.

Jeaffreson, C. S. Ossification of a large portion of the choroid following chronic traumatic inflammation. Lancet, Lond., 1873, II, 413.

Boncheron. Ossification de la Choroïde. Bull. soc. Anat. de Par., 1875, I, 108.

Laquer. Ein Fall von Ossification der Chorioidea mit ophthalmoscopischem Befunde. Arch. f. Augen. u. Ohrenh., Wiesb., 1877, VI, 29-35.

Dianoux. Ossification de la Choroïde. Bull. soc. Anat. de Nantes, 1879, Par., 1880, 66.

Amick, W. R. Ossification of the choroid: malignant tumor: enucleation and sympathetic ophthalmia. Cincin. m. News., 1880, N. S., IX, 505-512.

Wadsworth. Osseous deposits in choroid. Extr. Rec. Bost. Soc. m. Improve., 1880, VII, 78.

Dianoux. Ossification de la Choroïde. Bull. soc. Anat. de Nantes, 1880, Par., 1881, IV, 95.

Goldzieher, W. Ossification in the eye. Arch. of Ophth. & Ot., N. Y., 1880, IX, 300-317.

Hoene, J. Recherches microscopiques sur les ossifications choroïdiennes. Rec. d'Ophth., Par., 1882, 3 s., IV, 708-718.

Fontan, J. Ossification de la Choroïde: examen. de trois

bulbes oculaires atteints de cette ossification. Rec. d'Ophth., Par., 1883, 3 s., V, 205-211, 2 pt.

Frost, W. A. Ossification of choroid, causing repeated attacks of sympathetic irritation. Tr. Ophth. Soc. U. Kingdom, Lond., 1883-4, IV, 171.

Kipp, C. J. Ossification of the choroid. Tr. Am. Ophth. Soc., 1883, III, Part 4, 564.

Ware, L. Ossification of the choroid. J. Amer. M. Asso., Chicago, 1886, VI, 39.

Laënnec. Ossification de la choroïde. Bull. Soc. Anat. de Nantes, 1880, Par., 1890, XII, 17.

Ruiz, P. Ossification totale de la choroïde: glaucome sympathique dans un oeil primitivement opéré de cataracte: rupture spontanée de la cicatrice: énucléation de l'oeil sympathizant: guérison. Rec. d'Ophth., Par., 1889, 3 s., XI, 29-32.

Drake-Brockman, E. T. Case of ossification of the choroïd. Brit. Med. J., Lond., 1889, I, 585.

Ehrhardt. Ossification de la choroïde, et décellement "en paraphine" de la rétine ayant provoqué une ophthalmis sympathique. Bull. Soc. Anat. de Par., 1890, LXV, 25.

Wood, T. H. Ossification of choroid. Arch. Ophth., N. Y., 1890, XIX, 388. Ophth. Rec., Nashville, 1891, I, 24.

Reid, T. Ossification of the choroid. Tr. Glasg. Path. & Clin. Soc. (1886-91), 1892, III, 96.

Meighan, T. S. A case of ossification of the choroid. Tr. Glasg. Path. & Clin. Soc., 1886, 1891, 1892, III, 120.

Romano-Catania. Ossification of the Choroid. Arch. di Ottalm., 1895, II, 11 p., 345.

De Beck, D. Ossification of the choroid. Tr. of Acad. of M., Cincin., 1897, 269, 272.

Randolph, R. L. Ossification of the choroid. Ophthal. Section A. M. A., 1900, 203-206.

Webster, D. Two cases of ossification of the choroid. Arch. of Ophth., 1901, XXX, pp. 23-26.

Kurt Pollack. Ueber Knochenbildungen in der Lunge.

Virchow's Archives Fur Pathologische Anatomie und Physiologie, und fur klinische Medicin. Band 165 Juli Seite, 129-189.

Paul Rohmer. Ueber Knochenbildung in verkalkten endocarditischen Heerden. Reference same as above. Band 166, October, Seite 13-40.

IMPROVEMENT OF VISION IN AMBLYOPIA FROM NON-USE.

BY HARRY FRIEDENWALD, A.B., M.D.

BALTIMORE, MD.

The nature of the amblyopia found in strabismus has been an object of inquiry for a number of years. Ophthalmologists had gradually become united in the view that while many squinting eyes were congenitally defective, strabismus itself led to amblyopia or increased that previously present. It was Schweigger,[1] in the early eighties, who disturbed this peace of mind by offering arguments to show that the amblyopia of strabismus was in all cases a congenital defect, and that when improvement in vision occurred, either after an operation or by exercise, it was due to correction of the hypermetropia and to the improvement in the use of the accomodation. A. Graefe added support to Schweigger's theory, and for a number of years it obtained wide adoption, although many ophthalmologists continued to adhere to the old view. Strange to say the only arguments which could finally settle the question were slow in coming; these were: first, definite cases in which eyes with good vision became amblyopic from strabismus, and, secondly, cases of marked improvement in vision in previously amblyopic eyes after their continued use.

A. As to the first I am able to find but few cases:

1. Schmidt-Rimpler[2] relates the case of a boy aged seven, with high strabismus and normal vision in each eye. An operation failed to correct the defect entirely. Ten years later the squinting eye could only count fingers at four meters.

---

[1] Klin. Studien ueber das Schielen, Berlin, 1884.

[2] Augenheilkunde und Ophthalmoscopie.

2. Lewuillon[1] reports a similar case.

3. Senn[2] stated recently that he has not only been able to improve vision in the amblyopic eye by permanent closure of the fixating eye, but has even produced amblyopia in the previously good eye.

4. But the most important case is that of Dr. Risley.[3] In a discussion before this Society in 1893 he related a "case in which the R. E., which was amblyopic, had been operated upon to correct the strong convergence; after four years the case again came under his observation, the L. E. now being the squinting eye. The R. E. before the operation had been almost blind, but now had perfect vision, while the L. E. had been reduced to eccentric vision so that the patient could barely count fingers. Tenotomy was done, the refraction corrected, and exercise ordered, and at the end of three months the vision of the poor eye rose to 6/7.5.

B. The list of cases which tend to prove that an amblyopic eye can recover its sight is now becoming quite numerous. In 1896 Straub collected the following references:

1. Romiée[4] reported that systematic exercise after strabismus operation has led to improvement of the vision of the squinting up to one-sixth, to one-third, or one-half, according to the degree of amblyopia.

2. Javal,[5] after very prolonged exercise, succeeded in restoring perfect binocular vision to a patient who had the highest degree of unilateral amblyopia.

3. Burchardt[6] reported that a few days after operation vision rose from counting of fingers to 3/10.

4. Dr. Johnson[7] reported in this society in 1893 the case of a young man of nineteen who had had strabismus from the age of three. Vision of the R. E. was perfect, that of the L. E. en-

[1] Annales d'Oculistique, 1893.
[2] Wochenschr. f. Therap. und Hygiene des Auges, Vol. IV, p. 221 (1902).
[3] See Transact. Oph. Society, Vol. VI, p. 556. Previously reported in the Phila. Med. Times, 1873, p. 453.
[4] Annales de la Société medico-cherurgicale de Liége, 1880.
[5] Annales d'Oculistique, 1888, p. 217.
[6] Charite-Annalen, XVII, 1892.
[7] Trans. Oph. Soc., Vol. VI, p. 551.

abled him to count fingers at six inches. A few days after the examination his good eye was injured and the eyeball removed. Vision rapidly improved until in about two weeks it reached 20/15 with or without correction of his hypermetropia.

5. Dr. Risley,[1] in discussing Johnson's paper, reported three cases. The first is mentioned above.

6. In Risley's second case, by prolonged exercise, vision of both eyes was kept at 6/7.5 or 6/9. After six months of neglect vision in the squinting eye sank to 1/3. By exercise and an operation which restored binocular vision, 6/6 was obtained in each eye.

7. Risley's third case (not mentioned by Straub) is that of a child which had convergent strabismus with vision reduced to 1/2 in the squinting eye. After correction of the hyperopic astigmatism the strabismus disappeared, and after several years the vision of each eye was found normal. During the discussion Randall and Holt mentioned similar cases.

8. Bourgeois[2] reported a number of cases in which vision improved somewhat after operation.

9. Lewuillon[3] reported a case in which vision improved from 1/7 to normal within six weeks after the operation. He also reported cases in which there was less improvement.

10. Panas[4] reported a case of a man aged thirty who lost the sight of his good eye from neuritis. In two years the sight of the other eye, which was highly amblyopic since childhood, had so much improved that he was able to read fine print.

To these cases, a few of which only are of doubtful value, the following must be added.

11. Simonton[5] reports a case in which a squinting eye with vision — 16/40 was improved to 16/16 in three months by the use of glasses.

12. Herrnheiser[6] reported the case of a boy aged eleven

[1] Trans. Oph. Soc., Vol. VI, p. 556.
[2] Receuil d'Ophthalm., 1893, p. 211.
[3] Annales d'Oculistique, 1893, p. 26.
[4] Traité d'Ophtalmologie, Vol. I, p. 758.
[5] Ophthalmic Record, 1897, p. 400.
[6] Wochenschr. für Therap. u. Hygiene d. Auges, 1900, No. 41.

whose fixating eye was injured (traumatic cataract), reducing vision to counting of fingers. Even so, this eye was at first still preferred as the fixating eye. The squinting eye with +2 was at first able to see fingers at one and a half meters; two weeks later at four meters. In three months vision rose to 6/24, and in one year to 6/9.

13. Klein[1] relates two cases, in both of which vision improved from the time that the amblyopic eye was forced into use, in the one case because of loss of the fixating eye through cysticercus and enucleation, and in the second by a foreign body. In both cases a relatively high degree of vision was obtained.

14. Bielschowsky[2] relates a most interesting case. The patient had been examined in Schweigger's clinic and vision =1/15 recorded. B. found the same vision five years later when the fixating eye was lost by an injury. In two and a half years vision in the amblyopic eye gradually increased, and finally reached half the normal.

15. The most important reference is to Javal's studies of the improvement in vision in amblyopic eyes through exercise.[3] These studies are the most systematic that have been made, and leave no doubt as to the great improvement that it is possible to obtain by long continued exercise according to Javal's plan.

Besides these cases we may refer to those in which sight is lost in early childhood in consequence of double cataract.

1. Leaving the older cases, I desire to call your attention to the recent publication of Axenfeld,[4] who reports a case of a child aged six, which after attending school for a while became blind, and was operated upon for double cataract when seven and a quarter years of age. In the mean time it had completely lost the ability to see and was in the condition of a child born blind excepting that it re-learned to see more quickly than those who are born blind.

2. Seydel[5] in 1901 reported a case of a girl aged ten who

---

[1] Wein. Med. Wochensch., 1900, No. 20.
[2] Graefe's Arch. f. Ophthalm., Vol. L, p. 487.
[3] Manuel de Strabisme, Paris, 1896.
[4] Monatsblätter f. Augenheilk, 1900, Appendix, p. 29.
[5] Monatsblätter f. Augenheilk, 1901, p. 817.

became blind when seven, was neglected, and when operated upon was in the condition of one born blind. Although the optical effect of the operation was good it required two months until she was able to walk about alone.

3. He also reports a case of a man aged thirty-one whose sight became bad when he was four years old, and was lost in his seventh year. After an operation he rapidly learned to see in about three weeks and his recovery was more complete than in the previous case.

Both Axenfeld and Seydel conclude that a child that can see well up to the sixth or seventh year may completely unlearn how to see. Seydel states that the degree and the persistence of this amblyopia depend upon the mental condition and training.

It is proper that I should here refer to the interesting discussion of the subject in a paper of Dr. Theobald read before this Society in 1886.

To the cases already reported[1] I desire to add the following: Mr. S., aged seventy-eight, consulted me on Nov. 11, 1898. As a child between six and seven years of age he was injured in the R. E. with a shoemaker's awl. Traumatic cataract followed, and he has never been able to make use of this eye since. The L. E. has been failing for some time. Examination showed constant nystagmus of both eyes, with slight divergence of the right. There was a shrunken cataract occupying the entire pupillary space of the R. E. and a minute peripheral corneal scar. The pupil reacted well to light, projection was fair, he could see movements of the hand close to the eye. The L. E. was in an advanced stage of chronic glaucoma, tension somewhat raised, corneal epithelium hazy, pupil slightly dilated, glaucomatous excavation of the optic disk. With this eye he could count fingers at seven feet. The inner half of the field was greatly impaired, the defect touching the point of fixation: the outer half was fair. Fearing the rapid loss of sight in the L. E., and recognizing the dangers of an iridectomy under the circum-

[1] The list of cases given above is not complete.

stances, it was deemed advisable to treat the L. E. with eserine and to attempt to restore vision in the R. E. by removal of the cataract. This operation was done Nov. 28, 1898, under cocaine. An incision was made with the keratome about two mm. from the upper corneal margin, the cataractous mass removed with the iris forceps and the remnants pressed out with a spoon. The recovery was rapid and unattended by any inflammation, and the clear round pupil admitted of easy examination of the fundus; this was found normal. It was a great disappointment, however, to find that notwithstanding the clear media, the patient saw exceedingly badly. He could not fixate, and at the time of his leaving the hospital, about two weeks after the operation, his vision was only sufficient to enable him to recognize the movements of the hand, and convex lenses made no improvement. On Dec. 21st vision equaled counting fingers at ten feet, and the field of vision was apparently normal. On June 25, 1899, he returned, complaining of pain in the temples. The vision of the L. E. had become further reduced so that he could but count fingers held very near by, and the R. E. saw movements of the hand at the length of the room. The tension of the L. E. was between plus 1 and 2. The pain increasing, an iridectomy was made on July 3, 1899. The eye stood the operation well, but the vision did not improve, and salicylate of soda was administered frequently on account of pain.

As the vision of the L. E. had slowly diminished, the R. E. had been used more and more, and September 6, 1899, the patient informed me that it had improved so much that he believed he was ready for glasses. Vision with +6Ds equaled 3/40; with +15.0 he read 1.0 m.

These glasses were ordered, and on Nov. 22, 1899, vision was found to be 10/40 with the same glass, and he could read fine print. From this time on he began reading the daily paper, the difficulty gradually diminishing. I examined the patient recently (July 2, 1902) and found that with +6 his vision is 6/15 without difficulty, and with +15.0 he reads 0.5 m. German print fluently. The condition of the eye has not changed otherwise;

the pupil is round and freely movable. The vision of the L. E. is reduced to seeing movements of the hand, the optic disk is atrophic without distinct excavation. Tension is normal. I may add that the patient still has some nystagmus, but my impression is that this has diminished. The L. E. is now slightly divergent.

The improvement of the vision of the amblyopic R. E. is marked and beyond question. The patient's vision after the operation was so poor that glasses were not ordered, the impression being that the sight was beyond recovery, and nine months elapsed before decided improvement was noted. Glasses were then given and the vision increased gradually so that in two months it had reached 10/40, and two and a half years later it was found to equal 16/40.

This case is in some respects unique. In the well-known case of V. Graefe vision was immediately restored after removal of a cataract of sixty years duration. Klein, Silex, and others have reported similar observations. Even those who admit the occurrence of amblyopia from non-use in strabismus and in double cataract in children under six or seven, do not recognize the occurrence of such an amblyopia in unilateral cataract as a result of non-use. It is probable that the cataract was not the sole factor in producing the amblyopia in the case related, but that strabismus played an important part. It is to be noted that vision was not entirely prevented by the cataract, for the patient could still see movements of the hands and had fair projection of light. This much is certain, that the eye was amblyopic, and that it gradually recovered a useful amount of vision when forced into work. The form of amblyopia was that associated with strabismus, the chief characteristic being the loss of the power to fixate. I feel no hesitancy therefore in placing this case with those referred to in the beginning of this paper, as offering another instance of the genuineness of amblyopia from non-use.

Two years ago Silex,[1] expressing his surprise that there were

[1] Deutsche Med. Wochenschr., 1900, p. 383.

still those who looked upon the amblyopia found in strabismus as due to non-use, reviewed the subject in a critical manner.

He first considers the theoretical arguments in favor of amblyopia from non-use, which cannot be proved or disproved, and may therefore be neglected. He next takes up the question of the observation of loss of vision through strabismus. As to the case of Schmidt-Rimpler he states that had it occurred in his own practice he would have attributed it to an error in recording. He further argues that at the age of seven years, in which the central visual apparatus has been completely formed, it is impossible to lose vision. This is disproved by the cases of Axenfeld and Seydel cited above. He does not mention the case of Dr. Risley, which I am sure none here will be willing to admit as due to an error in recording. We cannot agree with his statement that no unquestionable proof has been given, as demanded by Schweigger, that an eye with normal sight has become amblyopic, for we regard both Schmidt-Rimpler's and Risley's cases as such proof, and it must be remembered that the difficulties in the way of making such observations are very great. As to improvement of vision in amblyopic eyes, he takes the same view as Schweigger. Panas's case he throws aside, because the patient had never had an opportunity to test the true visual power of the squinting eye. He relates a case of amblyopia (not strabismic) in which glasses improved vision from 1/10 or 1/6 to 2/3 with glasses, but in this case there was neither loss of central vision nor of fixation. Silex's arguments do not disprove the value of the numerous cases cited in which highly amblyopic eyes have been restored to good vision. He overlooks especially the restoration of central vision where there has been loss of fixation. This does not occur in congenital amblyopia no matter how much care is given to the correction of the refractive error. No other hypothesis than the production of amblyopia from non-use will satisfactorily explain the gradual recovery of vision in this form of amblyopia.

It is not necessary at this time to discuss the argument that the amblyopia is not constant in all cases of strabismus. This

question can be understood only when we know more of the physiology of vision in strabismus, a subject which through the studies of Bielschowsky and others is now looming in an entirely new light.

A POINT IN THE DIOPTICS OF ASTIGMATIC REFRACTION ILLUSTRATED BY A NEW MODEL.

BY DR. HERMAN KNAPP,
NEW YORK.

In the autumn of 1859 I submitted to the medical faculty of the University of Heidelberg a paper "On the Curvature of the Cornea of the Human Eye," it being my thesis to obtain the Venia Docendi at the University. A few days later Prof. Helmholtz, in whose laboratory I had made the investigations, came to me and said: "There is one fundamental mistake in your thesis; nevertheless I reported it favorably, without reporting the mistake, for I knew that none of my colleagues would find it out. The thesis was unanimously accepted, but I have come to tell you where the mistake is, that you may correct it, and bring me back the MS., for as it is it should not be printed." The mistake was about the "focal interval of Sturm" (published in French, also in German, Poggendorff's Annalen, Bd. 65, 1845). I was acquainted with the effect of such a refraction by drawings and experiments, but had never seen or heard of Sturm's analysis of this remarkable phenomenon, and thus I naturally fell into the erroneous supposition into which, as I know by my editorial readings, others have likewise fallen, and still fall, viz.: When the focus of the strongest meridian is situated say 32 mm. behind the cornea and the weakest 33 mm. it seems natural to assume that the foci of the intermediate meridians must lie between the two. I have never attempted the mathematical analysis why this is not so, and all authors I have come across were satisfied with the experimental demonstration of the focal interval, all the details of which are familiar to every oculist. The thread model, showing the course of the rays of the refracted astigmatic bundle, which

after weeks of trial I succeeded in constructing at Heidelberg, has become popular, but it does not make it clear why only the rays of light that are broken by the principal meridians unite into foci, whereas those broken by the other meridians form no second foci at all, in fact no two of them ever meet again. Why this must be so is shown at the model I invite you to examine.

The refracting body represents a triaxial ellipsoid, in imitation of the cornea. The strongest (principal) meridian is verti-

Published by Gall & Lembke N.Y.

cal, the weakest horizontal. The substance of the model is wax, into which pins have been stuck along four different meridians, the two principal and the two diagonal between them. The pins are so implanted that they form the prolongations of the radii to the little circular surfaces of the ellipsoid on which they stand. To stick them in as correctly as possible, I have used nothing but the judgment of my eyes. Their setting is not, of course, mathematically accurate, but sufficiently so to show the law. You will easily see by looking directly at the front of the model

that all the pins of either principal meridian are in a plane surface, whereas the pins in the other meridians are no longer in even planes, but wind around like the steps of the staircase in a round tower, forming the skew surface (windschiefe Fläche, surface gauche) of mathematicians. On calling to mind the first law of refraction, that the incident ray, the perpendicular, and the refracted ray are situated in the same plane, you see that only the principal meridians can refract rays into foci, while all the other meridians cause the rays to incline according to the windings of their perpendiculars.*

THE DESIRABILITY OF A UNIFORM NOTATION OF THE MERIDIANS OF THE EYES AND THOSE OF THE VISUAL FIELD.

BY DR. HERMAN KNAPP,

NEW YORK.

Mr. President and Gentlemen:

I have discussed this subject several times in different places. If I implore your indulgence to bring it up before you again, it is because I consider it now more opportune than before, and because my views on it, by further thought and experience, are more settled than previously, in fact they point definitely in one direction. The controlling principle of my argumentation is the "symmetry of our eyes, in all their parts, as a dual organ, in reference to the median plane of the body." Snellen mentioned it briefly in 1869 in a paper "on the Direction of the Principal Meridians of Astigmatic Eyes."†

* This model is not altogether new; I devised it about 20 years ago, and showed it to some colleagues at the New York meeting of the Am. Med. Association. I never published it; in fact I had to make a new one to show it at the Saratoga meeting of the same association a month ago, and to exhibit and describe it before this society, in the hope that some of the younger members may work out an easily intelligible geometrical demonstration of the refracted rays of an astigmatic pencil. This does not seem too difficult if the pins and thread models are used.

† Graefe's Archiv., Bd. XVI, 2, S. 200.

At the Seventh International Ophthalmological Congress, at Heidelberg in 1888, I read a paper on the Symmetrical Position of the Meridians of the Eye, based on the examination of 200 successive cases.*

For the registration of the result of our examinations I considered **two systems most suitable** for the notation of the location of the meridians (l. c., p. 427).

In **the first** we count from the upper end of the vertical meridian, marking it 0°, down the nose to the horizontal meridian (90°), and further on to the lower end of the vertical meridian (180°). In the same way we proceed again from the upper end of the vertical meridian down on the temporal side, also marking the positions of the meridians from 0° to 180°. Those of the nasal side receive the index *n* (= nasal), those on the temporal side *t* (temporal).

The second system starts from the nasal end of the horizontal meridian (0°) of both eyes and goes upward all around the circle to 90° at the upper end of the vertical meridian, to 180° at the temporal end of the horizontal meridian, and so on over the lower half of the circle up to 360°, the point from which we started. I said (l. c., p. 428, below): "If this system should be chosen, I would accept it with pleasure. It is expedient, perspicuous, plain, and precise. Clerical mistakes between *n* and *t* would not occur." I preferred at the time the first system, as, in the first place, we were accustomed in the descriptions of the movements of the eye to refer constantly to the upper end of the vertical meridian, for instance in the physiological and pathological conditions of the superior oblique muscle, etc., and as, in the second place, the symmetrical position of the meridians in astigmatic eyes could also be well expressed by it. Later I gave it up because astigmatic determination had shown itself of such overwhelming practical importance that the adoption of the simplest and best method to record the results of our refractive work forced itself on my mind.

* Die Meridianbezeichnieng beim Verschreiben von Cylinderlinsen. Siebenter Internationaler Ophthalmologen-Congress zu Heidelberg, 8–11 August, 1888. Bericht von O. Becker u. W. Hess. Wiesbaden, 1888, S. 423.

At the 28th annual meeting of the American Ophthalmological Society, held at New London, Conn., July 20, 1892, I read a paper on "The Law of Symmetry of our Eyes as manifested in the Direction of their Meridians; its Rule and its Exceptions,* drawing my conclusions from the evidence of 1,000 successive cases of binocular astigmatism of my private practice, compiled and arranged by myself.

They showed the following positions of the principal meridians: **In both eyes:**

the strongest meridian was vertical in	605 cases,	=60.5%
the strongest meridian was horizontal in	110 "	=11 %
the strongest meridian was intermediate, *i. e.*, the same angle between vertical and horizontal, ...	146 "	=14.6%
Sum total of *symmetrical* meridians,	840 cases,	= 84 %
The number of eyes in which the principal meridians were unsymmetrical was	160 "	= 16 %

I still advocated the system of counting from the upper end of the vertical meridian on account of its simplicity, perspicuity, and small liability to make clerical mistakes. This system has become rather popular in Europe, and is recently warmly recommended by Snellen in preference to the method I advocated at the last international ophthalmological congress at Utrecht, 1899, in one of the general addresses, which do not admit discussion. In this address I based my remarks on 1,473 additional private cases added to the 1,000 reported at New London in 1892.

Among the 2,473 cases of binocular astigmatism, 1,934= 79% (omitting decimals), were situated symmetrically to the vertical median plane of the eye (*i. e.*, also of the body).

Of these the meridians of strongest refraction

were vertical in	1,396 cases,	= 57%
" horizontal in	256 "	= 10%
" diagonal, *i. e.*, 45° above the horizontal,	63 "	= 3%
" intermediary, but not diagonal, in	219 "	= 9%
Symmetrical position in	1,934 cases,	= 79%
Unsymmetrical position in	530 "	= 21%

* Trans. Am. Ophthalmological Society, Vol. VI, p. 308.

In this address I abandoned the mode of counting from the vertical meridian and advocated what in my paper before the Heidelberg International Ophthalmological Congress in 1888 I had recommended as equally suitable, which is a modification of the American notation. The latter was introduced by the late Dr. Henry D. Noyes of New York, at the 5th annual meeting of this Society, July 21, 1868, by a paper entitled, "What Manner of Designating the Meridians would you consider the best for us to adopt?"* It gradually made its way over the northern part of this continent. Its feature is not the symmetry in the position of the meridians, but the general principle with which physicists describe the motions of pieces of machinery and other moving objects. This principle has been used by Helmholtz in the chapter on the motility of the eyes in his "Physiol. Optics." Both eyes have to move harmoniously together, as if they were one (the Cyclopian) eye. It is expressed by the following rule: Look at the face of your patient as at the dial of a clock and note down the positions of the meridians *of both eyes* as the hands of the clock move, *i. e.*, from right to left, beginning at the temporal end of the right eye and the nasal end of the left, both of which mark 180°. In this way the *parallel* meridians of both eyes are designated with the same number. It fits the Cyclopian eye, but, in the *position of the meridians, parallelism is very rare.* In morphological descriptions we designate the symmetrical parts of dual organs with the same name, for instance, the thumb is always the thumb, even in the fingerings of the piano-school books, though the parallel movements of the fingers of both hands, for instance, the left little finger with the right thumb, are most common. If we designate the ocular meridians morphologically it will, to my mind, be most natural to begin with the nasal ends of the horizontal meridians in both eyes, proceed upward and go all around the circle, marking the nasal end of the horizontal meridian 0°, the upper end of the vertical meridian 90°, the temporal end of the horizontal 180°, the lower end of the vertical meridian 270°, and so on till we come to 360°, the starting point. (See Figs. 1 and 2).

* Trans. Am. Ophthalm. Soc., Vol. I, 5th Ann. Meeting, 1868, p. 29.

The symmetrical method of designation has the great advantage that the identical meridians always bear the same number, not only in both eyes, but also when we look at the spectacles from in front or from behind; for instance, 45° is 45° in the right as well as in the left eye, not 45° in the right and 135° in the left.

The change from the old into the symmetrical system should not — with some attention at the beginning — be confusing or awkward. We obtain new blanks, which the optician will furnish for the asking. We note the change in our records from the day we use it exclusively, and as soon as we are reconciled to the new condition, we change the numbering of the trial frame for the left eye. In recording the numbers for publication or

FIG. 1.

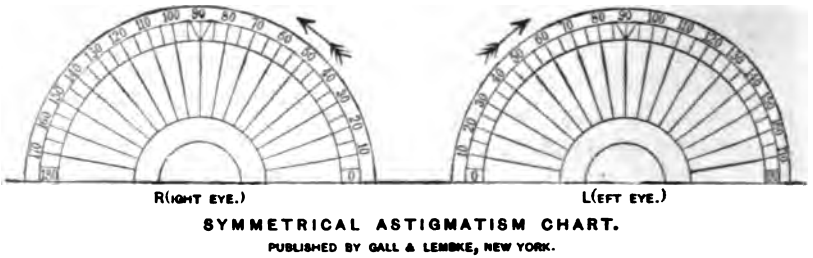

in correspondence we should mention "symmetrical notation" or abridged "(sym)" for a time.

The same system lends itself readily to the Field of Vision. The designations of the meridians are the same. The count begins at the nasal end of the horizontal meridian of each eye and continues upward and all around the circumference. The physiological fields of vision are symmetrical as the tracings and diagrams show.

I would, however, in conclusion point to a method by which any point, line, or figure in the chart can be put in written or printed letters, with accuracy and ease, whereas we cannot offer diagrams or even outline tracings to the publisher in large quantities for reasons of economy. Our charts have degrees of longitude (meridians), and degrees of latitude (parallels). *Any point in the chart is determined by the crossing of a meridian with a parallel.* The points in the upper half of the field are expressed

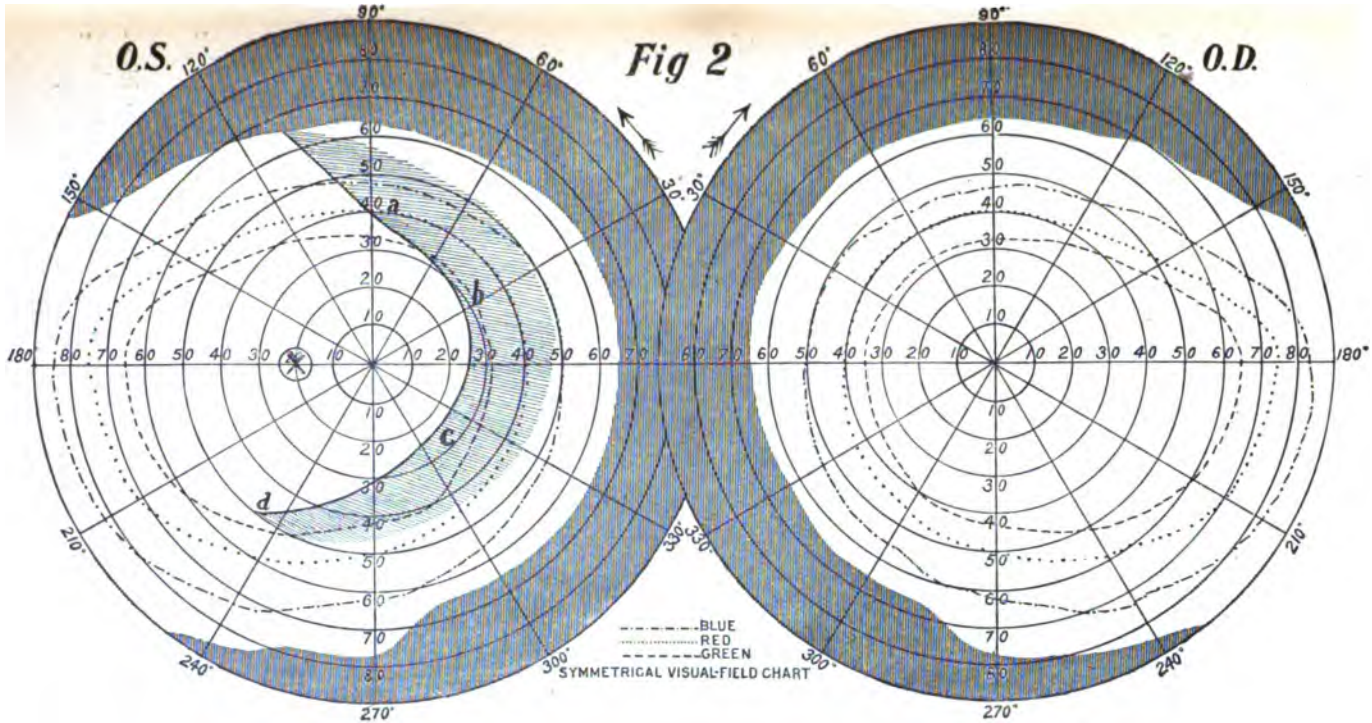

PUBLISHED BY GALL & LEMBKE, NEW YORK.

O. S. Blind spot: me 180, pa 20. Glaucoma: a — me 90, pa 40; b — me 30, pa 29; c — me 325, pa 23; d — me 236, pa 50.

O. D. Green-field: me 0, pa 35; me 60, pa 32; me 120, pa 37; me 170, pa 60; me 180, pa 64; me 210, pa 60; me 242, pa 50; me 300, pa 40.

by the meridians from 1° to 180°, those in the lower half by the meridians from 180° to 360°. All the meridians end in the center of the chart. If we abridge meridian into *me* and parallel into *pa*, we can register any point as the mariner registers the course of his ship. These records can simply be written in our manuscripts or sent by letter to anybody. For instance, the place of the yellow spot X (see chart in Fig. 2) is designated by me180°, pa20°. In the same way we can denote in writing the outlines of defects of the visual field in any disease or the color fields, etc., of which Fig. 2 gives an example. It is indifferent whether we examine the patient on directly looking at him, or placing him before a blackboard or behind the perimeter, the degrees remain the same. The only thing we must not put down wrong is whether it is the right or the left eye.

Mr. President and gentlemen, what I have presented to you is not a new way, but an attempt to amend an old one. I dare hope that the amendment will in time be generally adopted, adopted sooner in America than in Europe, for the Americans have nothing to change except to look at the left eye in the same manner they have looked so long at the right.

DISCUSSION.

DR. G. C. HARLAN. — In regard to the notation of the meridians I heartily approve of the suggestion; as a matter of fact it is mine. It is exactly what I advocated in an article published in Knapp's Archives ten years ago. In preparing the article I wrote Dr. Knapp asking his opinion. My paper was read before the Ophthalmological Section of the Philadelphia College of Physicians, and a committee consisting of Drs. Thomson and Risley and myself was appointed to consider the subject and report. Dr. Thomson joined me in advocating the proposed change in notation, but Dr. Risley read a minority report, giving his reasons for dissenting.

DR. KNAPP. — I think I received a letter from one of the committee that they had discarded the matter.

DR. HARLAN. — It was found at the meeting, after considerable discussion, that no satisfactory conclusion could be reached and the subject was indefinitely postponed. My paper was published in the 22d vol. of the Archives, 1893.

BULLER.—Tumor of Optic Nerve.

TUMOR OF THE OPTIC NERVE, WITH INTRACRANIAL COMPLICATIONS.

BY DR. F. BULLER,
MONTREAL, CANADA.

This case is one of the usual type of optic nerve tumors, but presents the unusual, though not unknown, peculiarity of involvement of both optic nerves and loss of vision of both eyes.

B. S., aged 14, was brought to me by her mother on Dec. 6, 1901, with a history of failing vision of the right eye since the preceding June. Previous to the latter part of December, 1900, had enjoyed excellent health and was considered up to the usual standard of development and intelligence as compared with her brothers and sisters. In December, 1900, she had an attack of measles, and according to her mother's statement, was never quite herself again, though she and several other members of the family recovered without definite complications. In the following June, first noticed some difficulty in seeing clearly with the right eye, and in July or August the eye had begun to be prominent, and was now quite blind. The proptosis has gradually increased ever since this time, and is now very great, as shown by accompanying photographs. Claims to have seen quite well with the left eye until about two weeks ago. Vision with this eye is now reduced to counting fingers at one foot distance. The visual field not determinable. Pupil wide and inactive. The optic nerve presents unmistakable optic neuritis, though the swelling of papilla is not very pronounced. Otherwise there is nothing to indicate disease within the left orbit.

To return now to the consideration of the conditions present in the right orbit. No tumor can be discovered by palpation (without an anæsthetic); the globe is displaced as nearly as can be estimated about six millimeters forward and four millimeters upwards. It is rotated inward most of the time, occasionally

there is a squint in the opposite direction, *i. e.*, a rotation outwards without corresponding position of the other eye. The movements are slightly restricted in all directions; the pupil wide and reactionless, except when the left eye makes an effort at near vision; then both pupils contract normally. The ophthalmoscope shows a typical choked disk without hemorrhage or other changes in the retina; refraction at macula equals 2½ D. At the surface of papilla about 10 D.

The early loss of vision, with proptosis occurring about the same time are common signs of optic nerve tumor, but there were in this case the additional early symptoms of a distinctly cerebral character, such as vertigo, ever since the spring of '91, and from about the same time purposeless vomiting, more particularly early in the morning. The child is slow of speech and rather lacking in general intelligence, but there is neither motor nor sensory paralysis unless we count as such the loss of olfactory sense and the loss of vision as described above.

The patient complains of some soreness down the right side of the neck, and the head is drawn somewhat downward towards the right, apparently in consequence of spastic contraction of certain muscles in the neck. There is also absence of patellar reflex.

It was fairly evident that we had to do with a neoplasm, involving the right optic nerve, the optic chiasm, and probably extending more or less widely within the cranial cavity.

In order to be quite certain as to the first part of this diagnosis, on the 11th of December the child was anæsthetized, and I divided the internal rectus and rotated the eye so far outward that I could see the condition of the optic nerve, which appeared enormously thickened and contorted, much as in the accompanying diagram; exploration with the finger also detected the larger mass extending to the apex of the orbit. I then reattached the rectus muscle, and waited several weeks, with the intention of removing the growth by Krönlein's method. This operation, done chiefly for the purpose of getting rid of the disfigurement and deformity produced by the presence of the growth in the orbit, I performed on the 9th of January. Recovery was uneventful.

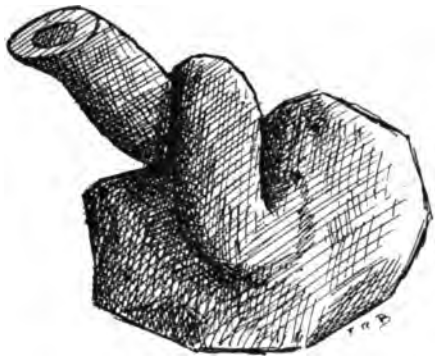

BULLER.—Tumor of Optic Nerve.

For some weeks there was still a considerable proptosis and great œdema of the ocular conjunctiva, all of which slowly subsided, leaving at the time of discharge on February 19th an appearance indicated in the accompanying photograph.

Besides the swollen and curiously contorted optic nerve, there was a great mass of new growth, completely occupying the apex of orbit. When this had all been cleared away the optic foramen could be distinctly felt with roughened margins and very much wider than normal. For some two or three weeks the child appeared listless and dull after the operation, but before the date of discharge from the hospital there was much improvement in this respect, though still far from being bright or intelligent. There was also at this time an increasing papillitis of the left optic nerve and vision reduced to qualitative perception.

It is remarkable how many of the recorded cases of optic nerve tumors have followed injuries about the head, or some constitutional febrile condition. This case belongs in the last mentioned group, and was attributed, by the parents at least, to the attack of measles already mentioned. This occurring as it did, some months before vision failed, a possible connection between the two cannot be denied, when we take into consideration the definite history of vision having failed gradually within six months, and allowing for the fact that the tumor must have been growing for quite a long time before the child would have noticed any loss of vision, this would in all probability bring the commencement of the trouble back to about the same period of time as the attack of measles.

In Dr. Byers' paper, referred to in this report, his synopsis of 102 cases shows one other case to have followed measles. This case is moreover somewhat rare, though not unique, as already stated, in the involvement of both optic nerves, and exemplifies the fact which Byers has pointed out, viz.: "The Frequent Co-Existence of an Intra-Cranial Growth with that of the Orbital Portion of the Optic Nerve," so that the former is not the result of extension from the orbit, but constitutes a part of the original neoplasm.

Dr. Byers has kindly furnished me with a pathological report of this case, which is herewith submitted.

PATHOLOGICAL REPORT.

After hardening for some time in formalin the tumor presented the appearance depicted in the accompanying sketch. Anteriorly the optic nerve was almost uniformly enlarged to a diameter of 5 or 6 mms. for a distance of about 2 cms., and then occurred a sudden marked increase in the size of the growth, which measured here about 15 mms. from before backwards and 20 mms. in height and breadth. The capsule of the tumor was formed by the nerve's dural sheath, which was present everywhere except on the posterior surface of the larger portion where separation had taken place. The anterior portion of the growth as depicted in the sketch was twisted one whole turn upon itself.

Section of the tumor showed the usual conditions — dural sheath externally separated from the paler nerve proper by the newly formed subdural tissue. In no part of the growth was there anything resembling a cystic condition. The course of the optic nerve proper throughout the tumor was quite eccentric, and this structure, apparently normal anteriorly, slightly increased in size towards the optic foramen, near which, somewhat oval in shape, it measured 5 x 3 mms.

Microscopically the subdural overgrowth consisted of a loose meshwork of flowing connective tissue arranged in ill-defined bundles which anastomosed freely with one another by means of delicate interlacing fibrils. There were numerous well-stained nuclei scattered throughout the field, but very few vessels. The picture was, in fact, identical with that of the first tumor removed by Dr. Buller and described and depicted in Vol. 1, No. 1, of the Royal Victoria Hospital Studies.

Absent from the sections were any marked signs of œdema or myxœdematous change, and dilation of the lymph spaces of the nerve, so marked a feature in the case already mentioned and in the tumor presented to the Society by Dr. Buller in 1899, was barely, if at all, noticeable.

BULLER.— Tumor of Optic Nerve.

Staining with Pal-Wiegert showed complete degeneration of the nerve fibrils. The slight enlargement of the nerve proper towards the optic foramen was apparently due to an increase in the endoneurium of the individual bundles rather than to a hyperplasia of the inter-fasicular connective tissue.

The microscopical characters of this growth present only the picture of a simple hyperplasia of the fibrous elements of the subdural space, and to a slight extent of the individual fasiculi especially toward the cerebral end of the nerve. The overgrowth corresponds in no way to any special type of tumor formation, and must be looked upon as a phase of that development of fibrous tissue in the abstract which we designate technically *fibromatosis*. It will be observed on examination how essentially the condition is one of simple overgrowth of the fibrous tissue elements and how little marked are the cellular and myxœdematous characters so commonly present in specimens of the condition mentioned.

It is worthy of note, also, that the macroscopical examination showed that the maximum intensity of growth was toward the optic foramen, that the extirpation of this tumor was incomplete, and that the tumor must necessarily have formed only part of a large intra-cranial neoplasm which, judging from the clinical history, must have developed more or less simultaneously with that situated within the orbit.

TEMPORARY LIGATION OF THE CANALICULI AS A MEANS OF PREVENTING WOUND INFECTIONS IN OPERATIONS ON THE EYE.

BY DR. FRANK BULLER.

In February last I exhibited before the Montreal Medico-Chirurgical Society a case of recent Suppurative Keratitis occurring in connection with dacryocystoblennorrhœa, in which the suppurative process had been promptly arrested by first

ligating the canaliculi and then energetically disinfecting the corneal ulcer. In connection with this case I called attention to another in which I had operated for cataract, the eye having perished from acute suppuration coming on within 48 hours after the operation. In this case there was no positive evidence of disease of the tear sac, but the puncta lacrymalia presented a patulous, somewhat pouting, appearance. This seemed to point to the tear passages as the source of infection. It then occurred to me that this could be effectually obviated by ligating the canaliculi close to the puncta and so shutting off any possible supply of disease germs from the tear passages.

Prior to the operation the usual precautions to make the eye as aseptic as possible were taken, and, in addition, just before operation on the second eye I ligated the canaliculi and carefully cleansed the puncta external to the ligatures. This eye recovered from the cataract operation without a single unfavorable symptom, notwithstanding the fact that the patient had been for two months shut up in the hospital and had gone through the pain, worry, and disappointment of a panophthalmitis.

Before the operations the condition of the two eyes was to all appearance alike. It therefore seems probable that the first eye was lost through local infection from the tear passages and that a similar result in the second eye was prevented by shutting off the source of infection.

Since February I have only had one case suitable for the same precaution, and here the result has been equally satisfactory; unfortunately this case had been too much meddled with before coming to my hands to be typical of the class in which I consider ligation specially suitable. This patient, about 65 years of age, with mature cataract in the right eye, had long been affected with a copious secretion of yellow muco-pus from the right tear sac. Decrepit, slovenly, and unclean, he did not at best appear particularly suitable for operation and much less so in the presence of a suppurating tear sac. He had been advised that the cataract should not be removed until the tear sac disease was cured, and to this end the lower canaliculus had been slit

and the tear sac treated by syringing and the use of lachrymal probes, apparently without benefit, at least there was when he came under my care still an abundant secretion from the sac, and a conspicuous chronic conjunctivitis. To have shut off the tear sac by ligation would obviously have been impracticable after the lower canaliculi had been opened, and as the usual treatment had already exhausted his patience, it was thought best to arrest the secretion from the tear sac by using a strong solution of zinc chloride. This caused intense reaction for a few days and was followed in a couple of weeks by complete closure of the artificial opening by way of the lower canaliculus, though fluid could be freely syringed through the upper canal into the nose, none escaping through the lower canal. The conjunctivitis was now practically cured. I therefore considered the condition of the eye suitable for the removal of the cataract, after having first taken the precaution of ligating the upper canaliculus.

The operation was followed by a rapid and uncomplicated recovery, and the principle I am advocating, that of effectually shutting off the source of infection rather than depending on other tedious and doubtful means of procuring asepsis, was again vindicated.

Now, as for the removal of cataract in the presence of a suppurating tear sac I have failed to find in ophthalmic literature any other recommendation than that of treating the tear sac until cured before undertaking the cataract operation. This would be all very well if the cure could be effected within a reasonably short time and if we could be certain that an absolute asepsis had been achieved. It is quite certain that many bitter disappointments have attended these supposed cures. Some go so far as to recommend treatment of the nasal cavities until they too are thoroughly disinfected before removing the cataract, but who can tell when this has been accomplished? Personally I have no faith whatever in the efficacy of such treatment. I do not believe that safety can be secured by any known means of restoring these parts to a state of health except by absolute obliteration of the tear sac. On the other hand, the plan I pro-

pose does secure immediate and absolute immunity so far as infection from the tear and nasal passages is concerned.

In the words of descriptive anatomy, "the canaliculi are dense and elastic in structure," hence they can be perfectly occluded by a fine ligature for some days at least without impairing their continuity. After removal of the ligatures, in one instance at the end of two weeks, there was no difficulty in passing a small probe through into the sac; in the other two cases the canals were opened after ten and seven days respectively. No doubt the ligature does cause a little swelling and reaction immediately around it for a few days, thus rather increasing the desired effect and securing perfect occlusion for the all important first few days.

Thus far I have used No. 2 iron-dyed silk with a fine curved needle, passing it around the canals just a little to the inner side of the puncta and tying about as firmly as the No. 2 silk will bear; a stronger silk might perhaps be made to cut through, but this I think cannot happen with No. 2 silk, though it seems to serve the intended purpose perfectly.

It is, of course, proper to wash out the tear sac and thoroughly cleanse the parts before applying the ligature. So far I have done this immediately before removing the cataract; but there might be cases in which it would be well to ligate a few days before, and treat the conjunctiva if inflamed, for some time prior to operation. As compared with treatment intended to cure chronic inflammation of the tear sac preparatory to operating for cataract, it will I think be conceded that ligation of the canaliculi is infinitely superior as a prophylactic measure; furthermore, it is almost painless, easy and simple of performance, and not followed by the slightest inconvenience or annoyance to the patient. The secretions pent up in the tear sac do not perceptibly increase and cause no inconvenience. There is moreover no loss of time for the reason that the cataract can be removed either immediately or at most after a few days delay. This is an important consideration for persons living at a distance and perhaps unable to remain for any considerable length of time away from home.

But there is still a larger class of cases in which ligation should, and I have no doubt will, prove to be of great value. I refer now to all those numerous cases of corneal ulcers infected by secretions from the tear passages; every one knows how disastrous they are apt to be and how impossible it has heretofore been to prevent reinfection of the ulcer from day to day. For this very reason an infinite number of eyes have perished in spite of all the most approved methods of treatment. Temporary ligation at once fulfils the most urgent indication and should prevent further spreading of the ulcer from the moment the corneal lesion has been thoroughly disinfected. The one case reported in the Montreal Medical Journal of last March is sufficient to illustrate a principle which awaits confirmation by the test of sufficient experience. If the idea is a new one and happens to meet with the approval of this Society, so much the better, but if their judgment of it should be adverse, there will be the satisfaction of knowing that condemnation comes from a thoroughly competent and impartial tribunal.

DISCUSSION.

Dr. N. J. Hepburn. — In relation to cataract I ran across one of the class of cases mentioned by the doctor some time ago. Operation had been declined for about a year on account of an apparently incurable dacryocystitis. The patient had been in the hands of a competent ophthalmologist who had been treating the dacryocystitis. I tried a new procedure. I did not tie the canaliculus, but tried to make it absolutely sterile at the time of operation. After using cocaine and adrenalin I cleaned out the canaliculus and injected 1 : 100 methylene blue and followed that by pure carbolic acid and alcohol. I think I sterilized it effectively. I think the method is applicable where you have to operate in a very short time. The extraction went on without any especial reaction, except that there was no return of the secretion for four days. It did return later, but in a much modified form and has been amenable to treatment since. Where you have to operate and cannot wait I think this means is applicable.

Dr. W. F. Mittendorf. — Heretofore the only way of preventing this has been the destruction of the sac, and as that is not

only very painful, but tedious, I think the method of Dr. Buller is a very good one.

DR. S. B. ST. JOHN. — I think Dr. Buller's suggestion extremely valuable and those who are dealing with the subject should know about it in order that they should not try to cure the dacryocystitis, because they cannot do the operation after they have slit the canaliculus. We cannot say how long it will take to cure the dacryocystitis.

I had a case some time ago where I had to do a cataract operation with a dacryocystitis of moderate severity — the canaliculus had been slit some years before. I treated the case for a few days with injections through the canaliculus and sterilized the canal as well as I could and then packed it full of yellow oxide ointment, six grains to the ounce, and kept it full. The wound healed without a trace of infection.

DR. J. A. ANDREWS. — Did Dr. Buller apply a compress bandage, or were they treated as open cases?

DR. C. J. KIPP. — I think the use of the galvano-cautery has been recommended in these cases.

DR. BULLER. — In answer to Dr. Andrews' question I would say the cases were treated with the compress bandage.

As to closing the puncta with the galvano-cautery, that is one of the things that made me desire to have some better means. I once lost an eye where I thought I had closed the puncta with the cautery, after which I proceeded to do an iridectomy, and the operation was promptly followed by suppuration and panophthalmitis.

PROGRESS TOWARD GREATER UNIFORMITY IN THE EXAMINATION OF THE VISION, COLOR-SENSE, AND HEARING OF RAILROAD EMPLOYEES.

CHARLES H. WILLIAMS, M.D.,
BOSTON, MASS.

Since our last meeting several steps have been taken toward greater uniformity in the examination of the eyes and ears of railroad men. At the beginning of the present year a plan was put in effect on the Great Northern System* which followed very closely that in use on the New York, New Haven & Hartford Railroad, and which was recommended by this Society at its last meeting. Within the last few months the Boston and Maine Railroad has adopted and put in operation a similar plan, with some slight modifications, and the instructions and blanks which are now being used on all the divisions of the Boston and Maine system are appended to this paper.

At the meeting of the American Medical Association at Saratoga last month the following resolutions were presented to its House of Delegates, and were adopted by them as representing the position of the Association on this matter. It will be noticed that the methods and standards mentioned in these resolutions correspond very nearly to those already in use on the above railroads and to those recommended by this Society.

The following, unanimously adopted by the Section on Ophthalmology after several years consideration of the subject, is respectfully submitted to the House of Delegates for the official endorsement of the American Medical Association.

Recommendations of the Section on Ophthalmology regarding tests of sight and hearing for railroad employees.

Section 1. It is essential that railroad corporations should require definite and scientific examinations of the sight and

* At date of printing the plan adopted by the Great Northern is being extended to the Northern Pacific Railway.

hearing of those employees who will be at all concerned with the active operating of trains, or in giving or receiving of signals.

Section 2. Such examinations should, wherever possible, be made by regularly appointed eye and ear surgeons; and in all cases be conducted according to the instructions, and under the supervision, of a regularly appointed eye and ear surgeon, and with apparatus and under conditions approved by him, and all doubtful cases should be referred to him for personal examination.

Section 3. New men should be required to hear the spoken voice at 20 feet in a quiet room, and have healthy ears.

Section 4. The acuteness of vision should be tested by the test-types of Professor Snellen, or those which conform to his standards.

Section 5. The following minimum requirements should be adopted for acuteness of vision:

CLASS A.

	Entrance to service or promotion.	Re-examination of those in the service.
Enginemen (road service), Firemen (road service).	20/20 in each eye tested separately, without glasses.	20/30 with both eyes open without glasses. Each eye should also be tested separately and the vision of each noted.

CLASS B.

Other employees in the engine, train, or yard service, and car and engine inspectors.	20/20 in one eye and not less than 20/40 in the other. Tested separately without glasses.	20/40 with both eyes open, without glasses. Each eye should also be tested separately and the vision of each noted.

CLASS C.

Towermen. Telegraph operators. Station agents. Section foremen.	20/20 in one eye and not less than 20/40 in the other. Tested separately. With or without glasses.	20/40 with both eyes open with or without glasses. Each eye should also be tested separately and the vision of each noted.

CLASS D.

Crossing flagmen.	20/40 with both eyes open, with or without glasses.	20/50 with both eyes open, with or without glasses.

Section 6. The color perception should be tested by means of the colored worsteds of Professor Holmgren, preferably with worsteds tagged for the purpose of record; also in every case an additional test should be made with a lantern showing a number of colored lights which can be varied in their size and intensity.

Section 7 (a). Employees enumerated in Class A must reach the visual standard without glasses, and should not be allowed to wear distance glasses when on duty.

Section 7 (b). Employees enumerated in Classes B, C, and D should be allowed to wear glasses when on duty, and should be required to do so if the wearing of glasses is necessary to bring vision up to the proper standard. They should always be required to carry an extra pair of glasses when on duty, in case of accident to one pair.

Section 7 (c). Employees enumerated in Class A should not be retained in such positions if vision sinks below 20/30 with both eyes open, or if the spoken word cannot be heard in a quiet room at 15 feet.

Section 7 (d). Employees enumerated in classes B and C should not be retained in such positions if vision sinks below 20/40 with both eyes open (in Class D the minimum standard should be 20/50), or if the spoken voice cannot be heard in a quiet room at ten feet.

Section 8. There should be two general standards of visual and aural requirements, viz.: one for new men hoping to enter the service and to be actively engaged in the operation of trains, and in giving and receiving signals; and one for those men engaged in similar work who have been uninterruptedly in a company's service for five years, either the company from which employment is sought or some other company enforcing similar regulations. These latter may be regarded as old employees.

Section 9. Re-examination should be made of all such employees every three years, and after any severe illness or accident, or any occurrence which seems to cast doubt on the visual and aural capacity of the individual. Re-examination should also be made more frequently on men known to be excessive users of tobacco or to be suffering from syphilis, albuminuria, diabetes, or acute or chronic eye or ear diseases. They should always be examined before promotion.

Section 10. Men known to be excessive users of liquor should not receive employment for the services above designated (Section 5). The co-operation of the employees them-

selves should be sought by regulations that would encourage them to report promptly any temporary impairment of vision or hearing.

Respectfully submitted on behalf of the Section on Ophthalmology of the American Medical Association.

H. V. Würdemann,
Edward Jackson,
Leartus Connor,
Committee.

The American Railway Association, which is the most influential body among the railways of this country in regard to the adoption of standard rules and methods, is now considering the matter of physical examinations. Its Committee on Safety Appliances presented to the annual meeting of the Association on April 23, 1902, a long report of 140 closely printed pages, filled with the replies which they had received from 128 railroads, in answer to a long list of questions in regard to the physical examination of railway men sent out to them by this committee, and these replies give a very good idea of the present practice among our American railroads as to the tests for vision, color sense, and hearing.

To the question 48, "Do you examine as to acuteness of vision?" 84 roads answered yes, and 19 no.

To question 49, "Do you examine as to field of vision?" 76 answered yes, 23 no.

To question 50, "What employees do you examine" (for vision)? all of the roads making this examination replied that they examined all enginemen and firemen in road service, passenger and freight conductors, freight brakemen, yard enginemen, and firemen;

All but one of these roads examine passenger brakemen;

All but one examine yard conductors and brakemen;

Three roads do not examine switchmen;

Four roads do not examine passenger baggagemasters or yardmasters;

Twenty-four roads do not examine engine inspectors;

Twenty-seven do not examine car inspectors;

Twelve do not examine block signal men or telegraph operators;

Fourteen do not examine station agents;

Eighteen do not examine section foremen;

Seventeen do not examine crossingmen:

Question 54, "What methods and appliances do you use for examination as to vision?" was answered as follows:

Dr. Thomson's test card, 6; Dr. C. H. Williams' test cards, 8; Prof. Snellen's cards, 23; opticians' cards, 3; test cards (kind not mentioned), 18; DeWecker, 1.

To question 55, "What standards are required to pass the examination as to vision?" the following answers were given:

(The numbers refer to the roads mentioned in the committee's report.)

2. Thomson's standard.

3. Normal in one eye and not less than 20/50 in the other, but enginemen and firemen must have normal vision in both eyes.

9. One eye 20/20, the other 20/30, enginemen and firemen. One eye 20/30, and at least 20/40 with the other, for conductors, brakemen, and switchmen.

14. 20/20 with each eye.

20. 20/20 for new men, 20/40 for old employees.

23. For enginemen and firemen normal vision in each eye, for others in train and yard service normal in one eye and at least 20/40 in the other. New brakemen normal in each eye.

29. 20/20 for combined use of eyes provided that neither eye is less than 20/70 without glasses.

31. First class. Enginemen, firemen, brakemen, engine despatchers, signalmen, conductors, train baggagemen, normal vision. Second class. Agents, operators, station baggagemen, crossing flagmen, switchmen, switch tenders, gatemen, and bridge tenders, 20/20 in one eye and not less than 20/40 in the other, or 20/30 with or without glasses.

37. 20/20 in each eye.

38. 20/20 in one eye and at least 20/70 in the other.

43. 20/20 in one eye and not less than 20/40 in the other.

50. Enginemen and firemen 20/20 in each eye, other trainmen, switchmen, signalmen, etc., 20/20 in one eye and 20/30 in the other.

53. 20/20 in each eye. Enginemen and conductors in company's service who have 20/20 in one eye and 20/40 in the other are approved, also all enginemen and conductors whose vision can be made normal by glasses.

62. All employees normal in one eye and at least one-half of normal in the other.

71. 20/20 for firemen, and for brakemen 20/20 in one eye and 20/40 in the other.

73. 20/20 for one eye and not less than 20/50 in the other.

74. 20/20 for one eye and not less than 20/80 in the other.

78. 20/20 in one eye and not less than 20/40 in the other. Not less than 20/30 in either.

85. 20/20 for new applicants.

87. Class A. Enginemen, firemen, and towermen, 20/20 in each eye without glasses on entering service or promotion; not less than 20/30 with both eyes open without glasses on re-examination in the service. Class B. 20/20 in one eye and not less than 20/40 in the other on entering service or promotion; not less than 20/40 with both eyes open on re-examination of those in the service. Crossing flagmen not less than 20/40 with both eyes open on entering service, and not less than 20/50 on re-examination.

88. Normal vision for new men, 20/30 in one eye for promotion.

90. Enginemen 20/20 with one eye and 20/50 with the other, or 20/30 with both eyes, may use glasses to bring vision up to standard. Firemen 20/20 with one eye, and not less than 20/50 with the other without glasses. Conductors 20/20 with one eye and not less than 20/50 with the other, or 20/40 with each, may use glasses. Train baggagemen 20/20 with one eye and not less than 20/50 with the other, or 20/40 with each, may use glasses to bring vision up to this standard. Train brakemen

must not use glasses, must have 20/20 with one eye and not less than 20/50 with the other, or 20/30 with both. Yard masters 20/20 with one eye and not less than 20/50 with the other without glasses, or 20/30 with both. Operators 20/20 with one eye and not less than 20/50 with the other, or 20/40 with both, may use glasses. Track and bridge foremen 20/20 in one eye and not less than 20/50 in the other, or 20/40 with both.

92. Normal vision in each eye without glasses for new men.

93. 20/20 in one eye and not less than 20/40 in the other without glasses for train service. For telegraph and other signal service glasses are allowed.

97. New men 20/20 in each eye. Old employees 20/20 in one and not less than 20/40 in the other.

98. Normal vision in each eye for enginemen, firemen, crossing watchmen, car inspectors, maintenance and battery men. 20/20 in one and not less than 20/30 in the other for conductors, brakemen, yardmasters, train baggagemasters, car runners, and engine wipers.

101. 20/20 in one eye and not less than 20/50 in the other.

109. 20/20 in one eye and not less than 20/30 in the other without glasses for enginemen, firemen, signal tower men, and switchmen. For others 20/30 with each, or 20/20 in one and not less than 20/50 in the other.

112. 20/20 with both eyes open, provided neither has less than 20/70.

115. 20/20 with one eye and not less than 20/30 with the other for enginemen, signal tower men, or drawbridge tenders, without glasses, for others 20/30 with each eye, or 20/20 with one and not less than 20/50 with the other.

116. 20/20 in one and not less than 20/30 in the other without glasses for enginemen, firemen, and signal tower men; for others 20/20 in one eye and not less than 20/50 in the other, or 20/30 in each without glasses.

118. 6/6 with one eye and not less than 6/15 with the other for conductors, enginemen, brakemen, firemen, and telegraph operators.

119. 20/20.

120. 20/20 with both eyes open, or one eye not less than 20/30.

125. 20/20 in one eye without glasses.

128. 20/20 for new men, 20/30 for old employees.

From the above replies it will be seen that there is no uniformity in the practice of these roads in regard to standard requirements for acuteness of vision. In general they all recognize the need of more acute vision for enginemen and firemen than is needed for other employees, and that a higher requirement should be fixed for men desiring to enter the service than is required of old employees, and they generally require for men entering the engine service 20/20 or normal acuteness of vision in each eye without glasses. In the case of old enginemen and firemen the requirements vary from 20/30 with both eyes open (in which case no account is taken of the poorer eye except as a matter of record) to 20/20 with each eye, but the tendency is, and very properly, to favor the old employee provided his vision has not become dangerously defective.

It would seem very desirable to have more uniform standards adopted both for enginemen and firemen, and also for other classes of employees, for it would result in greater safety for the traveling public, in less risk of loss to the railroads from wrecks, and in less hardship to the employees than sometimes happens under the present uneven practice, and no standards have been more carefully considered than those which have been adopted by this Society and by the American Medical Association as representing the minimum requirements which are desirable in the different classes of work, both for new men and for old employees. The adoption of these standards by several of the large railroad systems of the country shows that they have also received the approval of practical railroad men.

To question 56, "What employees are allowed to wear glasses on duty in order to bring their visual powers up to the standard requirements?" there are very different answers.

Twelve roads allow all employees to use glasses:

Seven do not allow any of their men to use them;

Eight allow old employees to use glasses, but do not allow them for new men;

Five allow them for old employees whose vision is brought up to normal by their use;

Several roads allow their enginemen to use glasses, and other roads allow them for conductors, station agents, etc.

There is no uniform practice, and the recommendation of the committee of this Society in its report last year would seem to be a safe rule for railroads to adopt. It is as follows:

"In regard to the use of glasses, they do not help in rain, storm, or fog, when most needed, and in case of accident it might be difficult to prove whether they were being worn or not. New men entering the engine, train, or yard service, or being promoted to such places, should come up to the required standard without glasses; but there will always be a few cases of old employees with an excellent record, who require the use of glasses to bring their vision up to the passing point, and such cases should be handled individually by the general operating officer of the road, with all the facts reported to him, the practice on some roads being that such men are given the less trying positions."

To question 58, "Do you re-examine your employees periodically?" the following answers were given:

37 roads, no re-examinations;

4 roads, every year;

20 roads, every two years;

5 roads, every three years;

3 roads, every two or three years.

1 road, every five years (for young men);

8 roads, where defective vision is suspected.

To question 59, "Do you re-examine before promotion?" the answers were as follows:

43 roads, yes;

29 roads, no;

1 road, only in motive power department;

4 roads, not unless there are reasons to suspect defects;

2 roads, expect to do so.

1 road, no, except firemen;

1 road, only employees who took no examination on entering service.

To question 60, "By whom are the examinations as to vision made?" the answers were as follows:

22 roads, company surgeons;

1 road, local surgeon;

14 roads, oculists;

2 roads, examiners whose reports were reviewed by company oculist.

2 roads, an oculist under supervision of chief surgeon;

5 roads, medical examiner of relief department;

5 roads, regularly appointed examiners;

12 roads, trainmaster;

2 roads, train master or traveling engineer;

6 roads, heads of departments;

4 roads, superintendent;

5 roads, chief clerk;

2 roads, train despatcher;

1 road, division officers;

1 road, locomotive clerk;

1 road, rule examiners;

2 roads, master mechanic;

1 road, master mechanic, train master, and road foreman;

1 road, train master and superintendent's chief clerk.

Considering that many of the above examiners have probably never had any instruction or training in the proper way to make these examinations, and that even those examiners who have had a medical training have in many cases given no special attention to the testing of vision and color perception, and have not as a rule been supplied with a sufficient and uniform outfit or instructions and standards to govern the making of such tests, it is not surprising that the results obtained have not been altogether satisfactory, and that not much dependence can be placed on the answers to question 57, as to percentage of rejections on account of defective vision.

A better plan for handling this whole matter of examinations for vision, color-sense, and hearing would be to have each railway company appoint certain examiners for this work. These examiners should first be tested by an expert of recognized standing to see if they were able to make such tests and were not defective themselves. They should then be instructed by him in the best methods and standards to be used, and should be furnished by the company with a complete and uniform outfit of testing materials and blanks for reporting the results of the examinations. These reports should all be filed at some central office of the company, and the testing materials should from time to time be examined by the expert to determine whether they were in proper condition or needed replacing. All doubtful cases should be referred to the expert or to a board of which he should be a member. The plan of having such examinations made by regularly appointed eye and ear surgeons, working under some uniform plan and standards, is also a good one. In either case the results will be much more reliable and satisfactory than the present plan of entrusting this work to a clerk in the train master's or superintendent's office, or to some other employee of equal lack of training for deciding the questions which sometimes rise in regard to such tests.

In regard to the examinations for acuteness of color perception, of the roads answering the question of the committee, 88 reported that they made such examinations, and 22 that they did not make them, but the latter roads were mostly of small mileage, or in some cases terminals used by the employees of other roads who had been examined. On all roads making these examinations, the enginemen, firemen, passenger conductors, and brakemen, freight conductors and brakemen, yard enginemen and firemen, are examined for color perception.

On 4 roads there is no color examination for passenger baggagemasters, on 3 for yard masters, on 3 for switchmen, on 8 for ticket collectors, on 16 for draw tenders, on 23 for engine inspectors, on 26 for car inspectors, on 12 for block signal men, on 13 for telegraph operators, on 16 for station agents, on 18

for section foremen, and on 17 there is no such examination for color for the crossingmen.

To question 66, "Do you use Holmgren's test for color perception?" 43 roads reported that they did not use it, 31 that they used it, and 1 that they used it with the Williams lantern. To these should be added the Great Northern System, which apparently has not answered the questions of the committee and is not included in their report, for since the beginning of the present year the Great Northern has used both the tagged Holmgren colored worsteds and the Williams lantern.

To question 67, "Do you use Thomson's test?" 44 roads answered yes, and 36 no.

To question 68, "If neither, please state what system you do use?" —

3 roads use cardboard colors;
3 colored yarns;
2 Rumble's test;
1 Jennings' test;
1 Scripture's color test;
1 Oliver's colored wools;
1 match colors as recommended by our chief surgeon;
1 practical field test;
1 to distinguish red, white, and green;
1 none.

To question 69, "Do you use test lamps showing colors?" 45 roads report that they do not use test lamps, and 30 roads that they do use them; 3 roads use them occasionally, and 1 uses the stereopticon.

To question 70, "Do you use hand lamps or special device?" and question 71, "If the latter, whose system?" —

41 roads report they do not use hand lamps;
15 use them;
9 use Williams' lantern (ten, with Great Northern added);
7 use a special device of their own;
2 Welsh's test;
1 Scripture's;

1 stereopticon;

1 miniature electric lights at twenty feet distance;

1 colored lamps;

1 Donders' lantern.

To question 72, "What defects in color perception constitute failure to pass the examination?" there is a very considerable variation in the replies, and some of the answers show how entirely this matter is misunderstood, at least by the person who fills in the answer to the question. In general a failure to distinguish clearly between red and green will always reject, but there is evidently a great need of better methods and standards in making these tests for color perception, and of a more thorough instruction of the examiners, both physicians and non-medical men, who have charge of these examinations, in order to be sure that they are thoroughly and properly made, and that the results are reliable.

In this matter of color examinations it is also very desirable that the test should be made both by colored worsteds, no names being required, but simply a test by comparison of colors as proposed by Holmgren, and also in every case a test should be made by colored lights which should include various shades of all the lights used for signals, and which should be named by the person examined.

The answers to question 72 may be summarized as follows:

17 roads reject for any defect in color perception;

10 for failure to correctly recognize the colors used in the transportation service;

9 for failure to distinguish red from green or green from red;

4 for color blindness;

4 for failure to promptly select red, white, blue, or green;

4 for failure to distinguish primary colors;

4 for calling red green or green red with the lantern test, or selecting confusion colors with both the green and the rose test skeins;

4 for failure to match worsteds of the same general color;

2 for failure to name colors correctly;

2 for selection of confusion colors;

2 for failure to pass Thomson's test;

2 for failure to readily recognize red, green, or blue;

2 for failure to select red, white, and green;

1 for failure to distinguish white, yellow, green, blue, or red;

1 for failure to distinguish one color from another in certain colors;

1 for failure to pick out all shades of green, pink, and red;

1 for failure to pick out green without confusion.

One road requires train and engine men to be perfect in color perception, and station men perfect for red and green.

To question 75, "Do you re-examine your employees periodically for color? If so, how frequently?" —

37 roads answered no;

22 yes, every two years;

6 once in three years;

2 every two or three years;

4 annually.

To question 76, "Do you re-examine for color before promotion?" —

44 roads answered yes;

36 roads no;

2 not unless deficiency is suspected;

1 provided there has been no examination within two years.

To question 77, "By whom are the examinations as to color perception made?" —

19 roads answered they are made by the company surgeon;

16 by the train master;

15 by an oculist;

6 by division superintendents;

7 by a regularly appointed examiner;

5 by the medical examiners of the relief department;

4 by the chief despatcher;

4 by the heads of departments;

3 by local surgeons;

3 by division superintendent's chief clerk;

3 by the master mechanic;
2 by the train despatcher;
2 by the traveling engineer;
1 by the general manager;
1 by the rule examiner;
1 by the locomotive clerk;
1 by the committee on vision;
1 by the division officers.

Better results would certainly be obtained by having these examinations made by oculists trained in such work, or by men instructed by them who would work under their supervision and approval.

In regard to hearing, 79 roads examine for hearing and 23 do not. 31 use the watch and voice test, 14 the voice alone, 9 the watch alone, 4 the acoumeter and voice, 2 the acoumeter, watch, and voice, 2 Bartlett's acoumeter, 2 voice, watch, and tuning fork, 1 voice, watch, and Galton's whistle.

The standards required to pass the hearing test vary very greatly on different roads. Generally the watch should be heard from one to three feet from the ear, and conversation from ten to twenty feet, but there are hardly more than half a dozen roads that have exactly the same requirements.

The provisions as to classes of men examined, re-examinations, and those who should make the hearing test, correspond very closely to those provided for the vision and color tests.

The report of the Committee on Safety Appliances of the American Railway Association, summarized above so far as it relates to the tests for vision, color sense, and hearing, is a valuable contribution to the better understanding of the conditions under which such tests are now being carried on, and it is to be hoped that this committee will in the future make some recommendations which will bring about more uniform and satisfactory methods and standards.

ON THE CONFUSION IN METHODS OF NUMBERING AND USING PRISMS.

DR. LUCIEN HOWE,

BUFFALO, N. Y.

It is evident that if there were less confusion in our methods of measuring and describing muscular anomalies, ophthalmologists would not only understand each other better but also more uniform results could be obtained in examination and in treatment. The object of this paper is, therefore, to call attention very briefly to that confusion and how it may be remedied at least to some degree.

First. A certain small part of this confusion is due to the lack of uniformity in the prisms themselves.

As one phase of this subject has already been considered at the International Congress in Berlin, it is unnecessary to consider the relative advantages of numbering prisms according to the angle, to the prism dioptrie, centrad, etc. It is sufficient to point out the fact that there still remains a difference in methods of numbering, and that prisms supplied by opticians do differ from each other so decidedly as to have this difference of real clinical importance, especially in the higher numbers.

A second source of confusion is the lack of uniformity in the manner of using the prisms to test the position of the eye when at rest, the static condition or the so-called muscular balance.

It is out of place here to discuss the relative value of these different tests either with the "inspection" or "cover test," Graefe test for distance, the Maddox rod, the phorometer, etc.

The actual fact is, that according to our present methods these different tests often give different results when tried upon the same individual at the same sitting, or the same method may give different results upon the same individual at different sittings.

In other words, there exists as to this, a very decided confusion. It is beyond the scope of this paper to consider the causes of this confusion, but suffice to say that with certain precautions as to uniformity in the methods, it is possible to obtain much greater or entire uniformity in the results of measurement of the so called muscular balance.

A third source of confusion is the lack of uniformity in the manner of using prisms to test the power of adduction and abduction — or the dynamic condition of the eyes. It is well known that if we hold before one eye any one of the revolving prisms and slowly turn the prism in such a direction as to bring the base out, we will find that most individuals can gradually increase their adduction to twelve or fifteen degrees or much more before diplopia is produced.

On the other hand, if after a few minutes rest, a single prism, but a weaker one, be placed before the same eye, in the same way, namely, with the base out, then we often have at once a distinct diplopia. In fact it may be necessary to lessen the strength of the prism by several degrees before the images blend that is, before the degree of real adduction is measured. In other words, when a muscle is measured by gradually increasing the strength of the prism, we find that the desire to fuse the images gives us apparently a high degree of strength for that muscle, whereas if we begin with a strong prism and then decrease the strength, we obtain another and quite a different measurement for the power of that muscle or group of muscles.

Now the fact is, that some practitioners use one method, obtaining one set of results, and other practitioners use another method, obtaining results quite different. It is true greater uniformity would be obtained if all employed only the separate prisms from the test case. But unfortunately they will not do that.

So great is the simplicity and rapidity with which tests can be made by means of the prisms in series, or by the revolving prisms, that these have been and always will be used by ophthalmologists, and it remains only to adopt some uniform method

of testing, so that the individual practitioner may know his own results and others may understand that of which he speaks or writes.

Without entering into detail, it may be stated as to this point also that proper precaution as to uniformity in method will give much more uniform results.

A fourth source of confusion which should be mentioned is in the different terms used to express the same muscular anomalies. The nomenclature of Graefe is still employed in Europe in the terms "latent" convergence, divergence, etc., while usually in America and occasionally in England, we find the conditions described as esophoria, exophoria, etc.

This unfortunate confusion needs only to be mentioned in order to be appreciated.

From the foregoing we find, therefore,

1st. There is often some difference in the strength of the prism which we use.

2d. Confusion arises in part from lack of uniformity in the manner of using prisms to test the static condition — the so called muscular balance, or

3d. From lack of uniformity in using them to test the dynamic condition.

4th. From the existence of different terms to express the same muscular conditions.

In view of so much confusion it seems desirable for this Society to take some formal action which might tend ultimately to the appointment of an international committee, whose duty it would be to report some simple plan which would ensure greater uniformity in methods of examining the muscles and perhaps also agree on some terms for describing the results obtained by our measurements.

By thus taking a single step toward uniformity in methods and terms we might hope to advance to a better understanding of the diagnosis and treatment of muscular anomalies.

ADDITIONAL NOTES ON A CASE OF HIGH ASTIGMATISM.

B. L. MILLIKIN, A.M., M.D.,

Professor of Ophthalmology, Western Reserve University, Ophthalmic Surgeon to Lakeside Hospital, Consulting Ophthalmic Surgeon to Charity Hospital.

In 1893 I reported in detail before this Society a patient who had a very high degree of mixed astigmatism, at that time his refraction being:

O. D. — 10.00 D. cy. ax. 90° (.) + 7.00 D. cy. ax. 180°.

O. S. — 6.00 D. cy. ax. 100° (.)+4.00 D. cy. ax. 10°.

These glasses had been worn with entire comfort until December, 1896. Examination at that time gave the following refraction:

O. D. — 13.00 D. cy. ax. 95° (.) + 7.00 D. cy. ax. 5°.

O. S. — 8.50 D. cy. ax. 100° (.) + 5.00 D. cy. ax. 10°.

It was found that with these glasses he was somewhat presbyopic, and + 2.00 Ds. added to the above glasses enabled him to read ordinary print best at 14 inches. These glasses were worn with entire comfort until March 3, 1902, when the man again reported at my office, giving the history that for two years the sight of both eyes had been failing slightly, the right worse than the left, but with no pain. He was able to read, however, fairly well. From some optician he had secured a pair of + 4 D. glasses for reading, and I have no doubt that this had something to do with his slight discomfort. Examination on this date gave the following result of refraction:

O. D. — 16.50 D. cy. ax. 100° (.) + 10 D. cy. ax. 10° V.= 6/9 + 2.

O. S. — 8.50 D. cy. ax. 100° (.) + 6.00 D. cy. ax. 10° V.= 6/6 — 2.

It is of very great interest to notice that in connection with this high and increasing astigmatism the eye grounds showed no gross pathological conditions present. As may be appreciated,

however, it is difficult or impossible to make out the fine details of the eye ground of either eye. With +2 Ds. added to these glasses he was able to read any print with the exception of diamond.

During the eleven years that this case has been under my observation three things have been of very great interest: In the first place the increase of the astigmatism in the right eye from a total of 17 D. to 26.5 D., and in the left from a total of 10 D. to 14.5 D., the sight after each correction being 6/9 in the right and nearly 6/6 in the left.

The second interesting point in the condition of the right eye is the slight change in the axis, this changing from 90° to 100° during a period of eleven years. The third remarkable feature of the case is that the man has been able to use his eyes as fully and freely as he wished, his work until five years ago being that of a bookkeeper, in which the use of his eyes was incessant. With the last correction he is able to read, carry on his business, that of general manager of a large concern requiring more or less correspondence, traveling on the road, etc. He does this work with entire comfort and great satisfaction, and with no more sense of fatigue or discomfort than any other hale man. The glasses he has worn have always been kept round, as the axis can thus be shifted as may be necessary on account of bending of frames or other reason. For his presbyopia he uses an eye glass frame which he slips on over his distance glasses, making his close work as easy and convenient as the ordinary case of presbyopia.

In the literature at my command I have found no similar case recorded, so that I am inclined to look upon this as a unique one, of very great practical interest and worthy of record.

PERMANENT LEFT HEMIANOPSIA, SEQUEL OF PUERPERAL ECLAMPSIA.

BY HIRAM WOODS, M.D.,
BALTIMORE, MD.

The following case came under my care in September, 1901, through the kindness of my friend, Dr. J. Whitridge Williams of Baltimore, professor of obstetrics in the Johns Hopkins University:

Mrs. X., thirty-three years of age, in good health save for the condition of her eyes, had 20/15 central vision in each eye, refraction error being only 0.5 D. H. Accommodation showed a near point of six diopters. Perimetric examination revealed the fields illustrated in Figs. 1 and 2. In each eye there is left hemianopsia, complete save for a small area above near the median line. The line of separation between the seeing and blind halves in the inferior fields cuts the median line in the right eye, while in the left it encroaches upon the nasal half to about 15°. The greatest interest in the case lies in the history. Mrs. X. was confined with her first child on March 17, 1900. Her previous health had been excellent and the period of gestation showed nothing abnormal until traces of albuminuria were found in the sixth month, and persisted through the rest of the pregnancy. On the morning of the 17th Mrs. X. ate her breakfast with relish and felt well. Between 9 and 10 o'clock, while returning from the toilet to the bedroom she became confused and "lost her way." She was giddy, and did not know where she was. Her husband, a physician, helped her to her room. He tells me that there was high arterial tension, flushed face, and, what he specially noted, very rapid dilatation and contraction of the pupils. Bromide and chloral were administered, but about 11 o'clock, after convulsive twitchings of the limbs for some time, there occurred an eclamptic convulsion, lasting, Dr. X. thinks, not over five minutes. His wife recovered from this in a condition of stupor, from which she

could not be aroused. Dr. Williams was summoned as promptly as possible, and effected instrumental delivery, under chloroform anesthesia, about 2 P. M. There was but one convulsion. The description of the visual disturbances was given me by Mrs. X. herself. While recovering from anesthesia she seemed to "be seeing through steam," yet there was no trouble in seeing all about her. The next day she was troubled with persistence of retinal impressions. She saw the flowers which were on the wall-paper when she looked out the window; a picture opposite her bed followed wherever she turned her eyes; the eyes of her attendants, after she had looked at them a moment, appeared where she next looked, etc. For four days these visual disturbances persisted. Occasionally she suffered from severe headache, most marked along the median line. During the night of the fourth day her headache was atrocious. She was treated with hot application, phenacetin, etc., and toward morning fell asleep, in part, at least, relieved. Shortly after awakening, and while free from pain, she says, "suddenly, as if some one on my left had pulled down a blind, my sight on the left side went out." From this time Mrs. X. made an uneventful recovery from her confinement; the urine showed nothing after two weeks, and, save for her left hemianopsia, she is a well woman. This defect produces typical disturbances in reading and other work. Objective examination showed nothing abnormal in the eyes. The hemianopsia was absolute. I tried to make Wernike's test, and thought I obtained slight pupillary reaction to light in the blind fundus, but I could not be sure of it.

Most of the text-books upon obstetrics give more or less attention to ocular disturbances occurring in connection with puerperal eclampsia. There are certain prodromic symptoms which, occurring in women who are expected to develop eclampsia, indicate that the seizure is approaching. Rapid asthenopia, diplopia, fading of vision with speedy recovery, convulsive movements of the eye, or, as in the case narrated, irregular action of the pupils, are among these warning symptoms. But the most interesting eye troubles are those of vision. They come usually after the seizures, and, as a rule, are in the form of complete loss

of sight. I have seen one such case during the eclamptic attack — a woman, twenty-two years of age, in her first confinement, who had seven or eight convulsions. After the second her sight was gone. I saw her a few hours later; pupils were dilated ad maximum, inactive. There was not even light perception, and the fundus of each eye was normal. She remained blind for four days, and then recovered. A hemiplegia persisted three weeks. There have been two pregnancies since and no trouble. This is the usual type observed in this rare disease, eclamptic blindness. Hemianopsia, however, is almost unknown. In a fairly exhaustive search of literature by myself and friend, Dr. Johnston, one of our hospital staff, but one reference to it has been found. Dr. Williams furnished me with this. It is a report made by Dr. G. Knapp. The following translation of Knapp's observations is from the Prager med. Wochenschrift, 1901, No. 21:

"Compared to amaurosis, which is frequently observed in eclampsia, hemianopsia is a rare occurrence, which has thus far

FIG. 1. FIG. 2.

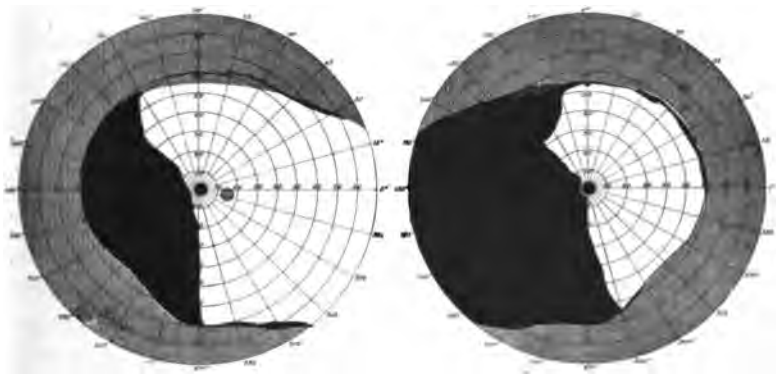

RIGHT EYE. LEFT EYE.

been described but twice. Knapp's patient was a 27-year-old primipara, who was brought to the clinic in coma, and delivered by version and extraction after dilatation of the cervix with Bossi's instrument. When consciousness returned she complained of disturbances of vision. The right halves of the visual fields showed themselves to be disturbed up to the middle line, as in them the hand could be seen only as if in the thickest fog. The symptoms disappeared within the next few days.

"According to F. Pick, it resulted from a toxic paralysis of the central tracts of the optic nerve, with more marked involvement of one hemisphere, so that after the disappearance of the amaurosis, which at first is always present, hemianopsia can remain for a longer or shorter time. The well-known half-sided motor disturbances which occur in neuremia confirm this view."

The hemianopsia in this case was temporary. If there is on record another case of permanent hemianopsia from puerperal eclampsia I have not found it.

The pathogenesis of the trouble is not entirely clear. Absence of any and all other nerve disturbance justifies one in assuming a nuclear lesion. We can, possibly, study with advantage some of the modern teachings concerning the etiology and pathology of puerperal eclampsia. I shall go over this briefly, referring anyone specially interested in the reasons for the conclusions given to such works as the American System of Obstetrics and other authorities. Among such I doubt not that the forthcoming work of Dr. Williams upon obstetrics will take a high place. The author has kindly put at my disposal some of the advance sheets of this work, and it is from these and the American System that I quote. Uremia is not accepted as either the basal or chief cause of puerperal eclampsia. Absence of convulsive seizures in nephritics, occurrence of them in women without or with only slight lesion of the kidney, essential differences in the renal from the puerperal convulsion — these are among the reasons for abandoning the teaching that nephritis is the cause of eclampsia. From the pages loaned by Dr. Williams it appears that in 1886 Jürgens and Klebs pointed out the existence of a hemorrhagic hepatitis in certain cases of eclampsia. Others observed similar changes, until in 1893 Schmorl published a monograph based upon seventeen autopsies of women dead of eclampsia. He found in every case lesions of the liver, which he considered more characteristic than those observed in the kidneys. These consisted of irregularly-shaped reddish or whitish areas scattered throughout the liver, but particularly marked in the neighborhood of the smaller portal vessels. They are areas of necrosis,

and their formation was attributed to degenerative changes following thrombotic processes in the smaller portal vessels. The same findings were recorded from time to time by others, and in 1902 Schmorl again published them as occurring in seventy-one of seventy-six autopsies. Many European observers have accepted them as the most constant eclamptic pathological change, and consider that the entire process is due to an impairment of the hepatic function (hepato-toxemia). Dr. Williams records a number of his own autopsies, in which the hepatic findings were constant. Similar changes are observed less constantly in the brain. Concerning this Dr. Williams says: "Various statements are made concerning the pathological findings in the brain, œdema, hyperemia, thrombosis, and apoplexy being described as the main lesions. Prutz noted œdema in 42 per cent., hyperemia in 35 per cent., apoplexy in 13 per cent., while the brain was apparently normal in 10 per cent. of his cases. Schmorl noted in fifty-eight out of sixty-five autopsies the presence of thrombi in the smaller cerebral vessels, and regarded them as the cause of the small areas of necrosis which are so often observed." Dr. Williams concludes his study of the pathology as follows: "The main lesions of eclampsia are found in the liver, kidneys, and brain, although those in the liver are most characteristic. Either we have included under the term 'eclampsia' a number of different diseases, each with different anatomical lesions, or, what is more probable, we have to deal with a disease which is caused by some as yet unknown poisonous substance circulating in the blood, which may give rise to lesions of varying intensity in the different organs."

This view of the pathology of eclampsia throws, it seems to me, light upon the ocular disturbances. We are dealing with a poisonous substance in the circulation, probably of hepatic origin, capable of producing decided nerve disturbances, which, as a rule, recover if the woman lives. But this poison may produce thrombi of smaller vessels, lead to areas of necrosis, and thus bring about permanent defect. The blindness, which comes like an avalanche, completely recovering in a few days, is most proba-

bly the result of the poison without organic change. As the poison is eliminated, its effects cease; but in a few cases thrombosis destroys a limited area, and if this area happens to be a part of the brain which has important function, that function is irreparably lost. And so, it seems to me, is the hemianopsia in my case most probably explained.

THE USE OF SUBCONJUNCTIVAL INJECTIONS OF SUBLIMATE IN CASES OF ORBITAL CELLULITIS.

BY CHARLES STEDMAN BULL, M.D.,
NEW YORK.

Miss F., aged 58, governess, was first seen March 24, 1902, and told the following story: Ten days before she noticed a small pimple on the terminal phalanx of the right index finger, which was soon accompanied by great swelling and severe pain. It was diagnosed as a felon, and on the third day it was freely incised. She *thinks* she rubbed her *left eye* with this finger while it was discharging. Three days before I saw her the left eye smarted, the lids became rapidly swollen and very painful, and there was a thin serous discharge which was stained with blood. The symptoms grew rapidly worse, and when I saw her the condition was as follows: The lids were enormously swollen, very hard, and purplish in hue, and there was a very extensive and pronounced chemosis. The eyeball protruded between the swollen lids and was completely immovable. The orbital tissue was densely infiltrated and the infiltration extended from the swollen lids upwards upon the forehead, outwards upon the temple, and downwards upon the cheek. The cornea was still clear, the iris was dilated and immovable, and the lens was clear, but the vitreous was very cloudy and no view of the fundus could be obtained. The parotid and upper cervical glands on the *right side* were enormously swollen and very hard. A slight serosanguinolent discharge could be wiped from the conjunctival surface of the left eye. There was constant severe pain, and the

temperature was 102⅘. The right eye was intact and remained so throughout.

The patient was at once sent to the Eye Infirmary and put in a private room in the isolation pavilion. Smears were made from the slight conjunctival secretion and examined. The secretion contained a few pus cells, with one or two rather large micrococci within the pus cells, and occasionally three within a cell, but nothing characteristic or distinguishing.

Constant hot applications were made to the swollen parts, and, owing to the rapid pulse and irregular heart action, iron, quinine, digitalis, and strychnia were administered in large doses, together with milk and whisky.

In spite of the treatment the infiltration of the subcutaneous connective tissue continued to extend. At no time was there any purulent discharge from the conjunctiva or orbit. On the third day after entrance into the hospital two large free incisions were made into the orbital tissue on the nasal and temporal sides of the eyeball in hopes of relieving the tension and finding pus, but without success. The cornea began to show infiltration on the fourth day, and within a week was entirely opaque and appeared about to slough. The incisions into the orbital tissue were repeated several times, and free incisions were also made in both lids and just above the eyebrow, but in no case was pus ever found. The slight secretion from the conjunctiva did not change its character, but was frequently tinged with blood. In the folds of the chemotic conjunctiva appeared what looked like small sloughs of the conjunctiva, which could be readily removed with the forceps, leaving a bleeding surface. These sloughs were carefully examined on repeated occasions by Dr. Dixon, the pathologist of the Infirmary, but nothing very definite was determined. The smears gave a negative result. The sloughs were filled with cocci, some diplococci, and on one occasion what looked like pneumococcus were found, but the mass of the cocci resembled the staphylococcus albus. Cultivations after twenty hours showed colonies of the staphylococcus albus.

On April 2d, nine days after the patient entered the hospital,

Dr. Dixon removed two sloughs from the conjunctiva, and placed one in the anterior chamber of the *left eye* of a small gray rabbit, and the other under the palpebral conjunctiva of the *right eye* of the same rabbit. Twenty-four hours after inoculation there was no reaction in the *right eye*. In the *left eye* the anterior chamber showed considerable opacity and the pupil could not be seen, and the wound gaped. Two days later there was a slight swelling about the implantation in the lid of the right eye. On the sixth day there was a distinct reddish nodule in the conjunctiva of the right eyelid. In the left eye there was iritis, with dilated vessels, a hazy cornea and aqueous humor, but no sign of panophthalmitis.

On the fourteenth day after I saw the patient, incisions into the orbit and lids having failed to find pus or diminish the tension, I began subcutaneous and subconjunctival injections into the lids and orbit of a solution of sublimate (1-1000), injecting five minims of a four per cent. cocaine solution and ten minims of the sublimate solution each time. The injections into the orbit were made as deeply as possible in the orbital tissue. The injections caused a little smarting, but no severe pain. They were repeated every day until May 3d (the thirty-eighth day). On the seventh day after beginning the injections the upper lid and eyebrow showed evidences of fluctuation, and free incisions evacuated about two drachms of pus and some blood. The wounds were thoroughly irrigated and packed with gauze. The case began to show an improvement after the third injection, the tissues becoming softer, and the constant pain very much less.

By May 1st considerable motion had been regained in the upper lid, and in the movements of the eyeball outwards, inwards, and downwards. All hardness had disappeared, and the infiltration was confined to the inner end of the lower lid and inner angle of the orbit. The cornea had partially cleared, and the iris was widely dilated.

By May 16th there was free mobility of the eyeball in all directions, and the upper lid could be raised so as to reveal the entire cornea. The corneal opacity had cleared except for a small central area, and the fundus could be seen indistinctly.

By June 6th there was no sign of infiltration or swelling in the lids or orbit, the cornea was almost entirely clear and the fundus showed a papillitis in the atrophic stage. The lens and vitreous were perfectly transparent, but there was no perception of light.

The swollen glands on the right side, which had remained unchanged until after the sublimate injections were begun, gradually softened and regained their normal condition. The right eye remained intact throughout.

In the last number of the Royal London Ophthalmic Hospital Reports, Vol. XV, Part II, Nettleship reports an interesting case, which bears upon the case just reported. The patient was a woman, aet. 42, who had a slight "festered sore" upon the dorsum of the right index finger, which was followed by a swelling in the axilla. The sore soon healed, but the swelling in the axilla developed into an abscess. She began to have headaches, and in a few days complained of severe pain in the *left* orbit whenever the eyes were turned to the left. The abscess in the axilla was opened and the temperature became normal, but in a few days the left eye became blind, without any signs of orbital cellulitis. Ten days later the right eye failed rapidly in the same way. Both eyes showed papillitis, without any evidence of orbital cellulitis or affection of the oculo-motor nerves. The eye complications occurred from ten to twelve weeks after the sore on the finger. Both eyes eventually recovered useful vision. Nettleship is inclined to believe that both optic nerves were affected at the chiasm by inflammation of the underlying periosteum or bone, and that a septic embolism was the cause. There was nothing to suggest thrombosis of the venous sinuses nor suppuration of the sphenoidal sinus.

ON THE PRIMARY INSERTIONS OF THE OCULAR MUSCLES.

BY DR. LUCIEN HOWE,
BUFFALO, N. Y.

Definition. When considering the insertions of the ocular muscles it is necessary to bear in mind a fact which is easily observed anatomically, and which undoubtedly has an important physiological and clinical bearing. It is that these insertions do not terminate abruptly at any one point, as they are usually represented, but near the insertion small connective tissue fibers pass from the muscle to the globe or to adjacent structures. These fibrous bands make it difficult sometimes to say just where that tendinous insertion actually ends, and where it is continued into the adjacent connective tissues.

The insertions of the tendons themselves may therefore be called the primary insertions of the ocular muscles and to these attention is especially directed in the present paper.

The connective tissue fibers, more or less extensive, just mentioned may be called the secondary insertions. They are treated more in detail elsewhere* and referred to here only incidentally.

Reasons for the Study and its Literature. It is probable that a considerable part of our confusion of ideas concerning the ocular muscles is due to our ignorance of their exact anatomical conditions and relations. We naturally assume that the force of every such muscle is exerted in a plane determined by three points, namely. The center of motion of the globe, the point of origin, and the point of insertion of the muscle. The first point, the center of motion, we can determine to within a fraction of a millimeter. The second point is constant and is also known. Concerning the point of insertion — the point with which we

* Prize Essay of the Medical Society of the State of New York, 1900.

are most frequently interested in practice — for some muscles, at least, further data are much desired.

When we ask ourselves what we actually know of the insertions of these muscles, most practitioners can simply recall certain familiar inaccurate wood cuts which have often been reproduced — or else certain stock quotations from authorities now otherwise unread.

When we examine the literature of the subject we find that some exact measurements were made by Volkmann in 1869, by Fuchs in 1884, and more recently by Weiss and Schneller. The number is really small, however, of globes which have been accurately measured with regard to the insertions of the ocular muscles.

The results obtained by German students of the subject have just been summarized in the chapter contributed by Merkle and Kallius in that part of the second edition of Graefe-Saemisch which is now being published.

The anatomical work done in that direction by Motais is perhaps the best known in this country, his plates having been copied by Landolt in Norris and Oliver, by Maddox, and by others. His monograph, however, gives no results of such measurements, and these beautifully colored diagrams, especially those of the check ligaments, do not correspond with sections of the connective tissue stained by more recent methods.

It is unfortunately evident, therefore, that it is desirable to have more complete and accurate data concerning the insertion of the tendons into the globe. This includes the position of the lines of insertion, the length of these lines, and the direction of their arcs, when insertions in arcs of a circle do exist. The object of this paper is to supply some of these data.

The material used for this study was obtained from the post-mortem room, and other subjects here, from specimens in my own collection, some from Drs. Ziegler and Oliver of Philadelphia and Dr. George S. Dixon of New York. To these colleagues my thanks are due for their cordial co-operation.

Methods of Study. The plan of study was somewhat similar to that followed by Fuchs, but I think much more exact, for, by marking the planes of the globe with very fine rubber bands, the distance could be measured with ease and accuracy.

It should be added, also, that the plan of viewing these dissections under magnification by the Jackson double loupe is a distinct advantage.

A few words, therefore, are necessary to explain how these measurements are made and recorded.

If the globe is at all collapsed it should be inflated. It should then be identified as right or left, as can easily be done from the direction of the fibers of the oblique. The antero-posterior diameter should be determined by a suitable measure (an accurate form of the old-fashioned foot rule, which is fitted with a vernier) and its length recorded. Then the equator can be determined and the vertical and horizontal planes. It is a decided advantage, as just mentioned, to mark these by delicate rubber bands slipped over the globe.

In recording the attachments of the ocular muscles it is convenient to represent the curves of the insertion in the same manner as lines on the earth are shown in the ordinary Mercator's projection, as suggested by Fuchs. Also, it is desirable to do this on a scale at least four times the size of the globe itself. If, therefore, the diameter of the normal eye is 23 millimeters, the length of the equator is 72.2 millimeters, and the line on which it is plotted is 288.8. In the plan, let this line of the equator be B B. The line representing the edge of the cornea is then A A parallel to B B, and a proportional distance in front. It is true that the cornea is not perfectly circular, but its representation by a straight line is sufficiently exact for this purpose.

Finally, the four perpendiculars are the representations by the Mercator projection of the lines in which the globe is cut by the horizontal and vertical planes. From these various lines it is possible to locate the positions of the various muscular insertions.

From the drawings showing the muscular insertions of each

eye it is easy, of course, to construct a composite drawing. For this composite all of the right eyes can be grouped together, and all of the left, as has been done here, or other groups can be made according to refraction, etc.

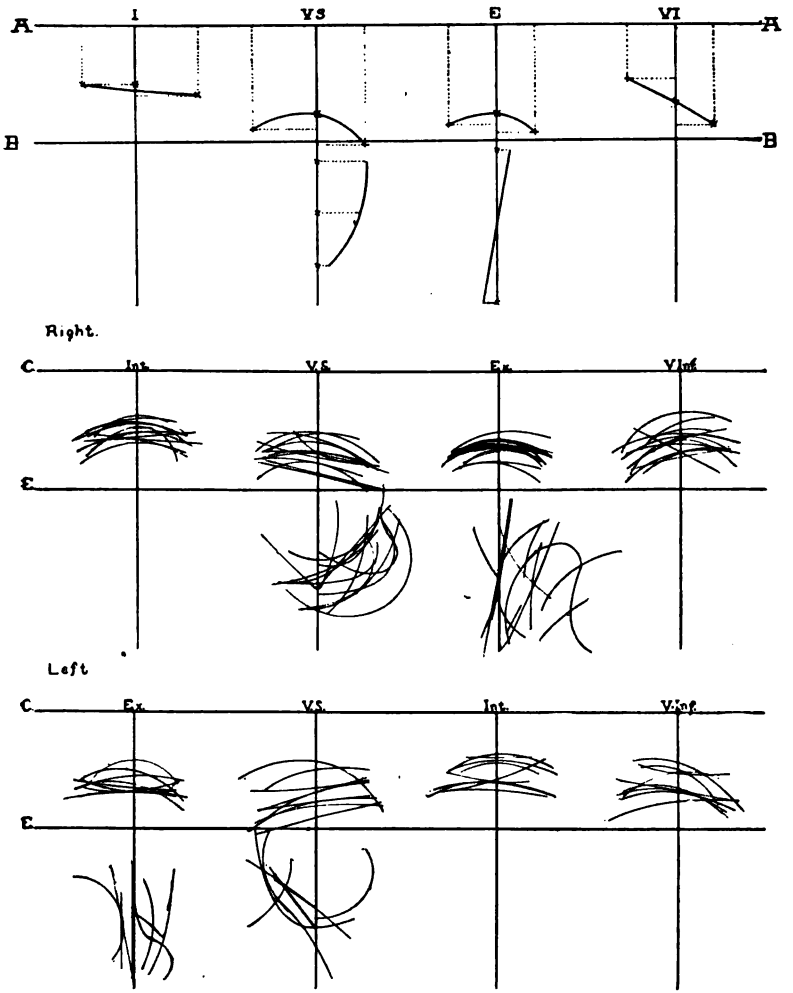

Also, tables can be made showing the distances of the insertions from the corneal edge, like the following, or the length of the tendon, etc.

As for the findings by these measurements, they may be stated:

First. Insertions of the four recti.

A. Concerning the distances of these insertions from the edge of the cornea.

The following table shows this at a glance.

	4 Emmetropic.			11 Myopic.			2 Hypermetropic.			
	Maximum.	Minimum.	Average.	Maximum.	Minimum.	Average.	Maximum.	Minimum.	Average.	Average.
Rectus internus,.....	7.0	4.0	5.8	6.0	5.0	5.5	8.0	4.5	5.7	5.72
Rectus inferior,.....	8.0	5.0	7.0	7.0	6.0	6.5	8.0	4.0	6.6	6.7
Rectus externus,.....	9.0	6.0	7.6	7.5	7.0	7.2	9.0	6.c	7.4	7.4
Rectus superior,. ...	10.2	5.0	7.8	8.5	6.0	7.2	10.5	6.c	7.9	7.6

EMMETROPIA.

Eye No.	Int.	Inf.	Ext.	Sup.
2	.4	5	.6	.5
9	5.5	7	7.5	.8
4	.7	8	.9	10.2
17	.7	8	.8	.8
Average,.....	5.875	7	7.625	7.8

MYOPIA.

No.	Int.	Inf.	Ext.	Sup.
1	5.5	4.0	6.0	6.0
3	7.0	7.7	7.7	10.5
5	6.5	8.0	9.0	9.0
6	5.0	6.0	7.7	6.0
7	5.0	6.5	7.5	7.0
8	5.2	7.0	7.0	8.0
10	4.5	5.0	6.5	6.5
12	4.5	6.5	7.0	8.0
13	6.5	6.0	7.5	9.0
15	8.0	7.0	6.5	9.0
16	6.0	7.0	9.0	8.7
Average,.....	5.79	6.60	7.4	7.97

HYPERMETROPIA.

Eye No.	Int.	Inf.	Ext.	Sup.
11	5.0	6.0	7.5	8.5
14	6.0	7.0	7.0	6.0
Average,.....	5.5	6.5	7.2	7.2

	Int.	Inf.	Ext.	Sup.
Average of total number,.	5.7	6.7	7.4	7.6

It will be observed that the figures in this table do not differ essentially from what we generally find in the text-books concerning the distance of the insertion of these tendons from the edge of the cornea. It will be noticed also that their average distance is roughly represented by a spiral which, beginning with the insertion of the internal rectus muscle, at a little over five millimeters from the cornea, passes first downward to meet the inferior rectus at a little over six millimeters from the cornea, then outward at somewhat over six and one-half millimeters from the cornea, and then upward to the superior rectus, which is nearly eight millimeters distant.

B. Relation of these insertions to the vertical and horizontal planes, or the relative position of these insertions up or down for the internal and external, and in or out for the superior and inferior recti. These relations, like the distance from the tendon of the cornea, are also comparatively constant. Occasionally the center of the internal rectus is slightly below the horizontal line, and the superior or inferior recti are occasionally toward the nasal side of the vertical meridian. But this occurs only in a small percentage of cases.

C. The arc of insertion of the tendons of the recti. Here we find considerable variation. In general the arcs of insertion of the internal and external are convex to the corneal tangent, but, in exceptional cases, parallel to that tangent. In the superior and inferior recti however, the arc is not only more convex, but, ordinarily, placed at an angle with that line.

D. As for the length of these arcs of the insertion of the recti, the internal is usually the shortest, and the superior the longest, even excluding those secondary bands which pass imperceptibly into adjacent connective tissue. As might be expected, these arcs of insertion in the myopic (the larger) globes are longer than in the normal eye.

Second. Insertions of the superior oblique.

These are particularly interesting, probably of importance from the physiological standpoint, and at least new as far as the present data are concerned. Former students of this subject

have also noticed very decided variations in the insertions of this muscle, and Fuchs has mentioned two distinct types, according to the length and position of the arcs of insertion. One of these types includes those in which the arc of insertion is quite on the top of the globe; that is, it crosses the vertical meridian, its anterior end being bent inward.

The second type is that in which the insertion lies entirely to the lower side of the vertical meridian.

Examples of these two are easily recognized, but the amount of variation in the position and in the length of the tendon of the insertion of the superior oblique, is so great as to make any such classification practically impossible. One type merges into the other by every possible variation, the arc being bent sometimes almost at right angles or, as it were, in a wave-like form.

Third. The inferior oblique.

The insertions of this muscle vary even more than that of the superior oblique.

A. The position. This is usually described as being in the center of the external and inferior quadrant of the posterior half of the globe. Exact measurements, however, show that the insertion may be in the lower part of this quadrant, in the upper part, or may even pass above the horizontal plane.

B. Length of arc or breadth. Its tendon is described as the shortest of all the extrinsic muscles. But such was not found to be the case, and indeed its average was greater than of any of the other muscles except the superior oblique and the superior rectus. It must be admitted, however, that it is often difficult to determine just where the primary insertion of the oblique ends and the secondary insertions begin, because of its secondary insertions in the form of lateral extensions of connective tissue.

C. Form of the line of insertion. This also is extremely irregular. Sometimes it is an arc with the concavity down and forward. Sometimes only a straight line or S shaped or, in one instance, a distinct break occurred and it bifurcated when it was lost on the sclera.

These individual variations in the attachment of the muscles

have probably a clinical importance which we have not thus far appreciated. For if an internal rectus, for example, has its attachment in an oblique line directed from above and upward, down and backward, then evidently its action when turning the eye in, is unequal above and below the horizontal plane.

In order to compensate for this anomalous attachment, we would naturally expect other muscles also to occupy a more or less unusual position, and this as a rule does exist.

Now, when making a tenotomy of the internal rectus, for example, it is easy under ordinary circumstances to rotate the eye outward, examine the tendon which has been divided, and measure its distance from the cornea as the arc of the attachment also can be seen almost as readily as on the eye of the cadaver.

If this were done more frequently it is probable that a clue might be obtained as to the cause of these disappointing results in the production of a sursum or deorsum vergens which occasionally are met with by every operator.

Finally a word in regard to the relation of the insertions of the two obliques to the vorticose veins.

Many years ago Arlt advanced the theory that progressive myopia was due to the pressure of the muscles upon the vorticose veins. Since then it is generally taken for granted that, inasmuch as these veins pass obliquely through the sclera and as pressure upon them must naturally increase intraocular tension, therefore any or all of the muscles may act as causative factors in producing this increase of tension. This theory is strengthened by the usual figures representing the vorticose veins as emerging nearer the equator.

More exact study of these veins, however, shows that in the larger proportion of cases, they open in the posterior half of the globe, and are, therefore, not pressed upon by the recti. It happens, however, that one of these is very closely related to the large flat tendon of the superior oblique and the opening of another is usually situated near the insertion of the inferior oblique.

A number of measurements have been made of these, and it

is probable that these two muscles do exert a marked effect in some individuals in preventing the venous outflow. It must be admitted, however, that it is not always easy to see these openings with the ordinary magnification.

The conclusions of this paper can be summed up as follows:

First, in regard to the recti.

A. The distance of the central portion of the tendon from the margin of the cornea may be represented by a spiral which, beginning near the internal rectus a little more than five millimeters distant, extends down, out, and upward, to the superior rectus at about 7¾ millimeters.

Second. The size and direction of these insertions of the recti varies in different individuals, the general direction, however, being comparatively constant.

Third. The insertion of the superior oblique is more variable than that of the recti, not only as to its position, but in its length and form. The insertion of the inferior oblique is the most irregular of all, both as to position, size, and form.

Fourth. The tendons of the two latter muscles have an important relation to the exit of two out of the four or five vorticose veins.

Fifth. In view of the average obtained from these sixteen eyes it is necessary to modify somewhat the average of former measurements, as they have been summed up and presented in the diagram recently given in Graefe-Saemisch. While the general position, size, and form of the insertions of the recti would remain about the same, the position of the superior oblique apparently should be changed.

Most of the text-books state that the line of insertion of the oblique muscles makes an angle of about fifty-one degrees with the vertical anterior-posterior plane of the eye. In those which I have examined I find, however, that this angle appears to be larger.

Also, as to the inferior oblique, the line of its insertion must be made longer, and it should be brought nearer to the horizontal plane than in this typical figure which is supposed to represent the composite of measurements made before.

Sixth. The physiological bearing of these measurements is that in any computation as to the action of the extrinsic muscles we must take into account the fact

A. That variations occur in them all.

B. That these are especially frequent with the oblique ; and

C. The plane of action of the two obliques must be changed to accord with the new position given in passing through the center of motion of the globe, the origin and the actual insertion.

Seventh. While the clinical bearing of these measurements may not appear of immediate importance in every operation for tenotomy, their meaning is not to be left out of account in those rather anomalous cases where unexpected deviations occur. It is probable that a study of these individual variations in the insertion of the recti which may be observed while making the operation will also assist in correcting a secondary deviation which might otherwise be inexplicable.

Although the possibilities in that direction can only be mentioned in a paper devoted entirely to an anatomical question, it is not too much to expect that a more exact study of the variations of insertion in the individual eye may throw considerable light on certain obscure questions regarding operations for strabismus.

A CASE OF UNILATERAL HEMIANOPSIA IN WHICH THE WERNICKE HEMIANOPSIC PUPILLARY REACTION WAS PRESENT.

By CHARLES J. KIPP, M.D.,
Newark, N. J.

An unmarried woman, about 50 years of age, who had been, previous to the accident, in excellent health, was thrown from a carriage and struck on her head. She was taken to a hospital in an unconscious condition and remained in this condition for three weeks. On recovering consciousness she noticed that

she was blind in the left eye and that the vision of the right eye was much impaired.

I saw her for the first time about three months after the accident. She was at that time in fair health, and the function of the other senses was unimpaired. She has an unadherent scar on right half of forehead and the upper lid of right eye. Both eyes were normal in appearance and the mobility of each was unimpaired. The right eye was emmetropic and $5\frac{5}{10}$. The ophthalmoscopic examination revealed nothing abnormal, except perhaps slight blanching of the nasal half of the optic papilla. The examination of the visual field of this eye showed right hemianopsia, the defect passing through the center of fixation. The left half of the field was of normal extent for form and for color.

The left eye was totally blind. The pupil was somewhat larger than that of the right eye, did not contract on exposure to light, but reacted consensually. The optic papilla was very white and the vessels were much smaller than those of the right eye.

Examination of the pupillary reaction of the right eye according to the Schmidt-Rimpler method left it undecided whether or not the blind half of the retina reacted to light less than the other half. Several examinations made since then have, however, convinced me that the pupil contracts much more promptly and more extensively when the seeing half of the retina is illuminated than when the light is thrown on the blind half. In the last few months I have made a number of examinations with an instrument devised by Drs. v. Fragstein and Kemper of Wiesbaden, Germany, and described in Zehnder's Klinische Monatsblätter, 1899, page 243, and I am now no longer in doubt that the contraction of the pupil takes place only, or at least more promptly and more extensively, when the light falls on the temporal half of the retina. I have taken every precaution to exclude error. The examination was made in a long dark room, with the patient's eye fixed on an object twenty feet away. Haab's brain-cortex reflex of the pupil I kept in mind, and I am sure that the contraction was not the result of it. The pupil of the left eye contracted consensually.

It seems most probable that in this case the left optic tract was torn or otherwise injured, and that the left optic nerve was torn or compressed in the optic foramen, perhaps by fracture of the bone, or that the chiasm was torn in the median line.

There are a few cases on record similar to the one here reported and are to be found in Vossius: Ueber die hemianopische Pupilenstarre. Halle, a. s., 1901. His own case is almost identical with the one reported above, except that in his case one-sided deafness was present, which was supposed to have been the result of fracture of the petrous portion of the temporal bone.

Vossius (op. cit.) says that about an equal number of writers approve of and oppose Wernicke's teaching. Some deny the existence of and others the possibility of bringing about the pupillary phenomenon. It is no doubt but seldom seen, as the fundamental condition for bringing it about, *i. e.*, basal affection of the chiasm and of the optic tracts, with complete interruption of the conductibility, is not very frequently met with. It is therefore very desirable that every case in which the hemianopic inaction, or rather the hemianopic pupillary reaction, is observed be published. In this I agree with him, and therefore put the above case on record.

VOL. IX.—INDEX.

INDEX OF SUBJECTS.

PAGE.

Adenoma of meibomian glands, Dr. H. Knapp, ... 328
Alexia — mind blindness, case of, Dr. E. E. Jack, ... 122
Amblyopia from non-use, improvement of vision in, Dr. H. Friedenwald, ... 612
Anchylostomiasis, eye complications in, Dr. H. F. Hansell, . . 377
Anophthalmos congenitus, Dr. J. H. Claiborne, ... 370
Astigmatism, additional notes on case of high, Dr. B. L. Millikin, 657
Carcinoma, double metastatic, Dr. E. E. Jack, ... 483
Carcinoma (metastatic) of one optic nerve, Dr. W. A. Holden, . 477
Cataract extraction, two unusual complications, Dr. T. R. Pooley, 518
Cavernous-sinus thrombosis following grippe, Dr. E. E. Jack, . 545
Chorio-retinitis, acute circumscribed exudative, Dr. H. Friedenwald, 577
Choroidal disease, two unusual cases of, Dr. W. H. Wilder, . . 111
Circle of diffusion in correction of ametropia, Drs. Wm. and A. G. Thomson, ... 572
Color-blindness from tobacco amblyopia, not detected by wool tests, but by lamp, Dr. A. G. Thomson, ... 540
Congenital coloboma of eyelid, Dr. W. E. Lambert, ... 402
Congenital orbital cyst with microphthalmos, Dr. G. C. Harlan, . 474
Conjunctival flap and cataract wound, Dr. F. M. Wilson, . . 503
Corneal loupe, Dr. C. Koller, ... 385
Corneal section for cataract and the cataract knife, Dr. E. Jackson, 145
Convergent strabismus — case of transient, spastic, Dr. S. Theobald, 167
Cyst of vitreous, Dr. C. Koller, ... 380
Dendritic keratitis and marginal ulcer of cornea — treatment of, with tincture of iodine, Dr. H. Friedenwald, ... 129
Detachment of retina treated by drainage incision, Dr. W. K. Rogers, 525
Dioptrics of astigmatic refraction, Dr. H. Knapp, ... 620
Displacements of the eyeball by disease of the frontal and ethmoid sinuses, Dr. S. D. Risley, ... 72
Distension of nasal accessory sinuses involving the orbit, Dr. G. C. Harlan, ... 44
Dropsical degeneration of rod and cone cells of the retina simulating glioma, Drs. de Schweinitz and Shumway, ... 283
Endothelioma of orbit, Dr. C. A. Veasey, ... 464
Entropion, operation for atrophic, esp. of lower lid, Dr. A. E. Ewing, 15
Entropion, operative treatment by transplantation of flap of mucous membrane, Dr. J. E. Weeks, ... 18
Exfoliation of the anterior layers of the iris, with partial opacity of the lens, Dr. E. Jackson, ... 149
Extraction metallic fragments from vitreous located by X-rays, Dr. S. D. Risley, ... 562
Foreign body in eyeball removed after eighteen years. Repeated sympathetic inflammation without loss of vision, Dr. A. A. Hubbell, ... 347
Foreign body removed from anterior chamber; perfect vision; photograph of foreign body in situ before removal, Dr. S. B. St. John, ... 345
Frontal headaches apparently ocular, but really nasal in origin, and the nasal condition found in these cases, Drs. A. E. Ewing and G. Sluder, ... 60

PAGE.

Frontal sinus and anterior ethmoidal cells, lesions of, in infancy and old age, Dr. R. Sattler, ... 50
Glaucoma, post op, history fifty cases, Dr. C. S. Bull, . . . 429
Glaucoma, simple, treated by resection of cervical sympathetic ganglia, Dr. J. E. Weeks, ... 441
Glaucoma, spasm of accommodation in, relieved by eserine, Dr. J. A. Lippincott, ... 178
Hemianopsia, case of unilateral with Wernicke pupillary reaction, Dr. C. J. Kipp, ... 678
Hemianopsia, permanent sequel puerperal eclampsia, Dr. H. Woods, ... 659
High Myopia, surgical treatment of, case of, Dr. C. W. Kollock, . 100
Homonymous similar sector defects in visual fields, Dr. S. M. Burnett, ... 118
Hunterian chancre of caruncle, Dr. N. J. Hepburn, . . . 383
Hypertrophy of the lid margin, unusual case of chronic inflammatory, Dr. F. E. Cheney, ... 367
Incandescent electric lamp for ophthalmoscopic examination, Dr. C. H. Williams, ... 387
Instrument for testing the position of the axes of the eyes, Dr. C. H. Williams, ... 388
Lachrymal Gland, dislocation of, Dr. W. F. Mittendorf, . . . 382
Lachrymal Gland, hypertrophy of, Dr. W. E. Lambert, . . 403
Lachrymal Gland in chronic dacryo-cystitis, histology of, Dr. G. E. de Schweinitz, ... 182
Lacrymal sac and gland, excision of, followed by neuro-paralytic keratitis, Dr. C. A. Veasey, ... 101
Lantern for testing color-perception, Dr. H. C. Williams, . . 192
Lantern for detecting color-blindness, Drs. Wm. and A. G. Thomson, ... 391
Lantern for detecting color-blindness in R. R. employees, Dr. Wm. Thomson, ... 189
Lenses of hanged criminal, Dr. C. A. Oliver, ... 490
Magnets, on the advantages of strong portable, Dr. J. A. Lippincott, 152
Melano-sarcoma of choroid and orbit, Dr. S. B. St. John, . . 469
Metastatic Choroiditis occurring in pneumonia due to grippe, Dr. C. S. Bull, ... 316
Methyl alcohol debauch, Dr. H. W. Ring, ... 529
Observations on some blind but quiet and apparently inoffensive eyes, Dr. S. C. Ayres, ... 137
Ocular changes from injection of bacillus typhosus into vitreous, Dr. C. A. Oliver, ... 494
Ocular muscles, primary insertions of, Dr. L. Howe, . . . 668
Opacity of posterior capsule of the lens due to remains of membrana vasculosa lentis, Dr. A. G. Thomson, ... 108
Optic atrophy from blows on forehead and temple, Dr. J. A. Spalding, ... 83
Optic nerve, tumor of, with intracranial complications, Dr. F. Buller, ... 633
Optic neuritis, case of acute double retro-bulbar, hereditary in origin, Dr. H. F. Hansell, ... 114
Ossification occurring in eye, Dr. B. L. Millikin, ... 589
Panophthalmitis and septicaemia (double) from abscess of the knee, Dr. E. Jackson, ... 335
Papilloma of orbital conjunctiva and cornea, Dr. W. E. Lambert, 404
Papilloma of the plica semi-lunaris, Dr. G. E. de Schweinitz, . 187
Perimeter, an improved, Dr. F. D. Skeel, ... 196
Posterior spinal sclerosis, ocular symptoms in, Dr. C. A. Oliver, . 173
Primary non-infective thrombosis of the cavernous sinus, operation, Dr. H. Knapp, ... 77

PAGE.

Prisms, on the confusion in methods of numbering, Dr. L. Howe, 654
Ptosis, congenital, treated by partial resection of tarsal cartilage, Dr. E. Gruening, ... 574
Relative accommodation and convergence, instrument for their measurement, Dr. L. Howe, ... 92
Report of committee on standards and methods of examination for acuteness of vision, color-sense, and hearing, . . . 406
Report of committee on supplementary histories of cases, . . 215
Retro-bulbar Lympho-sarcoma, removal with preservation of normal vision, Dr. C. A. Oliver, ... 36
Sarcoma of choroid followed by phthisis bulbi, etc., Dr. C. J. Kipp, 332
Sarcoma of eyelid, case of, Dr. H. Friedenwald, ... 133
Sarcoma of the iris, Dr. E. Gruening, ... 343
Sarcoma of the limbus associated with an implanted secondary growth in the lower lid, Drs. Wadsworth and Verhoeff, . 274
Sclero-corneal cyst, Dr. E. Gruening, ... 343
Strabismus in children, operative treatment, Dr. S. Theobald, . 556
Subconjunctival injections of sublimate in orbital cellulitis, Dr. C. S. Bull, ... 664
Thrombosis of the cavernous sinus, Dr. Jackson, ... 365
Treatment of the apparently unaffected eye in cases of monolateral Glaucoma, Dr. G. E. de Schweinitz, ... 291
Tuberculosis of iris (primary), Dr. N. J. Hepburn, ... 338
Tumor of orbit, three cases of vascular, Dr. C. S. Bull, . . . 27
Two new instruments, Dr. S. Theobald, ... 398
Uniform notation of meridians of eyes and visual fields, Dr. H. Knapp, ... 632
Vascular growths into the vitreous, Dr. W. B. Marple, . . . 254
Vision, color-sense, and hearing of railroad employees, Dr. C. H. Williams, ... 639
X-Ray diagnosis and operation in injuries from foreign bodies, Dr. W. M. Sweet, ... 352
X-Rays in treatment of epithelioma of eyelids, Dr. W. M. Sweet, 550

INDEX OF AUTHORS.

Dr. S. C. Ayres. Observations on some blind but quiet and apparently inoffensive eyes, etc., ... 137
Dr. C. S. Bull. Three cases of vascular tumor of orbit, . . . 27
Metastatic choroiditis occurring in pneumonia following grippe, ... 316
Post-operative history of fifty cases of Glaucoma, . . . 429
Subconjunctival injections of sublimate in orbital cellulitis, 664
Dr. F. Buller. Tumor of optic nerve with intra-cranial complications, ... 633
Dr. S. M. Burnett. Homonymous similar sector defects in visual fields, ... 118
Dr. F. E. Cheney. Unusual case of chronic inflammatory hypertrophy of the lid margin, ... 367
Dr. J. H. Claiborne. Anophthalmos congenitus, ... 370
Dr. A. E. Ewing. Frontal headaches apparently ocular but really nasal in origin, ... 60
Operation for atrophic entropion, especially of lower lid, . 15
Dr. H. Friedenwald. Treatment of dendritic keratitis and marginal ulcer of the cornea with tincture of iodine, . . . 129
Case of Sarcoma of eyelid, ... 133
Case of acute circumscribed exudative chorio-retinitis, . 577
Improvement of vision in amblyopia from non-use, . . 612

PAGE.

Dr. E. Gruening. Sclerò-corneal cyst, ... 343
Treatment of congenital ptosis by partial resection of the tarsal cartilage, ... 574
Sarcoma of the iris, ... 343
Dr. H. F. Hansell. Case of acute double retro-bulbar optic neuritis hereditary in origin, ... 114
Eye complications in anchylostomiasis, ... 377
Dr. G. C. Harlan. Distension of nasal accessory sinuses involving the orbit, ... 44
Congenital orbital cyst with microphthalmos, ... 474
Dr. N. J. Hepburn. Primary Tuberculosis of iris, ... 338
Hunterian chancre of caruncle, ... 383
Dr. W. A. Holden. Metastatic carcinoma of one optic nerve, . 477
Dr. L. Howe. Relative accommodation and convergence, with description of an instrument for their measurement, . . 92
On the confusions in methods of numbering and using Prisms, 654
Primary insertions of the ocular muscles, ... 668
Dr. A. A. Hubbell. Foreign body in eyeball removed after eighteen years—repeated attacks of sympathetic inflammation without loss of vision, ... 347
Dr. E. E. Jack. Alexia—mind blindness, case of, ... 122
Double metastatic carcinoma, ... 483
Cavernous-sinus thrombosis following grippe, ... 545
Dr. E. Jackson. Corneal section for cataract and the cataract knife, ... 145
Case of exfoliation of the anterior layer of the iris with partial opacity of the lens, ... 149
Double panophthalmitis and septicaemia from abscess of the knee, ... 335
Thrombosis of the cavernous sinus, ... 365
Dr. C. J. Kipp. Sarcoma of choroid followed by phthisis bulbi, 332
Case of unilateral hemianopsia in which the Wernicke pupillary reaction was present, ... 678
Dr. H. Knapp. Primary non-infective thrombosis of the cavernous sinus, ... 77
Adenoma of the meibomian glands, ... 328
A point in the dioptrics of astigmatic refraction, ... 620
The desirability of uniform notation of the meridians of the eyes and of the visual fields, ... 632
Dr. C. Koller. Corneal Loupe, ... 385
Cyst of Vitreous, ... 380
Dr. C. W. Kollock. Surgical treatment of a case of high myopia, 100
Dr. W. E. Lambert. Congenital coloboma of eyelid, ... 402
Papilloma of orbital conjunctiva and cornea, ... 404
Hypertrophy of the lachrymal gland, ... 403
Dr. J. A. Lippincott. On the advantages of strong, portable magnets, ... 152
Spasm of the accommodation in Glaucoma relieved by eserine, ... 178
Dr. W. B. Marple. Vascular growths into the Vitreous, . . . 254
Dr. B. L. Millikin. Additional notes on a case of high Astigmatism, ... 657
Ossification occurring in the eye, ... 589
Dr. W. F. Mittendorf. Case of dislocation of the lachrymal gland, 382
Dr. C. A. Oliver. Retro-bulbar lympho-sarcoma, removal with preservation of normal vision, ... 36
Ocular symptoms in a case of posterior spinal sclerosis, . 173
A study of the crystalline lenses of a hanged criminal, . . . 490
Ocular changes from the injection of bacillus typhosus into the vitreous, ... 494

PAGE.

Dr. T. R. Pooley. Two unusual complications of cataract extraction, ... 518
Report of Committee on Standards and Methods of examination for acuteness of vision, color-sense, and hearing, . . . 406
Report of Committee on Supplementary histories of cases reported to this society, ... 215
Dr. H. W. Ring. A methyl-alcohol debauch and its results, . 529
Dr. S. D. Risley. Displacements of the eyeball by disease of the frontal and ethmoid sinuses, ... 72
Extraction of metallic fragments from the Vitreous—located by X-rays, ... 562
Dr. W. K. Rogers. Two cases of retinal detachment treated by drainage incision, ... 525
Dr. S. B. St. John. Removal of large foreign body from anterior chamber with preservation of normal vision, photograph of the foreign body in situ, ... 345
Melano-sarcoma of choroid and orbit, ... 469
Dr. R. Sattler. Lesions of frontal sinus and anterior ethmoidal cells in infancy and old age, ... 50
Dr. G. E. de Schweinitz. Histology of lachrymal gland in chronic dacryo-cystitis, ... 182
Papilloma of the plica semi-lunaris, ... 187
Dropsical degeneration of rod and cone cells of retina simulating Glioma, ... 283
Treatment of the (apparently) unaffected eye in monolateral Glaucoma, ... 291
Dr. F. D. Skeel. An improved Perimeter, ... 196
Dr. J. A. Spalding. Optic atrophy from blows on forehead and temple, ... 83
Dr. Wm. M. Sweet. Results of X-ray diagnosis and operation in injuries from foreign bodies, ... 352
Treatment of epithelioma of the eyelids by X-rays, . . . 550
Dr. S. Theobald. Case of transient spastic convergent strabismus, 167
Two new instruments, ... 398
The ideal result to be aimed at in the operative treatment of convergent strabismus in children, ... 556
Dr. A. G. Thomson. Opacity of posterior capsule of the lens due to remains of the membrana vasculosa lentis, ... 108
Color-blindness from tobacco amblyopia not detected by the wool tests but immediately shown by lamp test, . . . 540
Dr. Wm. Thomson. Lantern for detecting color-blindness in R. R. employees, ... 189
Drs. Wm. and A. G. Thomson. Circle of diffusion in correction of ametropia, ... 512
Lantern for detecting color-blindness, ... 391
Dr. C. A. Veasey. Excision of lachrymal sac and gland followed by neuro-paralytic keratitis, ... 101
Endothelioma of orbit, ... 464
Dr. O. F. Wadsworth, Sarcoma of limbus associated with an implanted secondary growth in the lower lid, ... 274
Dr. J. E. Weeks. Cases of simple Glaucoma treated by resection of the superior ganglion of the cervical sympathetic, . 441
Operative treatment of entropion by transplantation of a flap of mucous membrane, ... 18
Dr. W. H. Wilder. Two unusual cases of choroidal disease, . 111
Dr. C. H. Williams. Lantern for detecting color-perception, . 192
Instrument for testing the position of the axes of the eyes, . 388
Incandescent electric lamp for ophthalmoscopic examination, 387
Vision, color-sense, and hearing of R. R. employees, . . 639
Dr. F. M. Wilson. Conjunctival flap and cataract wound, . . 503
Dr. H. Woods. Permanent hemianopsia, sequel of puerperal eclampsia, ... 659

AMERICAN OPHTHALMOLOGICAL SOCIETY.

REPORT OF THE COMMITTEE ON STANDARDS AND METHODS OF EXAMINING THE ACUTENESS OF VISION, COLOR-SENSE AND HEARING.

At a meeting of the American Ophthalmological Society held July 19, 1899, it was voted, that the President appoint a committee of three to consider the question of standards and the best methods of making examinations for acuteness of vision, color-sense and hearing, and that they be requested to report at the annual meeting two years hence. This vote was passed after the discussion of a paper which concerned the testing of railway employes, and your committee have directed their attention principally to the standards and methods of examination necessary for those whose work requires them to recognize form or color signals on land or sea.

Defects in acuteness of vision are far more frequent than defects in color perception, and with advancing years there are many causes which may impair the sharpness of sight; on the other hand there are very few causes which bring on an acquired defect in color perception, and if a careful examination is made of men entering the service, to eliminate the cases of congenital defect, very little trouble will be met in the re-examination of men on account of defective color-sense.

Before discussing these matters in detail, or making any recommendations, it will be profitable to see what other committees have recommended who have carefully considered the same questions, and what regulations have already been put in effect on some of the railways where these matters have been given most thoughtful attention.

INTERNATIONAL MEDICAL CONGRESS OF 1881.

At the International Medical Congress, held in London in 1881, a committee of the Ophthalmological section, of which Professor Donders was chairman, presented the following resolutions:

A.—WITH RESPECT TO LAND.

1. That the recommendations of the last International Medical Congress, held at Amsterdam in 1879, are accepted by the present Congress as forming the most suitable basis upon which every government may frame its own regulations as to its railway service. They are contained chiefly in article 12 of the "Projet d'un reglement pour l'examen des facultes

visuelles du personnel des chemins de fer," laid before and accepted by the Ophthalmological section of the Amsterdam Congress, which is nearly as follows:

"For admission as *driver* or *stoker* is required—a healthy condition as regards habitual congestion of irritation of the eyes and eyelids; *for each eye*, complete field of vision; normal acuity and refraction; color-sense at least four-fifths of the normal; total absence of commencing cataract or any other progressive disease.

"For admission to other *railway service* is required—a healthy condition as regards habitual congestion or irritation of the eyes or eyelids; *for eqch eye*, complete field of vision, total absence of cataract, or any other progressive disease; *for one of the eyes*, normal acuity and refraction, color-sense at least three-fifths of the normal; *for the other eye*, sight of at least half the normal, as regards both acuity and color-sense."

B.—WITH RESPECT TO SEA.

2. That in *ocean going ships* and in *all steamers*, especially those carrying passengers, there should be in actual control of the helm a person possessing *with the two eyes together, without glasses*, normal sight, both as to acuity and colors; and that, *in addition*, in such ships, *at least one* of the persons actually on the lookout should be similarly qualified.

3. That in vessels engaged in the coasting trade, every person liable to take charge of the helm should possess *with the two eyes together, without glasses*, sight equal to at least two-thirds of the normal, both as to acuity and colors.

4. That all persons engaged in marine signalling, ashore or afloat, and all pilots should have normal sight, both as to acuity and colors as defined in article 2.

5. That hypermetropic persons, although satisfying the requirements of articles 2, 3 and 4, should, nevertheless, not be admitted, if, before the age of eighteen, they have a manifest hypermetropia of one diopter.

6. That re-examinations should be made at the age of 45.

7. That the examinations should be conducted by persons of recognized competency, under the direction of a central medical authority in each country.

8. That an International Commission should be constituted, to fix upon such further measures as to signals as may be necessary for safe navigation, and especially, upon the standard colors, and the sizes of the signals employed.

RECOMMENDATIONS OF THE ROYAL SOCIETY.

In 1890 the British Board of Trade made some inquiries of the Royal Society as to the best tests for color-blindness. This resulted in the appointment of a committee by the Royal Society, who, after two years of work, made the following report:

"After weighing the evidence which they have obtained, the committee have unanimously agreed upon the following recommendations:

"1. That the Board of Trade, or some other central authority, should schedule certain employments in the mercantile marine and on railways, the filling of which by persons whose vision is defective either for color or form, or who are ignorant of the names of colors, would involve danger to life and property.

"2. That the proper testing, both for color and form, of all candidates for such employments should be compulsory.

"3. That the testing should be entrusted to examiners certificated by the central authority.

"4. That the test for color-vision should be that of Holmgren, the sets of wools being approved by the central authority before use, especially as to the correctness of the three test colors, and also of the confusion colors. If the test be satisfactorily passed, it should be followed by the candidate being required to name without hesitation colors which are employed as signals or lights, and also white light.

"5. That the tests for form should be those of Snellen, and that they should be carried out as laid down in appendix six. It would probably in most cases suffice if half normal vision in each eye were required.

"6. That a candidate rejected for any of the specified employments should have a right of appeal to an expert approved by the central authority, whose decision should be final.

"7. That a candidate who is rejected for naming colors wrongly, but who has been proved to possess normal color-vision, should be allowed to be re-examined after a proper interval of time.

"8. That a certificate of the candidate's color-vision and form-vision according to the appointed tests, and his capacity for naming the signal colors, should be given by the examiner; and that a schedule of persons examined, showing the results, together with the nature of the employments for which examinations were held, should be sent annually to the central authority.

"9. That every third year, or oftener, persons filling the scheduled employments should be examined for form-vision.

"10. That the tests in use, and the mode of conducting examinations at the different stations, should be inspected periodically by a scientific expert, appointed for that purpose by the central authority.

"11. That the colors used for lights on board ship, and for lamp signals on railways, should, so far as possible, be uniform, and that glasses of the same color as the green and red-sealed pattern glasses of the Royal Navy, should be generally adopted.

"12. That in case of judicial inquiries as to collisions or accidents witnesses giving evidence as to the nature or position of colored signals or lights should be themselves tested for color and form-vision.

"April 28, 1892."

The regulations governing the standards and methods of examination of railway employes in Holland have been in effect for about ten years and are by far the most complete at present in use. The Dutch railways belong to the State, but are operated by a company, and the authority of such distinguished men as Professors Donders and Snellen, who have taken a most active personal interest in the matter, has been sufficient to give these instructions a more scientific basis than has been obtainable elsewhere. On the other hand, it must be remembered that in a compact and small country like Holland, with an abundance of trained ophthalmic surgeons at all points where examinations are to be made, the conditions are very different from those which must be met in the United States of America, where a single system of railroads will sometimes extend over more than 5,000 miles of track, running through a territory not well supplied with ophthalmic surgeons.

(*Translation.*)

Regulations for testing the Eyesight of persons employed by the Company working the Dutch State Railways, along with Instructions to the Ophthalmic Surgeons, to whom the Examination is entrusted.

A.—TESTING OF CANDIDATES.

Article 1.

Every one appointed to the posts hereinafter named must be provided with a certificate showing that his eyesight is as good as the service requires.

The certificate must be signed by one of the ophthalmic surgeons (appointed by the Consulting Ophthalmic Surgeon in conjunction with the Director-General of the Company), but not until he has tested the candidate in the manner prescribed.

Article 2.

The certificate referred to in the foregoing article must not be given until the examination has shown that the candidate possesses eyesight fulfilling the following conditions:

a. For the post of engine driver or fireman.

Externally healthy eyes and eyelids, free from chronic congestion or inflammation; with both eyes open; *an unrestricted field of vision, normal acuteness of vision, normal refraction and power of distinguishing colors of at least four-fifths;* in looking with each eye separately, the other being covered: unlimited field of vision, acuteness of vision (without glasses), as well as color-sense of *not less than one-half;* both eyes free from cataract and other progressive affections.

b. For the post of stationmaster and his substitutes, petty stationmaster, head conductor, conductor, breaksman, pointsman, foreman, bridge watcher, signalman, assistant bridge watcher, surface-man and surface-woman, assistant watchman, line surveyor, chief snow ploughman, inspector of the locomotive and train service, and inspecting engineer.

Externally healthy eyes and eyelids; in looking with both eyes simultaneously: unrestricted field of vision, normal visual acuteness (without glasses), and free from hypermetropia of more than one dioptre, power of distinguishing colors of at least three-fifths; in looking with each eye separately, the other being closed: visual acuteness (without glasses) and color-sense not less than one-fourth; both eyes free from progressive ailments.

If the person examined should appear to be unfit for class *a*, it must be specified on the certificate whether the candidate is fit for class *b*.

ARTICLE 3.

In looking with both eyes simultaneously, and each eye separately, the examination must be directed to

a. The refraction.
b. The acuteness of vision.
c. The power of distinguishing colors.
d. The field of vision.

Attention must also be paid to the state of the eyes and eyelids, as well as to the possible occurrence of cataract and other progressive diseases.

ARTICLE 4.

Every person must be examined separately and exclusively by the appointed ophthalmic surgeon.

ARTICLE 5.

The person examined shall receive a certificate (Form A, No. 728) containing a statement of the condition and of the consequent conclusion, and shall append his own signature in the presence of the ophthalmic surgeon.

The ophthalmic surgeon shall keep a copy of this declaration on schedules provided by the Company (Form No.), and shall place this in the hands of the Consulting Ophthalmic Surgeon annually.

ARTICLE 6.

The results of the examination of both eyes simultaneously (E. E.), of the left eye (L. E.), and of the right eye (R. E.), are to be specified on different lines in the certificate of examination (Form No. 728, Column 1).

ARTICLE 7.

The eyelids are to be examined on the internal as well as

the external surfaces, and in the examination of the eyes attention must also be paid to the movements and co-ordination of both eyes (Column 2).

ARTICLE 8.

As regards the extent of the field of vision, it is to be determined by hand movement, eye fixing eye (Column 3).

ARTICLE 9.

The visual acuteness is estimated by Snellen's optotypes, or with letters which correspond therewith in size and clearness, at a distance of six metres, first without glasses (Column 4), then with glasses (Column 6), by which means the refraction also is ascertained (Column 5). The test types are to be suspended in a good clear light; the person to be examined standing with his back to the light.

ARTICLE 10.

The color-sense is to be estimated—

a. Qualitatively, by pseudo isochromatic tables of Stilling, and with wools, according to Holmgren's method.

b. Quantitatively, by Donders's method, which must be applied in every instance without exception (see the 14th No. of the Scientific Appendix to the 18th *Annual Report* of the Netherlands Hospital for Diseases of the Eye, 1877, page 77).

ARTICLE 11.

In the column "Remarks," morbid changes in the position and movements of the eyes, and also, in case of diminution of visual acuteness, the result of ophthalmoscopic examination must be noted.

ARTICLE 12.

The conclusion will read thus: "satisfactory" or "unsatisfactory." In the latter case the ophthalmic surgeon must add a statement as to how far the rejected candidate is or is not fit for office work.

B.—RE-EXAMINATION.

ARTICLE 13.

Those persons occupying situations in the Company mentioned in Article 2, A, are to be re-examined—

a. Within a year after their 45th birthday, and again every five years thereafter.

b. After every acute affection of the eyes or lids.

c. After serious accident, especially those which could cause concussion of the brain, and after diseases of the brain in general.

d. After the diagnosis of diabetes mellitus, or albuminuria, as well as secondary syphilis.

e. In general on the recommendation of the railway surgeon or the medical man who has been treating the person.

f. After each neglect or act which may be attributed to defective sight, especially such as are connected with accidents (collisions or derailments).

ARTICLE 14.

The re-examination shall take place in the Ophthalmic Hospital at Utrecht by or in name of the Consulting Ophthalmic Surgeon.

ARTICLE 15.

The results of the re-examination must be entered in the certificate of re-examination (Form No. 729), the conclusion reading thus:

Visual power satisfactory; satisfactory, but under obligation of wearing such glasses as will be prescribed for the service; relatively satisfactory; unsatisfactory; temporarily unsatisfactory (with the treatment, and thereupon re-examination after a fixed period).

ARTICLE 16.

On the certificate of re-examination mentioned in Article 15, the visual power of the examined is declared to be

A.—Satisfactory

when it fulfils the following conditions:

a. For the post of engine driver or stoker.

Externally healthy eyes and eyelids, free from chronic congestion or inflammation; in both eyes unrestricted field of vision; on looking with both eyes open, *visual acuteness of at least three-fourths* (*without glasses*), and color-sense of at least three-fourths; with each eye separately, the other eye being covered, visual acuteness of at least *one-third* (without glasses), and color-sense also of at least one-third. Both eyes must be free from cataract and other progressive diseases.

b. For the post of stationmaster and those who substitute him, petty stationmaster, head conductor, guard, breaksman, pointsman, foreman, bridge watcher, signalman, block signaller, under bridge watchman, level crossing keeper and his wife, inspector for the locomotive and train department, and inspecting engineer.

Externally healthy eyes and eyelids, free from chronic congestion or inflammation; with both eyes open, unrestricted field of vision, and visual acuteness of *at least two-thirds*, color-sense of at least two-thirds; with each eye separately (the other being covered), visual acuteness and color-sense of at least *one-fourth*. Both eyes must be free from cataract and other progressive diseases.

If the visual acuteness and color-sense herein stated is only obtained by means of glasses, spectacles must be compulsorily worn.

B.—Relatively Satisfactory.

When with both eyes open the visual acuteness and color-sense with or without glasses appear to be less than two-thirds, but more than one-third.

Those who belong to this category may be exclusively employed for positions in which the recognition of signals at short distances is sufficient. The office of engine driver or stoker may not be awarded to them under any conditions.

C.—Unsatisfactory.

When it is ascertained that the visual acuteness and color-sense, even with spectacles, do not exceed one-third. Those in this category may not be nominated under any circumstances whatsoever for any of the above-mentioned situations.

In the declaration of unfitness for any of the situations mentioned under *A* it shall be stated whether the person is or is not fit for any of the offices mentioned under *B*.

In the declaration of unfitness for any of the situations mentioned under *B* it shall be stated whether the person, in the judgment of the Consulting Ophthalmic Surgeon, is fit to be a clerk or messenger.

ARTICLE 17.

The person examined shall receive a certificate of having undergone re-examination (Form No. 729), and shall affix thereunto his signature in the presence of the Consulting Ophthalmic Surgeon or his substitutes.

GENERAL INSTRUCTIONS.

ARTICLE 18.

A record must be kept in the register of the Company's employes of the result obtained at each examination and re-examination, mentioning when and by whom the examination or re-examination was conducted.

The above report may be at any time subjected to the revision of the Consulting Ophthalmic Surgeon. He has also the right to examine without being requested to do so.

In both instances his judgment is final.

ARTICLE 19.

At each examination the Consulting Ophthalmic Surgeon may appoint a time for re-examination.

If ophthalmic treatment is required, with or without cessation of work, he shall give notice thereof to the Company (Central Office).

ARTICLE 20.

Every one who has undergone an examination by the Ophthalmic Surgeon, named in Article 1, is entitled, within six weeks of the first examination to appeal for re-examination to the Consulting Ophthalmic Surgeon, at which time the production of the first certificate is obligatory. This application is to be made officially, and through the Central Office.

ARTICLE 21.

The person examined shall receive a certificate of having undergone the re-examination in each instance (Form No. 728), and shall affix his signature thereto in the presence of the Consulting Ophthalmic Surgeon.

ARTICLE 22.

If it should appear in the re-examination that the person who is re-examined did not fulfil all the requirements of these regulations at the time of his entering the service, and that since then his sight has not decreased, the Consulting Ophthalmic Surgeon will be justified in limiting the application of these regulations according to his judgment.

In such a case a full statement must be made in the certificate given.

THE DIRECTOR-GENERAL,

J. L. CLUIJSENAER.

UTRECHT, January 1, 1892.

FORM No. 728.

Referred to in the Instructions under A of the Service Order New Series, No. , and in Article 5 of the Regulations for Examination of Eyesight.

THE STATE RAILWAYS COMPANY.

Certificate as to the eyesight of.....aged.....
applying for the post of .....

*a. Engine driver or stoker.

b. The other situations mentioned in the Regulations for the Testing of Eyesight.

* When applying for any of the situations mentioned under *B*, *A* must be crossed through, and *vice versa*.

When the person applying for any of the situations mentioned under *A* appears to be unfit for them, the ophthalmic surgeon shall mention whether the candidate appears to be fit for those mentioned under *B*.

Eye.	External Appearances.	Field of Vision.	Visual Acuteness.	Refraction.	Visual Acuteness with Glasses.	Color Sense.	Remarks.	Conclusion.
1	2	3	4	5	6	7	8	9

Signature of the candidate to be affixed in the presence of the Examining Ophthalmic Surgeon.

The 189

Received, f. 1,—

The Examining Ophthalmic Surgeon.

FORM No. 729.

Referred to in the Service Order, New Series, No. , and in Article 15 of the Regulations for Eyesight Testing.

THE STATE RAILWAYS COMPANY.

Re-examination of the eyesight.

Name and Surname.	Age.	Reasons for Re-examination other than that of Age.	Acting as	Result.	Age at which next Re-examination must take place.	Remarks.
1	2	3	4	5	6	7

* In the declaration of unfitness for the situation of engine-driver or stoker, it shall be stated whether the individual is or is not thought fit for the other situations mentioned in the Regulations for Examination for Eyesight.

In the declaration of unfitness for the last named situations it shall be stated whether, in the opinion of the Consulting Ophthalmic Surgeon, the person concerned is fit for the work of a clerk or messenger.

Signature of the Examined. *Utrecht, the* 189

Received, f. 1,—

The Assistant to the Consulting Ophthalmic Surgeon.

The Consulting Ophthalmic Surgeon.

In 1881 the Directors of the Pennsylvania Railroad Company approved and adopted the following instructions for the examination of their employes:

PENNSYLVANIA RAILROAD COMPANY'S INSTRUCTIONS FOR EXAMINATION OF EMPLOYES AS TO VISION, COLOR-BLINDNESS AND HEARING.

Instructions for examination as to vision, color-blindness and hearing.—The examination will be made as to vision, color-sense and hearing, and the following apparatus will be used:

1. A card or disc of large letters for testing distant sight. 2. A book or card of print for testing sight at a short distance. 3. An adjustable frame for supporting the print to be read, with a graduated rod attached for measuring the distance from the eye while reading. 4. A spectacle frame for obstructing the vision of either eye while testing the other. 5. An assortment of colored yarns for testing the sense of color. 6. A watch with a loud tick for testing the hearing. 7. A book or set of blanks for recording the observations. 8. A copy of an approved work on "Color-blindness."

Acuteness of vision.—For distant vision, place the test-disc or card in a good light twenty feet distant, and ascertain for each eye separately the smallest letters that can be read distinctly, and record the same by the number of that series on the card.

Range of vision.—For near vision, ascertain the least number of inches at which type D=0.5 or 1½ can be read with each eye, and record the result.

Field of vision.—Let the examiner stand in front of the examined, at a distance of three feet, and directing the examined to fix his eyes on the right eye of the examiner, and keep them so fixed, let the examiner extend his arm laterally, and opening and shutting his hands, let him by questions satisfy himself that his hands are seen by the examined without changing the direction of the eyes; recording the result as good or defective, as the case may be.

Color-sense.—Three test-skeins—A, light-green; B, rose; C, red—will be used with the colored yarns attached to the stick; of the latter there are forty tints, numbered from 1 to 40, and arranged in three sets—*a*, *b* and *c*—of which the odd numbers correspond to the colors of the test-skeins, whilst the even numbers are different or "confusion colors."

The first set is to test for color-blindness; the second to determine whether it be red or green blindness, and the third to confirm the opinion formed from the first or second test.

Place the test-skein A at a distance of not less than three feet, and, without naming the color, direct the person examined to name the color, and to select from the first twenty tints, or set *(a)*, of the yarns on the stick, ten tints of the same

color as skein A, stating that they do not match, but are different shades of the same color. Record the number of tints so selected. Do the same with skeins B and C, using for B the tints from 21 to 30, and for C the tints from 31 to 40. If the odd numbers are selected readily, the examination may be gone over very quickly.

When color-blindness is detected, any one of the even numbers or "confusion colors" may be used as a test-skein, and the man may be directed to select similar tints, when he will most probably choose odd numbers, which should be recorded, stating the number on the stick of the "confusion color" used for a test, and then giving the numbers chosen to match it.

Then a soiled *white* flag should be shown, and the man be directed to select tints to match it, which should be recorded; next a *green*, and finally a *red* flag.

All of the particulars are to be recorded as the examination proceeds, not leaving it to memory. Use the numbers in recording. The letters indicating the set need not be used. Note whether the selection is prompt or hesitating by a distinct mark after the proper word on the blank form. When deficient color-sense is discovered, and variations in the mode of testing are made by the examiner or examined, they should be noted under remarks, or on a separate sheet to be referred to, if the blank has not room enough.

Hearing.—Note the number of feet or inches distant from each ear at which a watch, having a tick loud enough to be heard at five feet, is heard distinctly, using a watch without a tick, or a stop watch, to detect any supposed deception; and the number of feet at which ordinary conversation is heard.

Explanations.—The test-card contains letters, numbered from 20 (xx), or D=.6, to 200 (cc), or D=60. Those measuring three-eighths of an inch, and numbered 20 (xx) or D=6, are such as a good eye of ordinary power sees distinctly twenty feet or six metres distant. If a man sees distinctly only those marked C (or 100), his acuteness of vision, V., is equal to 20-100 or 1-5. If he sees to XX (or 20), then V. is equal to 20-20 or 1.

This mode of statement indicates the relative value of the sight examined, and should be used in the records. If one eye is 20-20 or 1, and the other not less than 20-50 or 1-2½, with or without glasses, the sight may be considered satisfactory.

The power of discerning small objects at the reading distance is tested by the small print, and good sight may be assumed if one eye can see at twenty inches the matter marked 1½ or D=0.5, whilst the other distinguishes not less than 4½ or D=1.5. The small print should then be brought to the point of nearest vision for each eye, and that point mentioned in inches. A good eye should be able to read No. 1½ at twenty inches, and have a *range of vision* up to ten inches.

The color-test will indicate whether the man is deficient in color-sense. The colors are arranged in three sets, one of 20 and two of 10 each—the odd numbers are the colors similar to

the test-skeins, and the even numbers are the "confusion colors," or those which the color-blind will be likely to select to match the sample skeins or colors shown him. The first 20 *(a)*, numbered from 1 to 20, have green tints for the odd numbers or test-colors. In the second *(b)*, 21 to 30, the test colors are rose or purple, a combination of red and blue; and in the third *(c)*, 31 to 40, they are red. Ordinarily the test will be with each set separately, but the whole 40 may be employed on any test-skein. Anything but *green* matched with *green* indicates a defect in the color sense, for which use set *(a)*.

The test with the second set indicates whether red or green blindness exists. The odd numbers from 21 to 30 are purple. If either of these is matched with test-skein B, nothing is indicated, as they must appear alike to a color-blind person; but if blue is chosen, red-blindness is indicated, and if green, then green-blindness is established.

The third set *(c)* is scarcely needed, but may be used in confirmation of, or in connection with, the last, as to red or green defect.

When the numbers of the tints selected are recorded in the proper blank, color-blindness will be indicated in those instances where even numbers appear, and suspicions will arise where numbers beyond 20 are used with test-skein A, and under 21 or beyond 30 with B, and below 31 with C.

Further tests should be made of those found to be color-blind with the usual signal flags, requesting them to name each color, shown singly, and to match the colors of them from the tints on the stick, and with colored lamps; and finally to state what they understand them to mean as signals.

It will be well not to dwell on the examination of a man found to be defective in color-sense or in vision, but to pass over each examination with the same general care, and afterwards send for those giving indications of defects, to come in singly for fuller examination. The examination should be private as far as practicable, especially excluding persons who are to be subsequently examined.

Inability to name color accurately, or to distinguish nicely as to difference in tint, is not to be taken as an evidence of color-blindness.

In testing as to hearing, if the watch used can be heard at five feet distant, and the person examined hears it only at one foot, his hearing would be 1-5, and may be so recorded in fractions. Conversation in an ordinary tone should be heard at ten feet.

It should be understood that all employes examined, failing to come up to the requirements of the above standard, shall be accorded the benefit of a professional examination. When acuteness of vision is below the standard adopted, it may be possible to restore full vision by proper glasses, when it is due to optical defects, known as near-sight, far-sight, or astigmatism, or by other medical or surgical treatment, and useful men may then be retained in the company's service.

WEST JERSEY RAILROAD CO.

.....18

EXAMINATION OF SIGHT AND HEARING OF

.....Aged,.....

Employed as.....

Applicant for.....

ACUTENESS OF VISION. The number of the series seen at 20 feet distant.		RANGE OF VISION. Least number of inches at Right Eye, Left Eye, which type D—0,5. in test tpye pamphlet can be read. ....inches. ....inches.
Right Eye,	.....	FIELD OF VISION.
Lefl Eye,	.....	Good or Defective,.....

COLOR SENSE.

Test Skein Submitted.	Name Given.	Numbers Selected to Match.
A—Green,	.....	.....
B—Rose,	.....	.....
C—Red,	.....	.....

SECOND COLOR TEST.			THIRD COLOR TEST.		
No. Shown.	Name Given.	Nos. Selected.	Flag Shown.	Name and Use Given.	Nos. Selected.
.....	.....	.....	.....	.....	.....
.....	.....	.....	.....	.....	.....
.....	.....	.....	.....	.....	.....

Selection Prompt or Hesitating.

.....

HEARING.

RIGHT EAR.		LEFT EAR.	
Watch.	Conversation.	Watch.	Conversation.
.....Feet.	.....Feet.	.....Feet.	.....Feet.

REMARKS:

.....

.....

.....

.....Examiner.

Acuteness,..... Range,..... Field,.....

Color Sense,..... Hearing,.....

.....

.....

....Superintendent.

NOTE.—Those approved mark appd.
Those not approved mark not appd.

In April, 1899, the New York, New Haven and Hartford Railroad Company improved their old methods and put in effect on their Eastern District a carefully prepared set of instructions, which after more than a year's use were amended and extended over their whole system. These instructions have been again revised and under date of July 1, 1901, are as follows:

The New York, New Haven and Hartford Railroad Company.
Instructions for Examination of Vision, Color-Sense and Hearing.

Each Examiner appointed by the Division Superintendent, subject to the approval of the General Superintendent, will first be himself examined as to his vision, color-sense and hearing, and if this test is satisfactory will be instructed in the use of the following material, which will be furnished division headquarters.

1. A set of standard test-letters on cards, including cards on which semaphore signals are printed; for testing the acuteness of vision.

2. A set of cards with reading matter in print of various standard sizes, and some train orders written on the manifold copying sheets; for the reading test.

3. A set of approved Holmgren worsteds (125 colors, each with numbered tags), and a standard testing lantern, with 13 glasses of different colors, and smoke glasses, showing either one or two colors at a time; for testing the color sense.

4. A ratchet acoumeter; for the hearing test.

5. Two pairs of spectacles, one with plane glasses, the other with a convex lens of two diopters, for each eye.

6. Blank forms and certificates, for noting the result of the examinations.

The tests should be made in a well lighted room in which a distance of 20 feet can be measured from the test type to the person to be examined. Dark shades or shutters should be provided so that the room can be darkened for the lantern test. The colored worsteds must be protected from light and dust when not in use.

In case of persons desiring to enter the service, insert "App." before the proposed occupation.

If the person examined meets the required standard, each Examiner, after filling in form T 523, will note under the head of "Remarks," in each case, "Satisfactory."

If the person examined does not meet the requirements, or, if glasses are necessary to bring the acuteness of vision up to standard, the Examiner will note the facts under the head of "Remarks," in each case. After the form T 523 has been properly filled in, the Examiner will attach his signature and forward the form to the Division Superintendent, who will take a copy of the same and forward the original form to the General Superintendent.

The Examiner will give a certificate, form 1523, to each person who passes a satisfactory examination. This certificate will be dated and signed by the Examiner, and will also be signed in his presence by the person examined.

If in examining men in the service whose vision is to be tested without glasses it is found that glasses are needed to bring the vision up to the required standard, a full report of the examination, both with and without glasses, will be forwarded to the General Superintendent through the Division Superintendent, and the Examiner will not issue a certificate in such cases until he receives the approval of the General Superintendent.

The examinations should not be hurried. Some men are nervous when undergoing these tests, and need to be given plenty of time, and to be shown that no unfair advantage is to be taken of them. Do not allow frequent interruptions nor the presence of those not concerned in the test.

Each person should be examined separately, so that *no* assistance can be given by sign or sound to those who are defective.

All cases of doubt should be referred to a Board consisting of the General Superintendents and an expert oculist to be selected by the General Manager.

ACUTENESS OF VISION.

Place the person to be examined so that he will not face a strong light, have him completely cover one eye by holding a card over it, pressing it firmly against the nose, taking care not to press on the covered eye; hang one of the 20-foot cards at a distance of twenty feet from him in a good clear light, but not in direct sunlight, and ask him to read the letters on the card. If he can read them correctly, or with a mistake of not more than one letter, hold up another of the 20-foot cards, and, if this is also read correctly, note on the form the distance at which the test letters are read, and underneath it the number over the smallest line of test-type read correctly; in this case $\frac{20}{20}$, or normal vision. If he cannot read the letters on the 20-foot card at twenty feet, hold up a 30-foot card, then a 40-foot card, etc., until letters are found that he can read; if he cannot read the 50-foot letters at 20 feet let him approach the card until he can see them, or the fact is shown that he cannot see them at any distance. If the letters on the 40-foot line are the smallest that can be seen with this eye at 20 feet, its vision will be noted as $\frac{20}{40}$ of normal, the numerator of the fraction being the distance at which the letters are read correctly, and the denominator being the number of feet printed above the smallest line that can be read,—that is, the distance at which they ought to be read correctly by a normal eye.

Repeat this test with the second eye, the first being covered in its turn. If the vision is less than normal, repeat the test

with both eyes uncovered and open, but if the vision is normal in each eye omit the test with both eyes open.

These tests are to be made without glasses, except as otherwise specified. In case glasses are worn, test first without the glasses and then repeat the test with the glasses, noting on the form T523, under the head of "Remarks," the vision with the glasses.

POSITION SIGNAL TEST.

Place one of the cards with the semaphore signals at a distance of 20 feet as in the first vision test, and with each eye separately have the person being examined read the signals, as stop or proceed, beginning at one end of the card with one eye, and at the other end of the card with the other eye. Repeat the test with another of the semaphore cards, with both eyes open, and note the distance in feet at which the signals can be read correctly, without glasses. The position signal test need not be used for those desiring to enter the service, nor unless the vision is less than $\frac{20}{40}$.

READING TEST.

Note the smallest size of print read correctly at the ordinary distance of about 18 inches, either with or without glasses, also whether manifold train orders can be read correctly at that distance.

TEST GLASSES.

In the case of men making application to enter the engine service, either as a new employe, or by transfer from some other department, the following additional test will be made. Place one pair of the test glasses in spectacle frames before the eyes of the applicant, and have him read another of the 20-foot cards, at 20 feet, then try the other pair of glasses and have him read the line again in the opposite direction. If he can read the letters through the plane glasses, but cannot read them through the convex, or magnifying, glasses, note on the form, under the head of "Remarks," "Test with test glasses satisfactory;" but if the letters can be read through both pairs of glasses, note "Test with test glasses not satisfactory." Engineers and firemen in the service will be tested with the test glasses and if they have $\frac{20}{20}$ or $\frac{20}{30}$ vision with *both* pairs of glasses they will be re-examined yearly for vision.

COLOR SENSE.

1. Holmgren Test. Place the whole number of colored worsteds on a table in good clear daylight, put the light green test skein A at a little distance from the other colors and ask the person being examined to select from the heap of colors all that look to him like the test skein, and place them beside it. Have him understand that he is not expected to find an exact

match for the test skein, but that he is to choose all the colors that appear to him of the same general color as the test skein, both those that are lighter and those that are darker in shade. If he does not easily understand what is wanted, let the examiner himself select the colors, then having returned them to the general heap and mixed them thoroughly with the rest of the colors, let him call on the person being examined to repeat the selection. This demonstration will not enable a person who is defective in his color perception to select the colors correctly, and he will pick out as looking to him like the green test skein A, some greens, and also some of the gray or brown confusion colors, which will appear to him of the same general color as the test skein, only varying from it in shade. Note on the form, the numbers on the tags of the colors selected as similar to the test skein A, and also note whether the selection is prompt or hesitating. Return all the colors to the heap and mix them together, then place the rose test skein B apart from the rest and have the person being examined select as before all the colors that look to him like this skein, and note the numbers on the colors so chosen.

No names should be mentioned in connection with any color in the above worsted tests; the tests should be based only on a comparison of colors.

2. Lantern Test. The room being darkened, light the test lantern and place it 20 feet from the person being examined about on a level with his head. Set the upper disc so that empty spaces come in front of the lights, the letters A and C being illuminated on the upper part of the disc. Push the brass buttons on the front of the lantern so that the ground glasses on the inside of the lantern are brought in front of the lights. Set the handle of the diaphragm at the lowest notch so that the colors are seen through the full-sized openings of the discs. Then turn the lower disc, carrying the colored glasses, which will show two colors at a time, and have the person being examined call the names of the colors as shown; for instance, "left, green; right, red," etc. Note on form T523 the name given to each color as shown, corresponding to the number on the lower disc under the color.

Repeat the test, placing the handle of the diaphragm in the highest notch so as to have the color seen through the smallest opening, and turn the upper disc so that only the letter C is illuminated; in this way only one color will be seen at a time. Turn the lower disc and note as before the names given to the colors as shown. In case there is any question as to the color-perception of the person being examined, further tests may be made by combining the smoke glasses of the upper disc with the colored glasses of the lower disc and using either the largest or the medium-sized openings of the diaphragm; but the smallest openings of the diaphragm should not be used with the smoke glasses of the upper disc. Also, the ground glasses inside the lantern may be pushed aside to vary the test.

If a person being examined calls a red light green, a green light red, or a red light white, under any of the varying conditions of the lantern test; or, if he selects as looking like the green test skein any of the grays, browns or reds, *and* as looking like the rose test skein any of the grays, blues, violets, or greens, the Examiner will note under the head of "Remarks," "Not satisfactory, account defective color-perception." If the person selects some of the grays or browns with the greens as looking like the green test skein, or if he selects some of the grays, blues or violets as looking like the rose test skein he will be considered as doubtful, and, if he is an old employe, he will be referred to the Board, mentioned on page 1, for further examination; but if he is an applicant for employment he will not be accepted. If the person examined makes none of the above mistakes his color-perception will be considered as sufficient.

HEARING TEST.

Place the person to be examined at a distance of 20 feet, with one side toward the Examiner; have him stop the ear furthest from the Examiner by placing the finger over it, then let him repeat aloud the words or numbers spoken by the Examiner in a conversational tone, and note the distance in feet at which they can be repeated correctly. Have him turn the other ear toward the Examiner, and repeat the test.

With one ear closed as before, note the greatest distance in feet at which the ticks of the ratchet acoumeter can be counted correctly, with each ear. Hold the acoumeter by its narrow edge between the forefinger and thumb, not shielded by the fingers, and with one flat face directed towards the person being examined.

No person can be considered to have sufficient acuteness of hearing who is unable to repeat, with his eyes closed, words or numbers spoken in an ordinary conversational tone of voice at a distance of ten feet.

Applicants for employment should be able to hear ordinary conversation the full distance of twenty feet, and the acoumeter at a distance of at least ten feet.

REMARKS.

Under the head of "Remarks" note any incidents which might impair the accuracy of the tests, as escaping steam, etc., or anything which gives any additional information in regard to the tests.

RE-EXAMINATIONS.

All employes who are required to pass an examination for vision, color-sense or hearing, will be re-examined as follows: 1. At the end of three years from the date of the last examination; or, yearly (for vision) in Class A if one eye is found to have less than $\frac{4}{8}$ of normal vision. 2. After any accident which might be caused by defective vision, color-sense or hearing. 3. After any serious accident, or after recovery from

any severe illness, or after severe inflammation of the eyes or eyelids. 4. Before promotion. 5. Yearly, for vision, in case on enginemen and firemen who have $\frac{20}{30}$ or $\frac{20}{40}$ vision with *both* pairs of test glasses.

STANDARDS OF ACUTENESS OF VISION.

The following standards of acuteness of vision will be considered as satisfactory for the different classes mentioned. These standards must be strictly observed, but if in the opinion of the Division Superintendent any exception should be made, the matter must be referred to the General Superintendent for final decision, with full report containing the reasons therefor.

CLASS A.

	ON ENTERING THE SERVICE, OR PROMOTION.	RE-EXAMINATION OF THOSE IN THE SERVICE.
Enginemen (road service) Firemen (road service)	20/20 in each eye, tested separately, without glasses.	Not less than 20/30 with both eyes open, without glasses; each eye should also be tested separately and the vision of each noted.

CLASS B.

Passenger Conductors " Baggage-masters " Brakemen Ticket Collectors Freight Conductors " Brakemen Yard Masters " Conductors " Brakemen " Enginemen " Firemen Switchmen Draw Tenders Engine Inspectors Car Inspectors	20/20 in one eye and not less than 20/40 in the other, tested separately, without glasses.	Not less than 20/40 with both eyes open, without glasses; each eye should also be tested separately and the vision of each noted.

CLASS C.

Towermen Telegraph Operators Station Agents Section Foremen	20/20 in one eye and not less than 20/40 in the other, tested separately, with or without glasses.	Not less than 20/40 with both eyes open, with or without glasses; each eye should also be tested separately and the vision of each noted.

CLASS D.

Crossing Flagmen	Not less than 20/40 with both eyes open, with or without glasses.	Not less than 20/50 with both eyes open, with or without glasses.

The above instructions will apply to all tests for vision, color-perception and hearing, made after July 1, 1901.

As soon as practicable all employes who are required to pass such tests, and who have not been examined since April 1st,

1899, by one of the Company's Examiners, must be examined in accordance with the above instructions.

W. E. CHAMBERLAIN,
General Manager.

Boston, July 1, 1901.

Form T, 523.

THE NEW YORK, NEW HAVEN AND HARTFORD RAILROAD COMPANY.

.....DIVISION.

RECORD OF EXAMINATION OF SIGHT, COLOR SENSE AND HEARING.

....
NAME. OCCUPATION. DATE.

SIGHT.

Acuteness of Vision without Glasses.	Right Eye.	Left Eye.	Both Eyes Open.	Reading Test, both Eyes Open.	Without Glasses.	With Glasses.
Distance in feet, at which standard test-type are read,				Size of reading test-type read correctly,		
Smallest line of standard test-type read correctly,				Written train orders read correctly, (Yes or No.)		

Position Signal Test, without glasses.	Right Eye.	Left Eye.	Both Eyes Open.
Distance in feet, at which card with semaphore arms can be read correctly.			

COLOR SENSE.

Test-Skein Submitted.	Numbers on the Skeins in Standard Holmgren Color Set, selected as similar to Test-Sk'ns.
A Green.	
B Rose.	

	Size of Opening															
Testing Lantern two lights.		Number shown.	1	3	2	4	3	5	4	6	5	7	6	8	7	9
		Name given.														
		Number shown.	8	10	9	11	10	12	11	13	12	1	13	2	1	3
		Name given.														

	Size of Opening													
Testing Lantern two lights.		Number shown.	1	2	3	4	5	6	7
		Name given.							
		Number shown.	8	9	10	11	12	13	1
		Name given.							

HEARING.

Number of feet at which numbers or words can be repeated correctly when spoken in a conversational tone.	Right Ear,	Left Ear,
Number of feet at which ratchet acounter can be heard.	Right Ear,	Left Ear,

REMARKS :

.....
Examiner.

ERRATUM. — In table "Color Sense," page 21, for "two lights" read "one light."

FORM 1523.

THE NEW YORK, NEW HAVEN & HARTFORD RAILROAD CO.

This certifies that I have this day carefully tested the Acuteness of Vision and Color Preception of..... whose signature is attached hereto, and find that he is not disqualified by color blindness or other defective sight from employment where he is required to distinguish form and color of signals.

.....Examiner.

.....
DATE.

.....
SIGNATURE OF PARTY EXAMINED.

On the Burlington System a very similar standard has been adopted.

In June, 1901, a committee of the Ophthalmological Section of the American Medical Association made the following report to their Section at the meeting at St. Paul:

Mr. Chairman and Members of the Ophthalmological Section of the American Medical Association:

Your committee appointed three years ago, with the view of framing resolutions for the regulation of the eye and ear requirements of transportation employes, were unable two years ago to bring in a unanimous report. The committee was, therefore, requested to retain its membership and endeavor to report at the following meeting. Meanwhile the committee was led to believe that action upon this subject would be taken one year ago by the International Medical Congress meeting in Paris. It was, therefore, deemed wise to wait until the committee of the International Congress submitted its report, feeling that valuable ideas might be therein contained, which would enable us to improve the character of our own work. The committee, therefore, did not report at the city of Columbus, and since then, although the chairman of this committee has endeavored with all possible assiduity to ascertain something concerning the nature of the work accomplished along these lines by the International Congress, he has been absolutely unable up to the present time, although inquiry has been made along every possible avenue, to ascertain whether any work of this nature was accomplished or not. It, therefore, seemed useless to wait for the action of our European confrères, believing that it is not necessary for a country which leads all other countries in its transportation facilities to await the action of other nations. Your committee, therefore, begs leave to submit to the section the following resolutions, which have been unanimously adopted, and which it is hoped will

also be adopted by the American Medical Association, and then correctly placed before the proper railroad authorities of North America.

This work should be superintended by this section.

SECTION 1. The essential principle to be advocated is that railroad corporations shall require a scientific and correct examination of the eyes and ears of those employes at all to be concerned with the active operating of trains, or in giving or receiving signals.

SECT. 2. Such primary examinations should, whenever possible, be made by regularly appointed eye and ear surgeons, and this point is emphatically urged, especially as the expense of a first examination may always be borne by the applicant; but if such a course is not deemed expedient, the company's surgeon, aided by his medical assistants, might conduct them, with the understanding that all doubtful cases shall be sent to a regularly appointed eye and ear surgeon.

SECT. 3. There shall be two general standards of visual and aural requirements, viz., those for new men hoping to enter the service and to be actively engaged in the operation of trains and in giving and receiving signals; and secondly, those men engaged in similar work who have been uninterruptedly in a company's service for five years, and who have, therefore, a right to be called old employes.

SECT. 4. New men shall be required to possess perfect color sense. They shall also have a vision of 20|20 in each eye, without glasses, and have healthy eyes, and not over one diopter of hypermetropia. They shall also hear the whispered voice at twenty feet in a quiet room, and have healthy ears

SECT. 5. For the purposes of graduated requirements old employes shall be divided into two classes, as follows:

Class A.—Engineers, firemen, conductors, brakemen, switchmen, signalmen, switch tenders and engine dispatchers.

Class B.—Track foremen, bridge foremen, crossing flagmen, bridge tenders, gatemen, train baggagemen, telegraph operators, station agents and station baggagemen.

Employes enumerated in Class A shall not be retained in such positions if vision sinks below 20|30 in one eye and 20|40 in the other, or if the whispered voice cannot be heard in a quiet room at fifteen feet by one ear and ten feet by the other. Employes enumerated in Class B shall not be retained in such positions if vision sinks below 20|40 in one eye and 20|50 in the other, or if the whispered voice cannot be heard in a quiet room at ten feet by both ears. Employes, and especially engineers and firemen, enumerated in Class A, must reach the visual standard without glasses, and will not be allowed to wear distance glasses when on duty. Employes enumerated in Class B may reach the visual standard with glasses, and will be allowed to wear glasses when on duty, and will be required to do so if the wearing of glasses is necessary to bring vision up to the proper standard, and shall always be required to

carry an extra pair of glasses when on duty, in case of accident to one pair. All employes shall have perfect color sense.

SECT. 6. Re-examination shall be made of all men every three years, and after severe illnesses, or accident, or any occurrence which seems to cast doubt on the visual and aural capacity of an individual. Re-examinations shall also be made more frequently on men known to be excessive users of tobacco, or to be suffering from syphilis, albuminuria, diabetes, or acute or chronic eye and ear disease. Men shall always be re-examined before promotion.

SECT. 7. Men known to be excessive users of liquor shall not receive employment.

Respectfully submitted,

FRANK ALLPORT, M. D.,
Chairman of Committee.

92 STATE STREET, CHICAGO.

One of the above committee, Dr. W. Thomson, mailed a minority report to the Secretary of the Section at St. Paul, but it was not delivered to the Secretary in time to be presented at the meeting, and therefore did not form a part of the proceedings of the Section. The paper of Dr. Thomson is as follows:

1426 WALNUT STREET, PHILADELPHIA, June 1, 1901.

Dr. E. C. Ellett, Secretary of the Section of Ophthalmology of the American Medical Association.

Dear Doctor: Last year I was placed on the Committee on the Visual and Aural Qualifications of Transportation Employes, of which Dr. Allport is chairman.

Being unable to consult with him or his committee and other colleagues from various parts of the country, to enable me to discharge my duty to the section in advising them as to their action, I have decided to ask you to present these few words when the section acts upon the committee's report.

Trusting that I may be excused for performing my duty in this manner, I am Truly yours,

WILLIAM THOMSON.

Mr. Chairman and Members of the Section of Ophthalmology of the American Medical Association:

I may be unable to be present at our meeting at St. Paul to discharge the duty laid upon me at our last meeting to aid in advising the section what action to take upon the report of the Committee on the Visual and Aural Qualifications of Transportation Employes, of which I am a member, and Dr. Allport is the chairman.

The substance of a report has been submitted to me by the chairman, and in my inability to confer with the committee and other colleagues, I feel constrained to object to its whole-

sale condemnation of examinations made by instructed but non-professional persons; and to the demand that they should be made by none other than ophthalmic and aural surgeons.

It is well known that twenty years ago the Pennsylvania Railroad adopted, and has kept in use since, amended and improved, a system of non-professional examinations, and that it has been adopted by other corporations estimated to control about 150,000 miles of track.

Our section might well pause before the task of overthrowing so useful a beginning instead of trying to improve it by further evolution. In such an issue some members of our section might be brought into antagonism with the officials of great roads of which they are now valued advisers.

We possess little or no power, except that of persuasion, to enforce any changes we might demand.

The officers of roads having now any system would hesitate, in the present condition of the labor market, to invite struggles with their employes by reopening questions so full of danger.

It must also be remembered that the well described dangers from defects of color and form no longer exist, except on those roads which have never adopted any system. On the P. R. R. the dangerous men were eliminated twenty years ago, and the system now suffices to prevent their admission. So well satisfied are the officials of that road—controlling 15,000 miles of track and 80,000 employes—that no influence of mine would suffice to overthrow confidence in it; and I shall remain content with the system when my recently improved lantern has been adopted generally as an addition to the color stick and wools, since it will detect those doubtful cases of green-red blindness which have caused distrust in the Holmgren method so well described by Edridge-Green in the April number of the London *Lancet*, 1901.

The ophthalmic surgeons of our great roads are best fitted by their experience and influence with the officials of those roads to guide us aright, and I would suggest that the present committee be increased by the addition to it of a sufficient number of them to decide as to the possibility of pressing upon the roads the necessity of using only specialists as examiners; the division of employes into classes; and the consequent frequent re-examination of all signalmen.

I will conclude by adding an extract from a letter of March 3, from the General Manager of the Pennsylvania Railroad:

"I am in receipt of papers sent by you, and desire to say that, so far as our system east of Pittsburgh and Erie is concerned, we have no desire to change the method inaugurated by you for the examination of employes in connection with color-sense and acuity of vision. The method has been entirely satisfactory, and with such improvements as you have made and are making we are entirely satisfied.

"In order to ascertain the views of our Western lines upon the same subject, I asked their General Manager for his views, and he advises me that the present method of examining employes for color-sense and acuity of vision as prescribed for by you has been found entirely satisfactory on his lines. He received copies of pamphlets issued by Dr. Allport, of Chicago, and had them gone over by the oculist of his company, and it was recommended by him that they make some slight changes in their practice; the changes, however, being minor ones, and not affecting the principle of their present practice."

An experienced division superintendent also writes me:

"So far as Dr. Allport's attitude is concerned to the arrangement in existence on the Pennsylvania Railroad, for examination of employes, I would say that I do not think you will get any of our operating officers to agree that our present plan is not effective. Personally, I prefer it to any other that has thus far been suggested. It is a clean, concise and definite way of ascertaining the condition of a man's sight and hearing, and I prefer it to taking the judgment of those who are interested solely in making the examination. I believe I have on one occasion told you that one of the greatest advantages of our present method of examination is that we, as examiners, have no interest in any particular employe and our sole object of examination is that we may not place employes in positions in the service that would jeopardize life or limb."

I am unalterably opposed to local surgeons having charge of this work. The layman can secure as effective results with your apparatus as the surgeon and there is no probability of the layman being influenced to give anything but actual facts —in fact, he must, or make himself a party to the complications that would arise in employing those unable to pass the examination properly.

Our present methods keep politics out of the transaction. We need no professional assistance other than that which you are this week giving my train-masters.

Respectfully submitted,

WILLIAM THOMSON, M. D.

1426 WALNUT STREET, PHILADELPHIA, PA.

The standards which are used in the above tests to determine the acuteness of vision are the test types of Professor Snellen, or those based on his formula $v = \frac{d}{D}$ in which v represents the acuteness of vision, d is the distance at which the test letters are read by the person under examination, and D

is the distance at which they are seen under the standard angle of five minutes. Professor Snellen found that letters whose height and breadth subtended an angle of five minutes, and the width of whose component parts subtended an angle of one minute could be easily seen by the average normal eye; and although many eyes, especially in young people, will be found to have an acuteness of vision greater than this, it has been found to be a convenient and satisfactory standard, and has been generally adopted, so that a person who can read the twenty-foot letters at a distance of twenty feet, or the six-meter letters at a distance of six meters, that is, one who can read the letters when seen under the visual angle of five minutes, is considered to have normal acuteness of vision.

There is a very considerable variation in the visibility of different letters on any one line of test types, and in some respects the illiterate test types of Professor Snellen, in which all the characters are alike, and one is simply required to recognize their different positions, is a fairer test. The cards of Williams test types with semaphore arms in place of letters, also give a test in which all the characters are alike, and moreover correspond to the actual conditions of railroad service. The following cut shows one of these cards reduced to about one-third of its original size:

In practice we find there is so much variation in the size of test types published by different firms, or even in different editions published by one firm, that it would be possible for an applicant to pass if examined with one set of types and to be rejected if examined by another.

The following table shows the calculated sizes which letters should have in order to subtend a visual angle of five minutes at the indicated distances. These sizes have been calculated by the formula $x = 2AB \sin \frac{1}{2} a$, in which x is the height of the letter; AB is the distance from the person examined to the letter. and a is an angle of five minutes.

Height and width of test letters necessary in order to subtend an angle of five minutes at various distances.

English Feet.	Meters.	Meters.
20 feet...0.349 inches.	5 meters... 7.27 mm.	6 meters... 8.73 mm.
30 " ...0.524 "	6 " ... 8.73 "	8 " ...11.64 "
40 " ...0.698 "	10 " ...14.55 "	12 " ...17.46 "
50 " ...0.873 "	15 " ...21.82 "	18 " ...26.19 "
70 " ...1.222 "	20 " ...29.10 "	24 " ...34.92 "
100 " ...1.745 "	30 " ...43.65 "	36 " ...52.38 "
200 " ...3.491 "	50 " ...72.75 "	60 " ...87.30 "

The following table shows the measured size of some of the test types on the market. It will be noticed that there is not

much variation in the different editions of Snellen's types published in Holland, but in the American reprints there is, in some cases, enough variation from the correct sizes to render them unfit for use.

SNELLEN'S TEST TYPE.

Edition of 1875.

6	meters	9.	mm.
9	"	13.	"
12	"	17.7	"
18	"	26.2	"
24	"	34.7	"
36	"	52.	"
60	"	86.9	"

Edition of 1898.

5	meters	7.5	mm.
6	"	9.6	"
10	"	15.4	"
15	"	22.5	"
20	"	29.8	"
30	"	44.5	"
50	"	74.	"

Edition of 1898.

6	meters	9.	mm.
8	"	11.4	"
12	"	17.7	"
18	"	25.7	"
24	"	34.7	"
36	"	52.4	"
60	"	88.	"

AMERICAN RE-PRINTS.

Published by A.

16.4	feet	.24	inches.
19.7	"	.27	"
24.6	"	.34	"
29.5	"	.41	"
39.3	"	.54	"
49.	"	.69	"
66.	"	.93	"
79.	"	1.22	"
131.	"	1.83	"

5.	meters	6.	mm.
6.	"	6.8	"
7.5	"	8.8	"
9.	"	10.5	"
12.	"	13.6	"
15.	"	17.5	"
20.	"	23.5	"
27.	"	31.	"
40.	"	46.5	"

Published by B.

16.4	feet	.29	inches.
19.7	"	.34	"
24.6	"	.39	"
29.5	"	.52	"
39.3	"	.69	"
49.	"	.86	"
74.	"	1.29	"
98.	"	1.72	"
148.	"	2.56	"

5.	meters	7.5	mm.
6.	"	8.7	"
7.5	"	10.	"
9.	"	13.	"
12.	"	17.4	"
15.	"	21.8	"
22.3	"	32.6	"
30.	"	43.5	"
45.	"	65.	"

Published by C.

20	ft.	.31	in.	5	meters	6.6	mm.
30	"	.47	"	6.	"	8.	"
45	"	.70	"	9.	"	12.	"
65	"	1.05	"	13.5	"	18.	"
100	"	1.57	"	20.	"	26.8	"
200	"	3.15	"	30.	"	40.	"
				60.	"	80.	"

20	ft.	.39	in.	6	meters	9.7	mm.
30	"	.57	"	9	"	14.5	"
40	"	.76	"	12	"	19.3	"
50	"	.94	"	15	"	24.	"
70	"	1.32	"	21	"	33.5	"
100	"	1.87	"	30	"	47.5	"
200	"	3.73	"	60	"	94.5	"

In so important a matter as the standards for measuring the acuteness of vision it would seem desirable that the American Ophthalmological Society should have sets of test letters carefully engraved to correspond exactly to the calculated sizes, and that these should be sold to members at cost.

In hypermetropic men of forty-five years of age or over, there is often a very rapid falling off in the acuteness of vision, and the following case will show the reason for the rule of the New Haven road, which requires a yearly re-examination of

the vision of those employes who can read the test letters at the standard distance through a convex glass of two diopters, the usual period for re-examination being three years. A man forty-eight years old was examined May 15, 1899; he then had, without glasses, vision of 20|20 in the right eye and 20|30 in the left eye, and with a convex glass of two diopters he had the same vision. When he was re-examined in May, 1900, his vision without glasses had fallen to 20|50 in each eye, although with glasses it was as good as at the previous examination.

More attention should be paid to the effect of fatigue in reducing the acuteness of vision, and it will be found that on long runs, especially at night, the acuteness at the end of the run will be considerably less than at the beginning. This is an additional reason for requiring a high standard, especially for men on the head end of a train, for if only a moderate amount of vision were demanded at the start the effect of fatigue might bring it much below the danger point before the run was completed.

At the International Conference at Amsterdam in 1895, Dr. J. de Lantsheere, occulist of the Belgian railways, stated that in examining a number of men who had come to him in the morning fatigued by their work of the previous night, he found an unusually large number who were defective in acuteness of vision, and on testing several men, before and after a night run on express trains, he found the sight diminished as follows:

Before the Run'		After the Run.		Duration.
Right Eye.	Left Eye.	Right Eye.	Left Eye.	
1-3	1-2	1-4	1-3	2 hours.
2-3	2-3	1-3	1-2	2 hours.
2-3	2-3	1-2	1-2	1 hour.
1-2	1-4	1-3	1-4	1 and 1-2 hours.

After testing this same question on one of the express trains on the run from Chicago to Burlington, 206 miles, made in five hours, Dr. J. A. Denney, medical director of the road, writes as follows:

"CHICAGO, ILL., Oct. 6, 1898.

"Dr. Charles H. Williams, 15 Arlington Street, Boston, Mass.

"*Dear Dr. Williams:* On my return to Chicago yesterday I received your kind letter of September 28, asking what results we are getting in regard to the acuteness of visual perception before and after long runs, especially at night, in cases of engineers and firemen.

"In reply will say that I made a number of examinations in accordance with the suggestions you made to me when you were last in Chicago. These examinations or tests were made

under the most favorable conditions possible for the men. I selected clear nights with a full moon and a medium temperature. The average difference between the vision prior to starting on the run and immediately after the run, of both enginemen and firemen, showed that the vision was about one-fourth less at the end of the run than at the beginning. My impression is that in bad weather and very dark nights that the acuteness of vision will be even more than one-fourth less at the end of the run."

Again on March 30, 1900, he writes: "I have not made any tests of this kind recently, but the tests that I made I think were very accurate, and it is clear to my mind that the vision is one-fourth less after a run from Chicago to Burlington on one of our fast trains, and it is also clear that the color perception is, to a certain degree, affected, not to the point of being dangerous in a man who has otherwise normal color sense."

In regard to the use of glasses they do not help in rain, storm or fog, when most needed, and in case of accident it might be difficult to prove whether they were being worn or not. New men entering the engine, train or yard service, or being promoted to such places, should come up to the required standard without glasses; but there will always be a few cases of old employes with an excellent record, who require the use of glasses to bring their vision up to the passing point, and such cases should be handled individually by the general operating officer of the road, with all the facts reported to him, the practice on some roads being that such men are given the less trying positions.

In testing the acuteness of color perception it is essential that the green and the rose test skeins shall have the proper shade of color, as shown by Professor Holmgren, to give the best results.

Sets of Holmgren worsteds have been obtained from Dörffel of Berlin, from another dealer in Berlin, through Millar & Weltch in Boston, from A. J. Lloyd in Boston, from E. B. Meyrowitz in New York, from Fraulein Letty Oldberg in Upsala, and a Thomson's stick from Queen & Co. of Philadelphia. A comparison of these sets shows a considerable variation in the shade of the green test skein, and if we consider the worsteds from Upsala, which are put up in accordance with the specifications of Professor Holmgren, as the standard, we shall find the green test skein of most of the American sets to be too light, and in one of the Berlin sets to be of a very different shade from the Swedish set.

Dr. W. A. Nagel, Instructor in Physiology at Freiburg i. Br., who is himself defective in his perception for green, says in an

article in the *Archives of Ophthalmology* for March, 1900, "In order to show how greatly the results of the test depend upon the collection of yarns used, I wish to present the findings with four different sets. In the Freiburg Physiological Institute were three different sets: one selected from local shops, one put on the market by Dörffel of Berlin, and the third obtained from Letty Oldberg of Upsala. In my first trial with the Berlin set I matched with the light green sample, gray and grayish brown (but not rose) as well as green. According to Holmgren such an error does not prove the existence of color-blindness. As I show later, a number of persons who made this mistake had not a dichromatic but a trichromatic color sense, although with diminished powers of differentiation. The second test with purple (or rose) is supposed to show whether there is color-blindness or only a reduced color sense. He that matches only purple with the test color may, according to Holmgren, have a reduced, but nevertheless a trichromatic color sense.

"With this purple test I did not make a single blunder and felt quite positive in distinguishing purple from gray, bluish green, red and violet. Nor with Holmgren's third test with a saturated spectral red did I make any mistakes. In tests with another set of worsteds I made no blunders with either the green or the purple. I then went to the eye clinic and made the test successfully with their set of worsteds, and was assured that I was not color blind, but at the most merely weak in color sense, since I selected the colored yarns rather more slowly than persons with normal trichromatic perception. The Swedish set was better than the rest, in that it contains more confusion colors, and when only a few greens were left in and the bluish greens and yellowish greens were removed, I failed almost always on the green test. Holmgren intended the bluish greens and yellowish greens to be used only in the test for the diagnosis of tritanopsia (violet blindness), and stated that these yarns should not be mixed with the others. If bluish greens were present I carried out the test successfully. I was successful with the purple test also, when the Swedish set was used. According to the results obtained with the best of the worsted tests, I was what Holmgren would call 'incompletely color blind.' Yet in my case this diagnosis was entirely wrong, although as a matter of fact my case is exceptional, and I have found but a single other green blind person who blundered in the test for green, but did the purple test successfully. My experience with the purple test can hardly be used as an argument against the practical value of Holmgren's method. There is, however, one practical point that I wish to call attention to. In my case I matched the purple test skein perfectly, but failed always on the green when the set of yarns was properly composed. Yet Cohn and Daae have proposed that the purple test be made first and the green resorted to only when mistakes have been made with the pur-

ple. This 'simplification' of the test in the light of my personal experience does not seem judicious."

Dr. Nagel has constructed a new apparatus for testing color perception by means of colored glasses so arranged that an apparently equivalent field of red and yellow can be shown, or two reds, etc. Two colors can be shown at one time, and a sliding screen behind each regulates their intensity. Your committee have obtained one of these instruments, but have not yet had time to give it an extended trial. It seems to be well adapted to the testing of referred and doubtful cases by an ophthalmic surgeon, but not to the ordinary work of railway examinations.

In his paper, Dr. Nagel claims that the test with Holmgren worsteds should not be relied upon as the only test to show whether the person can recognize colored lights and flags, and that for this purpose the color perception of the fovea and the adjacent central portions of the retina should be specially tested with small colored lights.

In the supplement to the last edition of "Nettleship on Diseases of the Eye," Dr. William Thomson favors the substitution of a loose set of colored worsteds for the stick. He says, "As the result of much experience, and after a study of the entire subject, I suggested in 1894 some improvements that would enable a new test to be used in connection with the color-stick or any substitute for it. The color skeins of this new wool test have been most carefully selected, and a standard set will be kept, so that renewals may be made of the entire set or of those skeins that may become faded, soiled or lost. The new set consists of a large green and a large rose test skein and forty small skeins, each marked with a bangle having a concealed number, extending from 1 to 40, placed in a double box, so arranged as to keep the two series apart and to permit each to be exposed upon a table in a confused mass. The stick is dispensed with, as giving too fixed an arrangement to the skeins and not enough *confusion*, although the skeins can be readily removed from their hooks and changed in position for this purpose, and should be so used. The large green skein being placed near by, the small skeins, from one to twenty, are exposed in good daylight, and the employe under examination is directed to select ten shades of the color of the test skein. One with normal vision will choose promptly and with ease the ten greens with odd numbers on the bangles. A color-blind person will hesitate, and his selections will contain some even numbers, and the confusion colors will be shades of brown, etc., containing some red, or shades of gray, and will indicate the color defect.

"These figures are to be recorded on a blank and the twenty skeins are to be removed. A large rose skein is then used and the examination repeated in like manner with skeins numbered from 21 to 40, and the result recorded. The confusion skeins, which have even numbers, are blue, green and gray. From

the selection made by the man found color defective by the rose test we are able to decide the character of his color blindness. Those selecting blues are red blind, those taking greens and grays are green blind, according to the nomenclature of Holmgren. There are ten roses and ten confusion colors in the second series. The red test skein of the stick, with its confusion colors, is omitted entirely, and the test is made to conform more strictly with Holmgren's method, while the examiner is also provided with forty questions of decisive clearness. Greater scientific accuracy is obtained by this method, and with the careful selection of these confusion colors I now regard this system as an improvement upon the stick and as a safer and more simple method to be used by a non-professional examiner."

On the Burlington System complete sets of 125 tagged Holmgren worsteds have been in use for a little over ten years; they continue to give satisfaction and afford an easy way of keeping an accurate record of each examination, the odd numbers being the true colors and the even numbers the confusion colors. This arrangement of tagged worsteds has been adopted by the New Haven System and some other roads.

In connection with the use of the large tagged sets of worsteds it has been found of much service to have a reference set of colors at the central office where the reports of the examinations are filed. This reference set is made by taking the colors of one of the standard sets and sewing them in numerical order to a piece of white cotton cloth. If it is desired to see what colors have been selected in any examination the cloth with this reference set is spread on a table, and each number, as given in the report, can be quickly found on the reference set.

The following description by Professor Holmgren of the proper method of using his test is quoted from the book of Dr. Jeffries on Color-blindness.

"METHOD OF EXAMINATION AND DIAGNOSIS.

"The Berlin worsteds are placed in a pile on a large plane surface, and in broad daylight; a skein of the test-color is taken from the pile and laid aside far enough from the others not to be confounded with them during the trial; and the person examined requested to select the other skeins most resembling this in color, and place them by the side of the sample. In the first place it is necessary that he should thoroughly understand what is required of him; that is, that he

should search the pile for the skeins making an impression on his chromatic sense independent of any name he may give the color, similar to that made by the sample. The examiner should explain that resemblance in every respect is not necessary; that there are no two specimens exactly alike; that the only question is the resemblance of the *color;* and that, consequently, he must endeavor to find something similar of the same shade, something lighter and darker of the same color, etc. If the person examined cannot understand this by a verbal explanation, we must resort to action. We must ourselves make the trial by searching with our own hands for the skeins, thereby showing in a practical manner what is meant by a shade, and then restoring the whole to the pile, except the sample-skein. As it would require much time to examine each individual in this way, it is advisable, when examining a large number at the same time, to instruct all at once, and, moreover, to ask them to attentively observe the examination of those preceding them, so as to become more familiar themselves with the process. By this, time is saved, without loss of security; for no one with a defective chromatic sense finds the correct skeins in the pile the more easily from the fact of having a moment before seen others looking for and arranging them. He makes the same characteristic mistakes; but the normal observer, on the other hand, generally accomplishes his task much better and more quickly after having seen how it must be done, and this is the advantage of our method."

"TEST I.—The *green* sample is presented. This sample should be the palest shade (the lightest) of very pure green, which is neither a yellow green nor a blue green to the normal eye, but fairly intermediate between the two, or at least not verging upon yellowish green.

"*Rule.*—The examination must continue until the one examined has placed near the sample all the other skeins of the same shade, or else, with these or separately, one or several skeins of the class corresponding to the 'colors of confusion' (1-5), until he has sufficiently proved by his manner of doing it that he can easily and unerringly distinguish the confused colors, or until he has given proof of unmistakable difficulty in accomplishing this task.

"*Diagnosis.*—He who places beside the sample one of the 'colors of confusion' (1-5)—that is to say, finds that it resembles the 'test-color'—is *color-blind.* He who, without being quite guilty of this confusion, evinces a manifest disposition to do so, has a *feeble chromatic sense.*

"TEST II.—A purple skein is shown the examined. The color should be midway between the lightest and darkest. It will only approach that given in II. of the plate, because the color of the worsted is much more brilliant and saturated, and more towards the blue.

"*Rule.*—The trial must be continued until the one examined has placed near the sample all or the greater part of the skeins

of the same shade, or else, simultaneously or separately, one or several skeins of 'confusion' (6-9). He who confuses the colors selects either the light or deep shades of blue and violet, especially the deep (6 and 7), or the light or deep shades of one kind of green or gray inclining to blue (8 and 9).

"*Diagnosis.*—1. He who is color-blind by the first test, and who, upon the second test, selects only purple skeins, is *incompletely color-blind.*

"2. He who, in the second test, selects with purple only blue and violet, or one of them, is *completely red-blind.*

"3. He who, in the second test, selects with purple only green and gray, or one of them, is completely *green-blind.*"

"THE DETECTION OF COLOR-BLINDNESS AMONG LARGE NUMBERS.

"Those who, in the collection of material for scientific research or for the practical purpose of control among railroad employes and sailors, have to test the color-sense of large numbers of persons, in order to separate the color-blind from the normal, and ascertain the former's kind of defect, will have found the great value of a method which is rapid and sure in its working. This is very satisfactorily fulfilled by my method with the worsteds as originally given. But, to gain still further time,—that is, to increase the rapidity of the examination without detracting from its surety and practicability,—I have lately somewhat simplified the method of working, whilst retaining the same principle, thereby gaining a third or more of the necessary time.

"1st, In the first test, we leave out of the bundle of worsteds all the greens, with the single exception of those to which the test-color I. belongs (*vide* the plate), and which should consist of about five grades or shades.

"2d, When using the second test, we put in the bundle or near it the bluish greens of various intensities, corresponding to the confusion-color No. 9.

"3d, Before commencing, let some fifty stand round the table on which the worsteds are placed, or be so arranged that they can see what takes place on the table. Then call attention to the test as follows:

"4th, We hold up the five green worsteds before the examined and tell them to carefully observe them, so as to readily and quickly pick them out from all the mixed-up colors. Then we place the test I., the brightest of the five, to one side, and mix the others well in the bundle. With our own hand we rapidly pick these out again, and lay them with the first to one side: in other words, we perform the test just as it should be, and this we can repeat as often as is useful in hastening the examination.

"5th, After this preparation, we let the examined come one after the other to the table, and repeat the test they have seen done. The others must keep quiet, and neither by laughing, calling out, or signs, interfere with the one being tested.

"6th, When any has shown himself color-blind by this test, then, for the differential diagnosis, Test II. will be used. Test III. need not be at all.

"7th, As in general the test is rapidly made, a feeble sense of color is shown by great slowness in the manifestation."

The following directions sent out with one of the Berlin sets of Holmgren worsteds shows the method now largely used in Berlin:

Translation of the directions with Berlin set of Holmgren worsteds recently imported by Millar & Weltch.

TESTING FOR COLOR-BLINDNESS WITH HOLMGREN ZEPHYR WORSTEDS.

The examination consists of two tests:

1. A primary, by means of which it can be determined whether a person has normal color-perception or not.

2. A special test, to determine the kind and degree of the imperfect color-sense.

Among the whole collection the following colors should be particularly noted:

a. A pure light green, designated test skein 1.

b. Four darker shades of the same color.

c. A medium rose color, designated test skein 2.

d. A bundle of confusion colors, namely:

Greenish gray.
Brownish gray.
Light yellow.
Light rose (flesh color).
Light brown.

All the colored worsteds, with the exception of those above mentioned, from a to c inclusive, are to be mixed together on a table or other surface of suitable size.

Clear, uniform daylight is necessary; the background should not have any disturbing, strongly marked color.

The green test skein is then placed at a little distance from the heap of worsteds.

Before beginning the examination the person to be tested should be made acquainted with its general character, and especially the green test colors should be shown him, at one time held together in the hand, and again when placed on the whole collection of the remaining colors, in order to show him how strong a contrast they make with the latter, and therefore how easy it must be for a person with normal color-perception to pick them out.

A. The primary test is made as follows:

The test skein, 1 (green), is placed at a little distance from the rest, the four darker shades of this color are then mixed with the rest of the colors, and the person to be tested is requested to pick them out quickly one after the other and place them beside the test skein. The Examiner counts aloud, crisp and distinctly, each separate skein as it is selected, whether it is a true color or not, "one, two," etc. If there are several persons to be examined at one time the above test will be made by them all, one after the other.

The Examiner must watch the test in each case with the greatest attention. Those who pass the above test quickly and correctly have normal color-perception. On the other hand, those who make the smallest mistake must undergo a further test, which is made as follows:

B. The special test requires in the first place a strict repetition of the primary test.

If there is shown,

a. An uncertainty or uncommon slowness in selecting the worsteds, the test will be repeated in the following modified way:

While the person to be examined stands with his back toward the table the four green worsteds are placed on the heap so that they are wholly or at least in part in plain sight and irregularly placed one to the other, on top of these, confusion colors are placed straight and parallel. The person to be examined is then told that he will find the true colors in plain sight, and that when he turns about he is to pick out these colors and place them beside the test skein. This is to be done in a measured time while the Examiner counts 1, 2, 3, 4,—each number representing one second, but the rapidity of the count can also be adapted to the person to be tested, and one thus determines the time which he requires to pick out the skeins and lay them beside the test skein.

If the person who is being examined accomplishes the test, but without confining himself to the given time, or if within the given time he selects false colors, it is shown that he has a feeble color-perception.

b. That the person examined, instead of selecting the prescribed colors, takes one or several of the confusion colors, his defect consists in either an incomplete or some form of complete color-blindness, which can be more accurately determined by the following additional test:

For the additional test we use the test skein, 2 (rose), which is placed apart from the others, and the person examined is told to select from the heap of worsteds some or all the skeins which have a similar color, and place them beside the test skein.

Whoever does this moderately, quickly and accurately is only incompletely color-blind; on the other hand, he who places other colors, such as purples, with the test skein, or at

least some distinct approach to purple, is completely color-blind.

He is completely red-blind if the confusion colors which he selects are dark blues or violets.

He is completely green-blind if they are greens, blue greens or grays.

He is completely violet-blind if they are reds or orange.

He is totally color-blind when the confusion colors he has selected include colors of all kinds, and the person examined arranges them only according to the similarity of their intensity.

In the sets of Holmgren worsteds (135 colors) sent out from Upsala, in Sweden, the green test skein No. 1 is tied up with four other skeins of green of different shades, and these five colors can be used as indicated in the above directions. The rose test skein No. 2 is tied up with eight other rose skeins. The eleven blue greens are tied, up in a separate bundle marked "Test packet II.," and the twelve yellow greens are tied up in a packet marked "Test packet III." The last two packets are not to be used in the first test with the green test skein No. 1, if it is carried out in accordance with the modified Holmgren instructions. With the second test with the rose test skein No. 2, the bluish greens should be mixed with the rest of the worsteds.

In the test for violet blindness the blue greens and the yellow greens alone are used. They are mixed together, then placing one of the clear blue greens on one side of the pile and one of the clear yellow greens on the other, the person is asked to separate the remaining skeins into two groups, placing the blue greens together and the yellow greens together. A violet-blind person will be unable to do this.

If it is preferred to make the tests according to Holmgren's first directions, all the skeins will be mixed together.

Before using the skeins for testing purposes they must be separated from the bundles in which they are sent out by the makers, and must be used as separate skeins.

When the New York, New Haven & Hartford Railroad introduced their improved methods of testing color perception, etc., in 1899, a test with a lantern devised by Dr. C. H. Williams, showing colored lights of varying size and intensity, was introduced as a part of the routine examination in each case. This lantern has been improved, and in its present form is now in use on their whole system. It is a square lantern, twelve inches high and five inches wide on each face, and its general arrangement can be well seen in the following cut:

* DR. WILLIAMS LANTERN.

The lower disc on the face of the lantern contains five red and four green glasses, of different shades, and one each of cobalt blue, yellow, white and smoke. The upper disc has glasses of London smoke of different shades. There is a diaphragm which moves between the discs and has openings of three sizes, 5-64, 1-4 and 3-4 of an inch, respectively, to regulate the area of the colored surface. By turning the lower disc the different colors can be shown, and by turning the upper disc the intensity of the colors can be modified by combining the smoke glasses of the upper disc with the colored glasses of the lower disc. By turning the upper disc in a certain position one of the lights can be shut off, and in this way the lantern can be used to show either two lights at one time, or one light at a time, as desired. Under each glass is an opening illuminated by the lantern, which shows the number of that glass; this opening is screened from the person under examination, but can be seen by the examiner, and allows him to note for his record the number of the glass shown and the name given to it. A new improvement has been introduced in the illumination of the lantern by having a small incandescent electric lamp in place of the oil lamp. This lamp can be connected with the ordinary incandescent office circuit, and

* This lantern is made by Peter Gray, 12 Marshall Street, Boston, Mass.

gives a much more uniform light than the oil. In the base of the lamp is a small rheostat with six resistances; by this means the intensity of the light can easily be varied by fixed amounts, and persons who depend on the intensity of the light to distinguish its color are thus more easily detected.

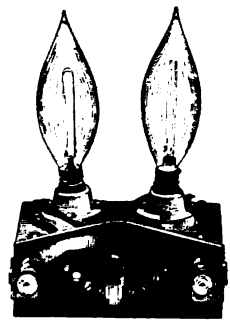

ELECTRIC LIGHT.

Dr. William Thomson is also a warm advocate of the use of a lantern with colored lights in addition to the worsted test, and concerning a lantern of his invention he writes: "For two-fifths of the time, during the night, of an employe's life, he is expected to govern his actions by colored lights, and this lantern appears to have a practical value in imitating the night signals in form, color, intensity and size, as they appear under all obstructions caused by rain, snow, fog and smoke. Its power over the wools to detect the central amblyopias of tobacco, alcohol, drugs, disease and scotomata, that would not be revealed by the skeins, makes it almost a necessity. I propose this lamp or lantern then as an adjunct to the 'color wool stick' and the 'new wool test' to be used, if desired, under the supervision of the division superintendent, by intelligent instructed laymen. With this addition to the Pennsylvania Railroad system it seems to me more complete and sufficient to eliminate from any road all color-blind employes and to furnish an insuperable barrier to their admission to the service.

"It consists of an asbestos chimney, which can be placed on a kerosene lamp in universal use on railroads, or over an argand or other gas light, electric lamp or spring candlestick. Two discs, four inches in diameter, are so placed upon the chimney as to permit of their being superimposed partly. The lower disc contains seven glasses in apertures of half an inch in diameter, having the white, red, green and blue colors in general use on railroads. This may be considered the 'examination in chief,' whilst the upper disc, when combined with the lower by turning one or both, furnishes the 'cross examination.' The upper disc has two apertures, one half an inch, the other one-twelfth of an inch in diameter. The other five have one white ground glass, one deep London smoke, one pink,

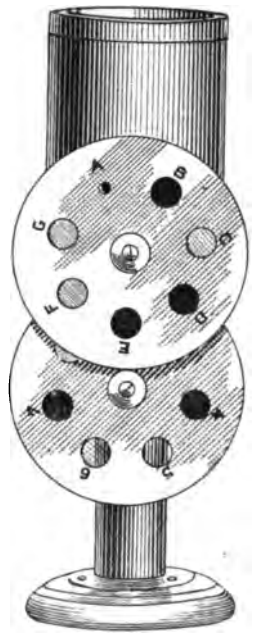

† DR. THOMPSON'S LANTERN.

one green and one cobalt glass. The combination of the white ground and the smoke glasses with the reds and greens of the lower disc enables all atmospheric conditions to be imitated, and the lights to be diminished in brightness and tint. The use of the small openings enables size and distance to be imitated. The standard of normal color sense is taken as one-twelfth inch opening at twenty feet. A man failing to see the colored lights at this distance may have it increased six times by using the large openings. Again failing, he may approach to one foot and reveal a color sense equal to one-sixtieth only. Since the color blind depend alone on intensity of brightness to distinguish the white, green and red colors, the diminishing effect of the ground glass and of the London smoke often reveals the defect. The cobalt, transmitting blue and red both, is usually described by the color blind as blue, which color they always see well, although blind for red. The cobalt, combined with the lower red, gives a very deep red color, which, when compared with the usual red, may induce the color blind to name one red, the other green, when shown in turn. Combined with the lower blue it gives a deep pink, called blue by the color blind. In the pink, London smoke and light green glasses, in the upper disc, I have imitated the 'confusion colors.' The pink looks cherry red to the normal eye, but it transmits both red and blue by the spectroscope, hence

† This lantern is made by Queen & Co., 1010 Chestnut Street, Philadelphia.

the color blind pronounce it blue; or, when backed by the yellow kerosene flame, white. The light green is called white, as is also the light gray of the London smoke. Hence we have in these three glasses tints which the color blind name white and thus reveal the color defects. The upper disc has its seven openings marked by the letters of the alphabet, and the lower by the numerals from one to seven. The examination should be made in a darkened room, and the results reported on the blank now in use."

The test with a lantern in addition to the test with the colored worsteds, is a return in a modified way to the regulations of Professor Snellen for the Dutch railways. In an article by Dr. F. W. Edridge-Green in the London *Lancet*, for April 13, 1901, it is interesting to see how a number of men who have interested themselves in the tests for color-sense and have been firm supporters of the Holmgren method, are now beginning to believe that the ability to recognize a distant red or green signal light cannot always be determined by the Holmgren test alone.

Dr. C. H. Williams has reported several cases where the test with the Holmgren worsteds, or the stick, was passed without hesitation, but who failed badly with the lantern, and were unsafe men for railroad service. Another interesting fact which has been brought out by the use of the Williams lantern is that in some cases a man will be more confused and make more mistakes when shown two lights at a time than when only one light is shown. In one case on the Boston Elevated Railway a man who passed the worsted test without hesitation called a green light white and a yellow light white, when shown one light at a time with the small opening of the lantern; yet when shown two colors at one time with the larger opening, he was more confused and called a red light green once, a red light white three times, a yellow light white twice and a green light white three times. Another case, on the New Haven road, who made no mistake with the worsteds, and only the mistakes of calling a smoke glass green when one light was shown, made the following mistakes when shown two lights at a time: He called a red light green three times, a green light yellow once, a red light white once, a yellow light white twice, and a smoke glass red once.

CONCLUSION.

Your committee feel that no attempt should be made to compel the adoption of any standards or methods of examination by means of legislation; they believe the best results will be obtained by showing the operating officers of our railroads

how their service can be improved, by adopting methods of examination which will be reliable, and by maintaining standards which will be high, but not impracticable, for those entering the service, and will be the minimum of safety for old employes on re-examination.

Railroad officials are justly sceptical as to the value of certificates issued by physicians not connected with the road, especially when their fee is paid by the man who employs them and not by the company, and the following typical case may be quoted as a representative of a large number. A man had been examined by the company examiner (not a physician) and had been turned down, the record of his examination showing that he was dangerously defective in his color-perception. He then went to a physician, a graduate of one of the best of the medical schools in New York, who examined him and gave him the following certificate: "The undersigned has examined ..... for alleged defective eyesight and finds that he passes all the necessary tests for colors and print which are usually given to those who are supposed to be deficient in sight."

On re-examination this man, with the Williams lantern, called a red light green thirteen times, a green light white three times, a red light yellow six times, a green light yellow four times, a red light white four times, a yellow light red once, and out of twenty-nine times that a red light was shown him he only called it red six times. With the Holmgren worsteds he made the usual characteristic mistakes. When he presented himself for re-examination he produced from his pockets a number of pieces of colored glass and some skeins of colored worsted, all of which he named correctly; but the pieces of glass were of different sizes and shapes and the worsteds were tied together in bundles in such a way that it was easy for him to remember in each case the proper name for the color.

Experience has shown that excellent results can be obtained by having the examinations for vision, color-sense and hearing made by employes who have been carefully instructed by a trained ophthalmic surgeon in the methods to be followed, and who have been supplied by the railroad company with a complete and uniform outfit for making these tests. With a record of each examination filed at the central office, and especially when all the work is done under the supervision of an expert ophthalmic surgeon, and in accordance with instructions formulated by him, the results are likely to be much more satisfactory than when the work is left to physicians, or others, without fixed standards or methods, and with only such an outfit for making the tests as they may happen to have.

YOUR COMMITTEE RECOMMEND:

1. That all railroad employes concerned with the movement of trains or reading of signals be carefully examined as to their acuteness of vision, color-perception and hearing.

2. That a trained ophthalmic surgeon be selected by each company, who shall instruct and examine the men selected by the company to make these tests, shall recommend the standards and methods to be used, shall see that the equipment furnished to each examiner is sufficient, that it is kept in proper order and renewed when necessary, and who shall be the authority to whom the doubtful cases shall be referred for final settlement.

3. That the acuteness of vision shall be tested by the test types of Professor Snellen, or those which conform to his standards.

4. That the following minimum requirements be adopted for acuteness of vision:

	Entrance to service or promotion.	Re-examination of those in the service.
CLASS A.		
Enginemen (road service). Firemen (road service).	20/20 in each eye tested separately, without glasses.	20/30 with both eyes open without glasses. Each eye should also be tested separately and the vision of each noted.
CLASS B.		
Other employes in the engine, train or yard service, and car and engine inspectors.	20/20 in one eye and not less than 20/40 in the other. Tested separately without glasses.	20/40 with both eyes open, without glasses. Each eye should also be tested separately and the vision of each noted.
CLASS C.		
Towermen. Telegraph operators. Station agents. Section foremen.	20/20 in one eye and not less than 20/40 in the other. Tested separately with or without glasses.	20/40 with both eyes open with or without glasses. Each eye should also be tested separately and the vision of each noted.
CLASS D.		
Crossing flagmen.	20/40 with both eyes open, with or without glasses.	20/50 with both eyes open, with or without glasses.

5. That the color-perception be tested by means of the colored worsteds of Professor Holmgren, preferably with worsteds tagged for purposes of record; also, that in every case an additional test be made with a lantern showing a number of colored lights, which can be varied in their size and intensity.

6. That no one shall be considered to have satisfactory color-perception who calls a red light green, a green light red, a red light white, under any of the varying conditions of the lantern test; or who selects with the green and also with the rose test skeins the characteristic confusion colors.

7. That the hearing be tested by the spoken word of the examiner and by a watch or acoumeter, and that for entrance to the service a candidate be required to repeat correctly words or numbers spoken in an ordinary conversational tone at a distance of twenty feet; or, for re-examination, at a distance of ten feet.

8. That re-examinations be made at intervals of three years, also before promotion, and oftener in special cases, where necessary.

9. That a copy of this report be sent to the Secretary of the American Railway Association for transmission to their committee on safety appliances.

CHARLES H. WILLIAMS,
WILLIAM THOMSON,
WILLIAM S. DENNETT,
Committee.

July 17, 1901.

41
22